



NOTE

Internal Medicine

Antifungal drugs-low-susceptibility in *Aspergillus flavus* isolated from a captive reared Okinawa rail (*Hypotaenidia okinawae*)

Rui KANO^{1)*}, Meika TSUNOI¹⁾, Yumiko NAKAYA²⁾, Takashi NAGAMINE²⁾ and Koji ONO³⁾

¹⁾Department of Veterinary Dermatology, Nihon University College of Bioresource, 1866 Kameino, Fujisawa, Kanagawa 252-0880, Japan

²⁾Okinawa Wildlife Federation, 308 Maehara, Uruma, Okinawa 904-2235, Japan

³⁾Yambaru Wildlife Conservation Center, Ministry of the Environment, 1-15-15 Higawa, Naha, Okinawa 900-0022, Japan

J. Vet. Med. Sci.

83(1): 28–30, 2021

doi: 10.1292/jvms.20-0380

Received: 24 June 2020

Accepted: 29 October 2020

Advanced Epub:

13 November 2020

ABSTRACT. A four-month old female Okinawa rail (*Hypotaenidia okinawae*) presented with respiratory distress. Despite antifungal treatment with voriconazole (VRZ), micafungin (MCF), and itraconazole (ITZ), respiratory distress did not improve and the bird died 167 days after initiating treatment. Necropsy revealed multifocal pyogranulomatous necrotic nodular lesions with numerous whitish-green fungal hyphae in the left air sac. *Aspergillus flavus* was isolated from the left air sac lesion. Antifungal susceptibility tests indicated that the isolate showed low susceptibility to amphotericin B (AMB), fluconazole (FLZ), VRZ and MCF.

KEY WORDS: antifungal susceptibility tests, *Aspergillus flavus*, avian aspergillosis, Okinawa rail, low-susceptibility

Bronchial pneumonia and airsacculitis due to *Aspergillus* sp. are common diseases in avian species, such as parrots, raptors, and penguins [8]. *Aspergillus fumigatus* is the most prevalent aetiological causative agent isolated from aspergillosis cases in avian species, while *A. flavus*, *A. niger*, and other *Aspergillus* species are typically encountered less frequently [8].

The Okinawa rail (*Hypotaenidia okinawae*) is a flightless bird in the family Rallidae that is endemic to the northern forests zone of Okinawajima, Japan. In response to recent declines in wild populations of this bird, the species is listed as endangered in the Red List published by The International Union for Conservation of Nature (IUCN, 2017). Here we describe the case of an Okinawa rail exhibiting bronchial pneumonia and airsacculitis as a result of *A. flavus* infection. Moreover, *in vitro* antifungal susceptibility tests revealed that *A. flavus* showed low-susceptibility to antifungal drugs.

The four-month old female Okinawa rail was reared as part of an endangered species breeding program (“Protection and Recovery Program for the Okinawa Rail”) being conducted by the Okinawa Wildlife Federation and administered by the Ministry of the Environment of Japan. The concrete floor of the aviary (180 × 420 cm) that was used to house the rail was divided into two parts; one part was covered with soil and dead leaves and the other part was covered with gravel, so drainage was considered to be adequate. The cage was cleaned every 1 to 2 days. Since the one wall of the aviary was constructed of wire mesh, the rail was exposed to the same temperature and humidity conditions as the outdoor environment. The temperature inside the cage generally ranged from 10 to 35°C over the course of one year. Mitigation measures against cold weather conditions were implemented from mid-November when the average temperature drops below 20°C, and against hot weather conditions from around June when the average temperature typically exceeds 30°C. Humidity is high throughout the year, ranging from just below 70% in winter season to over 80% during the rainy season.

The Okinawa rails that were reared in this program were administered an artificial diet for Okinawa rail and ibis, vegetables, fruits, frozen smelt, canned crickets, and frozen meal worms. Bags of artificial feed were stored in an air-conditioned room at 25°C before they were opened, and refrigerated after opening. Fruits and vegetables were stored in a refrigerator.

The bird examined in this study presented with respiratory distress. Auscultation findings revealed increased breath sounds in the left abdominal air sac. X-ray examination revealed a high-density shadow in the left abdominal air sac.

Based on these findings, a fungal infection was considered most likely and antifungal treatment, including voriconazole [VRZ; 23.5 mg/kg/day, intramuscular (IM), single in day (SID) or bid in day (BID)], micafungin [MCF; 11.6 or 22.7 mg/kg, Subcutaneous injection (SC), SID or BID], and itraconazole (ITZ; 10 mg/kg, per os (PO), BID) was administered for 162 days.

*Correspondence to: Kano, R.: kanou.rui@nihon-u.ac.jp

©2021 The Japanese Society of Veterinary Science



This is an open-access article distributed under the terms of the Creative Commons Attribution Non-Commercial No Derivatives (by-nc-nd) License. (CC-BY-NC-ND 4.0: <https://creativecommons.org/licenses/by-nc-nd/4.0/>)

However, the respiratory distress did not improve. At 161 days, computed tomography (CT) revealed severe pneumonia and hyperplasia in the left abdominal air sac, and the bird died 167 days after the start of treatment. Necropsy revealed multifocal pyogranulomatous necrotic nodular lesions with numerous whitish-green fungal hyphae in the left air sac (Fig. 1), and histopathological examination showed hepatocellular degeneration.

Aspergillus flavus was isolated and identified based on morphological characteristics and molecular analysis using sequences of the internal transcribed spacer (ITS) region and the β -tubulin-encoding gene. Specimens for analysis were collected from necropsy samples collected from the left air sac. Isolation of genomic DNA from the isolate was performed as described previously [4].

The ITS region and β -tubulin-encoding gene of the *Aspergillus* isolate were amplified using the universal fungal primers ITS5 (5' GGAAGTAAAAGTCGTAACAAGC) and ITS4 (5' TCCTCCGCTTATTGATAGC), and the beta-tubulin primers, benA-F (5' AATTGGTGCCGCTTCTGG) and benA-R (5' AGTTGTCGGGACGGAATAG), respectively [9]. PCR amplification and sequence analysis were performed as described previously [5].

Comparative nucleotide sequence analysis using the Basic Local Alingment Search Tool (BLAST) algorithm on the National Center for Biotechnology Information (NCBI) website revealed that the ITS sequences were 99.8% identical to *A. flavus* (GenBank Accession nos. MT447545 and MT447532). The homology of beta-tubulin sequences was also 100% identical to *A. flavus* (GenBank Accession nos. MN882794 and MN882787). Based on these findings, the isolate was identified as *A. flavus*.

Susceptibility of the isolate to the antifungal drugs amphotericin B (AMB) and MCF was assessed *in vitro* by the E-test method [1, 10]. To assess the susceptibility of the fungal isolates to fluconazole (FLZ), ITZ, VRZ, posaconazole (PCZ), and terbinafine (TRF), were assessed by broth microdilution assays that were performed according to Clinical & Laboratory Standards Institute (CLSI) M38-A2 guidelines [7]. *Candida parapsilosis* ATCC 22019 was used as quality control for the E-test and for the control of the antifungals' potency in the broth microdilution assay.

The findings of the antifungal susceptibility tests indicated that the minimum inhibitory concentrations (MICs) of the clinical isolate were 32 mg/l for AMB, >32 mg/l for FLZ, 0.25 mg/l for ITZ, 2 mg/l for VRZ, 0.03 mg/l for PCZ, >32 mg/l for MCF, and 0.03 mg/l for TRF, which indicated that the isolate showed low susceptibility to AMB, FLZ, VRZ, and MCF.

Aspergillosis is typically an opportunistic respiratory infection, and host immunocompetence is considered to be an important determinant in the development of infection. However, we did not observe any evidence of either predisposal to infection or the route of infection in this case.

In avian medicine, the demonstration of lesions combined with isolation of *Aspergillus* remains the most commonly used method for the diagnosis of this infection [5].

The detection of antibodies to *Aspergillus* antigens by current enzyme-linked immunosorbent assay methods has been shown to be insufficiently sensitive or specific for the diagnosis of aspergillosis [8]. Another antigen detection method includes the measurement of galactomannan and beta-glucan in blood samples, but positive galactomannan results have only rarely been observed in experimentally infected falcons and in penguins with confirmed infection [8]. Therefore, future studies focusing on the development of simple diagnostic tools and effective therapy regimes for treating avian aspergillosis.

In this case, we isolated an *A. flavus* strain that showed low susceptibility to a variety of antifungal agents. Although the extent and mechanisms of azole resistance in *A. fumigatus* are well studied, [6] relatively few studies have examined resistance in *A. flavus* [11]. It is therefore considered that the true incidence of antifungal resistance in *Aspergillus* species may be much higher than expected, and thus, that routine *in vitro* susceptibility testing of all clinical *Aspergillus* isolates should be undertaken [11].

For many pathogenic fungi, antifungal resistance has been observed in patients receiving long-term antifungal therapy. In the present case, the *Aspergillus* strain was isolated from a bird that had been treated with antifungal drugs for more than five months.

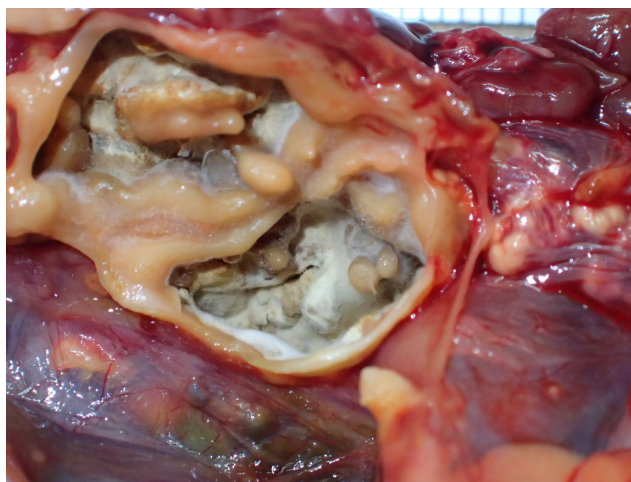


Fig. 1. Multifocal pyogranulomatous necrotic nodular lesions with numerous whitish-green fungal hyphae in the left air sac.

We speculate that the long-term nature of the antifungal regimen used in this study may have resulted in the development of azole resistance *in vivo* in the *A. flavus* strain isolated in this study.

The main route of resistance acquisition in *A. fumigatus* has been reported to be through exposure to azole fungicides present in the environment [6, 11]. Azole compounds are widely used for food production, plant protection, and material preservation [8]. In human cases, *A. flavus* infection is rarer than infection by *A. fumigatus*, although both fungal species are exposed to the same azole fungicides in the environment. Al-Wathiqi *et al.* and Araujo *et al.* reported that the MIC of azoles in environmental strains of *A. flavus* was lower than those of clinical isolates from human cases [2, 3].

A. flavus is more prevalent in the environment of some tropical areas that are abundant of rotten dead leaves on the soil [11]. Breeding of the Okinawa rail requires a breeding environment with dead leaves and soil that are similar to nature, but they are at risk of becoming a source of *Aspergillus* infection. Therefore, it is necessary to make improvements such as breeding materials that are reduced contamination of *Aspergillus*. Future studies should also be conducted to assess azole resistance in environmental strains of *A. flavus* in Japan.

Wildlife veterinarians should therefore be cautious about the prevalence of fungal infections due to fungal strains showing low susceptibility to antifungal agents. Although aspergillosis in the Okinawa rail is a rare infectious disease, we reported this case because the outcomes are potentially serious for birds.

DECLARATION OF INTEREST. The authors report no conflicts of interest. The authors alone were responsible for the content and writing of this paper.

REFERENCES

1. AB BIODISK. 2004. Etest technical guide 10, Antifungal Susceptibility Testing of Moulds, AB BIODISK, Solna.
2. Al-Wathiqi, F., Ahmad, S. and Khan, Z. 2013. Molecular identification and antifungal susceptibility profile of *Aspergillus flavus* isolates recovered from clinical specimens in Kuwait. *BMC Infect. Dis.* **13**: 126. [Medline] [CrossRef]
3. Araujo, R., Pina-Vaz, C. and Rodrigues, A. G. 2007. Susceptibility of environmental versus clinical strains of pathogenic *Aspergillus*. *Int. J. Antimicrob. Agents* **29**: 108–111. [Medline] [CrossRef]
4. Asano, M., Kano, R., Makimura, K., Hasegawa, A. and Kamata, H. 2011. Molecular typing and in-vitro activity of azoles against clinical isolates of *Aspergillus fumigatus* and *A. niger* in Japan. *J. Infect. Chemother.* **17**: 483–486. [Medline] [CrossRef]
5. Balajee, S. A., Kano, R., Baddley, J. W., Moser, S. A., Marr, K. A., Alexander, B. D., Andes, D., Kontoyiannis, D. P., Perrone, G., Peterson, S., Brandt, M. E., Pappas, P. G. and Chiller, T. 2009. Molecular identification of *Aspergillus* species collected for the Transplant-Associated Infection Surveillance Network. *J. Clin. Microbiol.* **47**: 3138–3141. [Medline] [CrossRef]
6. Chowdhary, A., Sharma, C. and Meis, J.F. 2017. Azole-resistant aspergillosis: epidemiology, molecular mechanisms, and treatment. *J. Infect. Dis.* **216** (suppl_3): S436–S444. [Medline]
7. CLSI. 2008. Reference Method for Broth Dilution Antifungal Susceptibility Testing of Filamentous Fungi; approved standard 2nd ed. CLSI document M38-A2. Clinical Laboratory Standards Institute, Wayne.
8. Hauck, R., Cray, C. and França, M. 2020. Spotlight on avian pathology: aspergillosis. *Avian Pathol.* **49**: 115–118. [Medline] [CrossRef]
9. Hinrikson, H. P., Hurst, S. F., Lott, T. J., Warnock, D. W. and Morrison, C. J. 2005. Assessment of ribosomal large-subunit D1-D2, internal transcribed spacer 1, and internal transcribed spacer 2 regions as targets for molecular identification of medically important *Aspergillus* species. *J. Clin. Microbiol.* **43**: 2092–2103. [Medline] [CrossRef]
10. Pfaller, M. A., Messer, S. A., Boyken, L., Hollis, R. J. and Diekema, D. J. 2003. *In vitro* susceptibility testing of filamentous fungi: comparison of Etest and reference M38-A microdilution methods for determining posaconazole MICs. *Diagn. Microbiol. Infect. Dis.* **45**: 241–244. [Medline] [CrossRef]
11. Rudramurthy, S. M., Paul, R. A., Chakrabarti, A., Mouton, J. W. and Meis, J. F. 2019. Invasive aspergillosis by *Aspergillus flavus*: epidemiology, diagnosis, antifungal resistance, and management. *J. Fungi (Basel)* **5**: 55 (Basel). [Medline] [CrossRef]