

# Clinical and endoscopic response to high dose rate endobronchial brachytherapy in malignant lung tumors: A single centre experience

Sneha Dhillon, Saurabh Bansal, Girish Sindhwani<sup>1</sup>, Meenu Gupta, Vipul Nautiyal, Sunil Saini<sup>2</sup>, Mushtaq Ahmad

## Abstract

**Purpose:** The aim of the study was to evaluate the short-term clinical, endoscopic response, and acute toxicities in endobronchial cancer treated with high-dose-rate endobronchial brachytherapy (HDR-EB). **Materials and Methods:** Thirty patients of advanced endobronchial cancers were treated with HDR-EB. Brachytherapy was delivered at a depth of 1 cm from the source axis at weeks 1, 2, and 3 with 7 Gy per fraction. All patients were evaluated before treatment and at 1 month after completion of therapy. Using Speiser's scoring criteria, the severity of symptoms (dyspnea, cough, hemoptysis, and postobstructive pneumonia) and degree of obstruction were graded. **Results:** Symptomatic response for cough, dyspnea, and hemoptysis was seen in 88%, 75%, and 96%, respectively, with a significant *P* value ( $<0.05$ ). Obstructive pneumonia was resolved in 94% of patients. Endoscopic response in terms of degree of obstruction was seen in 84% of patients. Acute toxicities in the form of radiation bronchitis were seen in 32% of patients, whereas 8% of patients experienced esophagitis. Bronchospasm was seen in one patient during treatment. **Conclusion:** HDR brachytherapy is a highly effective, safe, convenient therapy in alleviating symptoms of endobronchial obstruction with endoscopic response in the majority of cases. Thus, HDR-BT is a promising treatment for palliation of patients presenting with symptoms of endobronchial obstruction with an acceptable rate of complications.

**Key words:** Endobronchial obstruction, high-dose-rate brachytherapy, lung cancer

## Introduction

Lung cancer is one of the most common cancers and cause of cancer-related death all over the world. It accounts for 13% of all new cancer cases and 19% of cancer-related deaths worldwide.<sup>[1]</sup>

Only 20%–30% of all lung cancer patients are operable at diagnosis and only 40%–50% of them can be resected for cure. Most patients presenting with lung cancer have a locally advanced or metastatic disease at the time of presentation and are managed with radiotherapy and/or chemotherapy.<sup>[2]</sup> Nearly 30%–40% of these patients present with symptoms related to the endobronchial component, namely, cough, hemoptysis, shortness of breath, and postobstructive atelectasis with infection.<sup>[3]</sup>

Efforts to relieve this obstructive process are worthwhile to improve the quality of life. Until recently, the most common technologies used in these situations were laser photoresection and cryotherapy. External beam irradiation, although effective, may not be possible because of the proximity of dose-limiting structures adjacent to the tracheobronchial tree (i.e., esophagus and spinal cord).<sup>[4]</sup>

Brachytherapy is one of the most efficient methods in overcoming symptoms of endobronchial obstruction in the palliative treatment of tracheal and lung cancer with a significant improvement in the quality of life and performance status with acceptable toxicities.<sup>[5,6]</sup>

Cancer Research Institute, Dehradun, is the largest and single referral tertiary cancer center in the state of Uttarakhand, India. We present our experience of short-term clinical and endoscopic response and treatment-related acute toxicities in patients with malignant endobronchial tumors treated with high-dose-rate endobronchial brachytherapy (HDR-EB).

## Materials and Methods

### Patient selection

This prospective study was conducted in the Department of Radiation Oncology, Cancer Research Institute, SRHU

University, over a period of 12 months. Thirty patients with primary diagnosis of carcinoma lung and significant endobronchial component and symptoms, Eastern Cooperative Oncology Group Performance Status (ECOG PS)  $\geq 2$  were recruited after taking written informed consent and ethical clearance certificate from Institutional Ethics Committee. Exclusion criteria include informed consent not granted, impediments to bronchoscope catheter insertion, the presence of tracheoesophageal fistula, and bleeding disorders.

Speiser's scoring index was used for scoring the degree of endobronchial obstruction and the symptoms of hemoptysis, dyspnea, cough, and pneumonitis. The extent of tumor involvement was assessed by bronchoscopy and contrast-enhanced computed tomography chest.

### Treatment

EB was performed as an outpatient procedure. Transnasal fiberoptic bronchoscopy was performed to define the location and extent of tumor. Afterloading Lumincath applicator (a 6 French flexible nylon catheter) was introduced into the airway lumen and positioned at least 2 cm beyond to the visible tumor.

Brachytherapy planning was done with the help of Oncentra MasterPlan system. Computed tomography-based dose distribution was done with the aim of 95% of clinical target volume receive more than 90% of the prescribed dose [Figure 1]. The target volume was described at a depth of 1 cm from the source axis. Brachytherapy was delivered at weeks 1, 2, and 3 at 7 Gy per session using microselectron HDR remote afterloading unit (Nucletron) with an iridium-192 radioactive source [Figure 2].

All patients were evaluated clinically and with fiber-optic bronchoscopy 1 month after completion of therapy. Procedure and treatment-related toxicities were recorded. Radiation bronchitis was recorded using The Clinique Sainte Catherine grading system.

This is an open access journal, and articles are distributed under the terms of the Creative Commons Attribution-NonCommercial-ShareAlike 4.0 License, which allows others to remix, tweak, and build upon the work non-commercially, as long as appropriate credit is given and the new creations are licensed under the identical terms.

**For reprints contact:** reprints@medknow.com

**How to cite this article:** Dhillon S, Bansal S, Sindhwani G, Gupta M, Nautiyal V, Saini S, *et al.* Clinical and endoscopic response to high dose rate endobronchial brachytherapy in malignant lung tumors: A single centre experience. South Asian J Cancer 2018;7:267-9.

### Access this article online

#### Quick Response Code:



Website: www.sajc.org

DOI: 10.4103/sajc.sajc\_29\_18

Departments of Radiation Oncology, <sup>1</sup>Pulmonary Medicine and <sup>2</sup>Surgery Oncology, Cancer Research Institute, SRHU, Dehradun, Uttarakhand, India

**Correspondence to:** Dr. Saurabh Bansal,  
E-mail: drbansal1985@gmail.com

### Data management and statistical analysis

Interpretation and analysis of obtained results were carried out using software SPSS version 20 (IBM, Armonk, NY, USA). Categorical variables are expressed as frequencies and percentages. Wilcoxon sign test was used to determine the significant change in cough, degree of obstruction, obstruction pneumonia, etc., pre and posttreatment.  $P < 0.05$  was considered statistically significant.

### Results

The median age was 62 years (range 42–75). The subjects were predominantly male with male:female = 14:1. Squamous cell carcinoma was the most predominant histology (63.3%). Cough and hemoptysis were the most common symptoms and were seen in 90% of patients. Summary of baseline patient characteristics is shown in Table 1.

Out of 30 patients, 25 patients were able to complete the treatment and were analyzed 1 month posttreatment. Two patients were expired and three were defaulted during treatment and were not included in the analyses.

On posttreatment response assessment, all the patients had significant symptomatic relief with a significant  $P$  value ( $<0.001$ ) for all the symptoms analyzed [Table 2]. Cough was improved in 95.6% of patients with complete resolution in 43.4% of

patients. Complete response for dyspnea was seen in 30% of patients, whereas PR was seen in 65% of patients. Out of 23 patients presenting with hemoptysis, all of them have symptomatic relief posttreatment. Complete response was seen in 87% of patients and partial in 13% of patients. Sixteen patients presented with obstructive pneumonia and a complete response was seen in 12 patients, while partial in 3 patients.

All the patients had obstruction of  $>50\%$  at presentation. Endoscopic response was seen in 21 patients, while 4 patients had no change in degree of obstruction. Fifteen (60%) patients had a reduction of  $>50\%$  of their endobronchial component [Table 2].

The treatment-related morbidity was low, and there were no serious acute complications. Radiation bronchitis was seen in 8 (32%) patients, and esophagitis was seen in 2 (8%) patients. One patient experienced bronchospasm during treatment and was managed with inhaled beta-2 agonists. No fatal complications such as fistula, massive hemoptysis, and pneumothorax occurred.

### Discussion

Most of the patients diagnosed with lung cancer have a locally advanced or metastatic disease at the time of presentation and are not candidate for definitive/curative treatment.<sup>[7]</sup> Endobronchial obstruction and related symptoms worsen the quality of life in lung cancer patients. The most important consideration in these patients is to restore the patency of the airway.<sup>[8,9]</sup>

As a result, most of these patients are managed with palliative intent and various treatment options include laser therapy, external beam radiation therapy (EBRT), systemic therapy, and endobronchial brachytherapy (EBBT). Various studies have shown that EBBT is effective, safe, and convenient with limited toxicities as compared to other modalities. Although the advantages of this technique are well established in clinical practice, it lacks the benefit of robust randomized controlled trials. Many investigators have shown that patients treated with EBBT have a significant symptomatic response as well as improvement in performance status.<sup>[10,11]</sup>

As per literature, majority of the patients with endobronchial obstruction present with poor performance status. In our study, majority of the patients had an ECOG PS of 3 (66.7%). Similarly, Taulelle *et al.*<sup>[12]</sup> and Celebioglu *et al.* in their studies showed that  $>50\%$  of patients had a poor performance status  $\geq 2$ .<sup>[13]</sup>

There is a lack of consensus regarding doses and fractionation schedules and different investigators had used different HDR-EB protocols.<sup>[14]</sup> In the present study, patients were treated with HDR-EB with a dose of 7 Gy weekly for 3 weeks, which was close to the most effective fractionation scheme 7.5 Gy in

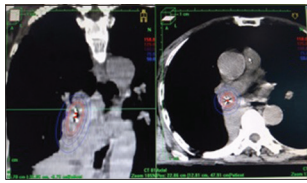
**Table 1: Baseline characteristics of patients**

Baseline characteristics	Our study (%)
Median age (years)	62
Sex ratio (male:female)	14:1
Performance status (%)	
2	33.3
3	66.7
Stage	
IIIA	316.7
IIIB	23.3
IV	60.0
HPE	
NSCLC-NOS	10.0
NSCLC-Adeno	13.3
NSCLC-SCC	63.3
Small cell carcinoma	13.3
Anatomical location	
Trachea/carina	2
Mainstem bronchus	11
Lobar bronchi	17
Percentage of bronchial obstruction (%)	
100	19
$>75$	6
$>50$	5

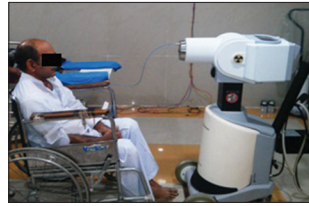NOS=Not otherwise specified, SCC=Squamous cell carcinoma, NSCLC=Non-small-cell lung carcinoma, HPE=Histopathological examination

**Table 2: Clinical and endoscopic results for the studied patients**

	Cough	Dyspnea	Hemoptysis	Obstructive pneumonia
Clinical response				
Pretreatment	23	20	23	16
Posttreatment				
Complete response	10	6	20	12
Partial response	12	13	3	3
$P$	$<0.001$	$<0.001$	$<0.001$	$<0.001$
Endoscopic response	$>50\%$ response	$<50\%$ response		No response
Number of patients	15	6		4



**Figure 1: Dose distribution of a treatment planning to main right bronchus lesion**



**Figure 2: Patient with a catheter in airway during treatment on high-dose-rate-microselectron**

three fractions once a week in the study done by Speiser and Spratling.<sup>[15]</sup>

Kubaszewska *et al.* showed that, in patients with poor performance status, single fraction of 10–15 Gy can be used, which is cost sparing and more convenient. On the other hand, in patients with good performance status, weekly treatment enables to have a better local control and effectively relieves the symptoms of endobronchial obstructions.<sup>[16]</sup>

All the patients had a good symptomatic relief in the presenting symptoms. Hemoptysis, cough, and dyspnea were improved in 100%, 95.6%, and 95% of patients, respectively. Symptomatic response for cough, dyspnea, and hemoptysis was seen in 88%, 75%, and 96%, respectively, with a significant *P* value (0.0001) in the analyses done by Escobar-Sacristán *et al.*<sup>[17]</sup> Similar response rates were also seen in the large series done by Gollins *et al.*<sup>[18]</sup> and Taulelle *et al.*<sup>[12]</sup>

At 1 month posttreatment, endoscopic response was seen in 84% of patients with more than 50% reduction of their endobronchial component in 15 patients. Gustafson *et al.*<sup>[4]</sup> reported that 64% of their patients had a 50% or greater reduction in the degree of obstruction.

In the present study, acute toxicities were reported in the form of radiation bronchitis (32% of patients), bronchospasm (4%), and esophagitis (8%).

The incidence of radiation bronchitis in the various studies reported in the literature is variable because of different HDR-EB protocols used as well as depending on whether used alone or with EBRT. In a study done by Anacak *et al.*,<sup>[19]</sup> the rate of radiation bronchitis reached as high as 70%. Dagnault *et al.* in their study showed an incidence of 46% radiation bronchitis when HDR-EB is given as 5 Gy per week for four sessions.<sup>[20]</sup>

Given these findings, we believe that HDR-EB can provide effective palliation and should be recommended in patients with a symptomatic endobronchial disease. For cost-sparing reasons, single dose treatment can be chosen in place of weekly repeated fractions.

## Conclusion

Our results support that HDR-EB is a highly effective, safe, convenient treatment for palliation of patients presenting with symptoms of endobronchial obstruction. The procedure was well tolerated with acceptable rate of complications and can be done as an outpatient procedure.

## Acknowledgment

Authors are highly thankful to SRH University for permitting this research study and Uttarakhand State Council for Science and Technology assistance in data management and compiling.

## Financial support and sponsorship

Nil.

## Conflicts of interest

There are no conflicts of interest.

## References

1. Ferlay J, Soerjomataram I, Ervik M, Dikshit R, Eser S, Mathers C, *et al.* Cancer Incidence and Mortality Worldwide. GLOBOCAN 2012 v1.0, IARC Cancer Base No 11. Lyon, France: International Agency for Research on Cancer; 2013. Available from: <http://www.globocan.iarc.fr>. [Last accessed on 2014 Jan 21].
2. Sedky L, Kamal KA, Kasenter AG. Endobronchial High Dose Rate Brachytherapy for control of NSCLC. *J Egypt Natl Cancer Inst* 2001;13:215-21.
3. Chang LF, Horvath J, Peyton W, Ling SS. High dose rate afterloading intraluminal brachytherapy in malignant airway obstruction of lung cancer. *Int J Radiat Oncol Biol Phys* 1994;28:589-96.
4. Gustafson G, Vicini F, Freedman L, Johnston E, Edmundson G, Sherman S, *et al.* High dose rate endobronchial brachytherapy in the management of primary and recurrent bronchogenic malignancies. *Cancer* 1995;75:2345-50.
5. Stewart A, Parashar B, Patel M, O'Farrell D, Biagioli M, Devlin P, *et al.* American brachytherapy society consensus guidelines for thoracic brachytherapy for lung cancer. *Brachytherapy* 2016;15:1-11.
6. Ozkok S, Karakoyun-Celik O, Goksel T, Mogulkoc N, Yalman D, Gok G, *et al.* High dose rate endobronchial brachytherapy in the management of lung cancer: Response and toxicity evaluation in 158 patients. *Lung Cancer* 2008;62:326-33.
7. Cavaliere S, Venuta F, Foccoli P, Toninelli C, La Face B. Endoscopic treatment of malignant airway obstructions in 2,008 patients. *Chest* 1996;110:1536-42.
8. Schray MF, McDougall JC, Martinez A, Cortese DA, Brutinel WM. Management of malignant airway compromise with laser and low dose rate brachytherapy. The mayo clinic experience. *Chest* 1988;93:264-9.
9. Cortese DA, Edell ES. Role of phototherapy, laser therapy, brachytherapy, and prosthetic stents in the management of lung cancer. *Clin Chest Med* 1993;14:149-59.
10. Barber P, Stout R. High dose rate endobronchial brachytherapy for the treatment of lung cancer: Current status and indications. *Thorax* 1996;51:345-7.
11. Sutedja G, Baris G, van Zandwijk N, Postmus PE. High-dose rate brachytherapy has a curative potential in patients with intraluminal squamous cell lung cancer. *Respiration* 1994;61:167-8.
12. Taulelle M, Chauvet B, Vincent P, Félix-Faure C, Buciarelli B, Garcia R, *et al.* High dose rate endobronchial brachytherapy: Results and complications in 189 patients. *Eur Respir J* 1998;11:162-8.
13. Celebioglu B, Gurkan OU, Erdogan S, Savas I, Köse K, Kurtman C, *et al.* High dose rate endobronchial brachytherapy effectively palliates symptoms due to inoperable lung cancer. *Jpn J Clin Oncol* 2002;32:443-8.
14. Skowronek J, Piorunek T, Kanikowski M, Chicheł A, Bielłda G. Definitive high-dose-rate endobronchial brachytherapy of bronchial stump for lung cancer after surgery. *Brachytherapy* 2013;12:560-6.
15. Speiser B, Spratling L. Fatal hemoptysis: Complication or failure of treatment. *Int J Radiat Oncol Biol Phys* 1993;25:925.
16. Kubaszewska M, Skowronek J, Chicheł A, Kanikowski M. The use of high dose rate endobronchial brachytherapy to palliate symptomatic recurrence of previously irradiated lung cancer. *Neoplasma* 2008;55:239-45.
17. Escobar-Sacristán JA, Granda-Orive JI, Gutiérrez Jiménez T, Delgado JM, Rodero Baños A, Saez Valls R. Endobronchial brachytherapy in the treatment of malignant lung tumours. *Eur Respir J* 2004;24:348-52.
18. Gollins SW, Burt PA, Barber PV, Stout R. Long-term survival and symptom palliation in small primary bronchial carcinomas following treatment with intraluminal radiotherapy alone. *Clin Oncol (R Coll Radiol)* 1996;8:239-46.
19. Anacak Y, Mogulkoc N, Ozkok S, Goksel T, Haydaroglu A, Bayindir U, *et al.* High dose rate endobronchial brachytherapy in combination with external beam radiotherapy for stage III non-small cell lung cancer. *Lung Cancer* 2001;34:253-9.
20. Dagnault A, Ebacher A, Vigneault E, Boucher S. Retrospective study of 81 patients treated with brachytherapy for endobronchial primary tumor or metastasis. *Brachytherapy* 2010;9:243-7.