

Successful auto-implantation of hepatic cells in lung tissue: An animal study

Gholamreza Mohajeri, Hessam Ghassemof, Mohammad Reza Mohajeri¹, Shahriar Adibi², Amir Hosein Davarpanah Jazi³

Department of Thoracic Surgery, School of Medicine, ¹Clinical Pathologist, ²Veterinary Surgeon, ³Medical Education Research Center, Isfahan University of Medical Sciences, Isfahan, Iran

Background: This study was proposed to evaluate a new method for autograft transplantation of liver tissue fragments (LTF) in the lung parenchyma and bronchus of dogs and to compare the results to find out if they are suitable sites for hepatocyte implantation or not. **Materials and Methods:** The dogs were randomly assigned into two categories: LTF auto-transplantation to the lung parenchyma and into the bronchus. The suspensions of normal saline and LTF were injected and implanted into the lung parenchyma and the main bronchus of the right accessory lobe in first and second groups, respectively. Two weeks later the right accessory lobe was removed and sent for a histopathological study. All samples were checked under a light microscope with regard to the presence of hepatocytes, with both the Hematoxylin and Eosin (H and E) preparation and immunohistochemistry (IHC) method, using a CK-18 marker. All results were double-checked with a polymerase chain reaction (PCR). **Results:** The mean weight of all the dogs was 19.87 ± 0.93 kg and mean age was 3.58 ± 0.31 years. After 15 days, the H and E, IHC, and PCR studies revealed that in the first group, all the dogs ($n = 4$) had living liver tissue, which survived in the lung parenchyma successfully. In contrast, none of the dogs ($n = 0$) in the second group showed surviving hepatocytes in the bronchus ($P < 0.001$). **Conclusion:** Implantation of the LTFs into the lung parenchyma could be a source of hepatic cell production.

Key words: Auto-transplantation, IHC, PCR

How to cite this article: Mohajeri G, Ghassemof H, Mohajeri MR, Adibi SH, Davarpanah Jazi AH. Successful auto-implantation of hepatic cells in lung tissue: An animal study. *J Res Med Sci* 2013;18:791-4.

INTRODUCTION

The liver is an important organ, responsible for protein synthesis and the metabolism of exogenous and endogenous substrates.^[1-3] Liver failure is a devastating syndrome caused by loss of hepatic cell mass below a critical level due to different diseases.^[4] After improvements in both surgical techniques and immunological protocols, liver transplantation has become the treatment of choice for patients suffering from end-stage liver disease,^[5] and management of liver failure has been revolutionized by transplantation of the whole liver or a portion of the liver.^[2,3]

Despite all benefits of liver transplantation, some major concerns, such as, chronic shortage of organs available for transplantation, growth of the number patients on waiting list, and side effects of the immunosuppressive drugs are still present.^[4,5]

Therefore, there is a gap between the demand and the availability of organs for transplantation. For this reason, several alternative methods have been used to reduce this gap.^[5] For instance, split-liver and living

donations have been widely used with appreciable outcomes.^[6,7]

Through hepatocyte proliferation, the liver is able to regenerate and produce adequate hepatic volume. Based on this phenomenon, the use of allograft-isolated liver parenchymal cells in the form of isolated hepatocyte or fragmented liver tissue has been investigated by many researchers.^[5,8,9] In addition to the liver, the histological similarity between the lungs and the liver (artery, vein, and bronchus in the lung versus artery, vein, and biliary duct in liver) makes the lungs a good option for hepatocyte transplantation; however, the lungs have strong immunological properties, which limit the success of this procedure. Besides, different extrahepatic sites including the spleen, renal subcapsular, omentum, and lung have been studied for the implantation of hepatocytes.^[10,11]

Although these new methods have been good solutions for shortage of the organ, the other important problem — need for immunosuppressive therapy — is still a hurdle.

Patients with liver failure have decreased complement levels and impaired phagocytic function; hence, they

Address for correspondence: Dr. Hassan Ghassemof, Department of Surgery, Al Zahra Hospital, Isfahan, Iran.
E-mail: hessam.ghassemof@yahoo.com

Received: 26-08-2012; **Revised:** 28-04-2013; **Accepted:** 06-07-2013

are very susceptible to bacterial and fungal infections.^[12,13] The need for immunosuppression in the presence of liver failure increases the risk of infections.^[14]

Using autograft hepatocyte transplantation instead of allograft transplantation can reduce the need for immunosuppressive drugs, and it consequently relieves the concerns related to this therapy.

Given the above-mentioned theories, this pilot study was proposed to evaluate a novel method for autograft transplantation of liver tissue fragments (LTF) in the lung parenchyma and bronchus of dogs and to compare the results, to find out whether or not they were suitable sites for hepatocyte implantation. In the next phase of the study, an operation would be performed to transplant the lung lobe to the abdomen with precise vascular techniques, for anastomosis. Although finding of normal liver tissue in systemic diseases such as acute liver failure or cirrhosis is impossible, in some conditions such as multiple liver metastasis and hepatocellular carcinoma (HCC), in multifocal cancers, we would be able to obtain normal hepatocytes from healthy parts of the liver. In this study, we just wanted to find out if hepatic cells could survive in the lung or not. If the answer was yes, then in the next phase we would implant more tissue in the lung and transplant it into the abdomen to generate a new liver lobe.

MATERIALS AND METHODS

This study was performed in the 'Safahan' Veterinary Hospital, Isfahan, Iran, with financial support from the Isfahan University of Medical Sciences during 2011-2012. The study protocol was approved by the Ethics Committees of the Isfahan University of Medical Sciences. Eight healthy, intact Persian male dogs aged between three and four years were included in the present study. All the dogs were normal on the physical examination performed prior to the study, had been completely vaccinated, and had received a complete course of anti-parasite medication. The dogs were randomly assigned to two categories: Liver tissue fragments (LTF) auto-transplantation to the lung parenchyma and LTF auto-transplantation into the bronchus.

After 12 hours of fasting, anesthesia was induced with Ketamine 20 mg/kg, and a cuffed endotracheal tube was inserted into the trachea. Then, the dogs were placed on mechanical respiration. Anesthesia was maintained by Nitrous oxide (N₂O) and Halothane. The dogs were placed in the left lateral decubitus position.

After the prep and drape, a 3-cm incision was made below the right side of the rib cage, and a 0.5 cm by 0.5 cm tissue sample of the liver was taken.

In an environment with high standards of sterility, the tissue was fragmented and mixed with 10 cc of normal saline, and a suspension of LTF in normal saline was prepared.

Next, an incision in the fourth intercostal area was made, and after a right lateral thoracotomy, the accessory lobe of the right lung was explored and the bronchus cut, in order to making a lobar atelectasis; the stump was repaired by separated sutures with Vicryl 3-0.

In the first group, the suspension of normal saline and LTF was injected and implanted into the lung parenchyma via a 14-gauge needle (an area with 3 cm diameter), and the area was marked with a nylon suture.

In the second group, the lung alveoli and bronchioles were destroyed by an injection of 10 cc ethanol 50%. Two minutes later, the injection site was completely washed out with normal saline before suctioning. Then, the suspension was injected into the main bronchus of the right accessory lobe, and the bronchus was closed with a Vicryl suture. The thoracotomy incision was closed, and the dogs were treated with appropriate doses of analgesics. In addition, a complete course of antibiotic therapy was commenced. After the operation, the dogs were visited by a veterinarian and the surgeon on a daily basis to check the general condition. All eight dogs completed the study.

Two weeks later, the dogs underwent thoracotomy at the same site again; the right accessory lobe was removed, put in the FineFix (Milestone, Bergamo, Italy) fixative, and sent for histopathological study.

All samples were checked under a light microscope, with both the H and E preparation and IHC method using a CK-18 marker, with regard to the presence of hepatocytes. All results were double-checked with the polymerase chain reaction (PCR). Survival of the hepatocytes after 15 days was considered as a successful implantation.

Data was analyzed using the SPSS 16 software and the Mann Whitney and Chi-square tests were also used; *P*-values less than 0.05 were considered as the level of significance.

RESULTS

There was no significant difference between the two groups in the mean weight and age (*P*: 0.81 and *P*: 0.67, respectively).

The mean weight of all dogs was 19.87 ± 0.93 kg (R: 18.6-21.00 kg), and the mean age was 3.58 ± 0.31 years (R: 3-4 years).

After 15 days of the LTF implantation, H and E and IHC study of the samples revealed that in the first group, all

four dogs had living liver tissue, which survived in the lung parenchyma successfully [Figure 1].

In contrast, none of the dogs in the second group showed survived hepatocytes in the bronchus.

All results were confirmed by PCR. Therefore, a significant difference between lung parenchyma and bronchus was evident in the survival of the implanted LTF ($P < 0.001$).

DISCUSSION

Several new alternatives for orthotopic hepatic transplantation are proposed for helping patients who need liver transplantation. Among these procedures, hepatic cell transplantation has had the most satisfactory results.^[15-23] This method helps to overcome the shortage of organ donation. Its advantages include lower invasiveness, lower cost, and preservation of the function and architecture of the host liver; however, other issues related to allograft transplantation are still present.^[20,21]

In acute liver failure and metabolic diseases, engraftment of the implanted cells or tissue is not efficacious, and hepatocytes cannot proliferate normally due to the quiescence of the host liver.^[24-26]

Therefore, it will be a good idea to implant liver cells primarily into an organ other than the liver for better proliferation. In the previous studies, different organs have been reported as being suitable sites for extrahepatic implantation of the hepatocytes.^[10,11] In all of these studies, the implanted hepatocytes have been non-autologous, and therefore, immunosuppressive therapy was needed.

This is the first study in which autologous LTFs have been implanted into the lung.

In order to explain this study, it is better to ask and answer some questions:

First, why did we use the lungs as the implantation site?

The structure of the lung and the liver are histologically similar. On account of the triple structures in the lung tissue

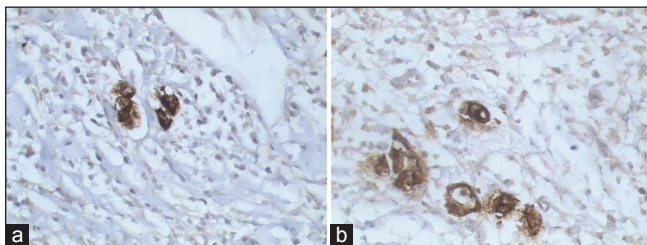


Figure 1 (a and b): The microphotographs of CK 18 staining revealed the presence of hepatocytes within the lung parenchymal tissue (400X)

(artery, vein, and bronchus) the probability of successful implantation of the liver tissue (which has triple structural parameters of the artery, vein, and biliary duct) may increase, for future autologous implantations. Hence, the lung can be a good candidate for extrahepatic hepatocyte implantation. In addition, having separated independent lobes help us to manipulate a part of the lung without any significant problem to the rest of the organ.

Results showed that although the lung parenchyma is a suitable site for hepatocyte implantation, the lung bronchus is not an appropriate host for hepatocytes. Survival of the hepatocytes in the lung parenchyma indicates that this site can be a good choice for implantation of hepatocytes in patients who are candidates for hepatocyte transplantation. This investigation shows that the lung parenchyma is a better site than the bronchus for the hepatocytes to stay alive and proliferate. Unlike the bronchus, which has a specific sort of tissue different to the liver, the lung parenchyma is more similar to the liver tissue. The blood supply of the lung parenchyma may help the LTF to survive.

Second, why use autologous LTFs?

Using autologous LTFs eliminates the need for immunosuppressive therapy, which is a problem associated with non-autologous or orthotopic liver transplantation.

Administration of immunosuppressive drugs in patients with liver failure increases the risk of infections, which are sometimes fatal.^[14]

The important hurdle in choosing the lungs as the host for implantation of hepatocytes is the immunological properties of the lung, which disturb the survival of non-autologous hepatocytes. This problem was solved in our study by using autologous LTFs.

Finally, why LTFs and not isolated hepatocytes?

Dissociation of single hepatocytes from the non-parenchymal cells and extracellular matrix (ECM) may lead to disturbance of the hepatocyte function, lack of survival signals, and consequently, apoptosis.^[27,28] In contrast, LTFs comprise all types of liver cells and ECM.^[29,30] Therefore, implanting LTFs instead of isolated hepatocytes increases the chance of survival of the implanted liver tissue.^[10]

Another important issue is that using autologous LTFs for treatment of patients with liver failure needs the availability and accessibility of healthy liver tissue; hence, healthy liver tissue should be extracted at early stages of the disease before the disease involves all the parts of the liver.

In this study we just wanted to determine if the liver cells could survive in the lung parenchyma as an alternative matrix for proliferation or not.

According to the findings of this pilot animal study, we suggest that autologous implantation of the LTFs into the lung parenchyma may be a good alternative for the previous methods. For example, the lung parenchyma can replace the very expensive and technically difficult tissue engineering methods. Lung lobectomy has been tolerated by the animals and also patients without any major problem.

For extrapolation of these findings, more studies on a larger number of cases are needed.

The practical goal of this study, in future, is to produce a new liver lobe by extracting healthy liver tissue and implanting LTFs in a lung lobe with multiple injections and transplanting this lobe into the abdomen, which is our goal for next phase of the present project.

ACKNOWLEDGMENTS

No financial support has been received in support of the study. The research project number is 390123.

REFERENCES

- Gewartowska M, Olszewski WL. Hepatocyte transplantation-biology and application. *Ann Transplant* 2007;12:27-36.
- Muiesan P, Girlanda R, Jassem W, Melendez HV, O'Grady J, Bowles M, *et al.* Single-center experience with liver transplantation from controlled non-heartbeating donors: A viable source of grafts. *Ann Surg* 2005;242:732-8.
- Lucey MR, Terrault N, Ojo L, Hay JE, Neuberger J, Blumberg E, *et al.* Long-term management of the successful adult liver transplant: 2012 practice guideline by the American Association for the Study of Liver Diseases and the American Society of Transplantation. *Liver Transpl* 2013;19:3-26.
- Ogawa S, Miyagawa S. Potentials of regenerative medicine for liver disease. *Surg Today* 2009;39:1019-25.
- Baccarani U, Sanna A, Cariani A, Sainz-Barriga M, Adani GL, Zambito AM, *et al.* Isolation of human hepatocytes from livers rejected for liver transplantation on a national basis: Results of a 2-year experience. *Liver Transpl* 2003;9:506-12.
- EB K. Liver transplantation: Current status and novel approaches to liver replacement. *Gastroenterology* 2001;120:749-62.
- Gridelli B, Remuzzi G. Strategies for making more organs available for transplantation. *N Engl J Med* 2000;343:404-10.
- Sauer IM, Obermeyer N, Kardassis D, Theruvath T, Gerlach JC. Development of a hybrid liver support system. *Ann N Y Acad Sci* 2001;944:308-19.
- Allen KJ, Soriano HE. Liver cell transplantation: The road to clinical application. *J Lab Clin Med* 2001;138:298-312.
- Katchman H, Tal O, Eventov-Friedman S, Shezen E, Aronovich A, Tchorsh D, *et al.* Embryonic porcine liver as a source for transplantation: Advantage of intact liver implants over isolated hepatoblasts in overcoming homeostatic inhibition by the quiescent host liver. *Stem Cells* 2008;26:1347-55.
- Soto-Gutierrez A, Navarro-Alvarez N, Yagi H, Yarmush ML. Stem cells for liver repopulation. *Curr Opin Organ Transplant* 2009;14:667-73.
- Iida T, Kaido T, Yagi S, Yoshizawa A, Hata K, Mizumoto M, *et al.* Posttransplant bacteremia in adult living donor liver transplant recipients. *Liver Transpl* 2010;16:1379-85.
- Rolando N, Harvey F, Brahm J, Philpott-Howard J, Alexander G, Gimson A, *et al.* Prospective study of bacterial infection in acute liver failure: An analysis of fifty patients. *Hepatology* 1990;11:49-53.
- Rust C, Gores GJ. Hepatocyte transplantation in acute liver failure: A new therapeutic option for the next millennium? *Liver Transpl* 2000;6:41-3.
- Strom SC, Fisher RA, Thompson MT, Sanyal AJ, Cole PE, Ham JM, *et al.* Hepatocyte transplantation as a bridge to orthotopic liver transplantation in terminal liver failure. *Transplantation* 1997;63:559-69.
- Smets F, Najimi M, Sokal EM. Cell transplantation in the treatment of liver diseases. *Pediatr Transplant* 2008;12:6-13.
- Shao X, Qian Y, Xu C, Hong B, Xu W, Shen L, *et al.* The protective effect of intrasplenic transplantation of Ad-IL-18BP/IL-4 gene-modified fetal hepatocytes on ConA-induced hepatitis in mice. *PLoS One* 2013;8:e58836.
- Dhawan A, Mitry RR, Hughes RD, Lehec S, Terry C, Bansal S, *et al.* Hepatocyte transplantation for inherited factor VII deficiency. *Transplantation* 2004;78:1812-4.
- Muraca M, Gerunda G, Neri D, Vilei MT, Granato A, Feltracco P, *et al.* Hepatocyte transplantation as a treatment for glycogen storage disease type 1a. *Lancet* 2002;359:317-8.
- Bilir BM, Guinette D, Karrer F, Kumpe DA, Krysl J, Stephens J, *et al.* Hepatocyte transplantation in acute liver failure. *Liver Transpl* 2000;6:32-40.
- Habibullah CM, Syed IH, Qamar A, Taher-Uz Z. Human fetal hepatocyte transplantation in patients with fulminant hepatic failure. *Transplantation* 1994;58:951-2.
- Dhawan A, Mitry RR, Hughes RD. Hepatocyte transplantation for metabolic disorders, experience at King's College hospital and review of literature. *Acta Gastroenterol Belg* 2005;68:457-60.
- Ambrosino G, Varotto S, Strom SC, Guariso G, Franchin E, Miotto D, *et al.* Isolated hepatocyte transplantation for Crigler-Najjar syndrome type 1. *Cell Transplant* 2005;14:151-7.
- Fox IJ, Chowdhury JR, Kaufman SS, Goertzen TC, Chowdhury NR, Warkentin PI, *et al.* Treatment of the Crigler-Najjar syndrome type I with hepatocyte transplantation. *N Engl J Med* 1998;338:1422-6.
- Gupta S, Aragona E, Vemuru RP, Bhargava KK, Burk RD, Chowdhury JR. Permanent engraftment and function of hepatocytes delivered to the liver: Implications for gene therapy and liver repopulation. *Hepatology* 1991;14:144-9.
- Ponder KP, Gupta S, Leland F, Darlington G, Finegold M, DeMayo J, *et al.* Mouse hepatocytes migrate to liver parenchyma and function indefinitely after intrasplenic transplantation. *Proc Natl Acad Sci U S A* 1991;88:1217-21.
- Zvibel I, Smets F, Soriano H. Anoikis: Roadblock to cell transplantation? *Cell Transplant* 2002;11:621-30.
- Kumaran V, Joseph B, Benten D, Gupta S. Integrin and extracellular matrix interactions regulate engraftment of transplanted hepatocytes in the rat liver. *Gastroenterology* 2005;129:1643-53.
- Joseph B, Berishvili E, Benten D, Kumaran V, Lipoava E, Bhargava K, *et al.* Isolated small intestinal segments support auxiliary livers with maintenance of hepatic functions. *Nat Med* 2004;10:749-53.
- Seller MJ. Prolonged survival of fragments of liver transplanted to an ectopic site in the mouse. *Anat Rec* 1972;172:149-55.

Source of Support: Nil, Conflict of Interest: None declared.