

# Relapsing sepsis episodes of *Escherichia coli* with CTX-M ESBL or derepressed *ampC* genes in a patient with chronic autoimmune pancreatitis complicated by IgG4 hypergammaglobulinaemia

T. Tuuminen<sup>1,2</sup>, M. Österblad<sup>3</sup>, S. Hämäläinen<sup>4</sup> and R. Sironen<sup>5,6,7</sup>

1) Eastern Finland Laboratory Centre Joint Authority Enterprise (ISLAB), Mikkeli District Laboratory, Mikkeli, 2) Department of Bacteriology and Immunology, Haartman Institute, University of Helsinki, Helsinki, 3) Bacterial Infections Unit, Department of Infectious Diseases, National Institute for Health and Welfare, Turku, 4) Department of Medicine, 5) Imaging Center, Clinical Pathology, Kuopio University Hospital, 6) Institute of Clinical Medicine, Pathology and Forensic Medicine and 7) Biocenter Kuopio and Cancer Center of Eastern Finland, University of Eastern Finland, Kuopio, Finland

## Abstract

Bloodstream recurrent infections have been reported for a variety of opportunistic bacteria. These are often either catheter related or are caused by indwelling devices. A case of relapsing sepsis with two *Escherichia coli* strains carrying extended-spectrum  $\beta$ -lactamase and derepressed *ampC* genes is reported. The patient had seven episodes of bloodstream infections within 1 year and was diagnosed with chronic autoimmune pancreatitis and IgG4 hypergammaglobulinaemia. Abscesses were found in his spleen and pancreas cauda, which was finally resected. Relapses of bacteraemia with resistant enterobacteria should be considered during perioperative protection. Surgical removal of the infective focus could be curative.

New Microbes and New Infections © 2015 The Authors. Published by Elsevier Ltd on behalf of European Society of Clinical Microbiology and Infectious Diseases.

**Keywords:** Autoimmune pancreatitis, bacteraemia, ESBL, IgG4 hypergammaglobulinaemia, relapsing sepsis

**Original Submission:** 3 September 2015; **Revised Submission:** 14 October 2015; **Accepted:** 26 October 2015

**Article published online:** 30 November 2015

**Corresponding author:** T. Tuuminen, Eastern Finland Laboratory Centre Joint Authority Enterprise (ISLAB), Mikkeli District Laboratory, Porrassalmenkatu 35-37, Mikkeli FI-50100, Finland  
**E-mail:** [tamara.tuuminen@islab.fi](mailto:tamara.tuuminen@islab.fi)

## Introduction

Recurrent bloodstream infections are either reinfections or relapses caused by the same strain. Bloodstream recurrent infections have been reported for a great variety of opportunistic bacteria, with coagulase-negative staphylococci being the most common [1]. The majority of the relapsing sepsis infections are either catheter related or are caused by indwelling devices that serve as an excellent solid phase for sticky biofilms, the source for transient bacterial translocation into the vessel lumen. Relapsing *Escherichia coli* bacteraemias have also been described

[2–5]. Molecular fingerprinting [2,3] as well as biochemical analysis and serotyping [4] have shown that the majority of the sepsis episodes might be caused by the same strain even when adequate antimicrobial therapy is provided. Taking into account the multistrain and multispecies complexity of biofilm, it remains unclear why sepsis episodes are often caused by exactly the same strain and what kind of “leads” this strain may have compared to other “inhabitants” of the biofilm ecosystem.

Here we report a case of recurrent *E. coli* sepsis. Altogether, the patient experienced seven episodes of *E. coli* bacteraemia in just over a year. All the episodes can be considered as relapses caused by the extended-spectrum  $\beta$ -lactamase (ESBL) strain or by the AmpC hyperproducer. Finally, the focus of these bloodborne infections was found in his spleen and pancreas cauda, which was resected. Of interest, the underlying disease, autoimmune pancreatitis of type I with IgG4 hypergammaglobulinaemia, had probably contributed to the formation of the cyst that harboured infection.

### Case Report

A 47-year-old man came to Finland as a refugee from Southeast Asia. In the immigration health inspection, he was diagnosed with a *Toxocara canis* infection and treated with mebendazole. Soon after arrival, he complained of epigastric pain and fever; he was diagnosed with acute pancreatitis, which was treated conservatively. After this episode, the patient gave up alcohol completely. Pancreatitis episodes, often complicated with septicæmias, recurred several times during the following years. Radiologic findings confirmed chronic pancreatitis with calcifications. Papillotomy, dilatation and stent insertion into the strictured ductus Wirsung were performed. Written informed consent was obtained from the patient.

Three years after the first pancreatic episode, the patient was hospitalized again for fever and multiple liver abscesses. Abscesses were also found in the spleen and pancreas. Blood cultures revealed *Lactococcus* species. Drainage of abscesses was not feasible because of the small size of the multiple abscesses and the challenging anatomic site. An infection of the pancreatic duct stent was suspected, and the stent was removed. ESBL-producing *Escherichia coli* septicaemia complicated the surgical intervention. The condition progressed despite long-term antimicrobial therapy.

The patient was negative for parasitic infection, HIV, and *Echinococcus* serology. Instead, *Toxocara canis* serology remained positive, compatible with his early infection. During the following months, the patient was hospitalized several times for recurrent pancreatitis and relapsing episodes of sepsis. The laboratory data on the blood culture isolates are presented in Table 1.

Abscess formation continued even though the patient received various antimicrobials (Tables 2 and 3). Eventually cholecystectomy, splenectomy and a partial pancreatic resection were considered. In addition to resection of the pancreatic cauda, the enlarged spleen was removed, and cholecystectomy was performed. Histopathologic examination of the pancreas revealed extensive fibrosis, multiple cysts (1–2 cm in diameter)

**TABLE 2. Antibiotic treatment of patient in periods between bacteraemia episodes**

Date	Duration of administration (days)					
	TZP	CIP	ETP	VAN	MEM	CXM
April 2013	3					7
March 2013			9	14	14	
May 2013			18	19	19	
August 2013			14			2
December 2013	4	4				
February 2014			13			
March 2014	7		13			
		7	3			
April 2014		7	5			
May 2014	2				14	
			14	14		

CIP, ciprofloxacin; CXM, cefuroxime; ETP, ertapenem; MEM, meropenem; TZP, piperacillin–tazobactam; VAN, vancomycin.

and inflammatory cells such as neutrophils, macrophages, lymphocytes and plasma cells that were partly immunopositive for IgG4. Histology revealed no microorganisms. The hilum of the spleen revealed purulent inflammation, but the splenic parenchyma and gallbladder were structurally normal. Computed tomographic scan revealed numerous degenerative cystic lesions in the spleen that most probably had formed as a result of prolonged bacterial infection (Fig. 1). A pseudocyst filled with a grey fluid was found between the pancreatic cauda and the spleen. ESBL *E. coli* was isolated from the fluid. All other tissue cultures were negative in bacteriologic, mycobacteriologic, virologic and parasitologic examinations. These findings finally confirmed suspected end-stage chronic autoimmune pancreatitis associated with the IgG4 syndrome [6]. During convalescence, the patient had a relapse of ESBL *E. coli* sepsis but recovered completely.

The strains were tested for β-lactamase genes as previously described [7]. All 3 ESBL isolates harboured a *CTX-M* gene. Three other *E. coli* isolates (Table 1) had an AmpC phenotype and were negative for *ampC* genes (*CIT*, *DHA*, *MOX*, *FOX*, *EBC*,

**TABLE 1. Characteristics of isolated *Escherichia coli* strains from blood culture samples and pancreatic cyst**

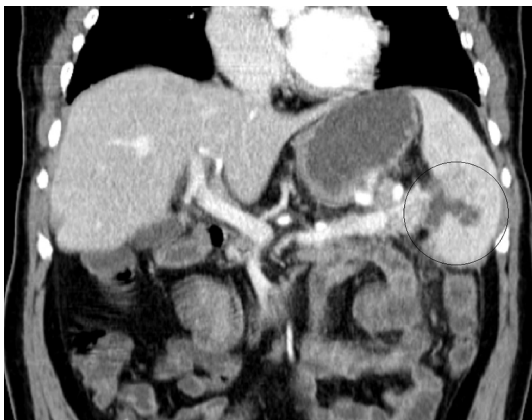Sepsis episode	Organism	Antimicrobial susceptibility (mm) (interpretation)										
		TZP	CIP	TOB	SXT	ETP	MEM	NET	ATM	CRO	CXM	CAZ
April 2013	ESBL <i>E. coli</i>	22 (I)	6 (R)	20 (S)	6 (R)	30 (S)	30 (S)	20 (S)	21 (I)	ND	ND	ND
May 2013	ESBL <i>E. coli</i>	22 (I)	6 (R)	20 (S)	6 (R)	30 (S)	30 (S)	20 (S)	21 (I)	ND	ND	ND
August 2013	AmpC <i>E. coli</i>	24 (S)	35 (S)	22 (S)	27 (S)	28 (S)	29 (S)	ND	23 (I)	27 (S)	18 (S)	21 (I)
November 2013	AmpC <i>E. coli</i>	24 (S)	35 (S)	22 (S)	27 (S)	28 (S)	29 (S)	ND	23 (I)	27 (S)	18 (S)	21 (I)
March 2014	AmpC <i>E. coli</i>	24 (S)	35 (S)	22 (S)	27 (S)	28 (S)	29 (S)	ND	23 (I)	27 (S)	18 (S)	21 (I)
March 2014	ESBL <i>E. coli</i>	25 (I)	6 (R)	20 (S)	6 (R)	27 (S)	30 (S)	ND	18 (R)	ND	ND	ND
May 2014	ESBL <i>E. coli</i>	25 (I)	6 (R)	20 (S)	6 (R)	27 (S)	30 (S)	ND	18 (R)	ND	ND	ND

CAZ, ceftazidime; CIP, ciprofloxacin; CRO, ceftriaxone; CXM, cefuroxime; ESBL, extended-spectrum β-lactamase; ETP, ertapenem; I, intermediate; MEM, meropenem; ND, not determined; NET, netilmicin; R, resistant; S, susceptible; TOB, tobramycin; TZP, piperacillin–tazobactam.

**TABLE 3.** Drug dosages and routes

Drug abbreviation	Drug name	Dosages (per day)	Administration route
CXM	Cefuroxime	1.5 g × 3	iv
TZP	Piperacillin–tazobactam	4 g × 3	iv
MEM	Meropenem	1 g × 3	iv
ETP	Ertapenem	1 g × 1	iv, po
VAN	Vancomycin	1 g × 2	iv
CIP	Ciprofloxacin	500 mg × 2	po

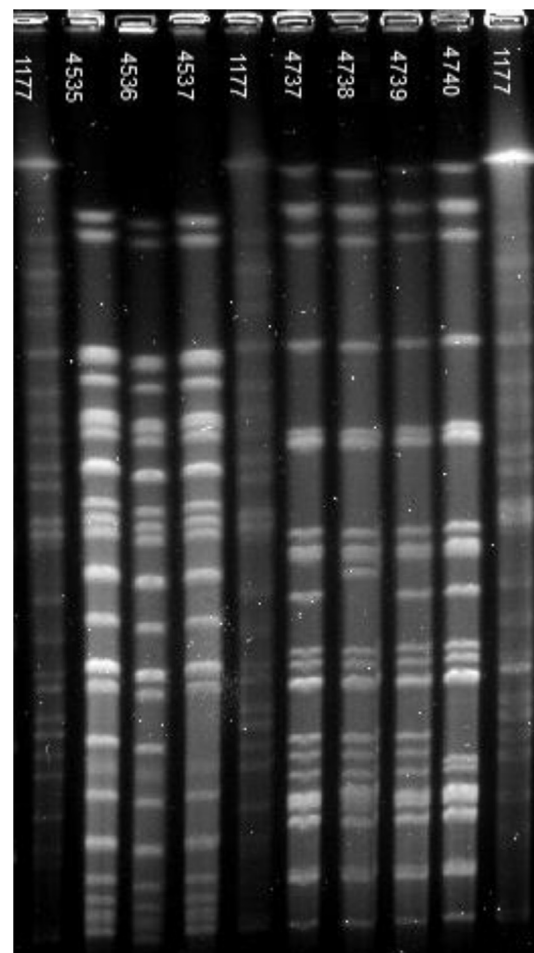
iv, intravenous; po, by mouth.



**FIG. 1.** Radiologic description of computed tomographic scan of the body (shortened). Liver is diffusely fatty without clear features of cirrhosis. Spleen is enlarged, with craniocaudal dimension of 14 cm. In hilus region there are small fingerlike liquid retentions that could be traits of abscesses or pseudocysts. Prominent lymphatic node is evident between ventricle and spleen, with dimension of 11 mm. Corpus and cauda of pancreas are atrophic; ducts are widened, maximum 7–8 mm at corpus region. Abundance of calcified lesions in caput is compatible with chronic pancreatitis. Region of abscesses in spleen is circled. Breathing artifact is evident in abdominal region.

ACC), thus apparently overproducing the chromosomal AmpC. In order to investigate the clonality of the strains, we performed molecular typing. The culture isolates were analysed with pulsed-field gel electrophoresis using a protocol based on PulseNet for *E. coli* (<http://www.cdc.gov/pulsenet/pathogens/ecoli.html>). Briefly, genomic DNA was digested with *Xba*I (New England Biolabs), and separated in a Chef DR III (Bio-Rad). Banding patterns were interpreted using the criteria of Tenover *et al.* [8]. The ESBL isolates were found to be the same strain (one- to two-band differences in the banding patterns). The AmpC overproducers were also similar (a one-band difference in one isolate); however, they were different from the ESBL clone (Fig. 2).

Soon after the surgical intervention, our patient experienced a new episode of ESBL sepsis—a complication that might have



**FIG. 2.** Pulsed-field gel electrophoresis of strains. Lanes 1, 5 and 10, control strain; lanes 2–4, 2 AmpC overproducer; lanes 6–9, ESBL strain. ESBL, extended-spectrum  $\beta$ -lactamase.

been avoided if previous bacteriologic data had been taken into account so perioperative carbapenem prophylaxis could have been implemented.

## Discussion

The reported case emphasizes that the primary prevention of bloodstream relapses caused by Gram-negative bacteria is the surgical elimination of the focus of infection. Being encapsulated in a cyst, the bacteria are well protected against the bactericidal action of antimicrobials even in organs with good vascularization such as the pancreas.

Relapses of bacteraemia with enterobacteria can occur in patients with underlying gastrointestinal or autoimmune disorders, as in our case. These episodes can be caused by resistant bacteria, which should be considered during

perioperative protection after the first sepsis episode. Surgical removal of the focus of infection could be curative.

### Conflict of Interest

---

None declared.

### References

---

- [1] Kumar A, Kethireddy S, Darovic GO. Catheter-related and infusion-related sepsis. *Crit Care Clin* 2013;29:989–1015.
- [2] Sanz-García M, Fernández-Cruz A, Rodríguez-Crèixems M, Cercenado E, Marin M, Muñoz P, et al. Recurrent *Escherichia coli* bloodstream infections: epidemiology and risk factors. *Medicine (Baltimore)* 2009;88:77–82.
- [3] Maslow JN, Mulligan ME, Arbeit RD. Recurrent *Escherichia coli* bacteremia. *J Clin Microbiol* 1994;32:710–4.
- [4] Brauner A, Kaijser B, Kühn I. Recurrent *Escherichia coli* bacteremia—clinical characteristics and bacterial properties. *J Infect* 1994;28:49–57.
- [5] Al-Hasan MN, Eckel-Passow JE, Baddour LM. Recurrent Gram-negative bloodstream infection: a 10-year population-based cohort study. *J Infect* 2010;61:28–33.
- [6] O'Reilly DA, Malde DJ, Duncan T, Rao M, Filobos R. Review of the diagnosis, classification and management of autoimmune pancreatitis. *World J Gastrointest Pathophysiol* 2014;5:71–81.
- [7] Nyberg SD, Österblad M, Hakanen AJ, Huovinen P, Jalava J, Resistance TF. Detection and molecular genetics of extended-spectrum beta-lactamases among cefuroxime-resistant *Escherichia coli* and *Klebsiella* spp. isolates from Finland, 2002–2004. *Scand J Infect Dis* 2007;39:417–24.
- [8] Tenover F, Arbeit R, Goering R, Mickelsen P, Murray B, Persing D, Swaminathan B. Interpreting chromosomal DNA restriction patterns produced by pulsed field gel electrophoresis: criteria for bacterial strain typing. *J Clin Microbiol* 1995;33:2233–9.