



Cervical Mass Following Carotid Attempt at Interventional Repair of Aortic Coarctation: a case report

Ali Dabbagh, MD*, Manuchehr Hekmat, MD, Arash Ghanavati, MD, Abdolrahim Ghasemi, MD

Shahid Modarres Hospital, Shahid Beheshti University of Medicine (SBMU), Tehran, Iran.

Received 27 November 2008; Accepted 25 April 2009

Abstract

A 4-month-old boy was admitted to our hospital following an unsuccessful attempt at interventional repair of aortic coarctation via the right carotid artery, which seemed to have given rise to the formation and growth of a cervical mass overlying the entry site. Despite the initial anticipation of difficulty during intubation due to the pressure effect of the mass, anesthesia progressed uneventfully, the mass, which was a hematoma, was evacuated, and the coarctation was repaired. The patient was discharged after the operation. At three weeks' follow-up, there was no significant lesion in the neck and transthoracic echocardiography demonstrated no residual coarctation.

J Teh Univ Heart Ctr 1 (2010) 39-41

Keywords: Neck • Aortic coarctation • Carotid arteries

Introduction

Penetrating carotid artery trauma may occur in consequence of incidental puncture during a number of procedures like the insertion of central venous catheters, which, if not performed meticulously, could give rise to a number of untoward complications.¹ Penetrating carotid artery trauma may also happen during many rare instances when the carotid artery is used as a portal for angiography, interventional angioplasty, extracorporeal membrane oxygenation (ECMO), etc.

This manuscript presents a case of neck hematoma in the wake of carotid artery trauma sustained during an unsuccessful attempt at interventional repair of aortic coarctation. The complication was treated surgically under general anesthesia, during which the cervical mass was evacuated and the coarctation was repaired.

Case presentation

A 4-month-old boy was admitted to our university hospital due to an enlarged cervical mass following carotid attempt at interventional repair of aortic coarctation diagnosed via transthoracic echocardiography. The patient had previously been referred to the pediatric catheterization lab for the definite repair of the coarctation as well as pressure gradient correction; however, initial attempts at introducing the guidewire into the arterial system (first femoral, then brachial, and finally right carotid) failed. The patient was thereafter transferred to the ward for further treatment, but his parents chose to take him home. Three weeks later, the patient was admitted to the operating room for an emergency operation to evaluate and possibly evacuate the mass and also to assess and repair the carotid artery rupture and coarctation (Figures 1 and 2). Before the decision for surgery had been made, a Doppler examination of the carotid

*Corresponding Author: **Ali Dabbagh**, Associate Professor of Cardiac Anesthesiology, Anesthesiology Research Center and School of Medicine, Shahid Beheshti University of Medicine, Shahid Modarres Hospital, Sa'adat Abad, Tehran, Iran. 1998734383. Tel: +98 912 1972368. Fax: +98 21 22074101. E-mail: alidabbagh@yahoo.com.

artery ruled out a pseudoaneurysm of the carotid artery under the hematoma. Volatile anesthetics, supplemented with ketamine, were planned for the patient; and under standard non-invasive monitoring, 3mg/Kg intramuscular ketamine plus 1.5% halothane was administered. With the patient breathing spontaneously under deeper levels of anesthesia, laryngoscopy showed that the glottis was not difficult for intubation. A peripheral intravenous line was established for muscle relaxants, and the trachea was intubated without any need for extra devices. Additionally, an arterial line in the right brachial artery was established to commence invasive arterial monitoring. The left subclavian approach was chosen for the insertion of the central venous line at the first attempt, which demonstrated the central venous pressure waveform.

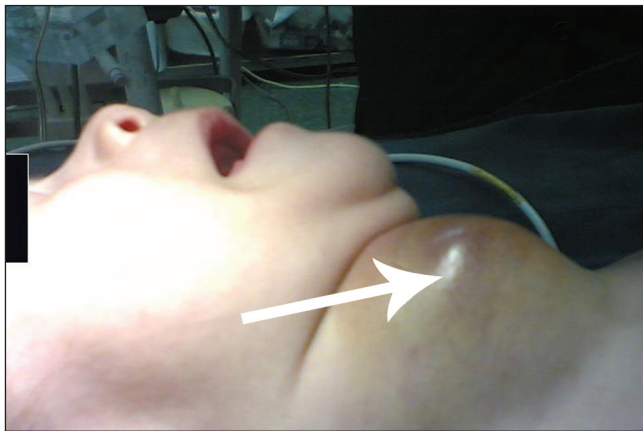


Figure 1. Lateral view of the mass (arrow)

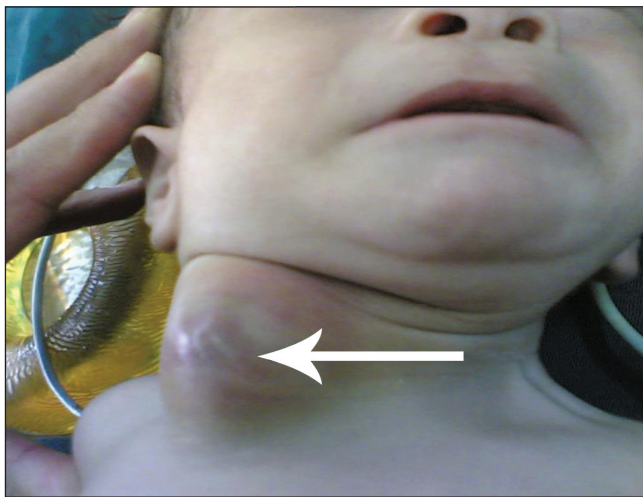

Figure 2. Anteroposterior view of the mass (arrow)

The patient was operated on in the supine position with a roll below the neck to extend the neck gently and produce a "thyroid position". The surgical approach was initially based on making the proximal and distal control of the right external carotid, but the hugeness of the cervical mass rendered it impossible. The skin over the mass was, therefore, gradually dissected and the mass, which was a hematoma around and

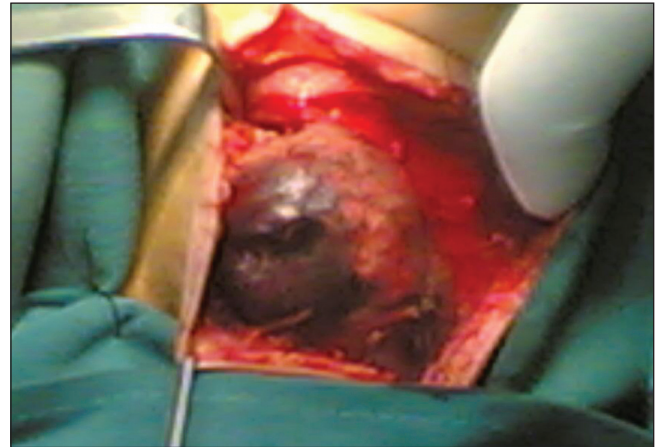


Figure 3. Dissected view of the mass

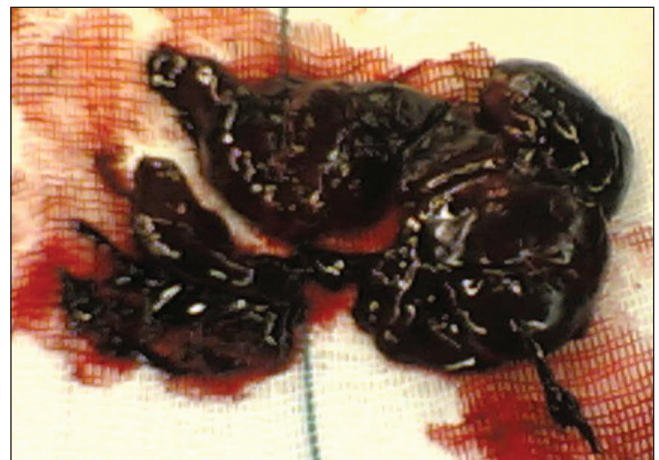

Figure 4. Hematoma mass after evacuation on a 10 × 10 cm sponge

inside the sternocleidomastoid muscle, appeared (Figures 3 and 4). The hematoma was evacuated and the bleeding site, the punctured right external carotid, was repaired by direct suturing. Subsequently, the sternocleidomastoid muscle was repaired, a hemovac drain was inserted, and the overlying skin was sutured.

The patient was then placed in the right lateral decubitus position for a thoracotomy approach both to repair the coarctation of the aorta with a subclavian flap angioplasty and to close the patent ductus arteriosus (PDA). After this surgical procedure, the pressure gradient at the level of the coarctation was corrected, the left lung was re-expanded, the thorax was closed, and the skin was sutured.

The patient was transferred to the pediatric cardiac intensive care unit and was extubated the following day. Transthoracic echocardiography was indicative of no significant gradient across the repaired site of the coarctation, and the patient was discharged to the ward after 3 days. At three weeks' follow-up, there was no significant lesion in the neck and transthoracic echocardiography demonstrated no residual coarctation.



Discussion

Carotid artery trauma in the existing medical literature is categorized as penetrating and blunt. Arterial interventions or angiography through the carotid artery, albeit not commonly practiced, may be utilized in rare cases in which the clinician has no good portal for arterial entry, e.g. in patients with weak pulses; though it is not as much common as traumatic arterial complications in other arteries.² Interventional repair of aortic coarctation is one of these rare situations. Inadvertent puncture of the common carotid artery is the most frequent complication of central venous catheter insertion and may result in central nervous system injury or airway compromise.³

One of the main untoward effects of carotid rupture, which is fortunately not common, is the effect of the enlarging mass on the upper airway. This effect may lead to gross mass effect, eventual fatal airway obstruction, and airway compromise.⁴ ⁵ The case presented herein was a typical case of penetrating carotid artery trauma leading to a mass effect and a partially displaced airway. As a result, the coarctation was repaired in the next step after the repair of the carotid artery while the patient was in a stable situation. It is worthy of note that using the carotid artery for interventions or angiography in such cases may beget a number of deleterious effects;^{1,4-6} it is mandatory that this approach be taken cautiously with respect to the angiography catheter entry portal. If there is a no other arterial choice except for the carotid artery in diagnostic and interventional repair therapies of the aortic coarctation, the clinician should increase his/her attention for the possibility of post-procedure events. The reason is that in such cases, the blood pressure in the upper limb is increased due to the pathophysiology of the aortic coarctation; the blood leakage from the ruptured artery is, therefore, much more severe than that in normal cases. Such surgical cases require much more sophisticated cautious interventions on the part of the anesthesiologist, surgeon, and interventionist.

Conclusion

This case demonstrated that a penetrating carotid artery puncture could lead to a number of life-threatening complications; especially in a newborn with aortic coarctation.

References

1. Mussa FF, Towfigh S, Rowe VL, Major K, Hood DB, Weaver FA. Current trends in the management of iatrogenic cervical carotid artery injuries. *Vasc Endovascular Surg* 2006;40:3543-3561.
2. Dabbagh A, Mar'ashi AS, Malek B. Traumatic arteriovenous fistula due to an old gunshot injury: a victim from the Afghanistan War.

- Mil Med 2007; 172:1129-1131.
3. Lieberman JA, Williams KA, Rosenberg AL. Optimal head rotation for internal jugular vein cannulation when relying on external landmarks. *Anesth Analg* 2004;99:982-988.
4. Lacey L, Dabbas N, Saker R, Blakeley C. Dissection of the carotid artery as a cause of fatal airway obstruction. *Emerg Med J* 2007;24:367-368.
5. Guilbert MC, Elkouri S, Bracco D, Corriveau MM, Beaudoin N, Dubois MJ, Bruneau L, Blair JF. Arterial trauma during central venous catheter insertion: case series, review and proposed algorithm. *J Vasc Surg* 2008;48:918-925.
6. Hamilton HC. Advantages of a nurse-led central venous vascular access service. *J Vasc Access* 2004;5:109-112.