

CLINICAL ARTICLE

The Aesthetic Contour Graft - Enhancing peri-implant soft tissue contours and pontic sites with guided bone regeneration

Bach Le DDS, MD¹  | Naoki Hayashi RDT, MDT, MDC²

¹Clinical Associate Professor, Division of Oral and Maxillofacial Surgery, University of Southern California, Los Angeles, California, USA

²Private Practice, Ultimate Styles Dental Laboratory, Irvine, California, USA

Correspondence

Bach Le, 16157 Whittier Blvd, Whittier, CA 90603, USA.
Email: btl@usc.edu

Abstract

Objective: In this article, we will discuss strategies for enhancing peri-implant soft tissue contours and pontic sites with hard tissue augmentation.

Clinical consideration: One of the keys to the esthetic illusion of an implant-supported restoration is to create an ideal emergence profile. A critical part of any emergence profile is based on the height and thickness of the tissue surrounding the restoration and whether there are any defects in this tissue. Even when there is adequate bone in which to place implants, if any irregular ridge anatomy that supports this tissue is not corrected, then an unesthetic appearance of the restoration can result due to the lack of soft tissue with which to develop a proper emergence profile.

Conclusion: Most peri-implant soft tissue deficiencies represent an underlying bony defect that can be corrected or enhanced through bone augmentation.

Clinical significance: Traditional methods of enhancing soft tissue emergence profiles around implants and pontic sites mostly involve the use of soft tissue augmentation techniques. Although there are few reports of the use of bone augmentation for this purpose, soft tissue contours can be enhanced by augmenting the underlying bone contours and, in many instances, may obviate the need for subsequent soft tissue augmentation.

KEYWORDS

esthetic contour graft, bone augmentation, guided bone regeneration, implant esthetic, pontic site development, soft tissue graft

1 | INTRODUCTION

One of the keys to the esthetic illusion of an implant-supported restoration is to create the ideal emergence profile.¹ A critical part of any emergence profile is based on the height and thickness of the tissue surrounding the restoration and whether there are any defects in this tissue. Even when there is adequate bone in which to place implants, if irregular ridge anatomy supports this tissue and is not corrected,

then an unesthetic appearance of the restoration can result due to an inadequate amount of soft tissue with which to develop a proper emergence profile (Figure 1A,B). Traditional methods of enhancing soft tissue thickness and height to create a proper emergence profile around implants mostly involve the use of soft tissue augmentation techniques.²⁻⁴

Soft tissue augmentation is beneficial in situations in which there is a thin biotype metal show of the implant collar or for the

This is an open access article under the terms of the Creative Commons Attribution-NonCommercial-NoDerivs License, which permits use and distribution in any medium, provided the original work is properly cited, the use is non-commercial and no modifications or adaptations are made.

© 2022 The Authors. *Journal of Esthetic and Restorative Dentistry* published by Wiley Periodicals LLC.

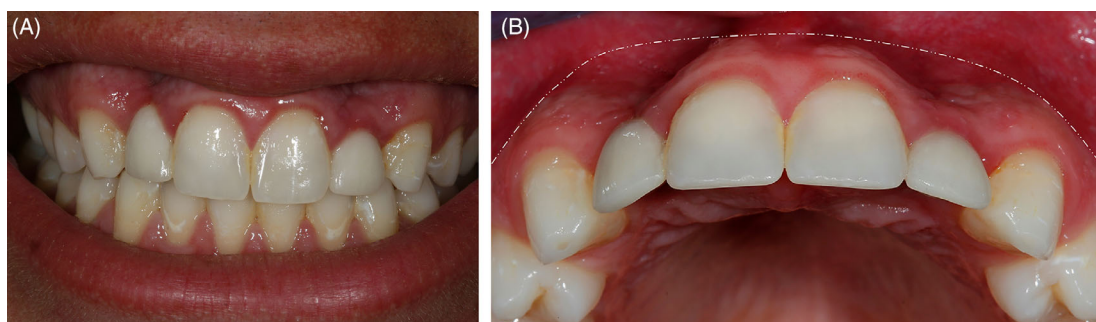


FIGURE 1 (A) and (B) Inadequate labial ridge contour often result in soft tissue collapse and unnatural appearance of the implant restoration due to poor emergence profile

small vertical augmentation of the soft tissue. However, many peri-implant soft tissue deficiencies represent underlying bone defects that can be ideally corrected or enhanced with guided bone regeneration (GBR). In this article, we will discuss strategies for enhancing peri-implant soft tissue contours and adjacent pontic sites with bone augmentation.

2 | RELATIONSHIP BETWEEN LABIAL BONE THICKNESS AND LABIAL SOFT TISSUE THICKNESS

Many factors can influence peri-implant soft tissue thickness and height, such as mucosal type, labial bone thickness and crest level, implant size and position, prosthetic connection type, and the emergence profile of the restoration. Soft tissue thickness is critical to maintaining implant health and esthetics.^{5,6} A minimum vertical soft tissue thickness of 2–3 mm is needed for the development of an emergence profile around dental implants and pontic sites. Over 2 mm of vertical soft tissue thickness is also needed to protect against crestal bone loss.⁵ Horizontal soft tissue thickness of 2–3 mm is associated with less tissue recession and is ideal when trying to achieve natural esthetics using various abutment materials.⁶ Because of the importance of adequate vertical and horizontal soft tissue thickness, many authors recommend using a connective tissue graft in the esthetic zone to thicken the crestal labial soft tissue to 2 mm.^{7,8}

Bone augmentation of alveolar ridge defects has the obvious benefit of improved support for the implant fixture, but it can also be implemented to restore and enhance the overlying soft tissue architecture. Gingival recession around teeth and implants is associated with alveolar bone dehiscence and rarely occurs in the presence of an intact labial wall.⁹ Clinical observation of labial soft tissue thickening has been reported after successful bone augmentation with particulate allografts and collagen membranes at the time of implant placement.¹⁰ A high correlation between labial crestal soft tissue thickness and underlying bone thickness around maxillary anterior implants has been reported, suggesting that soft tissue thickness can be heavily influenced by labial bone thickness.¹⁰

3 | RELATIONSHIP BETWEEN IMPLANT POSITION AND LABIAL SOFT TISSUE THICKNESS

Dental implant therapy is prosthetically driven and not primarily bone driven. To this end, the implant must be accurately placed in a 3D position with the goal of achieving a proper emergence profile for the final restoration. When the implant position is not accurate, the esthetic result is often compromised.¹¹ Implants that are placed too deep or too labially often result in long restorations while those that are placed too shallow lack vertical tissue height for sculpting. Implant position has been shown to have a direct influence on peri-implant soft tissue thickness.¹² Investigators identified a significant association between crestal labial soft tissue thickness and implant buccolingual angulation.¹² Implants with cingulum angulation had a mean crestal soft tissue thickness of 2.98 mm while those with incisal and labial angulation had decreased mean tissue thickness of 2.24 and 1.71 mm, respectively. The results of an animal study that involved comparing implant positions within the alveolar ridge (palatal, center, labial) also showed that there is a direct relationship between implant position and bone and soft tissue volume after 2-months, and implants in the labial position were found to have the lowest bone and soft tissue volumes.¹³

4 | GINGIVAL HEIGHT

Because gingival recession is possible after implant placement, it is critical to assess the gingival margin height of the tooth or implant site.¹⁴ This margin is usually dictated by the underlying facial bone level. A free gingival margin that lies coronal to the planned restorative margin offers an abundance of soft tissue height for sculpting and insurance against recession and is considered favorable (Figures 13 and 21). In clinical cases in which the gingival margin is in an unfavorable position, the use of bone augmentation to bring the gingival margin and bone toward a coronal level prior to implant placement should be considered.

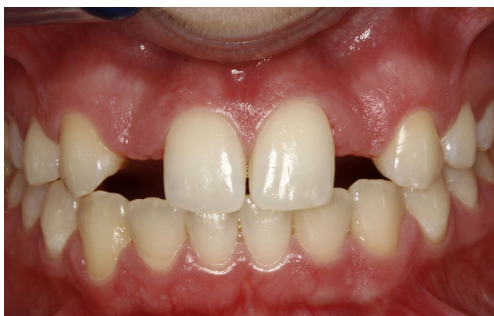

FIGURE 2 Preoperative image - Congenitally missing maxillary lateral incisors with labial ridge defect

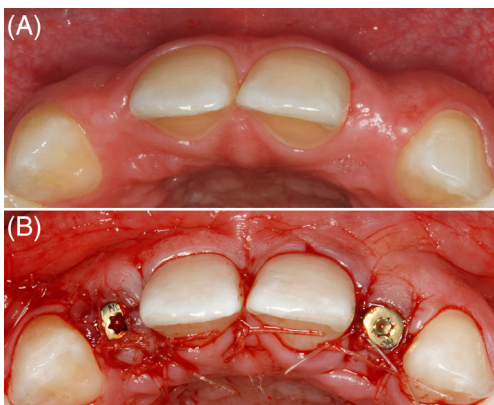


FIGURE 4 (A) and (B) A healing abutment was connected to the implants to provide support for the graft and contour the overlying soft tissue

5 | ESTHETIC CONTOUR GRAFT: DEVELOPING LABIAL SOFT TISSUE CONTOUR THROUGH GUIDED BONE REGENERATION

5.1 | Staged approach

GBR has been shown to promote osseous regeneration.^{15,16} The primary goal of bone augmentation in the esthetic zone is to create adequate labial bone crest and height to provide peri-implant soft tissue width and height. Bone augmentation that fails to maintain bone at the labial crest is at risk of peri-implant marginal tissue recession. Bone augmentation prior to implant placement will allow for ideal implant position to maximize soft tissue volume. Tenting screws can be used with GBR to move the graft toward the bone crest to support the labial ridge contour (Figure 10B).¹⁷ Because most bone augmentation procedures inherently result in secondary remodeling and resorption,¹⁸ it is important to factor in the amount of anticipated resorption by overcorrecting defects so that a critical 2–3 mm threshold of labial bone is achieved labial to the implant platform after long-term remodeling.

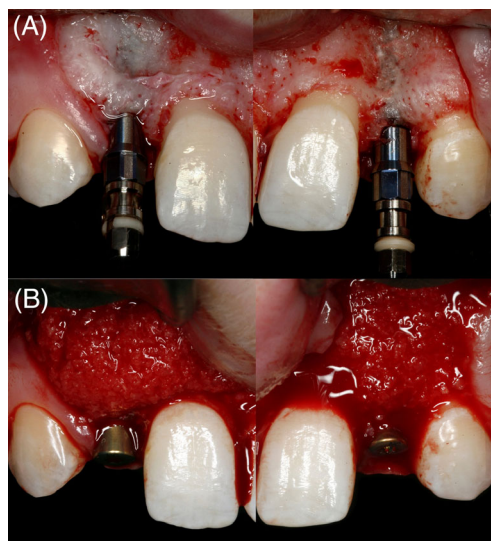


FIGURE 3 Although there was adequate bone thickness for implant placement, additional bone augmentation was necessary to support gingival contour and emergence profile for the restoration

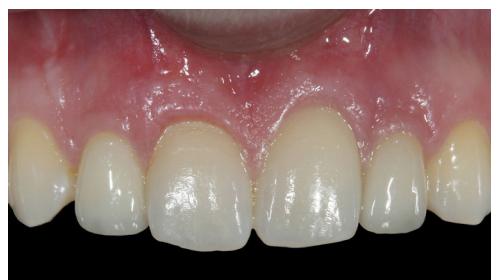

FIGURE 5 Final restorations at 8 years follow-up show stable peri-implant soft tissue contour

5.2 | Single-stage implant placement with simultaneous bone grafting

Traditional GBR procedures are performed as a staged approach with a second surgical intervention to place the implant. Single-stage implant placement with simultaneous bone augmentation in properly selected cases is a possible alternative that enables the treatment of mild to moderate defects with a single surgical procedure and can be performed immediately at the time of tooth extraction or in a healed ridge. Traditionally, simultaneous bone grafting is done following a two-stage protocol with the implant submerged beneath the soft tissue flap.¹⁹ Simultaneous bone augmentation with non-submerged healing has been performed by adding a healing abutment.²⁰ This approach minimizes compression and the migration of particulate graft material and allows the bony and soft tissue architecture to develop around the healing abutment during site healing. A healing abutment will provide some

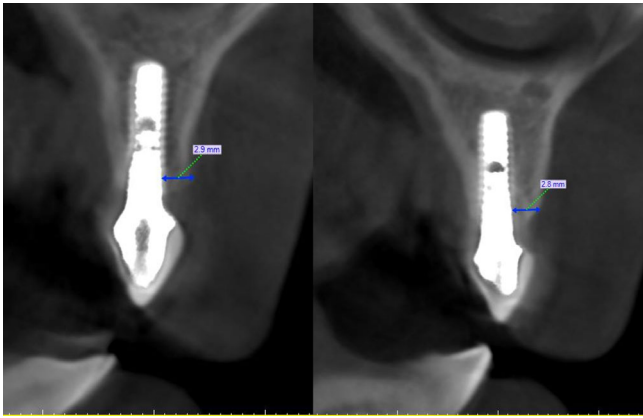


FIGURE 6 CT scan at 8 years show stability of the graft

tenting of the peri-implant soft tissues and result in reduced apical migration of the graft material.

Investigators have assessed the outcome of single-stage, non-submerged implant placement with simultaneous augmentation of buccal bone dehiscence defects using a mineralized allograft covered with a collagen membrane.²¹ The buccal defects were classified as small (less than 3 mm), medium (3–5 mm), or large (greater than 5 mm). The initial defects were recorded by measuring the amount of implant rough surface exposure after implant placement. To assess site healing, sectional CBCT scans were obtained at 36 months post-grafting. The results of the evaluation of the sites of the original defects showed bone regeneration of 100% and 79.3% of small- and medium-sized dehiscences. Large defects showed only partial improvement.

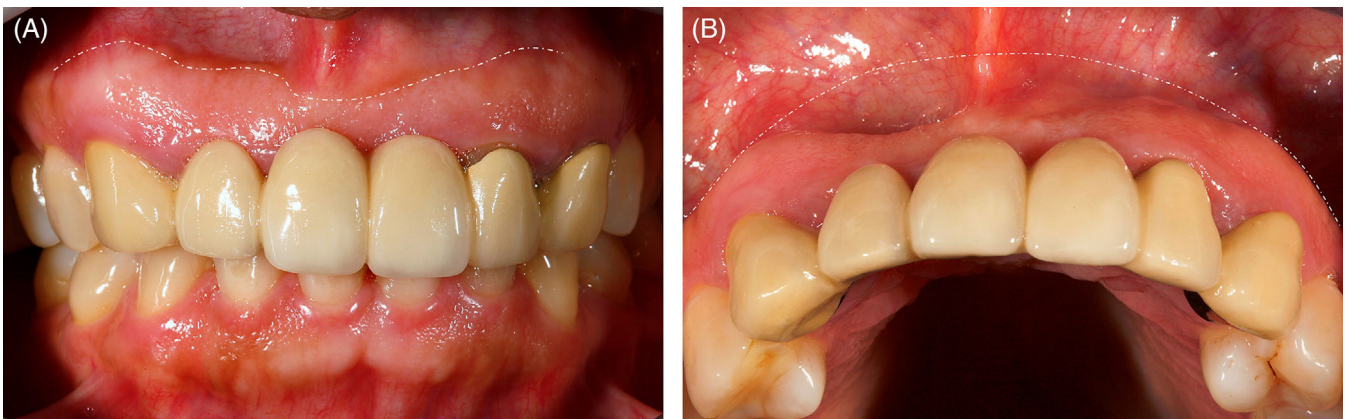


FIGURE 7 (A) and (B) Preoperative views show unesthetic bridge between #6–9 and 11. Inadequate hard and soft tissue thickness resulted in the use of a ridge lap pontic design with unnatural emergence profile. The pontic sits on top of the ridge rather than emerge from within the gingival tissue. Note the dark halo where the pontic rests on top of the tissue and subtle darkness (black triangles) in the embrasure area. Note the shrinkage of the attached mucosa at the pontic area which is especially pronounced at site #8

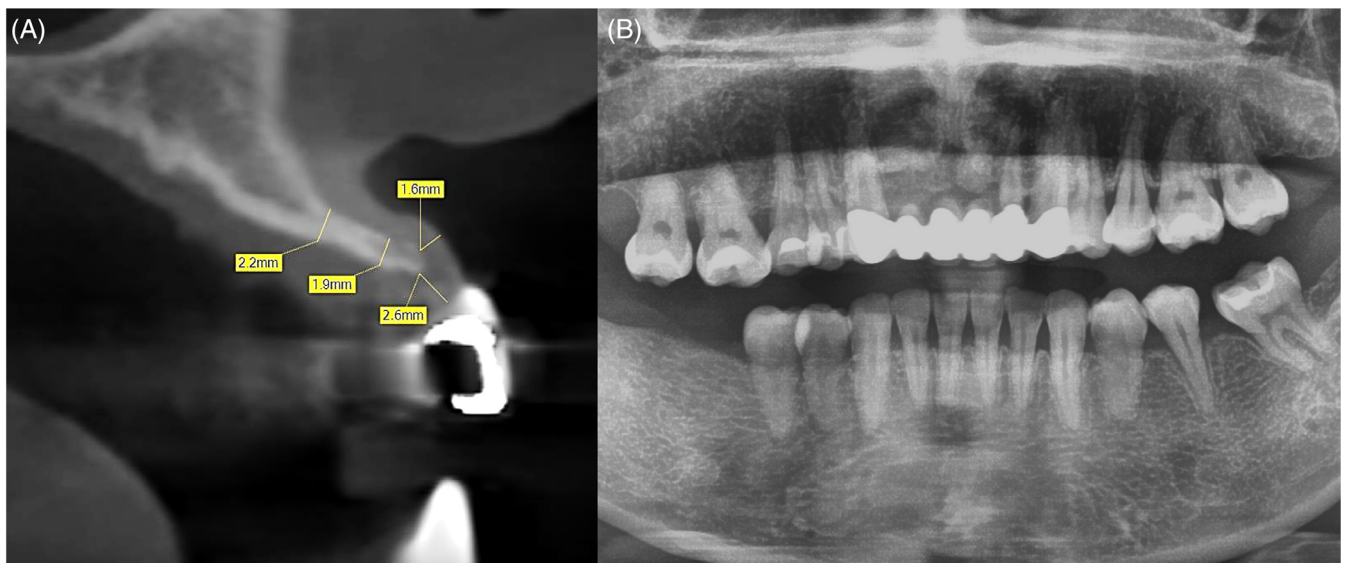


FIGURE 8 (A) and (B) Preoperative panorex radiograph and CBCT of site #8 show severe alveolar ridge atrophy

In another study, Jensen et al. analyzed the long-term stability of bone contour augmentation in the esthetic zone used with early implant placement (i.e., 6–8 weeks of healing after tooth extraction) assessed using biopsies harvested after various time intervals.¹⁹ Implant placement was performed with simultaneous contour

augmentation using a combination of autogenous bone and deproteinized bovine bone mineral (DBBM) covered with a collagen membrane. Biopsies collected after 14 to 80 months of healing were subjected to histomorphometric analysis. The investigators concluded that their study confirmed previous findings that osseointegrated

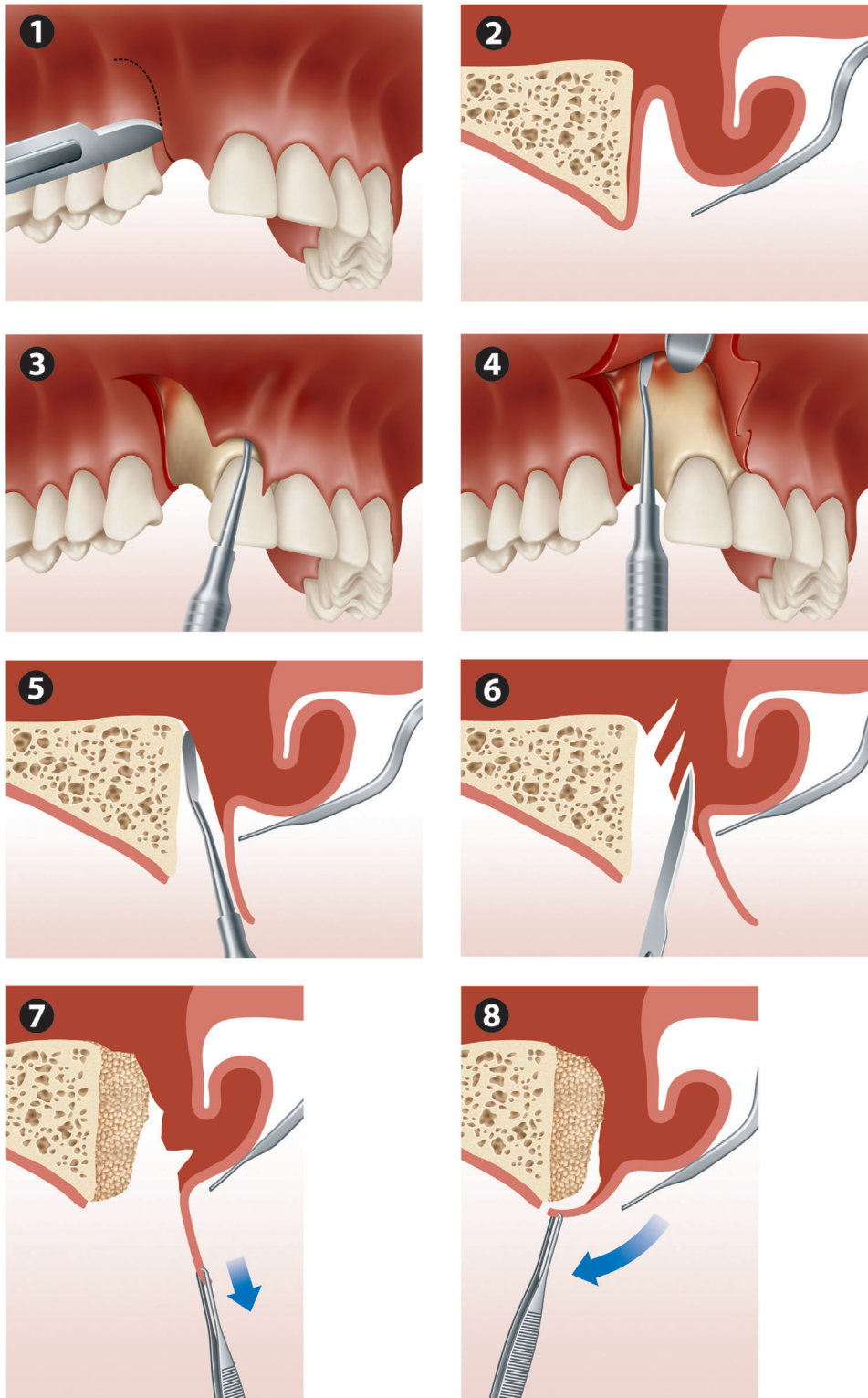


FIGURE 9 Open book flap design

DBBM particles do not undergo significant resorption and substitution over time and that this low substitution rate is likely the reason for the long-term clinical and radiographic stability of contour augmentations done using this procedure.¹⁹

The success of the esthetic contour graft concept is dependent on multiple variables, including defect configuration, flap design, space maintenance, graft selection, membrane selection, and implant position.

5.3 | Defect configuration

With traditional GBR, the migration of graft particles during site healing often results in unfavorable healing and soft tissue collapse/recession. The challenge of maintaining graft particles in position depends on several factors related to defect configuration.

5.3.1 | Width of edentulous span

Single-tooth defects have a much better esthetic prognosis than multiple teeth defects²² because particulate grafts placed in

wider edentulous spans are prone to migration due to the wide flap elevation required. Wide defects often require the use of a containment barrier or space maintenance device, such as a mesh or a membrane with tacks to contain the bone graft material.

5.3.2 | Number of walls

New bone formation mainly depends on the surface area of the exposed bone and bone marrow because the osteogenic and angiogenic cells that form new bone reside in the bone marrow.²³ The number of bony walls available in a defect has a significant influence on the success of a GBR procedure. With more bone walls available, the healing potential of a given defect increases.²⁴ In other words, three-wall defects (e.g., extraction sockets) have better healing potential than two-wall defects. One-wall defects, however, are challenging to repair because there is a great distance for osteogenic cells to bridge. Three- to four-wall defects also have a better prognosis for graft containment and space maintenance than others.

FIGURE 10 (A) and (B) Subperiosteal reflection was carried to the level of the anterior nasal spine. Note the very thin labial crestal bone. A strategically placed tenting screw was used to guide the augmentation to create the ideal labial soft tissue height and contour

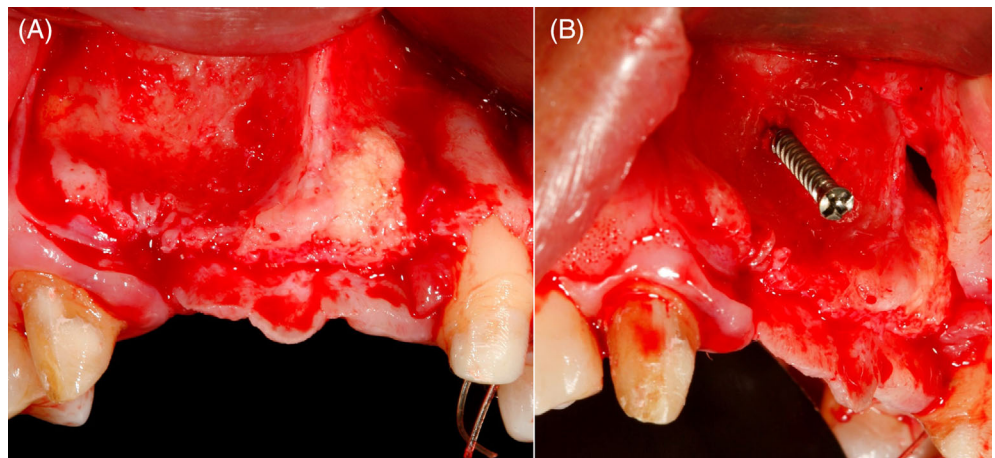
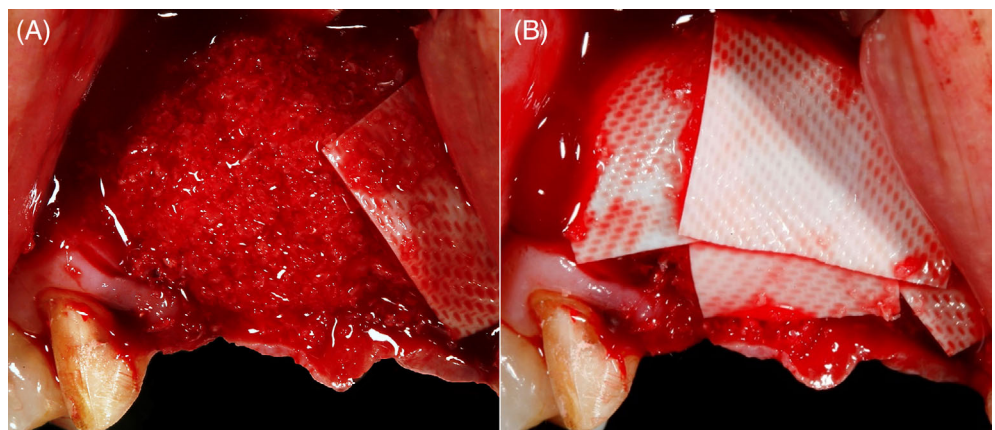


FIGURE 11 (A) and (B) A mineralized allograft was placed to sculpt the alveolar ridge in the desire contour. The graft material was covered entirely with a resorbable collagen membrane. Note that the palatal flap was not elevated to preserve blood supply to the thin alveolar crest



5.3.3 | Type of defect

Horizontal defects with bony concavities (Figures 2 and 3A) that will contain graft material have better prognoses than those with no concavities. Defects with vertical components are the most difficult due to the difficulty involved in space maintenance. The use of space maintenance devices such as titanium meshes²⁵ or tenting screws¹⁷ is recommended for the treatment of these defects (Figure 10B).

6 | SURGICAL TECHNIQUE

The augmentation of ridge defects using GBR with or without flap elevation has been described.^{26–28} Although it can be easy to place a bone graft using a tunnel approach, positioning and maintaining the bone material in an esthetic position at the labial crest can be difficult due to graft migration and limitations in the ability to visually “sculpt” the alveolar ridge and its overlying soft tissue. To achieve the most natural ridge form and overlying soft tissue profile, the 3D augmentation of the alveolar process is best done under direct vision. An open-book flap design²⁰ is used to enhance visualization and promote graft containment for most localized defects (Figure 9). It is important to achieve the tension-free adaptation of wound margins during wound closure, and this often requires incising the periosteum of the flap before repositioning it. In addition, the scoring of the periosteum promotes angiogenesis by creating bleeding into the graft.²⁹

The flap is developed with a crestal incision made slightly lingual to the ridge midline to preserve an adequate amount of labial keratinized tissue in the flap (Figures 2–6). This is followed by a distal, curvilinear, vertical incision that follows the gingival margin of the distal proximal tooth. A wide subperiosteal reflection is made to expose two to three times the treatment area, and the papilla is reflected on the mesial side of the edentulous site. The peri-implant soft tissue is released and coronally advanced by scoring the periosteum so that tension-free closure can be achieved around the neck of the implant. To reduce intra-operative bleeding at the graft site, the periosteal release should be the final step before graft placement. Mineralized bone allograft material is packed into the defect and over-contoured by at least 30% to compensate for possible apical migration and the resorption of the material. After graft placement, the material is covered with a resorbable membrane, and a healing abutment is connected to the implant (Figure 3B). The graft provides a tenting effect for the soft tissue and, together with the healing abutment, provides an esthetic contour for the soft tissue during healing (Figure 4B).

Perforating the recipient bone bed is recommended by some surgeons to enhance healing.^{30–32} By perforating the cortical bone with a small bur, the marrow cavity is opened and bleeds into the defect. Animal studies have shown that such perforations improve healing in a membrane-protected defect.^{30,31} Large perforations were found to be associated with relatively quicker bone formation.³⁰ A recent systematic review, however, concluded that the evidence in support of creating perforations in GBR and with autologous bone blocks is

limited.³² This author does not routinely perforate the recipient bone bed and has not seen a difference in outcomes. Two scenarios (Figures 7A,B and 18B) with multiple missing teeth are presented to illustrate a staged and simultaneous contour augmentation using a

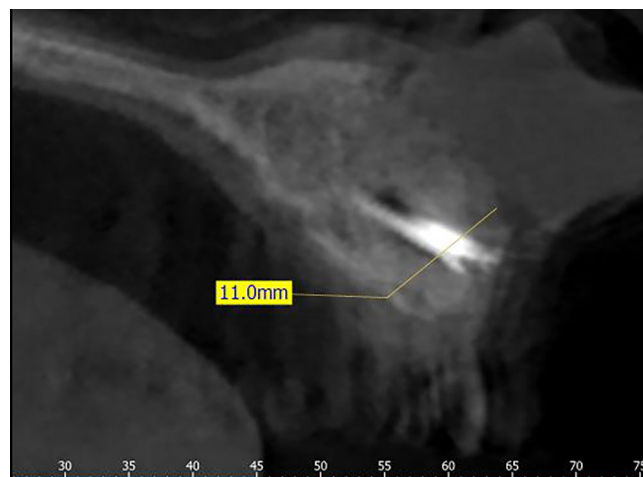


FIGURE 12 Follow-up CT scan at 4 months after augmentation show graft consolidation with excellent bone contour at the labial alveolar crest

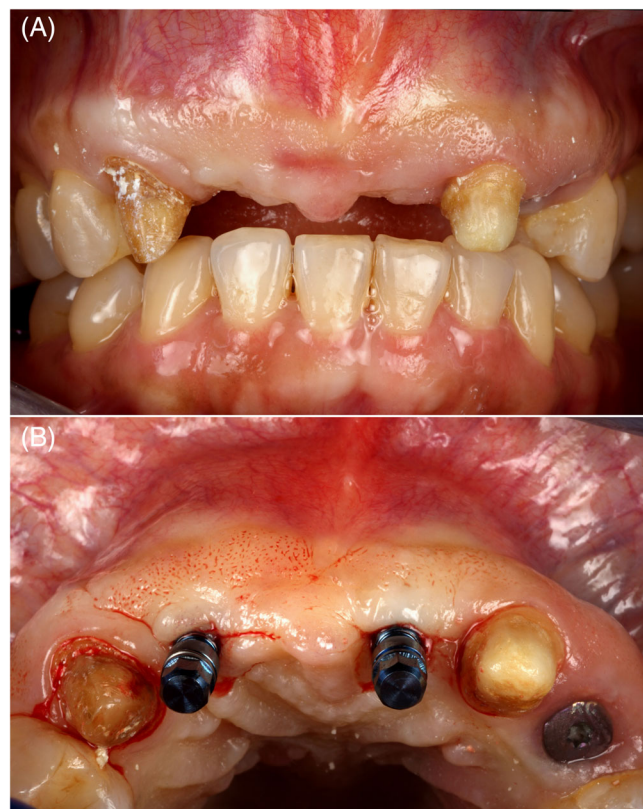

FIGURE 13 (A) and (B) 4 months after GBR procedure. Note the favorable gingival height. Implant placement with flapless protocol with the implant angulation inclined toward the cingulum to maximize labial soft tissue thickness. GBR, guided bone regeneration

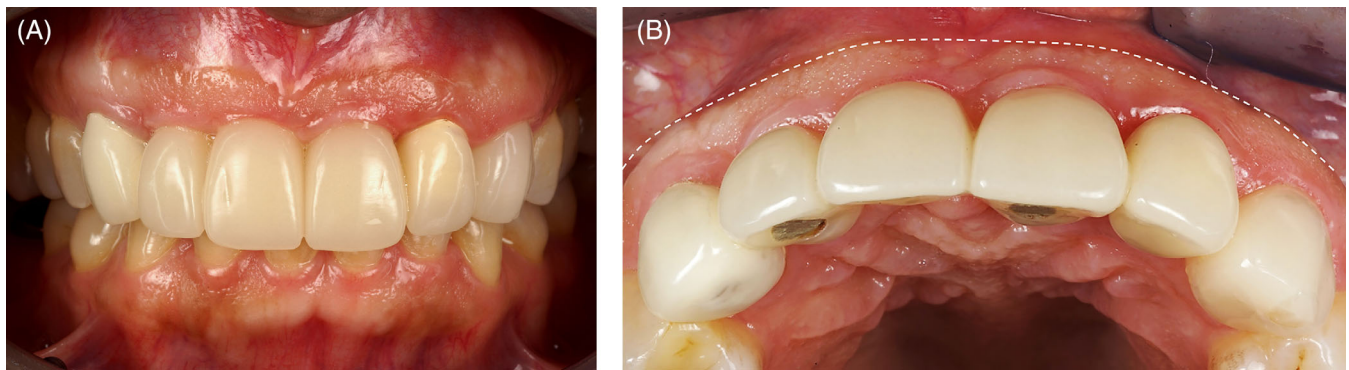


FIGURE 14 (A) and (B) Screw-retained provisional restoration delivered 2 months after implant placement to sculpt the soft tissue profile. Note the labial ridge and soft tissue contour is at least 2 mm outside the emergence of the provisional restoration

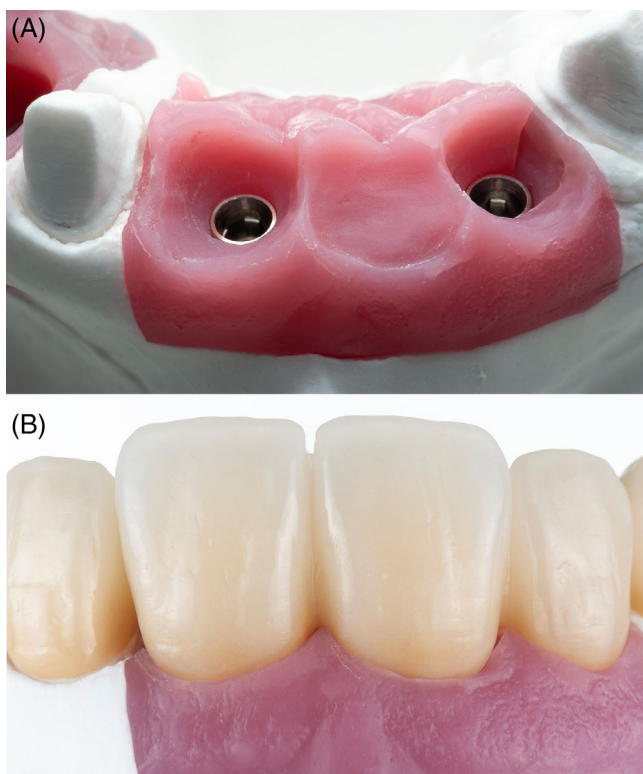


FIGURE 15 (A) and (B) Soft tissue cast model show excellent thickness of the labial soft tissue contour, which is outside the emergence of the restoration around the implants and the pontic site

particulate allograft to sculpt the overlying soft tissue to create an esthetic emergence profile for both the implant restorations and their adjacent pontic sites.

6.1 | Case #1 staged approach

(Figures 7-17) A 42-year-old female with an existing bridge restoration between teeth #6 and 11 was referred for implant

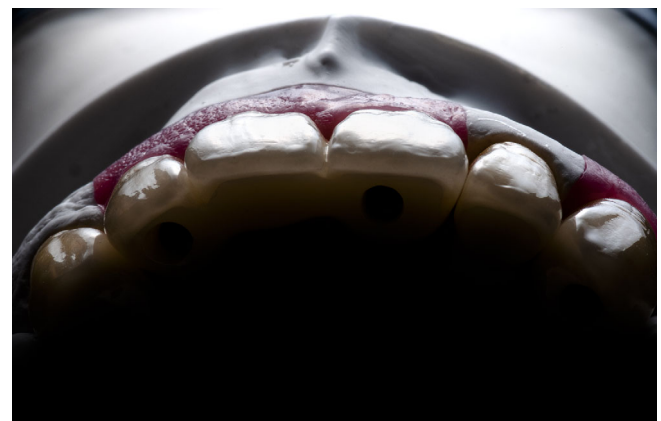

FIGURE 16 Emergence profile of the restorations

reconstruction of sites #7, 8, 9, and 11. The patient was unhappy with the esthetic appearance of her current bridge because the teeth looked “unnatural” (Figure 7A,B). Radiographic exam revealed a severely atrophic alveolar ridge in areas 7-9 with a poor emergence profile of the pontic areas (Figure 8B). Asymmetry of the keratinized tissue band was observed between sites #7, 8, and 9 (Figure 7A). Because of a severe ridge defect, a staged bone augmentation was performed to allow for the placement of implant fixtures for sites #7, 9, and 11. An open-book flap design (Figure 9) was used to facilitate graft containment and minimize apical graft migration. A palatal flap was not elevated to preserve blood supply to the already-thin alveolar crest (Figure 10). A tenting screw was placed to guide the graft toward the labial crest (Figure 10B). A mineralized allograft (MinerOss, Biohorizons, Birmingham, Alabama) was placed at sites #7-9 with labial overcorrection of about 30%-40% in anticipation of resorption and remodeling. A collagen membrane (Ossix Plus; OraPharma, Horsham, PA) was placed over the entire graft, and primary closure was obtained (Figure 11B). A CBCT taken 4 months after the procedure showed excellent reconstruction of the labial bone crest (Figure 12). Implants (Straumann, Basel,

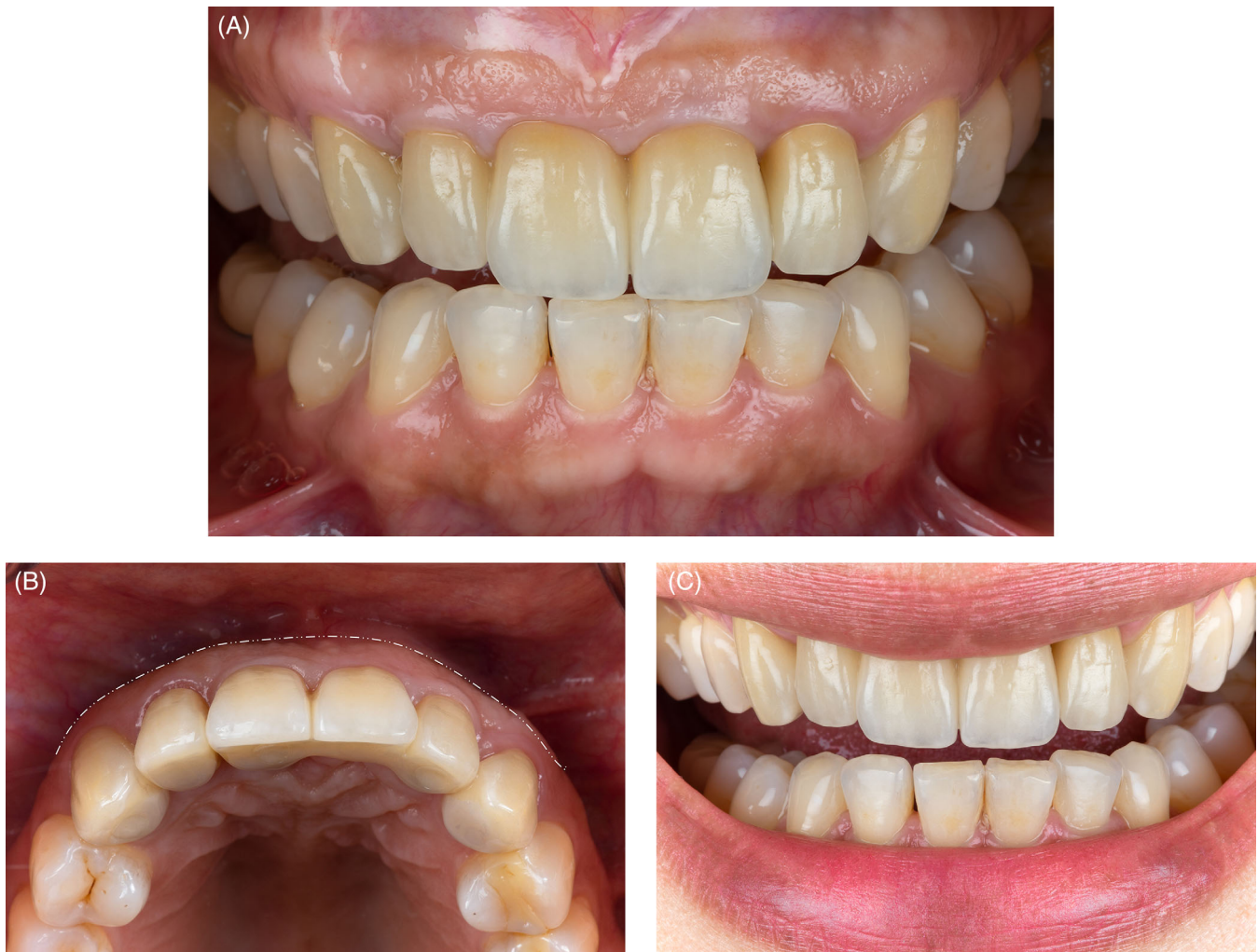

FIGURE 17 (A)–(C) Final restorations in the mouth. Note the improvement of the attached mucosa with a broader band of keratinized tissue at pontic site #8. The emergence profile of the implant and pontic appear natural without black triangles or darkness underneath the pontic

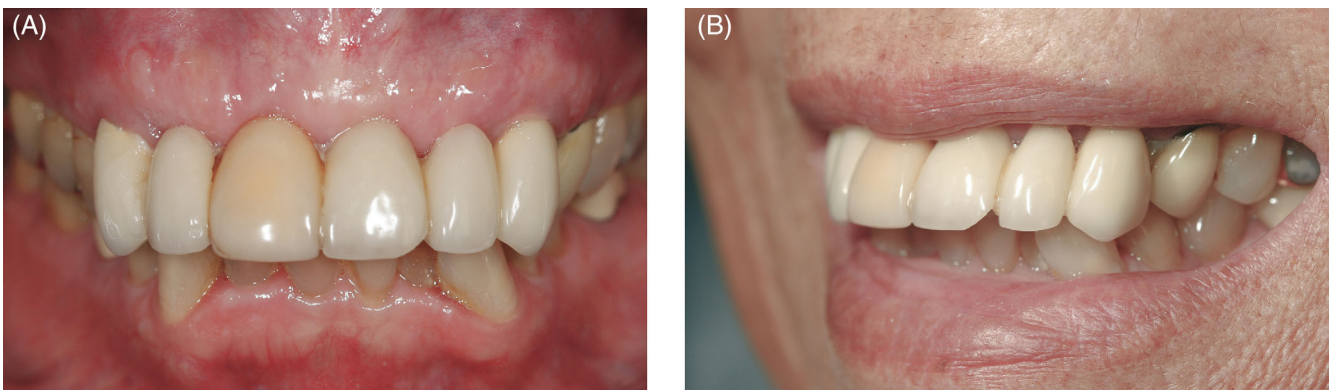

FIGURE 18 (A) and (B) Preoperative clinical views show unesthetic maxillary PFM bridge between #6 and #11. The patient was unhappy with the angulation of her “flared out” teeth. The emergence profile of the bridge was poor due to inadequate facial soft tissue thickness in the pontic area

Switzerland) were placed using a flapless protocol at sites #7, 9, 11 (Figure 13B). Three months after implant placement, a screw-retained provisional restoration was delivered to sculpt

the soft tissue around the implants and pontic sites (Figure 14B). An improvement of the keratinized tissue width at pontic site #8 was also observed (Figure 17).

6.2 | Case #2: Single-stage implant placement with simultaneous bone grafting

(Figures 8–25) A 65-year-old female with a failing bridge restoration between teeth #6 and 11 was referred for extraction and implant reconstruction. The patient was unhappy with the appearance and angulation of her “flared out” teeth (Figure 18B). The emergence profile of the existing PFM bridge was poor due to inadequate facial soft tissue thickness in the pontic area. Radiographic exam revealed adequate bone width and height for implant placement at sites #6, 8, 9, and 11 for two implant-supported bridge restorations (Figure 19B). The extraction of teeth #6 and 11 was performed, and implants were immediately placed (Biohorizons, Birmingham, AL) at sites 6 and 11 and 8 and 9 (Figure 20C). Although there was adequate bone thickness for implant placement, additional bone augmentation of the labial crest was performed to facially broaden the alveolar ridge to provide an adequate gingival contour and emergence profile for future restorations and adjacent pontic sites. The implant platform was placed 3–4 mm apical to the ideal gingival zenith and inclined

toward the cingulum to enhance tissue height and thickness for future sculpting.¹² After a healing period of 4 months (Figure 21), provisional restorations were delivered with enhanced subgingival contour to apically displace the gingival margin around the implants (Figure 22). An esthetic pontic design was used to create a natural emergence profile (Figure 23C).

7 | DISCUSSION

Many factors can influence peri-implant soft tissue thickness and height, such as mucosal type and thickness, labial bone level and thickness, implant position, size and design, implant-abutment and prosthesis connection, the emergence profile of the restoration, and the surgical protocol used. Traditional methods of enhancing soft tissue thickness and height to create a proper emergence profile around implants mostly involve the use of soft tissue augmentation techniques. However, the importance of having adequate labial bone thickness around implants cannot be underestimated. Many mucogingival deficiencies that occur around dental implants result

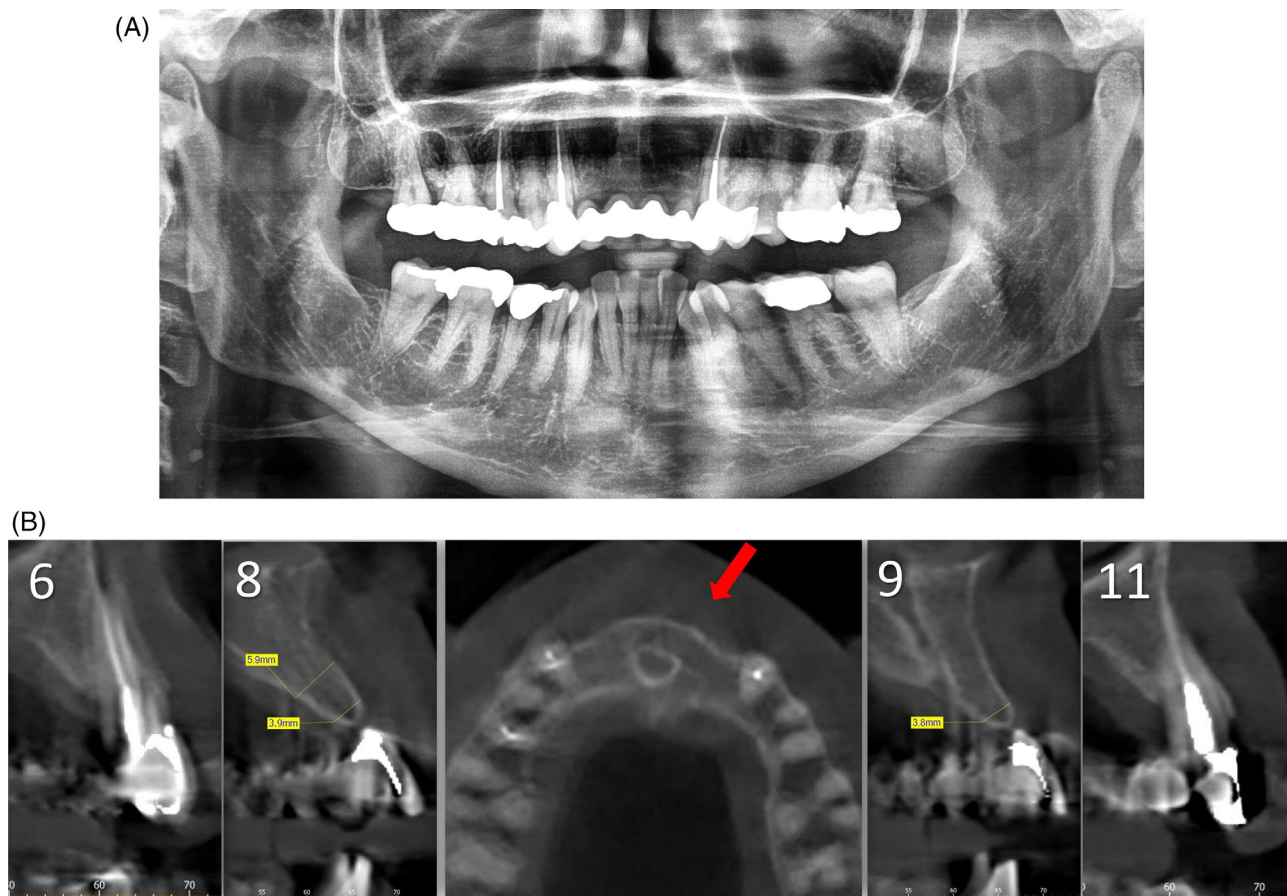


FIGURE 19 (A) and (B) Radiographic exam show adequate bone width and height for implant placement at sites # 6, 8, 9, 11 for two implant-supported bridge restorations

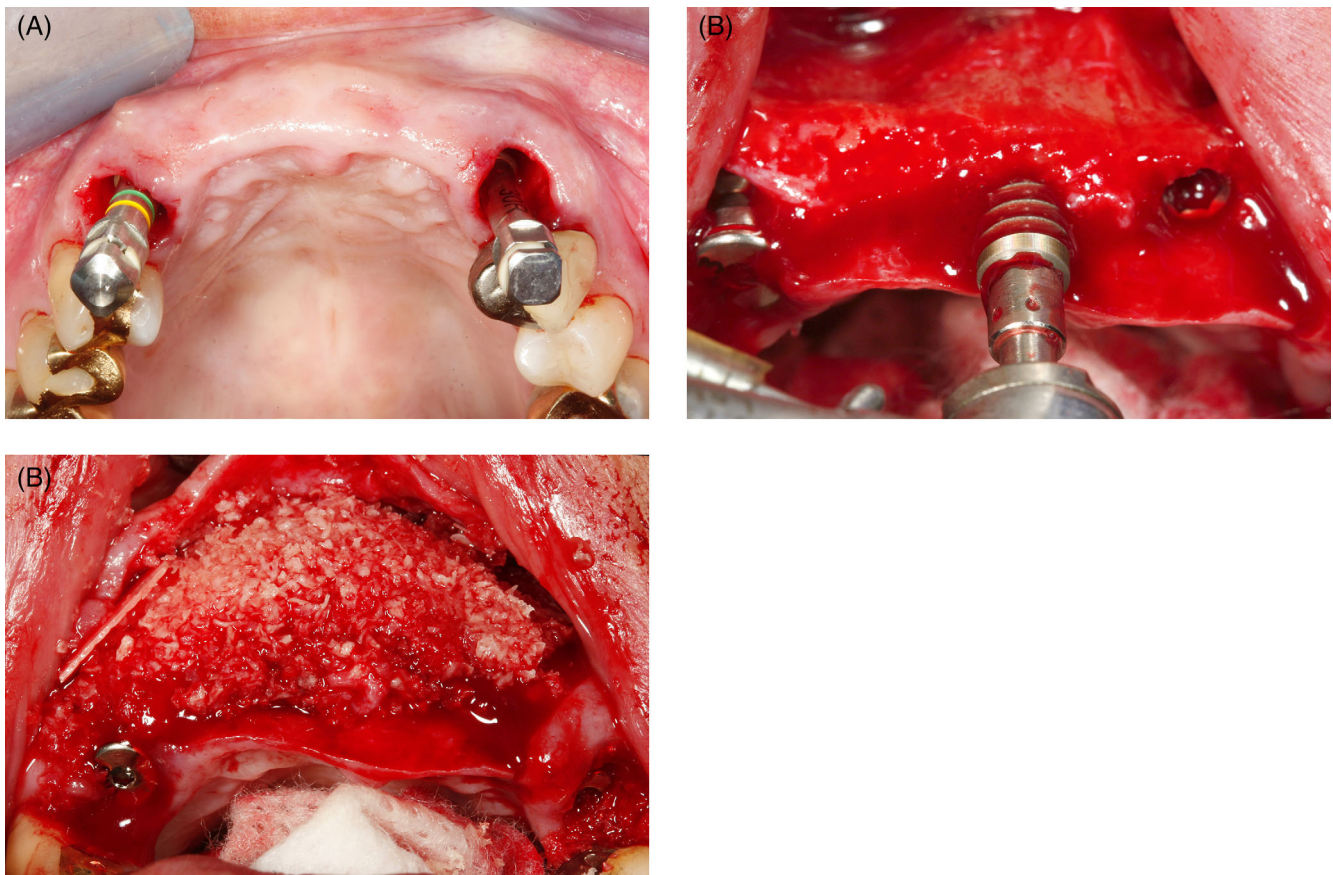


FIGURE 20 (A)–(C) Extraction of teeth # 6 and 11 was performed with immediate placement of four implants at sites 6, 11 and 8, 9. Although there was adequate bone thickness for implant placement, additional augmentation was necessary to facially broaden the alveolar ridge to provide sufficient gingival contour and emergence profile for the future implant-supported restoration and adjacent pontic sites. A healing abutment was connected to the implants to provide support for the graft and contour the overlying soft tissue. The mineralized allograft was covered with a collagen membrane

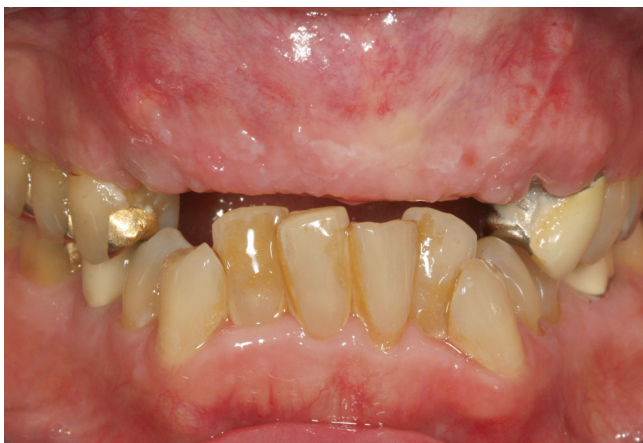

FIGURE 21 Healing at 4 months. Note the improved ridge contour and soft tissue height

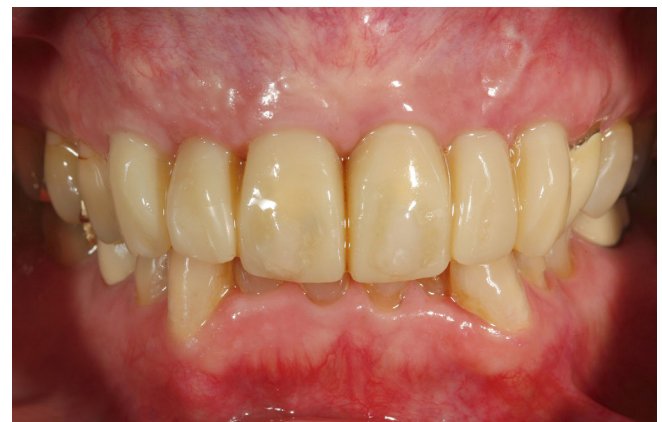

FIGURE 22 Provisional restorations are delivered with enhanced subgingival contour to sculpt the pontic sites and the gingival margin around the implants

from the loss of underlying bone support for the fixture. A minimum facial bone thickness of 2 mm has been suggested after implant placement to minimize labial bone height loss.³³ Peri-implant soft tissue

parameters were observed to be positively influenced by bone augmentation using GBR. The use of a collagen membrane with a particulate allograft in the treatment of facial soft tissue recession resulted in

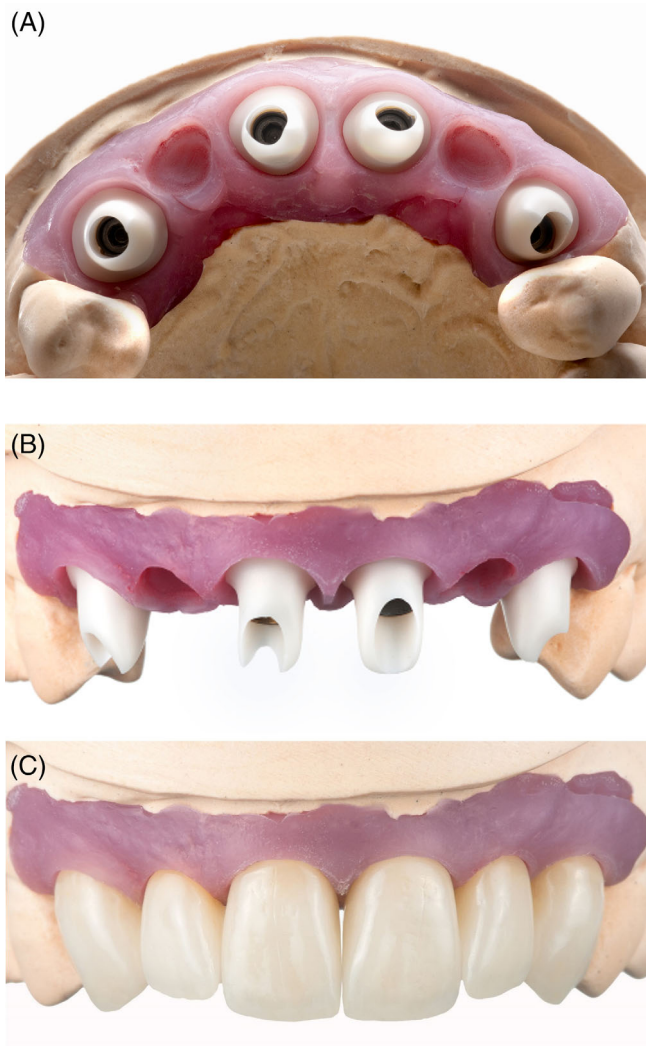


FIGURE 23 (A)–(C) An esthetic pontic design was used to give a natural emergence profile

approximately 1.0 mm of mean gain in soft tissue thickness, keratinized tissue width, and gingival height.^{34,35} In addition to improving soft tissue esthetics, the additional bone thickness provides stability in maintaining labial bone height. The use of particulate mineralized allograft through an open onlay technique has been reported to be successful in the reconstruction of a severely atrophic alveolar ridge prior to implant placement.³⁶ The advantage of using an open grafting technique is that it can be performed at the time of implant placement using a staged or single-stage implant placement protocol and allows for the precise placement of the graft material to “sculpt” the labial ridge to have the desired contour. The single-stage protocol minimizes the compression and migration of particulate graft material and allows the bony and soft tissue architecture to develop around the healing abutment during the healing phase. The use of a healing abutment following a single-stage placement protocol provides tenting of the peri-implant soft tissue and results in less apical migration

of graft material than a submerged protocol. This improves the prognosis by safeguarding the width and height of the remaining crestal bone. By restoring the labial bone crest, it is possible to create an esthetic result whereby the coronal soft tissue is supported by bone and, in many cases, eliminates the need for a subepithelial connective tissue graft. The authors of a limited number of retrospective studies reported observing increases in soft tissue thickness around dental implants, primarily in the anterior maxilla, after increasing the thickness of the facial bone through GBR.^{10,34,35} Further research is needed to understand these observed correlations between bone and soft tissue thickness.

The use of a pontic can improve the overall esthetic outcome when replacing multiple teeth with implants. The gingival height between pontic and implant can be higher than those between adjacent implants.³⁷ The ideal pontic should appear to emerge from the gingiva and support the labial soft tissue and adjacent papillae. This is only possible when the labial soft tissue contour is outside the planned emergence of the restoration (Figures 15A, B and 23A–C) and a favorable gingival height exists (Figure 21). Otherwise, the pontic designs used are often ridge lap or modified ridge lap, which gives the unnatural appearance that the restoration sits on top of the ridge rather than emerging from within the gingival tissue. A dark halo is often seen where the pontic rests on top of the tissue and black triangles often appear in the embrasure area between the abutments and the pontics, leading to an unesthetic appearance of the restoration (Figure 7A). There is often localized shrinkage of the attached mucosa at the pontic area, which can heighten such an unesthetic appearance (Figure 7A). Soft tissue grafts have been used for pontic site development. Although there are no reports of pontic site development using GBR, soft tissue height and width can be enhanced by augmenting the underlying bone contour to attain a favorable gingival height to optimize the emergence profile of peri-implant pontic sites. A strategically placed tenting screw can guide the augmentation to create the ideal labial soft tissue height and contour. After successful bone augmentation, a healing phase of at least 4 months is needed to allow the overlying soft tissue to settle. A customized provisional restoration is delivered to create the desired soft tissue profile. Alterations to the gingival margin level, contour, and papilla shape are achieved through modifications of the contour of the provisional restoration. The outcomes of these modifications vary depending on whether the contour alterations are done on a critical contour or a subcritical contour.³⁸ In cases in which implant placement is ideal, altering critical and subcritical contour can optimize the clinical outcome by creating a better soft tissue profile. It is often necessary to use local anesthesia to create optimal tissue displacement and manipulation. The location of the proximal contact can be modified to allow for tissue displacement into this area. The developed papillae and the buccolingual width of the soft tissue can create an ideal emergence profile, thus eliminating the appearance of black triangles between the pontics.

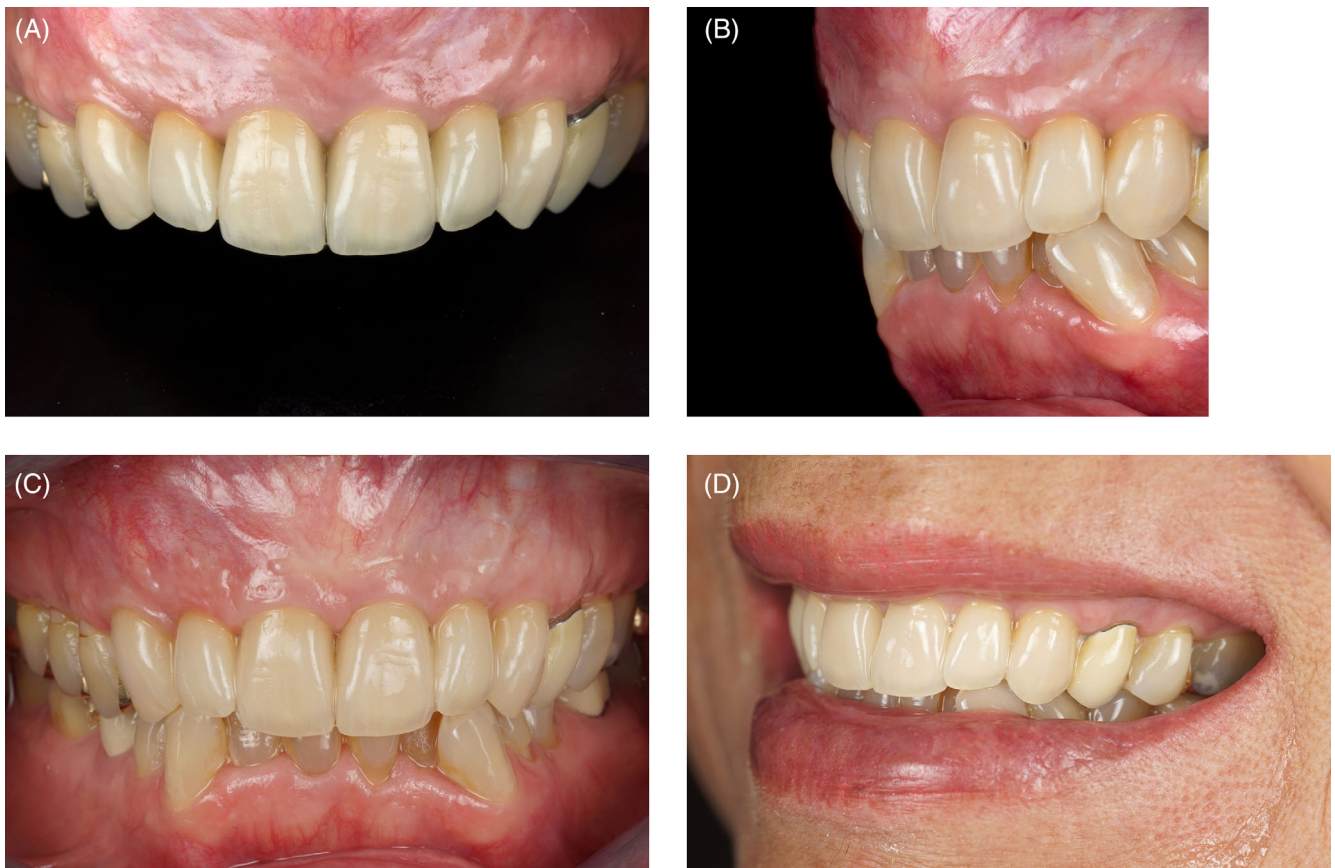

FIGURE 24 (A)–(D) Final restorations in the mouth. Note the improvement in the angulation of the restorations. The emergence profile of the implant and pontic appear natural without black triangles or darkness underneath the pontic

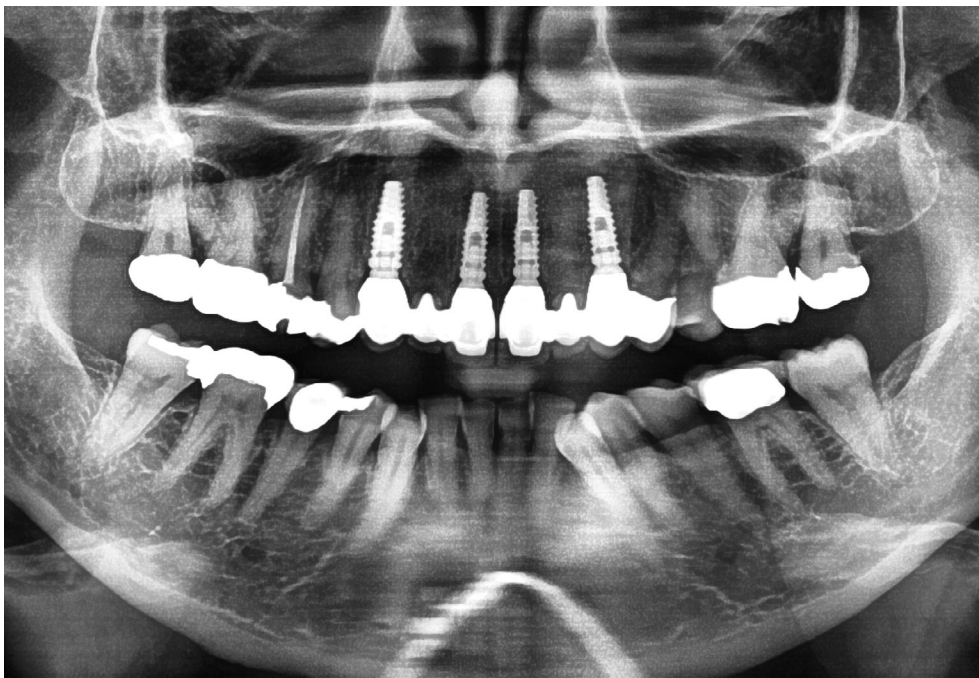

FIGURE 25 Panorex radiograph at 4 years follow-up

8 | CONCLUSIONS

A mineralized particulate graft can be used to reconstruct soft tissue or supplement soft tissue deficiencies by augmenting underlying bony defects, giving support to the overlying soft tissue and the contour needed for an excellent, natural-looking result. This can be done using staged protocols or at the time of implant placement, negating the need for secondary hard or soft tissue grafting. The correction of labial defects is just one of the many factors that can lead to excellent esthetic results. Treatment planning, case selection, correct implant positioning and angulation, proper provisional restoration design, and the esthetic fabrication of the final crown are equally important. Contour grafts made from mineralized allograft can be used to convert unhealthy and unesthetic gingival contours into favorable sites. A simple technique to improve the peri-implant esthetics has been demonstrated through a review of the various techniques used to develop the implant site at the buccal aspect of the ridge.

DISCLOSURE

The authors declare that they do not have any financial interest in the companies whose materials are included in this article.

DATA AVAILABILITY STATEMENT

The data that support the findings of this study are available from the corresponding author upon reasonable request.

ORCID

Bach Le  <https://orcid.org/0000-0002-9214-0312>

REFERENCES

- Kois JC. Predictable single tooth peri-implant esthetics: five diagnostic keys. *Compen Contin Educ Dent*. 2001;22(3):199-206.
- Lin GH, Chan HL, Wang HL. The significance of keratinized mucosa on implant health: a systematic review. *J Periodontol*. 2013;84(12):1755-1767.
- Iorio-Siciliano V, Blasi A, Sammartino G, Salvi GE, Sculean A. Soft tissue stability related to mucosal recession at dental implants: a systematic review. *Quintessence Int*. 2020;51(1):28-36.
- Zufia J, Blasi G, Gómez-Meda R, Blasi A. The four-layer graft technique, a hard and soft tissue graft from the tuberosity in one piece. *J Esthet Restor Dent*. 2019;31(4):304-310.
- Linkevicius T, Apse P, Grybauskas S, Puisys A. The influence of soft tissue thickness on crestal bone changes around implants: a 1-year prospective controlled clinical trial. *Int J Oral Maxillofac Implants*. 2009;24(4):712-719.
- Jung R, Sailer I, Hämmerle C, Attin T, Schmidlin P. In vitro color changes of soft tissues caused by restorative materials. *Int J Periodontics Restorative Dent*. 2007;27:251-257.
- Grunder U. Crestal ridge width changes when placing implants at the time of tooth extraction with and without soft tissue augmentation after a healing period of 6 months: report of 24 consecutive cases. *Int J Periodontics Restorative Dent*. 2011;31(1):9-17.
- Esposito M, Maghazreh H, Grusovin M, et al. Interventions for replacing missing teeth: management of soft tissues for dental implants. *Cochrane Database Syst Rev*. 2012;2:CD006697.
- Patel M, Nixon P, Chan M. Gingival recession: part 1. Aetiology and non-surgical management. *Br Dent J*. 2011;211:251-254.
- Le B, Borzabadi-Farahani A. Labial bone thickness in area of anterior maxillary implants associated with crestal labial soft tissue thickness. *Implant Dent*. 2012;21:406-410.
- Esquivel J, Gomez-Meda R, Blatz MB. The impact of 3D implant position on emergence profile design. *Int J Periodontics Restorative Dent*. 2021;41:79-86.
- Le B, Borzabadi-Farahani A, Pluemsakunthai W. Is buccolingual angulation of maxillary anterior implants associated with the crestal labial soft tissue thickness? *Int J Oral Maxillofac Surg*. 2014;43:874-878.
- Pluemsakunthai W, Le B, Kasugai S. Effect of buccal gap distance on alveolar ridge alteration after immediate implant placement: a micro-computed tomographic and morphometric analysis in dogs. *Implant Dent*. 2015;24(1):70-76.
- Bittner N, Schulze-Späte U, Silva C, et al. Changes of the alveolar ridge dimension and gingival recession associated with implant position and tissue phenotype with immediate implant placement: a randomised controlled clinical trial. *Int J Oral Implantol (Berl)*. 2019;12(4):469-480.
- Buser D, Ruskin J, Higginbottom F, et al. Osseointegration of titanium implants in bone regenerated in membrane-protected defects: a histologic study in the canine mandible. *Int J Oral Maxillofac Implants*. 1995;10:666-681.
- Wessing B, Lettner S, Zechner W. Guided bone regeneration with collagen membranes and particulate graft materials: a systematic review and meta-analysis. *Int J Oral Maxillofac Implants*. 2018;33(1):87-100.
- Le B, Rohrer M, Prasad H. Screw "tent-pole" grafting technique for reconstruction of large vertical alveolar ridge defects using human mineralized allograft for implant site preparation. *J Oral Maxillofac Surg*. 2010;68:428-435.
- Elnayef B, Porta C, Suárez-López Del Amo F, et al. The fate of lateral ridge augmentation: a systematic review and meta-analysis. *Int J Oral Maxillofac Implants*. 2018;33(3):622-635.
- Jensen SS, Bosshardt DD, Gruber R, Buser D. Long-term stability of contour augmentation in the esthetic zone. Histologic and histomorphometric evaluation of 12 human biopsies 14 to 80 months after augmentation. *J Periodontol*. 2014;10:1-15.
- Le B, Burstein J. Esthetic grafting for small volume hard and soft tissue contour defects for implant site development. *Implant Dent*. 2008;17:136-141.
- Le BT, Borzabadi-Farahani A. Simultaneous implant placement and bone grafting with particulate mineralized allograft in sites with buccal wall defects, a three-year follow-up and review of literature. *J Cranio Maxillofacial Surg*. 2014;42:552-559.
- Belser U, Schmid B, Higginbottom F, et al. Outcome analysis of implant restorations located in the anterior maxilla: a review of the recent literature. *Int J Oral Maxillofac Implants*. 2004;19:30-42.
- Schenk RK, Buser D, Hardwick WR, Dahlin C. Healing pattern of bone regeneration in membrane-protected defects: a histologic study in the canine mandible. *Int J Oral Maxillofac Implants*. 1994;9:13-29.
- Sculean A, Nikolidakis D, Schwarz F. Regeneration of periodontal tissues: combinations of barrier membranes and grafting materials – biological foundation and preclinical evidence: a systematic review. *J Clin Periodontol*. 2008;35:106-116.
- Louis P. Vertical ridge augmentation using titanium mesh. *Oral Maxillofac Surg Clin North Am*. 2010;22:353-368.
- Block MS, Degen M. Horizontal ridge augmentation using human mineralized particulate bone: preliminary results. *Oral Maxillofac Surg*. 2004;62:67-72.
- Block MS. Closed approach for horizontal augmentation of the maxilla. *J Oral Maxillofac Surg*. 2018;76(3):521-527.
- Lee EA. Subperiosteal minimally invasive aesthetic ridge augmentation technique (SMART): a new standard for bone

- reconstruction of the jaws. *Int J Periodontics Restorative Dent*. 2017; 37(2):165-173.
29. Wang H, Boyapati L. "PASS" principles for predictable bone regeneration. *Implant Dent*. 2006;15:8-17.
30. Nishimura I, Shimizu Y, Ooya K. Effects of cortical bone perforation on experimental guided bone regeneration. *Clin Oral Implants Res*. 2004;15:293-300.
31. Slotte C, Lundgren D, Sennerby L, Lundgren A. Surgical intervention in endochondral and membranous bone: intra-individual comparisons in the rabbit. *Clin Implant Dent Relat Res*. 2003;5:263-268.
32. Alvira-González J, De Stavola L. The role of cortical perforations in bone regeneration: a systematic review. *Int J Oral Maxillofac Surg*. 2020;49(7):945-951.
33. Spray JR, Black CG, Morris HF, Ochi S. The influence of bone thickness on facial marginal bone response: stage 1 placement through stage 2 uncovering. *Ann Perio*. 2000;5:119-128.
34. Le B, Borzabadi-Farahani A, Nielsen B. Treatment of labial soft tissue recession around dental implants in the esthetic zone using guided bone regeneration with mineralized allograft: a retrospective clinical case series. *J Oral Maxillofac Surg*. 2016;74(8):1552-1561.
35. Le B, Borzabadi-Farahani A. Treatment of labial mucosal recession around maxillary anterior implants with tenting screws, particulate allograft and xenogenic membrane: a case report. *J Oral Implantol*. 2016;42(5):427-431.
36. Le B, Burstein J, Sedghizadeh PP. Cortical tenting grafting technique in the severely atrophic alveolar ridge for implant site preparation. *Implant Dent*. 2008;17:40-50.
37. Salama H, Salama MA, Garber D, Adar P. The inter-proximal height of bone: a guide post to predictable aesthetic strategies and soft tissue contours in anterior tooth replacement. *Pract Periodontics Aesthet Dent*. 1998;10:1131-1141.
38. Su H, Gonzalez-Martin O, Weisgold A, Lee E. Considerations of implant abutment and crown contour: critical contour and subcritical contour. *Int J Periodontics Restorative Dent*. 2010;30(4):335-343.

How to cite this article: Le B, Hayashi N. The Aesthetic Contour Graft - Enhancing peri-implant soft tissue contours and pontic sites with guided bone regeneration. *J Esthet Restor Dent*. 2022;34(1):188-202. doi:10.1111/jerd.12865