

## Comparison of comma incision with Ward's incision in third molar extraction in terms of postoperative sequel – A clinical study

### ABSTRACT

**Objective:** The objective of the study was to compare standard Ward's incision and comma-shaped incision and its influence on postoperative complications in surgical removal of impacted mandibular third molar.

**Materials and Methods:** This was a prospective study. Fifty individuals divided into two groups with impacted mandibular third molars were recruited for the study. Twenty-five individuals were allocated to each group: a standard Ward's incision was made in Group A and a comma incision was made in Group B to reflect the mucoperiosteal flap, after which the common steps for removal of impacted third molars were followed. The postoperative parameters were recorded immediately on the postoperative days 1, 3, and 7.

**Observation and Results:** The pain scores which were recorded on days 1, 3, and 7 in the surgical area with comma incisions were found to be significantly lower as compared to the pain scores in the area where standard incisions were made. Similarly, swelling was lesser with comma incision than with standard Ward's incision. There was a significant difference in mouth opening between the two incisions on day 1, but no significance was seen on days 3 and 7. All of these findings showed significant statistical differences.

**Summary and Conclusions:** The results of the study showed that the new comma-shaped incision design was preferable over the conventional method (Ward's incision), considering the lesser degree of postoperative complications.

**Keywords:** Comma incision, third molar, Ward's incision

### INTRODUCTION

Third molars are the most commonly impacted teeth in the oral cavity, with 33% of the population having at least one tooth impacted. It is probably the result of both genetic and environmental factors. Surgical removal of third molars is one of the most frequently performed procedures in the oral and maxillofacial practice to prevent or to treat a variety of pathoses originating from impacted teeth.<sup>[1,2]</sup> Removal of such teeth requires sound understanding of the surgical principles along with patient management skills. It must be performed properly to allow expeditious and atraumatic removal of teeth embedded in a relatively atraumatic area of the oral cavity. Although it is a minor surgical procedure, its relation to the adjacent teeth, soft tissues, and neurovascular bundle makes it a complex procedure.<sup>[3]</sup>

Surgical removal involves the manipulation of both soft and hard tissues, so it is usually associated with a number of postoperative complications.<sup>[4-7]</sup> Therefore, reducing the

**ASHIQ ALI, SHAHI JAHAN SHAH<sup>1</sup>, AJAZ A. SHAH, SEHAR ASLAM<sup>2</sup>**

Department of Oral and Maxillofacial Surgery, Government Dental College, <sup>2</sup>Department of Gynaecology and Obstetrics, Government Medical College, Srinagar, Jammu and Kashmir, India, <sup>1</sup>Department of Oral and Maxillofacial Surgery, College of Dentistry, King Khalid University, Abha, Kingdom of Saudi Arabia

**Address for correspondence:** Dr. Shahi Jahan Shah, Department of Oral and Maxillofacial Surgery, College of Dentistry, King Khalid University, Abha, Kingdom of Saudi Arabia. E-mail: shahimaxfacurg@gmail.com

**Received:** 07-05-2018, **Revised:** 17-11-2018, **Accepted:** 26-03-2019, **Published:** 12-11-2019

This is an open access journal, and articles are distributed under the terms of the Creative Commons Attribution-NonCommercial-ShareAlike 4.0 License, which allows others to remix, tweak, and build upon the work non-commercially, as long as appropriate credit is given and the new creations are licensed under the identical terms.

**For reprints contact:** reprints@medknow.com

**How to cite this article:** Ali A, Shah SJ, Shah AA, Aslam S. Comparison of comma incision with Ward's incision in third molar extraction in terms of postoperative sequel – A clinical study. Natl J Maxillofac Surg 2019;10:200-5.

#### Access this article online

**Website:**  
www.njms.in

**DOI:**  
10.4103/njms.NJMS\_39\_18

#### Quick Response Code



incidence of these complications becomes imperative, which is possible only with a thorough knowledge of the various factors affecting them. One of the factors influencing the postoperative outcome following third molar surgery is the incision and flap design. Flap design is important not only to allow optimal visibility and access to the impacted tooth but also for subsequent healing of the surgically created defect.<sup>[8]</sup>

Being the most frequent procedure that is being performed in maxillofacial practice, the emphasis on curtailing the complications of impacted mandibular third molar is a prime pursuit. Trismus, pain, swelling, lingual nerve damage, and compromised periodontal status of preceding second molar are complications that occur too frequently to be ignored. Incision and flap design in any surgical procedure is based on time-tested principles. Incision lines should not, as far as possible, lie over prospective bony defects or cut across major muscle or tendon insertions. They should be minimally extensive. However, the distal leg of the incisions conventionally made to access impacted mandibular molars comes close to or even cuts across the insertion of temporalis tendon. It also commonly lies over bone defect formed after removal of the tooth. This could be responsible, at least in part, for the occurrence of these complications. This, therefore, is reason enough to consider alternative incision and flap designs.<sup>[9]</sup>

In this study, an attempt has been made to compare the traditional Ward's incision against the distolingually based flap design, i.e., comma incision to evaluate the influence of flap designs on the postoperative complications, including pain, trismus, swelling, and wound healing.

## MATERIALS AND METHODS

A prospective, randomized study was conducted on patients visiting the Department of Oral and Maxillofacial Surgery in Government Dental College and Hospital, Srinagar.

### Criteria for the selection of patients

1. American society of anesthesiologists Group 1 patients, with completely covered impacted mandibular third molars
2. Medically fit patients in the age range of 18–35 years, including both the sexes, with no significant habits, without local inflammation or other pathoses
3. Patients willing to report for follow-up study
4. Patients with mandibular second molar
5. Patients with no inferior alveolar nerve impingement.

Fifty patients who fulfilled the above criteria were selected. Before the surgical procedure, all patients were informed

about the surgery, postoperative recommendations, and possible complications, so an informed consent was obtained.

Before surgery, a periapical radiograph was taken for each gradient. All patients were treated and observed by the same surgeon.

They were randomly divided into two groups:

- Comma incision group (Group 1) and
- Ward's incision group (Group 2).

Each group consists of 25 patients.

The diagnosis of impacted teeth was done using intraoral periapical (IOPA) radiograph.

A pro forma was prepared and filled according to the examination done:

- Preoperatively
- Immediate postoperatively
- On 1<sup>st</sup>, 3<sup>rd</sup>, and 7<sup>th</sup> postoperative days.

### The scores of the parameters of the study were as follows:

1. Pain scores (using Visual Analog Scale by White and Strunin)<sup>[10]</sup>
2. Facial swelling (by measuring distance between the base of the tragus and a reproducible soft-tissue pogonion along skin surface given by Schultze-Mosgau *et al.*)<sup>[11]</sup>
3. Trismus (by measuring maximal interincisal distance as the index of trismus using divider and a ruler as advocated by "Wood and Branco")<sup>[12]</sup>
4. Wound healing (measured using clinical criteria for satisfactory wound healing given by "Holland and Hindle"<sup>[13]</sup> stating.

For recording the above-mentioned parameters:

- Patients should be pain free
- Healing should be of primary intention, or if healing occurred by secondary intention, the socket should be self-cleansing (not requiring any occlusive dressing).

### Preoperative examination

Before surgery, pain, swelling, and maximal mouth opening were evaluated.

### Surgical technique

- Comma incision was used in Group 1
- Ward's incision was used in Group 2.

In total, 25 Ward's incision patients and 25 comma incision patients were placed. Third molar surgery was performed on the patient under local anesthesia. All the patients in this study were anesthetized using classical inferior

alveolar nerve, lingual nerve, and long buccal nerve block using 2 ml of 2% lignocaine local anesthetic agent with adrenaline (1:200,000).

### Ward's incision

The flap consisted of a sulcular incision starting near the mesiobuccal edge of the second or first molar (depending on the depth of the impaction) to its distal surface. A relieving incision was made in the mesial region without cutting the interdental papilla. Another relieving incision was made in the mandibular ramus. Then, a full-thickness mucoperiosteal flap was elevated [Figure 1].

### Comma incision

The flap consists of a buccal incision starting from a point at the depth of the stretched vestibular reflection posterior to the distal aspect of the preceding second molar.

The incision is made in an anterior direction to a point below the second molar from where it is smoothly curved up to meet the gingival crest at the distobuccal line angle of the second molar. The incision is continued as a crevicular incision around the distal aspect of the second molar. Then, a distolingually based flap adequately exposing the entire third molar area is reflected [Figure 2].

Minimum osteotomy and tooth sectioning were performed with a round bur and a fissure bur, respectively, and irrigated with sterile saline. The distal bone adjacent to the second molar was preserved. The flap was repositioned and closed with 3-0 Black Braided Silk Sutures. The incisions were closed with simple interrupted sutures and all the patients were prescribed amoxicillin, metronidazole, and diclofenac potassium for 5–7 days. The duration of the operation was noted.

### Postoperative examination

Clinical examinations were carried out preoperatively, immediate postoperatively, and at 24<sup>th</sup> h, 3<sup>rd</sup> day, and 7<sup>th</sup> day postoperatively after third molar surgery. Pain,

trismus, and swelling were recorded preoperatively, immediate postoperatively, and at 24<sup>th</sup> h, 3<sup>rd</sup> day, and 7<sup>th</sup> day postoperatively, while wound healing was recorded at 7<sup>th</sup> postoperative day.

A postoperative examination evaluated pain, maximal mouth opening, and degree of postoperative swelling and wound healing. The values were tabulated and were subjected to statistical analysis [Figures 3-6].

### Methods of statistical analysis

The following methods of statistical analysis have been used in this study. The data were collected on forms and entered into a Microsoft Excel Worksheet and analyzed using SPSS for Windows, Version 16.0 (SPSS Inc., Chicago, USA). The results were averaged (mean standard deviation) for each parameter and presented in tables and figures.

1. Student's *t*-test was used to find a significant difference between two means
2. Mann–Whitney U-test (for wound healing score and pain score) was applied to find the significant difference between two independent groups
3. Repeated measurement design was used to test changes in scores of pain, swelling, and trismus over the time.

In all the above tests,  $P < 0.05$  was accepted as indicating statistical significance.

### OBSERVATION AND RESULTS

A total number of 50 cases with a mean age of 25.12 years  $\pm$  4.97 were studied to compare the postoperative complications using Ward's and comma incision flap designs in impacted mandibular third molar removal. Majority of the patients in this study were between 18 and 30 years (80%). Of 50 patients, 16 were male (32%) and 34 were female (68%).

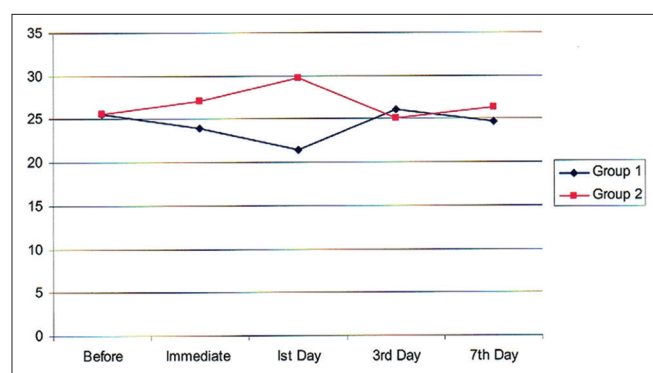


Figure 1: Pain Group 1 versus Group 2 in terms of mean rank with time

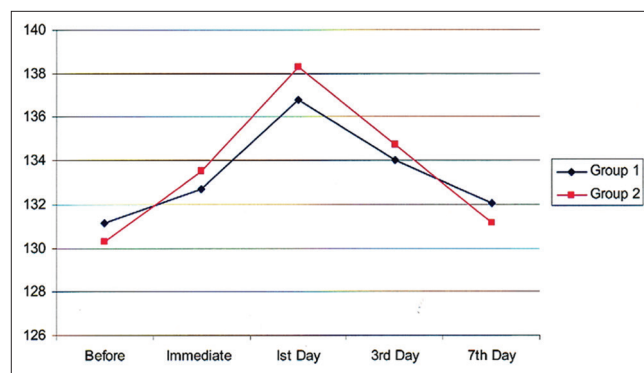


Figure 2: Swelling Group 1 versus Group 2 in terms of distance (in millimeters) from tragus to pogonion in relation to time

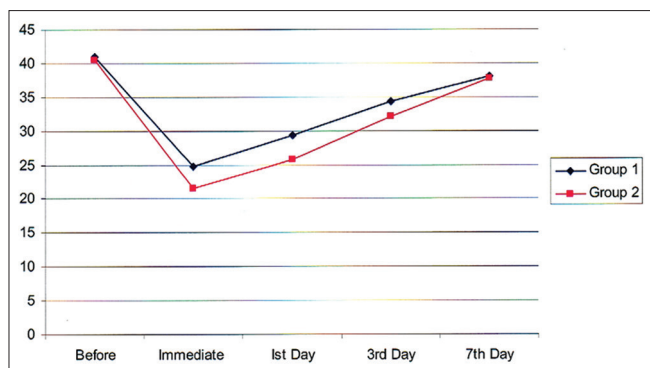


Figure 3: Trismus Group 1 versus Group 2 in terms of interincisal distance in millimeters in relation to time

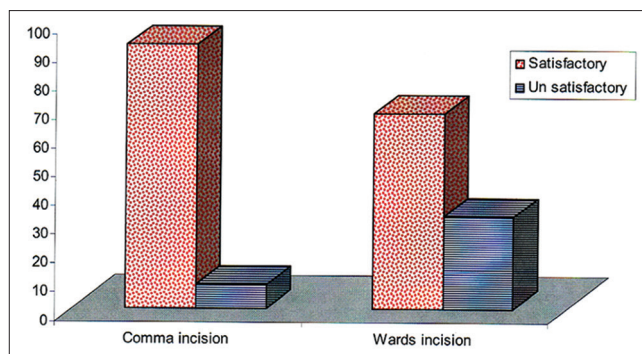


Figure 4: Wound healing at 7<sup>th</sup> postoperative day Group 1 versus Group 2 in terms of percentage of patients with satisfactory and unsatisfactory healing

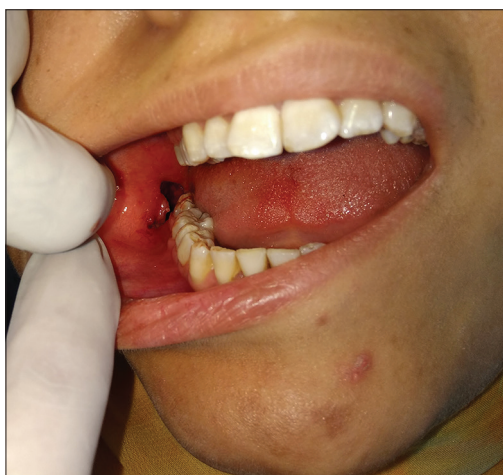

Figure 5: Comma incision

With Ward's incision design, the duration of surgery ranged from 20 to 45 min with a mean of 30.75 min  $\pm$  8.63 and with comma incision flap design 22–44 min with a mean of 30.15 min  $\pm$  8.52. There were no statistically significant differences between the two flap design groups in terms of duration of surgery ( $P > 0.05$ ).

At the 1<sup>st</sup> postoperative day, there were statistically significant differences between the two flap groups ( $P < 0.05$ ) in terms of pain. The mean rank obtained for Ward's incision and comma incision groups was 29.66 and 21.34 at the 1<sup>st</sup> postoperative day, respectively. However, by immediate, 3<sup>rd</sup> day, and 7<sup>th</sup> day postoperatively, the differences in the pain scores between the two flap design groups become insignificant ( $P > 0.05$ ).

The measurement of swelling showed no statistically significant differences between the Ward's and comma incision groups ( $P > 0.05$ ). However, in both the flap groups, measurement of swelling displayed the following evolution: an increase at the 1<sup>st</sup> day postoperatively, followed by a slight decrease at the 3<sup>rd</sup> day and a further

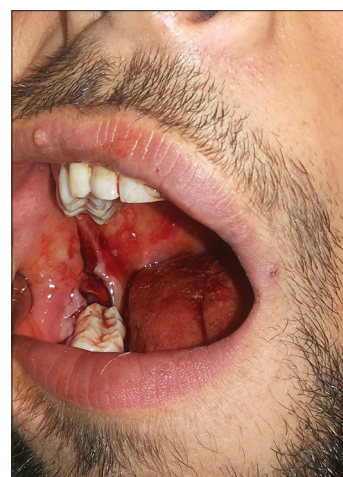

Figure 6: Ward's incision

decrease at the 7<sup>th</sup> day postoperatively. The measurement of swelling in each group shows statistically significant results ( $P < 0.05$ ).

The measurement of trismus shows statistically significant results between the two flap groups ( $P < 0.05$ ) at immediate, 1<sup>st</sup> day, and 3<sup>rd</sup> day postoperatively. The mean score obtained for Ward's flap group was 21.48, 25.76, and 32.00 at immediate, 1<sup>st</sup> day, and 3<sup>rd</sup> day postoperatively, respectively. Similarly, the mean score for comma incision flap group at immediate, 1<sup>st</sup> day, and 3<sup>rd</sup> day postoperatively was 24.76, 29.36, and 34.32, respectively. However, by the 7<sup>th</sup> postoperative day, differences in trismus in both the flap groups become statistically insignificant.

The assessment of wound healing (as per guidelines put forth by Holland and Hindle) shows statistically significant results ( $P < 0.05$ ) at the 7<sup>th</sup> postoperative day between the two flap groups. Unsatisfactory healed sockets were managed with repeated local normal saline irrigations, analgesics, and antibiotics wherever necessary.

## DISCUSSION

Flap design is one of the factors influencing the severity of postoperative complications.<sup>[3,14-17]</sup> For this reason, we have compared two different flap designs: ward's incision flap design, which is the traditional technique for third molar surgery, and distolingually based comma incision flap design, which is a new flap.

Pain, swelling, and trismus are the common sequelae of the surgical removal of the impacted third molars. All three phenomena (pain, swelling, and trismus) may reflect the formation of prostaglandins and other mediators of pain and swelling from membrane phospholipids as a result of surgery. The first clear presentation of the normal time course of these events was published by Szmyd in 1965.

Among the factors which account for the variation in various signs and symptoms are differences in patient population, surgical techniques, and methods of assessment. There is also considerable variation from patients to patients in occurrence and relative severity of signs and symptoms.<sup>[18]</sup>

There are several factors that influence the pain experience<sup>[6,9,19]</sup> and the methods to assess pain are given in the literature.<sup>[9]</sup> In the present study, pain is assessed using Visual Analog Scale 64–67 as this method of pain assessment is simple and easily understandable. Szmyd reported that onset of pain begins once the effects of the local anesthetic agents subside. Unless treated, moderate-to-severe pain usually occurs during the first 12 h, with peak intensity after 6–8 h, when a conventional local anesthetic is used. The pain then gradually subsides within a few days, if normal healing occurs. In the present study, statistically significant lower pain scores were recorded at the 1<sup>st</sup> postoperative day and proportionately lower pain scores (but statistically insignificant) were recorded at immediate, 3<sup>rd</sup> day, and 7<sup>th</sup> day postoperatively in the comma incision group as compared to the Ward's incision group. This could be because of the less tissue trauma as compared to the conventional incisions. This is in accordance with the results drawn by Neelkandan *et al.*<sup>[20]</sup> and Nageshwar.<sup>[9]</sup>

Several factors affect the swelling after third molar surgery,<sup>[9,17,21,22]</sup> and this can be assessed by various methods. In the present study, swelling is assessed in terms of horizontal distance from tragus to soft-tissue pogonion at the chin.<sup>[11]</sup> This method of assessing swelling is simple, easier, and economical. The time relation of swelling subsequent to mandibular third molar surgery has been examined in a number of studies. Szmyd reported that the development of swelling starts shortly after surgery and usually reaches

a maximum after 24–36 h.<sup>[23]</sup> The swelling then gradually subsides and disappears after approximately 1 week. The swelling is caused by extravasation of fluid and involves both vascular and cellular events. The surgical trauma triggers the release of mediators that cause a transient vasoconstriction of arterioles resulting in stasis of the blood and thus increases the permeability of the postcapillary venules resulting in extravasation of fluid. However, in the present study, the measurement of swelling (in both the flap groups) showed an increase at the 1<sup>st</sup> day postoperatively followed by a slight decrease at the 3<sup>rd</sup> day and a further decrease at the 7<sup>th</sup> day postoperatively. Overall, lesser (proportionately lower) swelling was recorded with comma incision group as compared to the Ward's incision group. This is in accordance with the results drawn by Neelkandan *et al.*<sup>[20]</sup> and Nageshwar.<sup>[9]</sup>

Interincisal distance has been a measure of trismus in a number of studies.<sup>[8,24]</sup> This can be measured either by caliper micrometer or a ruler. In this study, a divider and a ruler are used to measure the interincisal distance, as it is simple and economical.<sup>[12]</sup> Szmyd reported that trismus (restriction of mouth opening) peaks on the day of surgery. Other investigators found that trismus developed more slowly than swelling, reaching a maximum after 2–3 days.<sup>[23]</sup> Trismus also decreases more slowly than swelling; after 1 week, swelling subsides completely while roughly 40% of the maximal trismus may still be present.<sup>[12]</sup> In the present study, the measurement of trismus shows a statistically significant difference between the two flap designs ( $P < 0.05$ ) at immediate, 1<sup>st</sup> day, and 3<sup>rd</sup> day postoperatively. Thus, the levels of trismus were higher in the Ward's incision group as compared to the comma incision group. This could be because of the preservation of the critical anatomic structures in the third molar region due to its unique design. This is in accordance with the results drawn by Neelkandan *et al.*<sup>[20]</sup> and Nageshwar.<sup>[9]</sup>

The results of this study show statistically significant difference regarding wound healing for each of these flap designs at the 7<sup>th</sup> postoperative day. In Ward's incision group, 32% of the cases showed unsatisfactory healing, whereas in comma incision group, only 8% of the cases showed unsatisfactory healing. This may be attributable to the greater flap tension occurring with the Ward's incision resulting from postoperative edema and masticatory movements in the early postoperative period. This is in accordance with Jakse *et al.*<sup>[25]</sup> and Suarez-Cunqueiro *et al.*<sup>[15]</sup> that flap design influences primary wound healing after third molar surgery. Nevertheless, both the studies had used a single suture to adapt the flap coronally, thereby allowing depletion of the postoperative hematoma during masticatory movements. In the present study, 3–4 simple interrupted sutures were used to approximate the flap margins in Ward's incision group. This

may be the reason for higher percentage of unsatisfactory healing in the present study.

## SUMMARY AND CONCLUSIONS

Although in the present study the population size was small as compared to other studies to draw a significant statistical conclusion. However, the present study provided enough evidence to show that the conventional distal extension incisions for removing impacted mandibular third molar traumatizes various anatomical structures which can subsequently lead to complications discussed. So an alternative incision in the form of comma incision for mandibular teeth disimpaction was considered. After evaluation of the results, we came to the conclusion that this new comma incision may probably be a good substitute, considering the less degree of postoperative complications, i.e., a better wound healing, lower scores in pain, and proportionately lower swelling scores.

## Financial support and sponsorship

Nil.

## Conflicts of interest

There are no conflicts of interest.

## REFERENCES

1. Knutsson K, Brehmer B, Lysell L, Rohlin M. Pathoses associated with mandibular third molars subjected to removal. *Oral Surg Oral Med Oral Pathol Oral Radiol Endod* 1996;82:10-7.
2. Nencovsky CE, Libfeld H, Zubery Y. Effect of non-erupted 3<sup>rd</sup> molars on distal roots and supporting structures of approximal teeth. A radiographic survey of 202 cases. *J Clin Periodontol* 1996;23:810-5.
3. Kelley HC, Kay LW. *The Impacted Wisdom Tooth*. 2<sup>nd</sup> ed. London: Churchill Livingstone Co.; 1975. p. 1-9.
4. Goldberg MH, Nemarich AN, Marco WP 2<sup>nd</sup>. Complications after mandibular third molar surgery: A statistical analysis of 500 consecutive procedures in private practice. *J Am Dent Assoc* 1985;111:277-9.
5. Osborn TP, Frederickson G Jr., Small IA, Torgerson TS. A prospective study of complications related to mandibular third molar surgery. *J Oral Maxillofac Surg* 1985;43:767-9.
6. Sisk AL, Hammer WB, Shelton DW, Joy ED Jr. Complications following removal of impacted third molars: The role of the experience of the surgeon. *J Oral Maxillofac Surg* 1986;44:855-9.
7. Iizuka T, Tanner S, Berthold H. Mandibular fractures following third molar extraction. A retrospective clinical and radiological study. *Int J Oral Maxillofac Surg* 1997;26:338-43.
8. Andreasen JO, Peterson JK, Laskin DM. *Textbook and Color Atlas of Tooth Impactions: Diagnosis, Treatment and Prevention*. 1<sup>st</sup> ed. Munksgaard: Copenhagen; 1997. p. 219-313.
9. Nageshwar N. Comma incision for impacted mandibular third molars. *J Oral Maxillofac Surg* 2002;60:1506-9.
10. White P, Strunin L. Post-anaesthetic dental extraction analgesia: A comparison of paracetamol, codeine, caffeine (Solpadeine) and diflunisal (Dolobid). *Br J Oral Surg* 1982;20:275-80.
11. Schultze-Mosgau S, Schmelzeisen R, Frölich JC, Schmele H. Use of ibuprofen and methylprednisolone for the prevention of pain and swelling after removal of impacted third molars. *J Oral Maxillofac Surg* 1995;53:2-7.
12. Wood GD, Branco JA. A comparison of three methods of measuring maximal opening of the mouth. *J Oral Surg* 1979;37:175-7.
13. Holland CS, Hindle MO. The influence of closure or dressing of third molar sockets on post-operative swelling and pain. *Br J Oral Maxillofac Surg* 1984;22:65-71.
14. Wolf RH, Malmquist JP, Wright WH. Third molar extractions: Periodontal implications of two flap designs. *Gen Dent* 1978;26:52-6.
15. Suarez-Cunqueiro MM, Gutwald R, Reichman J, Otero-Cepeda XL, Schmelzeisen R. Marginal flap versus paramarginal flap in impacted third molar surgery: A prospective study. *Oral Surg Oral Med Oral Pathol Oral Radiol Endod* 2003;95:403-8.
16. Ten Bosch JJ, van Gool AV. The interrelation of postoperative complaints after removal of the mandibular third molar. *Int J Oral Surg* 1977;6:22-8.
17. Pedersen A. Interrelation of complaints after removal of impacted mandibular third molars. *Int J Oral Surg* 1985;14:241-4.
18. Guralnick W. Third molar surgery. *Br Dent J* 1984;156:389-94.
19. Clauser C, Barone R. Effect of incision and flap reflection on postoperative pain after the removal of partially impacted mandibular third molars. *Quintessence Int* 1994;25:845-9.
20. Neelkandan RS, Puneet W, Srinivasa PT, Pradeep D. Influence of incisions on post-operative complications in impacted mandibular 3<sup>rd</sup> molar removal. Comma incision versus standard incisions. *J Maxillofac Oral Surg* 2005;4:419-24.
21. Stephens RJ, App GR, Foreman DW. Periodontal evaluation of two mucoperiosteal flaps used in removing impacted mandibular third molars. *J Oral Maxillofac Surg* 1983;41:719-24.
22. Stanley HR, Alattar M, Collett WK, Stringfellow HR Jr., Spiegel EH. Pathological sequelae of "neglected" impacted third molars. *J Oral Pathol* 1988;17:113-7.
23. Szymd L. Impacted teeth. *Dent Clin North Am* 1971;15:299-318.
24. von Wowern N, Nielsen HO. The fate of impacted lower third molars after the age of 20. A four-year clinical follow-up. *Int J Oral Maxillofac Surg* 1989;18:277-80.
25. Jakse N, Bankaoglu V, Wimmer G, Eskici A, Pertl C. Primary wound healing after lower third molar surgery: Evaluation of 2 different flap designs. *Oral Surg Oral Med Oral Pathol Oral Radiol Endod* 2002;93:7-12.