

Research Article

Expression of Nestin, Vimentin, and NCAM by Renal Interstitial Cells after Ischemic Tubular Injury

David Vanstherthem,¹ Annabel Gossiaux,¹ Anne-Emilie Declèves,² Nathalie Caron,³
Denis Nonclercq,¹ Alexandre Legrand,² and Gérard Toubeau¹

¹Laboratory of Histology, Faculty of Medicine and Pharmacy, University of Mons, Avenue du Champ de Mars, 6 (Pentagone) 1B, 7000 Mons, Belgium

²Laboratory of Physiology and Pharmacology, Faculty of Medicine and Pharmacy, University of Mons, 7000 Mons, Belgium

³Laboratory of General Physiology, Faculty of Medicine, Facultés Universitaires Notre-Dame de la Paix, 5000 Namur, Belgium

Correspondence should be addressed to Gérard Toubeau, gerard.toubeau@umons.ac.be

Received 1 December 2009; Revised 12 March 2010; Accepted 13 April 2010

Academic Editor: Anton M. Jetten

Copyright © 2010 David Vanstherthem et al. This is an open access article distributed under the Creative Commons Attribution License, which permits unrestricted use, distribution, and reproduction in any medium, provided the original work is properly cited.

This work explores the distribution of various markers expressed by interstitial cells in rat kidneys after ischemic injury (35 minutes) during regeneration of S3 tubules of outer stripe of outer medulla (OSOM). Groups of experimental animals ($n = 4$) were sacrificed every two hours during the first 24 hours post-ischemia as well as 2, 3, 7, 14 days post-ischemia. The occurrence of lineage markers was analyzed on kidney sections by immunohistochemistry and morphometry during the process of tubular regeneration. In postischemic kidneys, interstitial cell proliferation, assessed by 5-bromo-2'-deoxyuridine (BrdU) and Proliferating Cell Nuclear Antigen (PCNA) labeling, was prominent in outer medulla and reach a maximum between 24 and 72 hours after reperfusion. This population was characterized by the coexpression of vimentin and nestin. The density of -Neural Cell Adhesion Molecule (NCAM) positive interstitial cells increased transiently (18–72 hours) in the vicinity of altered tubules. We have also localized a small population of α -Smooth Muscle Actin (SMA)-positive cells confined to chronically altered areas and characterized by a small proliferative index. In conclusion, we observed in the postischemic kidney a marked proliferation of interstitial cells that underwent transient phenotypical modifications. These interstitial cells could be implicated in processes leading to renal fibrosis.

1. Introduction

Renal ischemia leads to the development of an acute renal failure characterized by a massive tubular cell death mainly affecting S3 segments of proximal tubules in Outer stripe of outer medulla (OSOM). After a moderate ischemia (35 minutes), renal alterations rapidly elicit a process of regeneration leading to the restoration of both a normal tubular architecture and a normal renal function. An extensive literature exists about the cellular mechanisms involved in tubular regeneration but the source of regenerating cells remains highly controversial and still needs to be firmly established [1, 2]. It is generally accepted that these regenerating tubular cells derived from surviving resident cells that dedifferentiate and proliferate to restore the normal architecture and functions of proximal tubules [3]. However,

recent studies dedicated to the study of bone marrow stem cells (BMSC) have led to a re-evaluation of the process tubular regeneration [4–6]. These observations suggest that BMSC could rapidly be mobilized from peripheral blood to reach the kidney where they would establish, differentiate, and participate to tubular regeneration [7]. In support of this concept, we have found that extrarenal cells could be involved in postischemic kidney regeneration [8]. In the present study, we extend our initial findings by an immunohistochemical characterization of interstitial cells during a two week period consecutive to reperfusion.

Current evidence suggests that renal interstitium is not only a network of connective tissue around tubules but also represents an essential interface regulating vessels-tubules interactions. Interstitium plays a pivotal role during kidney embryogenesis but is also involved in the etiology

of various renal pathologies [9]. However, the structure of this interstitial compartment remains largely unknown since the distinction of the different interstitial cell types is barely possible in the narrow interstitial spaces. In normal conditions, numerous cell types, such as fibroblasts and cells of the immune system, coexist in renal interstitium but they exhibit a large polymorphism depending on their functional stage or their localization in the kidney [10]. In these conditions, the absence of precise data on the different cell types in normal kidney complicates the interpretation of structural observations in diseased kidneys.

In the present study, we have applied immunohistochemistry and double label immunofluorescence to determine the relative distribution of various markers (Table 1) expressed by renal interstitial cells in parallel to the regenerative processes consecutive to ischemic tubular injury. The main objective of our study was to investigate the potential involvement of these interstitial cells in the mechanisms leading to the restoration of a normal tubular structure. In this context, we have selected markers such as structural proteins known to be critical in the development of normal kidney or potentially involved in kidney regeneration. The selected markers were (1) vimentin as a marker of mesenchymal phenotype and/or dedifferentiation of tubular cells [11, 12]; (2) nestin as a marker expressed during kidney development [13–15], and (3) NCAM as a mesenchymal cell adhesion marker [3, 16]. The second objective of this work was to identify by immunohistochemistry the distribution of interstitial S-phase cells during the two weeks period needed for complete tubular regeneration.

Morphological observations after immunostaining revealed a consistent spatial organization of interstitial fusiform-shaped cells but also changes in the distribution of this population during the process of renal regeneration. Our study also revealed that these fusiform interstitial cells were never observed crossing the basement membrane of regenerating tubules. Locally, this cell population seems associated to fibrosis development around chronically altered tubules.

2. Materials and Methods

2.1. Animals and Treatment. All experiments were performed on 2-month old male Wistar rats weighing 200 to 250 g. originally obtained from Iffa Credo (Belgium) and bred in our animal facility. The animals were maintained and treated in compliance with the guidelines specified by the Belgian Ministry of Trade and Agriculture (agreement no. LA1500021).

Each experimental group of rats ($n = 4$) received an i.p. injection of BrdU (80 mg/kg b.w.) 1 hour prior to sacrifice. Before bilateral renal ischemia, the rats were anesthetized with an i.p. injection of sodium pentobarbital (60 mg/kg b.w.; Nembutal, CEVA, Brussels, Belgium). After a midline abdominal incision, the renal arteries and veins were carefully dissected from surrounding tissues and occluded by vascular clamps [11]. Ischemia was maintained for 35 minutes since preliminary experiments have shown that such an ischemic period led to the development of an acute renal failure characterized by massive cell death (90%)

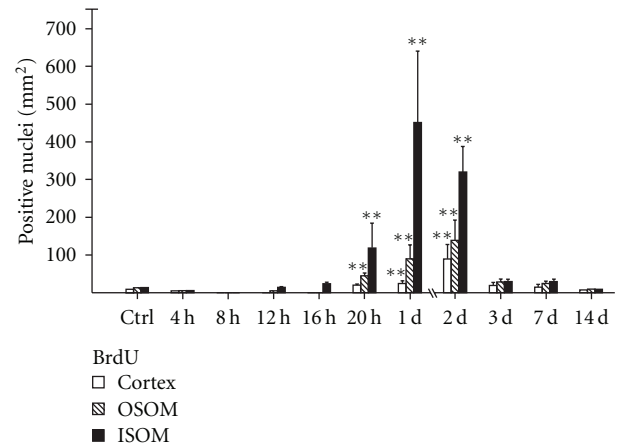


FIGURE 1: Density of S-phase fusiform interstitial cells evidenced by BrdU incorporation in cortex and outer medulla (OSOM, ISOM) of kidneys from control animals (Ctrl) or from animals sacrificed at increasing times (hours or days) after reperfusion. BrdU was administered to experimental animals 1 hour before sacrifice. Each column corresponds to the mean number of labeled nuclei per mm² (\pm SD) determined after examination of each region of the kidney for each experimental group ($n = 4$) (** $P < .01$ versus control).

mainly affecting S3 tubules. The renal alterations were followed by a process of regeneration leading to the restoration of tubular epithelium and of normal physiological functions one week after reperfusion [17]. The rats were sacrificed with a lethal injection of sodium pentobarbital every two hours during the first 24 hours post-ischemia as well as 2, 3, 7, 14 days post-ischemia. Four control rats not submitted to renal ischemia have received BrdU and were sacrificed one hour later.

2.2. Sample Processing for Histology. Immediately after sacrifice, the kidneys were removed and fixed by immersion in Duboscq-Brazil fluid or in 4% paraformaldehyde for 48 hours at room temperature. After fixation, the tissue specimens were dehydrated, embedded in paraffin, and sectioned according to standard procedures. Paraffin sections of 4–5 μ m thickness were obtained on a Reichert Autocut 2040 microtome and placed on silane-coated glass slides. Sections were stained with PAS, hemalun, and Luxol fast blue to allow the systemic examination of morphological alterations.

2.3. Immunohistochemical Procedures. The detection of BrdU incorporated into DNA was performed as previously detailed [8, 11]. Interstitial cells in ischemic kidney were analyzed for the presence of various markers by using a panel of primary antibodies (Table 1) chosen for their specificity for the target antigen in rat tissues. Paraffin sections were immunostained following a slightly modified version of the streptavidine-biotin immunoperoxidase method (ABC method) detailed in previous publications [8, 11]. Briefly, the sections were incubated sequentially at room temperature in the following solutions: (1) primary antiserum at optimal dilutions (see Table 1) for 1 hour (2) biotinylated swine

TABLE 1: Antibodies used for the immunohistochemical characterization of interstitial cells in rat kidney.

Primary antibodies	Origin	Dilution
AntiBrdU (Bromodeoxyuridine)	Mouse monoclonal (Bu20a)*—Dako, DK	1 : 20
AntiPCNA	Mouse monoclonal (PC 10)*—Dako, DK	1 : 40
Antivimentin	Chicken, polyclonal—Chemicon, USA	1 : 1000
Antirodent nestin	Mouse monoclonal (Rat-401)*—Chemicon, USA	1 : 100
Anti-NCAM (Neural cell adhesion molecule)	Rabbit, polyclonal—Chemicon, USA	1 : 100
Antihuman α -SMA (Smooth muscle actin)	Rabbit, polyclonal—Abcam, UK	1 : 200

* Antibody-producing clone.

antirabbit IgG, biotinylated goat antimouse IgG (diluted 1 : 50) or biotinylated goat antichickn IgY (diluted 1 : 50) for 30 minutes and (3) ABC complexes for 30 minutes. Biotinylated goat antichickn antibody came from Vector Laboratories (Burlingame, USA) while other secondary antibodies and ABC complex came from Dakopatts (Glostrup, Denmark). Bound peroxidase activity was visualized by incubation with 0.02% 3, 3'-diaminobenzidine—0.01% H₂O₂ in PBS. The sections were finally counterstained with PAS, hemalun and Luxol fast blue and finally mounted in a permanent medium. Controls for the specificity of immunolabeling included the omission of the primary antibody or the substitution of nonimmune sera for the primary antibodies.

Double-label immunofluorescence were performed following protocols extensively described in a previous publication [18] and using antisera raised in different species to avoid cross-reactivity between secondary antibodies. Briefly, the sections were incubated for 1 hour at room temperature with a mixture of two primary antibodies at the correct dilution. The sections were then incubated for 30 minutes at room temperature in presence of biotinylated swine antirabbit IgG antibody and FITC-conjugated goat antimouse IgG antibody (Dakopatts) both at a final dilution of 1 : 50. Finally, the immunostaining was completed by incubating for 30 minutes at room temperature with Texas red-conjugated streptavidine (Vector Laboratories Inc., Burlingame, Calif, USA) diluted 1 : 50. After final rinses in distilled water, the sections were mounted in Vectashield mounting medium (Vector Laboratories, Inc., Burlingame, Calif, USA). The superimposition of the immunofluorescence patterns revealed the respective distribution of both markers in renal tissue.

2.4. Morphological Analysis. The sections were observed on a Leitz Orthoplan fluorescence microscope equipped with a Ploem system for epi-illumination. Pictures were obtained by a PC-driven digital camera (Leica DC 300F, Leica Microsystems AG, Heerbrugg, Switzerland). The computer software (KS 400 imaging system, Carl Zeiss vision, Hallbergmoos, Germany) allowed the superimposition of images to detect colocalisations and was also used to perform morphometric analysis.

For each experimental group, we have analyzed the tissue distribution of interstitial cells immunolocalized by the different primary antibodies tested in our study (Table 1) using consecutive renal sections for each experimental ani-

mal. To standardize the evaluation procedure, an additional lens engraved with a 1 cm² square grid was inserted in one of the microscope eyepieces. Each paraffin section was systematically scanned at 400 fold magnification, the square grid covering in the field an actual area of 0.084 mm², until a total 10 square fields were evaluated for each region of the kidney (Cortex, OSOM, and ISOM). In each field and for each marker, this magnification allowed (i) the distinction of positive cellular profiles and (ii) the identification of histological structures localized in the immediate vicinity of positive cells such as type of renal tubules, blood vessels or areas of interstitial fibrosis. In the present case, however, only nucleated positive cellular profiles were considered. For each marker, the observations were expressed as the number of positive cells or positive nuclei (BrdU, PCNA) per square millimeter in each region of the kidney (cortex, OSOM, and ISOM). Individual observations were pooled for each marker and for each zone of the kidney and presented in histograms as mean \pm SD. Results obtained from morphological analysis for most markers were submitted to analysis of variance (ANOVA) and a post-hoc Dunnet's test by comparison to controls with the limit of significance set at $P < .05$.

3. Results

The analysis of S-phase cells distribution within kidneys only revealed dividing S3 tubular cells (Figure 2(c); detailed in 8) and fusiform interstitial cells (Figure 2(b)). From 20 hours after reperfusion, the density of S-phase fusiform cells rose significantly in outer medulla to reach maximum values at 1 day both in ISOM (Figure 1) and in OSOM (Figures 1 and 2(b)). After 3 days, the density of dividing interstitial fusiform cells declined rapidly to resume the appearance of controls (Figures 1, 2(a) versus 2(d)).

In kidneys from control rats, vimentin immunoreactivity was observed in interstitium in glomerular podocytes, in endothelium of peritubular capillaries and vasa recta of the medulla and in the media of arterioles. In control animals, tubular cells were generally negative but vimentin expression was sometimes found focally in cells devoid of brush border (Figure 5(a)). Within kidney interstitium, vimentin immunoreactivity was detected in cells interspersed among renal tubules. In controls, vimentin-positive fusiform interstitial cells were present in the different zones of renal interstitium (Figures 3 and 5(a)). This cell population was disposed along a gradient (Figure 3) characterized by low

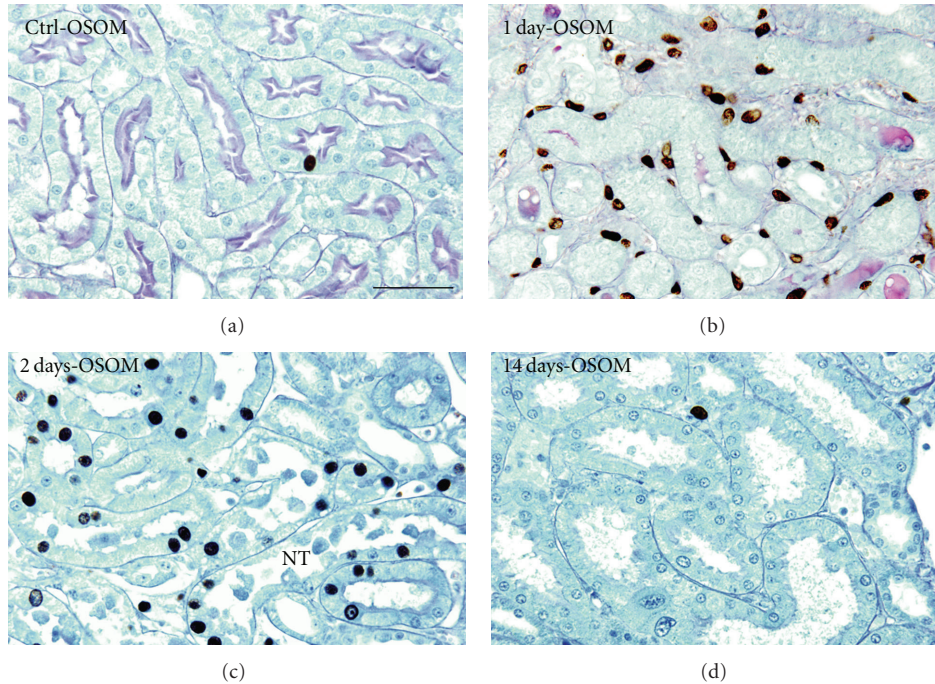


FIGURE 2: Immunohistochemical demonstration of BrdU-containing nuclei of S-phase cells in OSOM of control kidneys (a) or after reperfusion (b, c, d). S3 tubules of controls are characterized by a very low cell turn-over (a). In contrast cell proliferation increases dramatically in injured tubules two days after ischemia (c). The density of interstitial BrdU-positive cells is high in the periphery of necrotic tubules (NT) 1 and 2 days after ischemia (b, c) but appear similar to controls 2 week after ischemia (d). Scale bar. 30 μm : (a, b); 25 μm : (c, d).

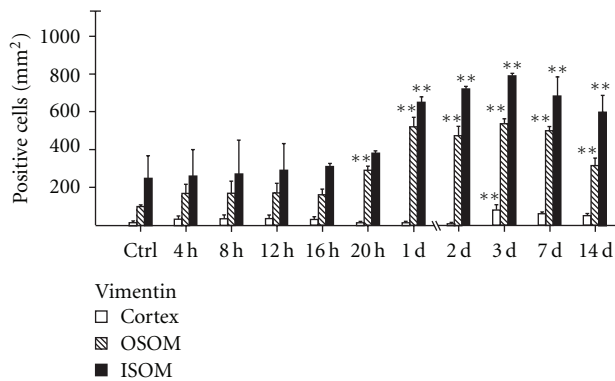


FIGURE 3: Distribution of vimentin immunoreactivity in the renal interstitium from controls (Ctrl) or from animals sacrificed at increasing time intervals (hours or days) after reperfusion. Each column corresponds to the mean number of vimentin immunoreactive fusiform cells (\pm SD) after examination of cortex and outer medulla (OSOM, ISOM) for each experimental group ($n = 4$) (** $P < .01$ versus control).

density within cortex (~ 35 cells/mm²) to higher densities in OSOM (~ 100 cells/mm²) and ISOM (~ 250 cells/mm²). From 20 hours after ischemia, the number of immunoreactive cells raised significantly both in OSOM and in ISOM to reach a maximum value at 3 days (Figures 3; 5(c), 5(e), and 5(g)). Double label immunofluorescence for vimentin and PCNA (Figure 8(b)) confirmed that this cell category

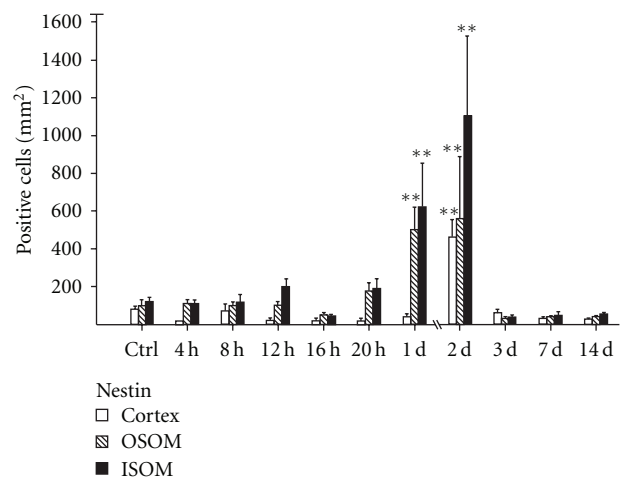


FIGURE 4: Distribution of nestin immunoreactivity in the renal interstitium from controls (Ctrl) or from animals sacrificed at increasing time intervals (hours or days) after reperfusion. Each column corresponds to the mean number of nestin immunoreactive fusiform cells (\pm SD) after examination of cortex and outer medulla (OSOM, ISOM) for each experimental group ($n = 4$) (** $P < .01$ versus control).

was able to divide within interstitium. At long term (1 and 2 weeks), the density of interstitial fusiform cells expressing vimentin remained high in OSOM and was preferentially localized in chronically altered areas characterized by the presence of residual cystic tubules.

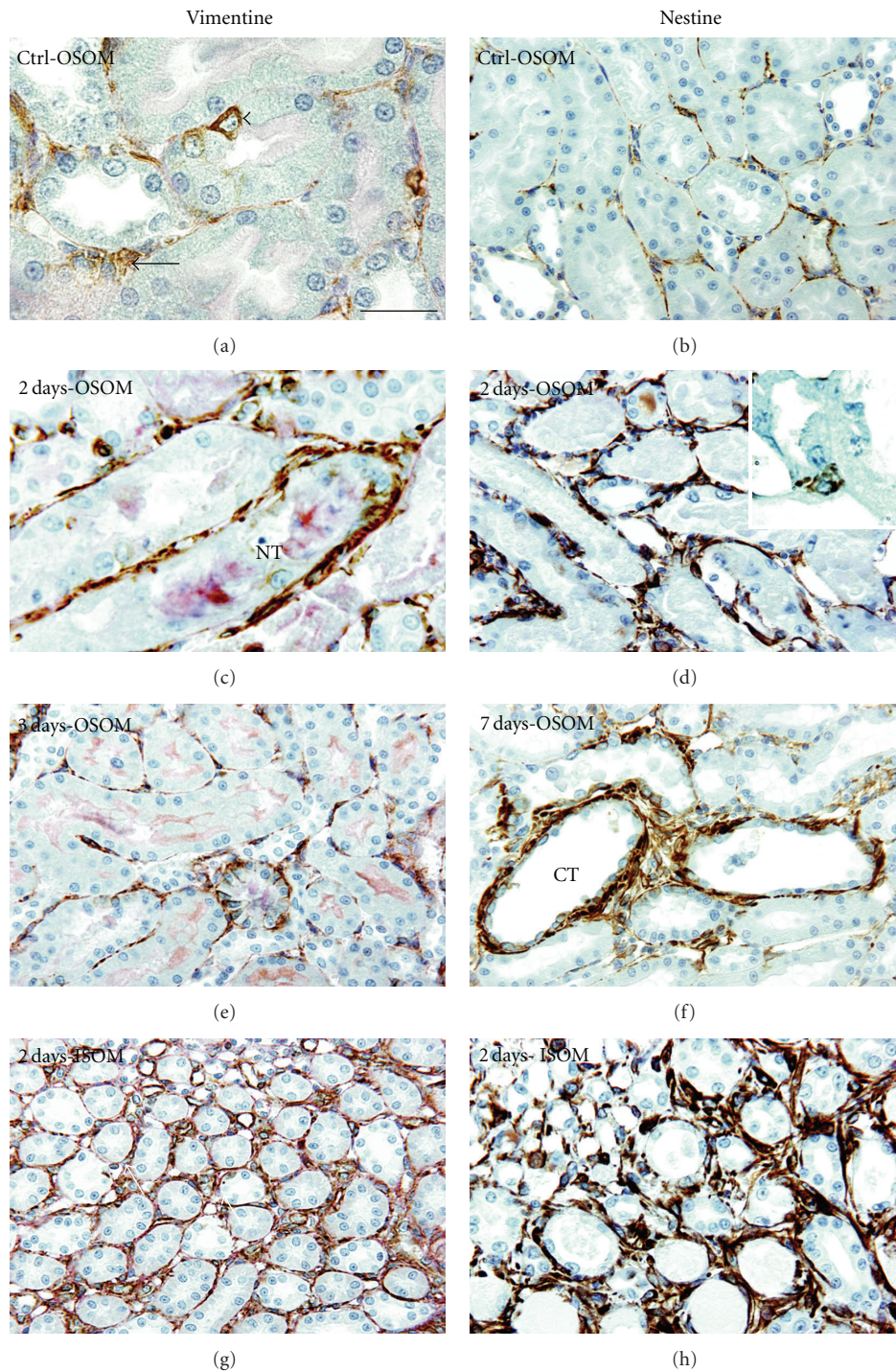


FIGURE 5: Distribution of vimentin-positive cells (left column) and of nestin-positive cells (right column) in the renal interstitium of control (a, b) or at different time intervals after ischemia-reperfusion (c–h). In control (a), vimentin-positive fusiform cells are scarce within interstitium (arrows) of OSOM. Focally in S3 tubules, undifferentiated epithelial cells devoid of brush border (arrowhead) appeared positive. Two and three days after reperfusion (c, e) vimentin-positive fusiform cells are localized around S3 necrotic tubules (NT) in OSOM. At the same period (2 days—(g)), their density is higher within ISOM. (b) Distribution of nestin positive cells in interstitium of OSOM in a control animal. Two days after reperfusion (d), nestin-positive fusiform cells form a dense network around necrotic tubules (NT) in OSOM. Focally, isolated epithelial cells appeared positive in altered tubules (d inset). Later, 7 days after reperfusion (f), positive cells are restricted to periphery of cystic tubules (CT). In ISOM (h), the density of fusiform positive cells is particularly high 2 days after reperfusion. Scale bar. 18 μm : (a, c); 25 μm : (d); 30 μm : (b, e, f, g, h).

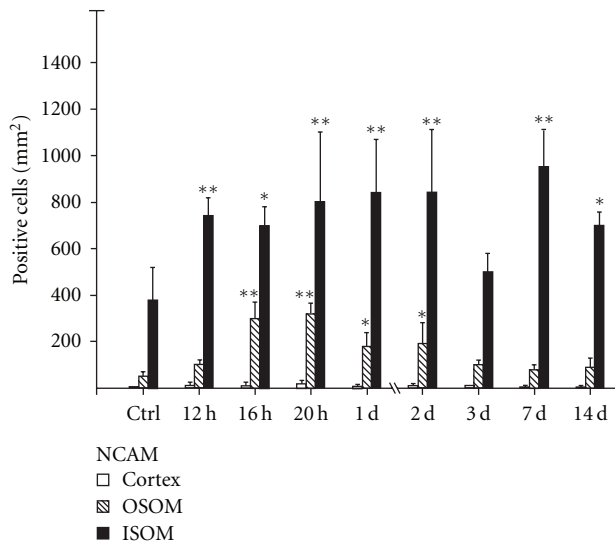


FIGURE 6: Distribution of NCAM immunoreactivity in the renal interstitium from controls (Ctrl) or from animals sacrificed at increasing time intervals (hours or days) after reperfusion. Each column corresponds to the mean number of NCAM immunoreactive fusiform cells (\pm SD) after examination of cortex and outer medulla (OSOM, ISOM) for each experimental group ($n = 4$) (* $P < .05$; ** $P < .01$ versus control).

Concomitantly with the distribution of vimentin-positive interstitial cells, other markers such as nestin and NCAM were detected in fusiform cells of the peritubular interstitium. In control kidneys, nestin-positive cells were scattered among tubules and formed a loose network of fusiform interstitial cells in renal cortex and medulla (Figure 5(b)). One day after ischemia, the density of nestin immunoreactive cells rose abruptly both in OSOM and ISOM to reach the highest values 2 days after reperfusion that is 550 and 1100 cells/mm², respectively (Figures 4; 5(d), and 5(h)). Three days after ischemia, the number of nestin-expressing cells fell rapidly to reach control values (Figure 4) while vimentin declined more slowly and remained expressed in interstitial cells of outer medulla after 14 days (see Figure 3).

However, after 2 weeks, clusters of nestin-positive interstitial cells persisted focally around cystic tubules (Figure 5(f)). Exceptionally, positive tubular cells were also disclosed in altered tubules (Figure 5(d) inset). At one or two days after reperfusion, double label immunofluorescence for nestin and vimentin revealed that these two markers are coexpressed by a majority of fusiform interstitial cells (Figure 8(a)).

In control kidneys, tubular cells were never positive for anti-NCAM antibody (Figure 7(a)) although sixteen hours after ischemia, some isolated epithelial cells appeared positive in altered tubules of OSOM (Figure 7(c) inset). However, this pattern appeared transitory since NCAM-positive cells disappeared totally from tubular epithelium 48 hours after reperfusion. In kidneys from control rats, NCAM-positive interstitial cells formed a loose network around tubules but their density was higher in ISOM than in cortex and OSOM

(Figures 6, 7(a), and 7(e)). The density of positive cells in OSOM increased 16 hours after reperfusion mainly in the vicinity of altered tubules (Figures 6 and 7(c)). Three days after ischemia, the density of NCAM-positive cells appeared similar to controls. Within ISOM, positive cells were restricted to the peritubular interstitium (Figure 7(e)) where their density increased significantly 12 hours after ischemia to remain high during the two following weeks (Figure 7(g)).

In control kidneys, the immunolabeling with an anti- α -SMA antibody was limited to the media of arteriolar vessels (Figure 7(b)) and to the cytoplasm of pericytes of the ascending vasa recta in the vascular bundles of ISOM (Figure 7(f)). In the interstitial compartment, the expression α -SMA was never observed in controls and poorly expressed in ischemic kidneys during the two weeks following reperfusion. However, at long term, small clusters of interstitial α -SMA-positive cells were disclosed focally in the vicinity of necrotic or cystic tubules (Figure 7(d)). Double label immunofluorescence for α -SMA and nestin revealed that these two markers were coexpressed only by fusiform interstitial cells surrounding cystic tubules (Figure 8(c)). This local expression of α -SMA thus suggests the presence of myofibroblasts and the beginning of focal processes of tubulointerstitial fibrosis.

4. Discussion

In a previous study [8], we demonstrated the presence of extrarenal cells in rat kidney after ischemic injury and suggested that these immature cells could be able to migrate from the blood to injured tubules where they actively proliferate to finally differentiate into mature epithelial cells. We showed that these cells coexpressed CD44 and vimentin. In the extracellular matrix of OSOM we observed concomitantly a transitory increase of hyaluronan suggesting that this molecule could play a pivotal role during the transit of CD44-positive cells through the interstitial compartment [19].

In the present study, we have extended our initial observations by an immunohistochemical characterization of fusiform shaped cells of renal interstitium. Indeed, in this compartment we detected two different cell categories: migrating round cells already described in a previous work [8] and fusiform-shaped cells that remained to be characterized. In this context, we used various markers such as vimentin, NCAM, nestin or α -SMA known to be expressed in kidney interstitium during episodes of renal regeneration.

The analysis of S-phase cells (BrdU 1 hour before sacrifice) revealed that the density of S-phase fusiform cells rose transiently (from 20 hours to 2 days) in outer medulla to resume the appearance of controls 3 days after reperfusion. During this short period of time, it is worth noting that this analysis only revealed dividing fusiform interstitial cells confirming that extrarenal round stem cells involved in tubular regeneration remain quiescent during their migration through interstitium. It is interesting to note that these round cells became PCNA positive only after implantation within altered proximal tubules (see Figure 2(c)). Altogether

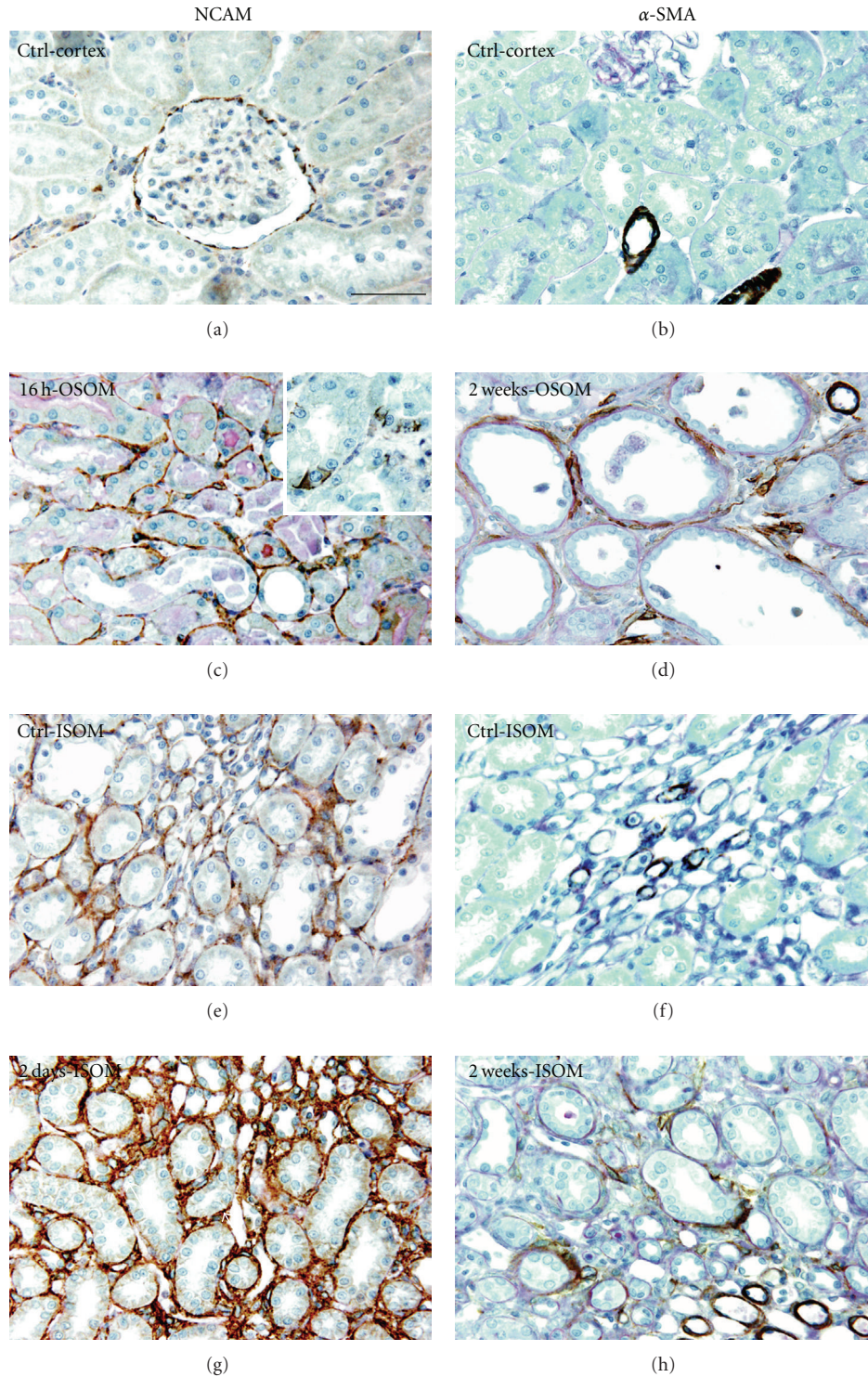


FIGURE 7: Distribution of NCAM-positive cells (left column) and of α -SMA-positive cells (right column) in the renal interstitium of control (a, b, e, f) or at different time intervals after ischemia-reperfusion (c, d, g, h). In control, NCAM-positive interstitial cells formed a loose network around cortical tubules (a) but with a higher density in ISOM (e). The density of positive cells in OSOM increased 16 hours after reperfusion mainly in the vicinity of altered tubules (c). Sometimes isolated epithelial cells appeared positive in altered tubules of OSOM (c inset). Within ISOM, the density of positive cells increased 12 hours after ischemia and remains high during the two following weeks (g). In control kidneys, the immunolabeling with an anti- α -SMA antibody was limited to the media of arteriolar vessels (b) and to pericytes of the ascending vasa recta in the vascular bundles of ISOM (f). Two weeks after reperfusion, α -SMA immunoreactivity is present in flattened cells surrounding precystic tubules (d) while ISOM remained similar to controls (h). Scale bar. 30 μ m: (a–h).

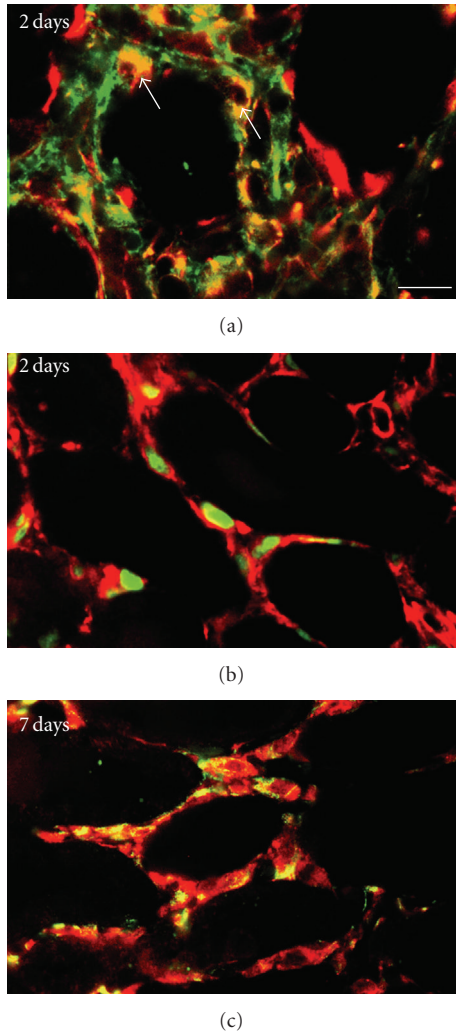


FIGURE 8: (a) Double label immunofluorescence for nestin (green) and vimentin (red) in an ischemic kidney two days after reperfusion. Interstitial cells coexpressing both markers appear yellow (arrows). (b) Double immunostaining for vimentin (red) and PCNA nuclei (green) two days after reperfusion. PCNA-positive nuclei were observed in interstitial fusiform vimentin-positive cells. (c) Double label immunofluorescence for α -SMA (red) and nestin (green) in ischemic kidney one week after reperfusion. Most of interstitial cells surrounding cystic tubules coexpressed both markers (yellow). Scale bar. 18 μ m: (a, b, c).

these data suggest that we have disclosed two different cell populations within outer medulla: a population of migrating cells only involved in tubular regeneration and a population of resident fusiform cells confined to the interstitial compartment.

The density of nestin-positive cells follows a time course similar to the pattern of cell proliferation, the highest densities of positive cells being observed at day 2 just before a rapid return to control values. Expression of nestin was thus transiently increased during the phase of interstitial repopulation, a transient expression already observed in a model of mesangial cell injury in the rat kidney [20]. Using this model, it was demonstrated that during the cell cycle,

high nestin levels were associated to S- and G₂-phase and that the blocking of nestin using specific siRNA resulted in inhibition of cell proliferation. Altogether, these observations suggest a supporting role for nestin during cell proliferation associated to repair reactions [20, 21].

As for nestin, the distribution of NCAM-positive interstitial cells follows a time course grossly similar to the pattern of cell proliferation although of lower densities within OSOM. NCAM is widely expressed in the central nervous system yet it is also expressed in nonneural tissues in which previous studies have demonstrated interplay between NCAM and fibroblast growth factor receptor (FGFR). These findings suggest that NCAM is a regulator of FGF-FGFR interaction and that NCAM expression could reduce FGF-induced proliferation of fibroblasts [22, 23]. In the kidney, the interaction NCAM-FGFR could thus be a regulating mechanism of fibrogenesis since bFGF is one of the main factors contributing to fibroblast proliferation [24]. In our study, these data could suggest that the expression of NCAM leads to a limited development of fibrosis, at least around regenerating S3 tubules.

In ISOM the density of cells expressing nestin, NCAM and vimentin appeared higher than in OSOM but always in the absence of tubular necrosis. This could be considered as a consequence of ischemia-induced hypoxia [25] since hypoxia can trigger the expression of various genes through increased expression of hypoxia-inducible transcription factors (HIF) both in tubular and interstitial cells [26]. As for OSOM, the important expression of NCAM could also be a limiting factor of fibrosis in this interstitial compartment.

Nestin was never observed in differentiated tubules [8, 15] but could be expressed focally by immature tubular epithelial cells [27]. Moreover tubular nestin expression is concomitant with interstitial nestin expression and all nestin-positive tubular cells costained with vimentin, a mesenchymal marker [28]. Similarly, NCAM-positive cells were also disclosed in altered tubules of OSOM an observation which is consistent with previously published observations [3, 16, 29]. Altogether these observations suggest that the nestin-, NCAM-positive tubular cells could be close to a mesenchymal phenotype. It is tempting to speculate that these cells could be involved in the process of epithelial-mesenchymal transition (EMT) leading to the accumulation of myofibroblasts within interstitium [30, 31]. In our study, such an accumulation of myofibroblasts was only observed in focal area of chronic injury. Again the coexpression of markers such vimentin, α -SMA, NCAM, and nestin suggest that these cells could be a subset of mesenchymal stem cells [32]. Interestingly, not all α -SMA-positive cells appeared positive for nestin suggesting the coexistence of two populations of myofibroblasts [27, 28]. In contrast, our observations rather suggest the existence of a single population of myofibroblasts in which nestin and NCAM, are expressed transiently.

The enhancement of peripheral blood stem cells availability by stimulating factors does not alter the course of renal fibrosis [33]. This is consistent with our previous observations suggesting that extrarenal stem cells contribute only to tubular regeneration [8] while fusiform interstitial

cells seem not involved in this process. However we cannot exclude a participation of these fusiform cells to the synthesis and deposition of matrix components such as hyaluronan which seems to be involved in the migration of extrarenal cells across the interstitial compartment [8, 19].

To conclude, our observations suggest that interstitial fusiform cells of the outer medulla, in response to ischemia, exhibited transient phenotypical changes and seem to evolve independently of tubular regeneration. However, at long-term after ischemia, the expression of nestin, vimentin, and NCAM was consistently observed in interstitial cells localized in the vicinity of chronically altered S3 tubules, a distribution that could eventually lead to fibrosis in these ill-repaired areas.

Acknowledgments

David Vanstherthem and Annabel Gossiaux are the recipients of a fellowship from the FRIA. The expert technical assistance of F. Coulon, A. Musieaux-Maes, and J. Noel was greatly appreciated.

References

- [1] Q. Al-Awqati and J. A. Oliver, "Stem cells in the kidney," *Kidney International*, vol. 61, no. 2, pp. 387–395, 2002.
- [2] B. D. Humphreys, J. D. Duffield, and J. V. Bonventre, "Renal stem cells in recovery from acute kidney injury," *Minerva Urologica e Nefrologica*, vol. 58, no. 4, pp. 329–337, 2006.
- [3] J. V. Bonventre, "Dedifferentiation and proliferation of surviving epithelial cells in acute renal failure," *Journal of the American Society of Nephrology*, vol. 14, no. 1, pp. S55–S61, 2003.
- [4] F. Lin, K. Cordes, L. Li, et al., "Hematopoietic stem cells contribute to the regeneration of renal tubules after renal ischemia-reperfusion injury in mice," *Journal of the American Society of Nephrology*, vol. 14, no. 5, pp. 1188–1199, 2003.
- [5] D. Krause and L. G. Cantley, "Bone marrow plasticity revisited: protection or differentiation in the kidney tubule?" *Journal of Clinical Investigation*, vol. 115, no. 7, pp. 1705–1708, 2005.
- [6] L. Li, P. Truong, P. Igarashi, and F. Lin, "Renal and bone marrow cells fuse after renal ischemic injury," *Journal of the American Society of Nephrology*, vol. 18, no. 12, pp. 3067–3077, 2007.
- [7] R. Poulosom, M. R. Alison, T. Cook, et al., "Bone marrow stem cells contribute to healing of the kidney," *Journal of the American Society of Nephrology*, vol. 14, supplement 1, pp. S48–S54, 2003.
- [8] D. Vanstherthem, N. Caron, A.-E. Declèves, et al., "Label-retaining cells and tubular regeneration in postischemic kidney," *Nephrology Dialysis Transplantation*, vol. 23, no. 12, pp. 3786–3797, 2008.
- [9] G. J. Becker and T. D. Hewitson, "The interstitium in renal disease," *Journal of Internal Medicine*, vol. 242, no. 2, pp. 93–97, 1997.
- [10] B. Kaissling, I. Hegyi, J. Loffing, and M. Le Hir, "Morphology of interstitial cells in the healthy kidney," *Anatomy and Embryology*, vol. 193, no. 4, pp. 303–318, 1996.
- [11] G. Toubeau, D. Nonclercq, J. Zanen, G. Laurent, P. Schaudies, and J. A. Heuson-Stiennon, "Renal tissue expression of epidermal growth factor receptor after ischemic tubular injury: an immunohistochemical study," *Experimental Nephrology*, vol. 2, no. 4, pp. 229–239, 1994.
- [12] R. Witzgall, D. Brown, C. Schwarz, and J. V. Bonventre, "Localization of proliferating cell nuclear antigen, vimentin, c-Fos, and clusterin in the postischemic kidney. Evidence for a heterogeneous genetic response among nephron segments, and a large pool of mitotically active and dedifferentiated cells," *Journal of Clinical Investigation*, vol. 93, no. 5, pp. 2175–2188, 1994.
- [13] Y.-H. Chou, S. Khuon, H. Herrmann, and R. D. Goldman, "Nestin promotes the phosphorylation-dependent disassembly of vimentin intermediate filaments during mitosis," *Molecular Biology of the Cell*, vol. 14, no. 4, pp. 1468–1478, 2003.
- [14] C. Wiese, A. Rolletschek, G. Kania, et al., "Nestin expression—a property of multi-lineage progenitor cells?" *Cellular and Molecular Life Sciences*, vol. 61, no. 19–20, pp. 2510–2522, 2004.
- [15] J. Chen, S. Boyle, M. Zhao, et al., "Differential expression of the intermediate filament protein nestin during renal development and its localization in adult podocytes," *Journal of the American Society of Nephrology*, vol. 17, no. 5, pp. 1283–1291, 2006.
- [16] M. Abbate, D. Brown, and J. V. Bonventre, "Expression of NCAM recapitulates tubulogenic development in kidneys recovering from acute ischemia," *American Journal of Physiology*, vol. 277, no. 3, pp. F454–F463, 1999.
- [17] R. P. Schaudies, D. Nonclercq, L. Nelson, et al., "Endogenous EGF as a potential renoprotective factor in ischemia-induced acute renal failure," *American Journal of Physiology*, vol. 265, no. 3, pp. F425–F434, 1993.
- [18] D. Nonclercq, V. Liénard, J. Zanen, G. Laurent, and G. Toubeau, "Phenotypic variations and dynamic topography of transformed cells in an experimental model of diethylstilbestrol-induced renal tumour in male Syrian hamster," *Histochemical Journal*, vol. 34, no. 10, pp. 487–497, 2002.
- [19] M. B. Herrera, B. Bussolati, S. Bruno, et al., "Exogenous mesenchymal stem cells localize to the kidney by means of CD44 following acute tubular injury," *Kidney International*, vol. 72, no. 4, pp. 430–441, 2007.
- [20] C. Daniel, H. Albrecht, A. Lüdke, and C. Hugo, "Nestin expression in repopulating mesangial cells promotes their proliferation," *Laboratory Investigation*, vol. 88, no. 4, pp. 387–397, 2008.
- [21] K. Michalczyk and M. Ziman, "Nestin structure and predicted function in cellular cytoskeletal organisation," *Histology and Histopathology*, vol. 20, no. 2, pp. 665–671, 2005.
- [22] C. Francavilla, S. Loeffler, D. Piccini, A. Kren, G. Christofori, and U. Cavallaro, "Neural cell adhesion molecule regulates the cellular response to fibroblast growth factor," *Journal of Cell Science*, vol. 120, no. 24, pp. 4388–4394, 2007.
- [23] N. Turner and R. Grose, "Fibroblast growth factor signalling: from development to cancer," *Nature Reviews Cancer*, vol. 10, no. 2, pp. 116–129, 2010.
- [24] F. Strutz and M. Zeisberg, "Renal fibroblasts and myofibroblasts in chronic kidney disease," *Journal of the American Society of Nephrology*, vol. 17, no. 11, pp. 2992–2998, 2006.
- [25] M. Brezis and S. Rosen, "Hypoxia of the renal medulla—its implications for disease," *The New England Journal of Medicine*, vol. 332, no. 10, pp. 647–655, 1995.
- [26] K.-U. Eckardt, C. Rosenberger, J. S. Jürgensen, and M. S. Wiesener, "Role of hypoxia in the pathogenesis of renal disease," *Blood Purification*, vol. 21, no. 3, pp. 253–257, 2003.
- [27] T. Sakairi, K. Hiromura, S. Yamashita, et al., "Nestin expression in the kidney with an obstructed ureter," *Kidney International*, vol. 72, no. 3, pp. 307–318, 2007.

- [28] J.-L. Bascands, J. Klein, and J. P. Schanstra, "A nest in renal fibrosis?" *Kidney International*, vol. 72, no. 3, pp. 242–244, 2007.
- [29] S. Villanueva, C. Céspedes, and C. P. Vio, "Ischemic acute renal failure induces the expression of a wide range of nephrogenic proteins," *American Journal of Physiology*, vol. 290, no. 4, pp. R861–R870, 2006.
- [30] T. A. Wynn, "Cellular and molecular mechanisms of fibrosis," *Journal of Pathology*, vol. 214, no. 2, pp. 199–210, 2008.
- [31] M. Guarino, A. Tosoni, and M. Nebuloni, "Direct contribution of epithelium to organ fibrosis: epithelial-mesenchymal transition," *Human Pathology*, vol. 40, no. 10, pp. 1365–1376, 2009.
- [32] V. Paunescu, F. M. Bojin, C. A. Tatu, et al., "Tumor-associated fibroblasts 4 and mesenchymal stem cells: more similarities than differences," *Journal of Cellular and Molecular Medicine*. In press.
- [33] G. Stokman, J. C. Leemans, I. Stroo, et al., "Enhanced mobilization of bone marrow cells does not ameliorate renal fibrosis," *Nephrology Dialysis Transplantation*, vol. 23, no. 2, pp. 483–491, 2008.