

Dealing with technical challenges in embolization of a rare aberrant left inferior bronchial artery arising from the left gastric artery in a patient with massive hemoptysis

Gaurav Gangwani, Ajit Yadav, Amit Dhamija¹, Arun Gupta

Departments of Interventional Radiology and ¹Chest Medicine, Sir Ganga Ram Hospital, New Delhi, India

Correspondence: Dr. Arun Gupta, Department of Interventional Radiology, Sir Ganga Ram Hospital, Rajinder Nagar, New Delhi - 110 060, India. E-mail: irdrarungupta@gmail.com

Abstract

Bronchial artery embolization is an established intervention for management of recurrent massive hemoptysis in a majority of patients. The source of bleeding in a majority of cases is systemic arteries – orthotopic bronchial arteries, anomalous bronchial arteries, or nonbronchial systemic collaterals. We report a case of an aberrant left inferior bronchial artery arising from the left gastric artery (LGA) in a patient with massive hemoptysis. Such origin from infradiaphragmatic vessels and specially left gastric arteries is very rare and needs to be considered by interventional radiologists and pulmonologists in case with hemoptysis disproportionate to supply by orthotopic arteries. Technical challenges were present in the present case in the form of an aneurysm in the aberrant artery and nontarget hepatic and gastric branches arising from LGA. Appropriate selection of hardware and embolic agents was done to deal with the clinical situation.

Key words: Aberrant bronchial artery; bronchial artery embolization; left gastric artery; massive hemoptysis; nonbronchial systemic collaterals

Introduction

Bronchial artery embolization (BAE) is an established intervention for management of recurrent massive hemoptysis in a majority of patients. The source of bleeder vessels is usually classified as orthotopic bronchial arteries (arising from the descending thoracic aorta at T5–T6 vertebral levels), anomalous bronchial arteries (aberrant arteries with normal course along pulmonary hila), and

nonbronchial systemic arteries (aberrant arteries with transpleural non-hilar course).^[1] We report our experience of embolization of a rare aberrant left inferior bronchial artery arising from the left gastric artery (LGA) in a patient with massive hemoptysis with an aneurysm in the parent aberrant vessel. The clinical situation was dealt with choice of appropriate hardware and embolic agents.

This is an open access journal, and articles are distributed under the terms of the Creative Commons Attribution-NonCommercial-ShareAlike 4.0 License, which allows others to remix, tweak, and build upon the work non-commercially, as long as appropriate credit is given and the new creations are licensed under the identical terms.

For reprints contact: reprints@medknow.com

Cite this article as: Gangwani G, Yadav A, Dhamija A, Gupta A. Dealing with technical challenges in embolization of a rare aberrant left inferior bronchial artery arising from the left gastric artery in a patient with massive hemoptysis. *Indian J Radiol Imaging* 2018;28:476-9.

Access this article online

Quick Response Code:



Website:
www.ijri.org

DOI:
10.4103/ijri.IJRI_162_18

Case Report

Exemption was obtained from the institutional review board for publishing the case report. An 81-year-old man was admitted to our hospital for control of hemoptysis. He had recurrent bouts of streaky to mild hemoptysis for the past 5 years with bilateral fibrobronchiectasis in the basal segments of bilateral lower lobes (left > right) as suggested by a previous computed tomography (CT). Fifteen days before admission, the patient had cough and two bouts of massive hemoptysis (>300 mL/day). Even after admission, he experienced massive hemoptysis (450 mL) despite administration of intravenous vasopressin and tranexamic acid. Emergency BAE was planned without any additional imaging work-up or video bronchoscopy.

After securing right common femoral artery access, a large intercostobronchial trunk was catheterized using a 5-Fr C2 cobra catheter (Cook Medical, Bloomington, IN, USA), and selective angiogram revealed a common bronchial trunk supplying mid and lower zones of bilateral lung fields [Figure 1A]. Superselective embolization of the common trunk was performed using polyvinyl alcohol (PVA) particles (diameter, 500–710 μm ; PVA-500; Cook Medical) with a 2.7-Fr progreat microcatheter (Terumo Corporation, Tokyo, Japan) [Figure 1B]. After attempt at selective cannulation of other orthotopic bronchial arteries, thoracic aortogram was performed with a 5-Fr pigtail catheter of six side ports (Boston Scientific, Galway, Ireland) which revealed an aberrant left inferior bronchial artery originating from a mediastinal branch extending from infradiaphragmatic region [Figure 1C]. Selective celiac angiogram using the 5-Fr C2 cobra catheter confirmed aberrant bronchial supply from the tortuous LGA with the left gastric branch and an accessory left hepatic artery branch arising from the proximal trunk of the LGA [Figure 2A]. Superselective angiogram of the aberrant branch revealed hypervascularity [Figure 2B and 2C] and shunting [Figure 2B] in the left lower pulmonary zone

and a small fusiform aneurysm arising from the distal trunk of the LGA [Figure 2B]. Due to tortuosity of the LGA, the progreat microcatheter was not able to pass beyond the nontarget branches, and thus, the parent C2 catheter was replaced by a Simmond 1 catheter (Cook Medical) for deeper LGA cannulation and providing stability. This enabled the microcatheter to be positioned well beyond the ostium of the nontarget branches. Initial embolization was performed with PVA particles (diameter, 300–500 μm ; PVA-300; Cook Medical) and gel foam to reduce distal hypervascularity [Figure 3A] and shunting followed by injection of 3 mL of 10% glue [0.3 mL of n-butyl cyano-acrylate (Samarth Life Science Pvt. Ltd., Himachal Pradesh, India) and 2.7 mL of lipiodol (Guerbet, Cedex, France)] [Figure 3B]. Postembolization angiogram revealed occlusion of the distal aberrant artery and aneurysm [Figure 3C]. Cone beam CT confirmed the radio-opaque glue cast in the aberrant bronchial artery lumen [Figure 3D].

Nonbronchial systemic supply to the left middle and lower zones from the left internal mammary artery was also superselectively embolized in similar fashion. The procedure resulted in complete control of hemoptysis with no recurrence at 1-month follow-up.

Discussion

The origin of the bronchial arteries is variable, with approximately 70% arising from the descending aorta between T5 and T6 vertebrae.^[2] The bronchial arteries that arise outside the level of T5 and T6 vertebrae but run along the course of major bronchi are termed anomalous/ectopic. The reported prevalence of anomalous bronchial arteries ranges from 8.3% to 35%.^[3,4] These may originate from various systemic arteries including aorta.^[3,5] In contrast, nonbronchial collateral (NBC) arteries enter the pulmonary parenchyma through adherent pleura or through the pulmonary ligament, and their course is not parallel to that of the bronchi.^[1]

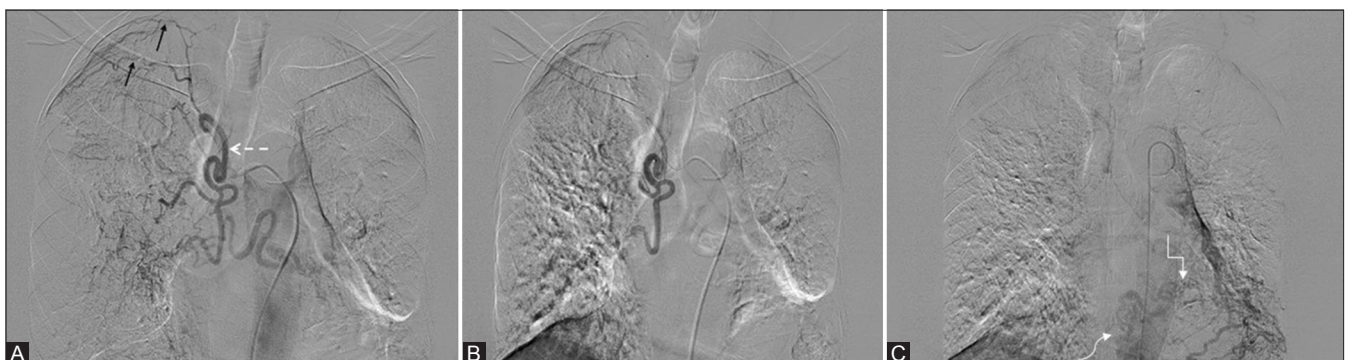

Figure 1 (A-C): (A) Selective angiogram of right intercostobronchial trunk reveals intercostal arteries (solid arrows – right second and third intercostal spaces) and a large common bronchial trunk (broken arrow). (B) Postembolization superselective angiogram of the common bronchial trunk revealed significant stasis of contrast material in the proximal lumen of bilateral bronchial arteries with no residual hypervascularity in bilateral lower zones. (C) Delayed phase in thoracic aortogram revealed a suspicious tortuous aberrant left inferior bronchial branch (square arrow) extending from infradiaphragmatic location (curved arrow) into mediastinum and then left lower zone

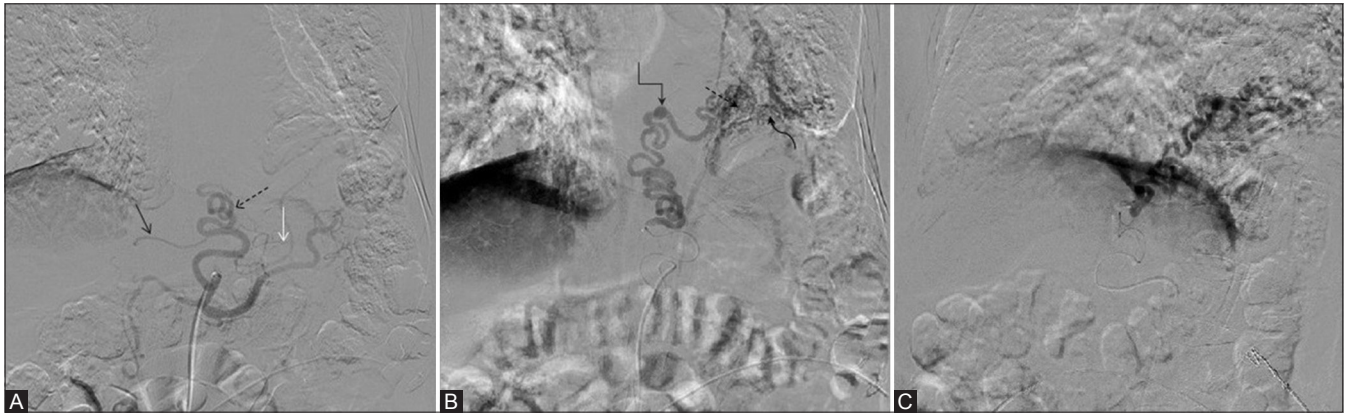


Figure 2 (A-C): (A) Selective celiac angiogram revealed tortuous left gastric artery with accessory left hepatic artery (black arrow), small gastric artery (white arrow), and proximal hypertrophied mediastinal branch (dashed arrow). (B) Superselective angiogram of the aberrant hypertrophied superior branch of left gastric artery revealed tortuous course with a focal fusiform aneurysm (square arrow) from its lumen and aberrant hypervascular bronchial supply (curved arrow) to left lower zone with systemic-pulmonary shunting (dashed arrow). (C) Superselective angiogram of the aberrant left inferior bronchial artery in lateral projection confirming the posterior mediastinal course of the vessel likely para-esophageal

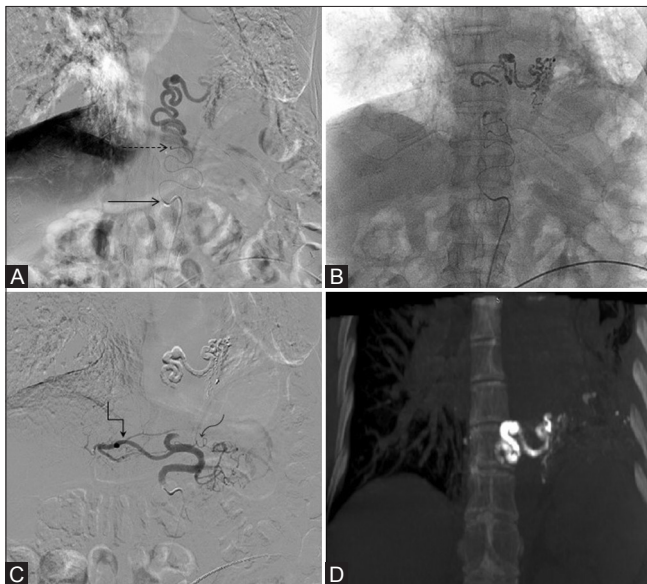


Figure 3 (A-D): (A) Postembolization superselective angiogram of the aberrant left bronchial artery revealed significant reduction in hypervascularity and shunting and mild stasis in the vessel lumen. Note is made of diagnostic 5-Fr Sim1 catheter (straight arrow) deep in the left gastric artery lumen with well-positioned microcatheter tip (dashed arrow) beyond the nontarget hepatic and gastric branches. (B) Superselective 10% glue injection into the aberrant artery. (C) Selective left gastric angiogram revealed stasis with lumen of the aberrant hypertrophied artery with normal opacification of accessory left hepatic (square arrow) and gastric (curved arrow) branches. Note is made of glue cast within the distal aberrant left bronchial artery. (D) Coronal reformatted maximal intensity projection image revealed radio-opaque glue cast within the distal lumen of aberrant bronchial artery, the aneurysm arising from it, and the distal intrapulmonary branches

Previous studies have well documented the potential for left gastric, splenic, and retroperitoneal arteries to contribute to NBC supply^[2,6] predominantly in the context of basal disease. The occurrence of such infradiaphragmatic supply from LGA is very rare. To the best of our literature search, we found only three reports of aberrant bronchial arteries arising from LGA.

The first report of such aberrant supply was by Sellars *et al.* in 2001^[7] where the authors documented two cases of aberrant bronchial arteries arising from LGA and concluded that infradiaphragmatic aberrant bronchial supply can extend into the entire pulmonary parenchyma and is not limited to basal segments. In *et al.*^[8] published another report of an aberrant bronchial artery arising from LGA and supplying left lower lobe. Jiang *et al.*^[9] published a case report establishing an anastomotic network between esophageal and left gastric arteries and aberrant bronchial supply through them. This kind of esophagogastric anastomosis was also established in previous reports.^[10] The collateral anastomosis between left bronchial artery and inferior esophageal artery (a branch of LGA) is also well known, and infectious or noninfectious pulmonary pathologies can give rise to neovascularity which may explain the tortuous, dilated, aneurysmatic long vessel course in the present case. There are also case reports of bronchoesophageal fistulas resulting as a complication of BAE further stressing the need for detailed research into the esophagogastric-bronchial anastomosis.^[11-13]

Our case was different from the previous cases of similar aberrant bronchial arterial origin from LGA because of the presence of aneurysm from the parent aberrant vessel which led to few technical challenges. One of them was the tortuous course of the LGA and need to position to avoid embolization of nontarget branches. This was achieved by apparent change in hardware. The biggest challenge was to inject particulate embolic agents in such a manner to achieve distal embolization, obliterate hypervascularity and shunting, and not cause significant stasis in the parent vessel stump. This was needed so that the subsequent glue injection could reach the aneurysm lumen and distal to it without polymerizing prematurely in the proximal lumen. For the same purpose, only 10% glue concentration was used.

Conclusion

Infradiaphragmatic NBC supply must be kept in mind while performing thoracoabdominal angiograms for massive hemoptysis if preprocedure CT angiography is not available, especially but not exclusively for basal lung pathology. The choice of hardware and combination of embolic materials should be made judiciously depending on the clinical scenario.

Financial support and sponsorship

Nil.

Conflicts of interest

There are no conflicts of interest.

References

1. Yoon W, Kim JK, Kim YH, Chung TW, Kang HK. Bronchial and nonbronchial systemic artery embolization for life-threatening hemoptysis: A comprehensive review. *Radiographics* 2002;22:1395-409.
2. Marshall TJ, Jackson JE. Vascular intervention in the thorax: Bronchial artery embolization for haemoptysis. *Eur Radiol* 1997;7:1221-7.
3. Sancho C, Escalante E, Domínguez J, Vidal J, Lopez E, Valdeperas J, *et al.* Embolization of bronchial arteries of anomalous origin. *Cardiovasc Intervent Radiol* 1998;21:300-4.
4. Cohen AM, Doershuk CF, Stern RC. Bronchial artery embolization to control hemoptysis in cystic fibrosis. *Radiology* 1990;175:401-5.
5. McPherson S, Routh WD, Nath H, Keller FS. Anomalous origin of bronchial arteries: Potential pitfall of embolotherapy for hemoptysis. *J Vasc Interv Radiol* 1990;1:86-8.
6. Webb WR, Jacobs RP. Transpleural abdominal systemic artery-pulmonary artery anastomosis in patients with chronic pulmonary infection. *AJR Am J Roentgenol* 1977;129:233-6.
7. Sellars N, Belli AM. Non-bronchial collateral supply from the left gastric artery in massive haemoptysis. *Eur Radiol* 2001;11:76-9.
8. In HS, Bae JI, Park AW, Kim YW, Choi SJ. Bronchial artery arising from the left gastric artery in a patient with massive haemoptysis. *Br J Radiol* 2006;79:e171-3.
9. Jiang S, Sun XW, Yu D, Jie B. Aberrant left inferior bronchial artery originating from the left gastric artery in a patient with acute massive hemoptysis. *Cardiovasc Intervent Radiol* 2013;36:1420-3.
10. Shapiro AL, Robillard GL. The esophageal arteries their configurational anatomy and variations in relation to surgery. *Ann Surg* 1950;131:171-85.
11. Hélénon CH, Chatel A, Bigot JM, Brocard H. Left esophago-bronchial fistula following bronchial artery embolization. *Nouv Presse Med* 1977;6:4209.
12. Hsu HK, Su JM. Giant bronchoesophageal fistula: A rare complication of bronchial artery embolization. *Ann Thorac Surg* 1995;60:1797-8.
13. Munk PL, Morris DC, Nelems B. Left main bronchial-esophageal fistula: A complication of bronchial artery embolization. *Cardiovasc Intervent Radiol* 1990;13:95-7.