



Clinical Research

Low resource screening method of pre-cancerous lesions and its reversal by *Triphala* in teen-age Indian population

Anshula Deshpande, Shobha Tandon¹, Neeraj Deshpande²

Departments of Pedodontics, K. M. Shah Dental College, Sumandeep Vidyapeeth, Vadodara, Gujarat,

¹Department of Pedodontics, Babu Banarasi Das College of Dental Sciences, BBD University, Lucknow, Uttar

Pradesh, ²Periodontics, K. M. Shah Dental College, Sumandeep Vidyapeeth, Vadodara, Gujarat, India

Abstract

Background: Cancer screening is the main weapon for early detection at a pre-invasive or premalignant stage. It has been reported that over 12 million people use some form of tobacco, which is one of the high risk factors and has hence become an alarming world-wide problem. **Aim:** To evaluate the effective diagnostic screening of disease in its early stage by inexpensive method and also to evaluate the effect of indigenous mouthrinse on reversal of pre-cancerous lesions. **Materials and Methods:** The screening for teenagers belonging to low socio-economic status was carried out. Suspected subjects were evaluated for the reversal of the lesions by use of Ayurvedic preparation as a mouthwash. From 13 to 19 years working-child population of North India was selected for the study. Screening was performed by new method-visual inspection with acetic acid. The positive subjects were further investigated by pap smear and biopsy was done as a confirmatory histopathological report. In second phase, the subjects showing positive lesions were advised indigenous anti-cancer mouth rinse and its effect was evaluated after 6 month and 9 month of prescribing the rinse. **Results:** The total 1095 children were screened (831 boys and 264 girls). Out of total 34 teenager boys were diagnosed, as acetowhite positive lesion. All the acetowhite positive lesions were found exclusively in males. Histological findings after 9 month use of *Triphala* mouth rinse revealed no changes in cells in 23 (85.2%), hyperkeratinization in 2 (7.4%), hyperkeratinization and spongiosis was evident in 1 (3.7%), mild pleomorphism in 1 (3.7%) patient. Comparative evaluation from 0-9 month showed statistically highly significant test ($P < 0.01$). **Conclusion:** Use of different forms of tobacco and betel nut showed convincing relationship between developments of oral pre-cancerous lesions. *Triphala* was found to have great potential for reversal of these lesions.

Key words: Alcohol, oral pre-cancerous lesions, screening, tobacco, *Triphala* and teenagers

Introduction

Oral cancer today is the fifth most common cancer seen in the human body. Ironically it is found in the most easily accessible part, which can be detected on the expense of least possible resources. It has been reported that over 12 million people use some form of tobacco, which is one of the high risk factors and has hence become an alarming world-wide problem.

Oral cancer is major problem in India and accounts for 50-70% of all cancers diagnosed when compared to 2-3% in UK and USA.^[1] More than 80% of cancer patients in developing

countries are diagnosed at an advanced stage and do not have access to early detection or screening for early-stage cancer. Keeping this in view India needs a safe, easy to perform and inexpensive screening method, which medical and dental health professionals can apply efficiently and giving results immediately by using equipment's which are available easily.

Over the last decade, there has been largest increase in the age-group of 8-17 years old in the consumption of tobacco in different forms especially smokeless tobacco.^[2] This is an alarming sign for the health professionals and especially the dental surgeons, as the oral cancer can be, easily examined. The early detection and prompt treatment could be provided at the stage of pre-cancerous lesions, which can be one of the corner stone of cancer prevention.

There are different treatment modalities of cancer but the alternative method with herbs and diets is practically ignored.

Address for correspondence: Dr. Anshula Deshpande,
Department of Pedodontics, K. M. Shah Dental College,
Sumandeep Vidyapeeth, Vadodara - 391 760, Gujarat, India.
E-mail: dranshula@rediffmail.com

In our economic system, if there is no profit motive, a serious focus on prevention would wreck havoc on the present economic status quo and further, there is no incentive for a highly vested pharmaceutical company to conduct research on herbs or other low-tech cancer treatments like herbal medicine.^[3] *Triphala* is the most popular Ayurvedic herbal formula of India, since it is an effective laxative, which also supports the body's strength, due to its high nutritional value. *Triphala* uniquely cleanses and detoxifies at the deepest organic levels without depleting the body's reserves. *Triphala* consists of equal quantities of *Haritaki* (*Terminilia chebula* Retz.), *Amalaki* (*Embllica officinalis* Gaertn.) and *Bibhitaki* (*Terminilia bellerica* Roxb.). All three fruits have proven to be antioxidant.^[4] The cytotoxic effects of aqueous extract of *Triphala*, were investigated on human breast cancer cell line (MCF-7) and a transplantable mouse thymic lymphoma (barcl-95).^[5] These results were suggested that, *Triphala* possessed ability to induce cytotoxicity in tumor cells but spared the normal cells. The differential effect of triphala on normal and tumor cells seems to be related to its ability to evoke differential response in intracellular reactive oxygen species generation.^[6] Toxicity study done showed that triphala was non-toxic up to a dose of 240 mg/kg, where no drug-induced mortality was observed.^[7] These results evidently show the promise of *Triphala* as a potential chemopreventive and/or anticancer drug.^[5,6,8]

In the view of increased prevalence of oral cancer and pre-cancerous lesions with predisposition of teenagers to various habits, this study was undertaken with the following aims and objectives:

- Effective diagnostic screening by inexpensive method
- To curtail the disease in its early stage
- To evaluate the effect of indigenous mouthrinse on reversal of pre-cancerous lesions.

Materials and Methods

This study was undertaken by the Department of Pedodontics and Preventive Dentistry, Manipal College of Dental Sciences, Manipal.

Materials

In total, 1095 teenage (13-19 years) population from North India and South India was included for the study. The subjects were chosen from the government schools and slum areas of Kanpur, Uttar Pradesh, India and Polytechnic College, Manipal, Karnataka, India. An informed consent form was prepared to obtain consent from the principals of the schools, as well as, the parents of the children participating in the study. A questionnaire to gather information on their oral health status and some of the risk factors of pre-cancerous lesions and pre-cancerous conditions was formulated.

Equipment used for the study were

mouth mirror, explorer, tweezers, disinfectant for instruments, gauze pieces, acetic acid 1%, gloves, towel and soap, disposable glasses, kidney trays, torch with white light, slides and fixing agent, local anaesthetic agent (xylocaine 2%), disposable syringes and needle, biopsy instruments - punch biopsy forceps and B.P. blade no. 15. An Ayurvedic mouth rinse - *Triphala* was used as an anti-cancer mouthrinse for interventional study.

Triphala (tri-three, phala-fruits) a combination of the fruit of the Chebulic, Belleric and Emblic myrobalan trees, respectively were used in equal proportions. The *Triphala* powder was prepared by the Pharmacy Manufacturing Department, KMC, Manipal.

Methods

The sample size for the screening population was determined by power analysis, where 0.1 prevalence of cancer as reported by World Health Organization for the year 1982-1999 in teenage group, was used. Consent forms were collected.

The schools and areas comprising of low-socioeconomic group of working teenage population were selected. Most of the working children were included for the study so equal sex distribution was not possible during screening. The screening was conducted at the initial 1st month. The intervention study was terminated after 9 months with follow-up of the positive acetowhite lesions cases treated with triphala mouthrinse at 3rd, 6th and 9th month.

The study was conducted in three phases

First phase of the study

All the aspects of the study were reviewed and approved by the Institutional Ethics Committee, MAHE, Manipal, India. A questionnaire to gather information on their oral health status and some of the risk factors of pre-cancerous lesions and pre-cancerous conditions was distributed among the study group.

Second phase of the study comprised of

The initial examination was done in natural light and the examiner was blinded from the information gathered by the questionnaires and the oral health status was documented. Screening was carried out by Visual Inspection with Acetic acid (VIA). Acetic acid is used to enhance and "mark" the acetowhite change of a pre-cancerous lesion or actual cancer, an approach suitable for lowest-resource settings. The study consisted of oral rinsing of mouth with 1% acetic acid for 1 min and then screening [Figures 1 and 2].

This method of screening was based on the concept of naked-eye visual inspection (VIA) of the cervix with acetic-acid wash.^[9,10] The data collected in the questionnaires was analyzed and risk factors were correlated with the positive acetowhite cases.

The lesion recognition was based on the classification given by Scully and Porter for white lesions, based on the cause.^[11] The positive acetowhite subjects were further investigated by pap smear and punch biopsy was done as a confirmatory histopathological report. A separate informed consent, from the parents of the children participating in the interventional study was obtained. The biopsy sites were selected on the basis of the clinical appearance of the lesion and the staining acetowhite "mark" result.

The sections were stained by hematoxylin and eosin and the histological diagnosis was recorded using a descriptive code. The lesions were histologically classified.^[12] Histological diagnosis was done by two pathologists who were blinded from the type of the lesions. In the cases where the tissue analyzed presented different histologic appearances, by both the pathologists the most severe histologic diagnosis was considered.

All the subjects were counseled for cessation of harmful oral habits and reinforcement of instruction for maintenance of optimum oral hygiene was done. To ensure the stoppage of habit the subject were questioned and was cross-checked with their parent/guardians and peers.

Third phase of the study

The cases diagnosed of pre-cancerous lesion or pre-cancerous condition were advised *Triphala* mouth rinse.

The *Triphala* powder was dispensed in the containers with pre-weighed pack of 60 mg and measuring cups of 100 ml to the subjects to prepare fresh mouth rinse of 0.6% concentration. The mouthrinse was freshly prepared in lukewarm water prior to rinsing so as to avoid alcoholic content which is a known etiologic factor for lesions most of the mouthrinse have alcoholic. The children were advised not to eat or rinse for the next 30 min after mouthrinse. The subjects were examined again after 3 months, 6 months and 9 months of prescribing the rinse. The smear was taken after 6 and 9 months and biopsy was done at 9 months to evaluate the effect of *Triphala* cytologically as well as histologically.

Statistical analysis

The Statistical Packages for Social Sciences (SPSS version 10.0) was used for analysis in which the data were compared among groups using Chi-square test (or Pearson test or linear association as appropriate) for categorical variables. For all tests, $P < 0.05$ was considered to be statistically significant.

Results and Observations

The relation of “acetowhite” lesions, which were recorded during screening, was studied with risk factors associated with pre-cancerous lesions. The effect of indigenous mouthrinse on reversal of pre-cancerous lesions that were diagnosed during the screening was evaluated. A total of 1095 children with a combination of 831 boys and 264 girls were screened. Out of total 34 teenager boys were diagnosed, as acetowhite positive lesion. All the acetowhite positive lesions were found exclusively in males and none in females. Chi-square analysis indicated a very high statistically significant correlation ($P < 0.001$).

Of the total teenagers screened, 274 (25%) of teenagers were consuming tobacco, whereas 821 (75.0%) were not consuming tobacco. The results obtained showed high statistically significant relation between acetowhite positive and tobacco consumption ($P < 0.001$).

Odds Ratio for tobacco 25.11 and 95% confidence interval had lower limit of 8.76 and upper limit of 71.98. 27 (2.5%) of teenagers were consuming alcohol, whereas 1068 (97.5%) were not consuming alcohol. Only 1 of the 27 alcohol consumers showed acetowhite positive lesion. The results obtained showed no statistically significant value between acetowhite positive and alcohol consumption. The correlation was statistically significant ($P < 0.05$) to their low monthly family income. Out of 1095 screened 53 (4.8%) belonged to the family where total family members were 3, 250 (22.8%) were from family of 4 members, 405 (37.0%) were from 5 and 387 (35.3%) from more than 5. The acetowhite lesions to the number of members in the family was not statistically significant ($P > 0.05$).

Site of the lesion

Totally 34 acetowhite positive lesions were found on screening 1095 teenagers. 28 (82.4%) of it were present in buccal mucosa, 5 (14.7%) in vestibule and 1 (2.9%) in retromolar region. Of the total 34 teenagers diagnosed as acetowhite positive 29 (85.3%) were having leukoplakia, 2 (5.9%) cheek biting lesions, 2 (5.9%) had traumatic ulcer and 1 (2.9%) had oral submucous fibrosis.

Smeard lesions

The teenagers having acetowhite positive lesions were given the consent form again and 27 out of 34 subjects returned the filled consent form back and agreed to participate further for the study. The attrition in sample size was of 7 (20.6%) subjects. All 34 acetowhite positive cases were administered *Triphala* mouth rinse, whereas 27 acetowhite positive subjects whose parents gave the written consent, the laboratory investigations were done for them (cytological and histological investigations) and were subjected to statistical analysis to evaluate the effect of *Triphala* on these lesions. Baseline data - pre-rinse cytology and histology report was obtained as shown in the Tables 1 and 2, Figures 3 and 4. Comparison of 1st visit with 6 month after use of *Triphala* mouth rinse by Linear by Linear Association, Chi-square value is 0.822 and with 9 month Linear by Linear Association value is 1.731 both were found statistically insignificant ($P = 0.364$ and $P = 1.731$ respectively).

Results after administering *Triphala* mouthrinse

Out of 34 positive acetowhite teenagers found in screening were administered *Triphala* mouth rinse, the written consent was obtained from 27 of their parents or guardians who agreed for the laboratory investigations (cytological and histological investigations) and took part in the study further. These 27 patients were evaluated after 3, 6 and 9 months [Figures 5 and 6].

Post-rinse cytology report at 6 month

The cytological report at 6 months after the use of *Triphala* mouth rinse showed normal cells in 19 (70.4%) of the total 27 cases, 5 (18.5%) showed anucleate keratin (keratosis), keratosis with pyknotic nucleus was seen in 3 (11.1%) cases. Linear-by-Linear Association by Chi-square test showed no statistically significant correlation ($P > 0.05$) [Table 1].

Post-rinse cytology report at 9 month

The cytological report after 9 months use of *Triphala* mouth rinse revealing normal cells in 23 (85.2%) of the total 27 cases, 4 (14.8%) showed anucleate keratin (keratosis) [Table 1 and Figure 7].

Post-rinse histology report at 9 months

Histological findings after 9 months use of *Triphala* mouth rinse revealed no changes in cells (normal) in 23 (85.2%), hyperkeratinization in 2 (7.4%). Hyperkeratinization and spongiosis was evident in 1 (3.7%), mild pleomorphism in 1 (3.7%) [Table 2 and Figure 8].

Linear-by-Linear Association by Chi-square test showed high statistically significant correlation with value 8.098 ($P < 0.01$) [Table 2].

Discussion

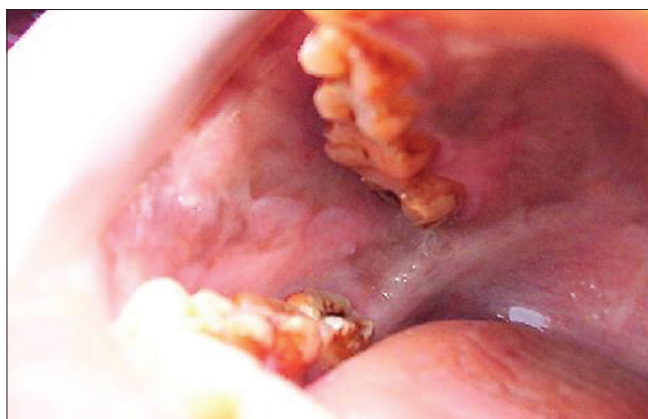
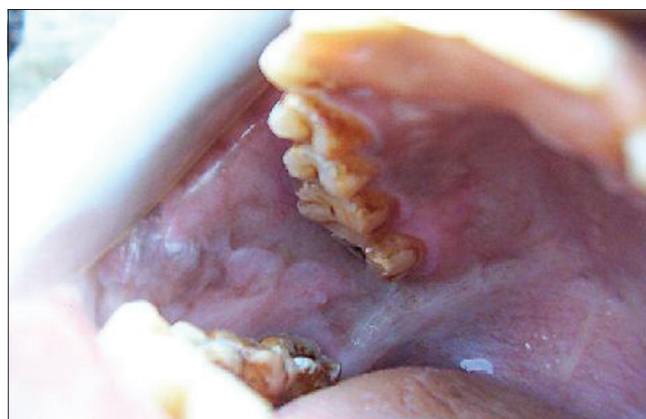
As there are very few studies done in the teenagers to assess the various risk factors causing oral pre-cancerous lesions

Table 1: Smear report at baseline and after 6 and 9 month follow-up with *Triphala* mouth rinse

Smear	Smear report at baseline		Smear report at 6 month		Smear report at 9 month	
	Frequency	Percentage	Frequency	Percentage	Frequency	Percentage
Normal	16	59.3	19	70.4	23	85.2
Abnormal						
Keratosis	6	22.2	5	18.5	4	14.8
Slight variation	3	11.1	0	0	0	0
Keratosis and pyknotic nucleus	2	7.4	3	11.1	0	0
Total abnormal out of 27	11	40.7	8	29.6	4	14.8

Table 2: Comparison of biopsy report at 1st visit and 9 month after use of *Triphala* mouth rinse

Histological findings	Biopsy report at baseline		Biopsy report at 9 month	
	Frequency	Percentage	Frequency	Percentage
Normal				
No changes in cells	1	2.9	23	85.2
Abnormal				
Hyperkeratinization	15	44.1	2	7.4
Hyperkeratinization and acanthosis	3	8.8	0	0
Hyperkeratinization and intracellular oedema	2	5.9	0	0
Hyperkeratinization and spongiosis	1	2.9	1	3.7
Hyperkeratinization, acanthosis and parakeratin plugging	1	2.9	0	0
Hyperkeratinization, acanthosis and basilar hyperplasia	1	2.9	0	0
Dyskeratosis, acanthosis and basilar hyperplasia	1	2.9	0	0
Mild pleomorphism	1	2.9	1	3.7
Fibrous bands	1	2.9	0	0
Total abnormal out of 27	26	96.2	4	14.8

**Figure 1: Before acetic acid rinse****Figure 2: Changes after acetic acid rinsing "acetowhite mark"**

the present study was undertaken in a small group of Indian teenage population. In this study, no significant association between age group and acetowhite positive lesion ($P > 0.05$) indicating lesion can occur in any age group even in the younger which may be also dependent on their socioeconomic status. One study reported that age of onset of oral cancer in India is falling and is significantly lower than reported in other countries.^[13] Similarly, another study reported the age for initiation for *Gutkha* in India as low as 8-14 years, which is a known risk factor for pre-cancerous lesions.^[14] All the acetowhite positive lesions were found exclusively in males and

none in females, in a cross-sectional study of aging Germans for oral mucosal lesions found similar sex predilection for males as compared to females^[15] [Table 2]. Of the total teenagers screened, 274 (25%) of teenagers were consuming tobacco, whereas 821 (75.0%) were not consuming tobacco. Researcher carried out survey of school children in a coastal village in the state of Kerala and showed 29% prevalence of tobacco chewing similar to the present study and in Mizoram showed a rate of 56.5%, which was slightly higher.^[14] Out of the total 1095 teenagers screened, 27 (2.5%) of teenagers were consuming alcohol. Tobacco use and alcohol consumption by young people remain serious public health problem. Another study also

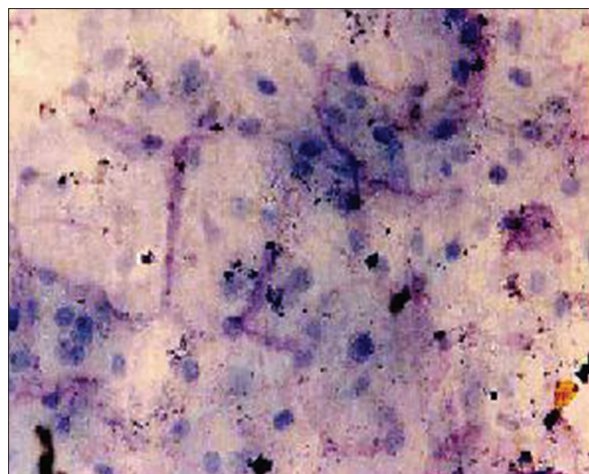


Figure 3: Smear showing variation in size and shape of nucleus

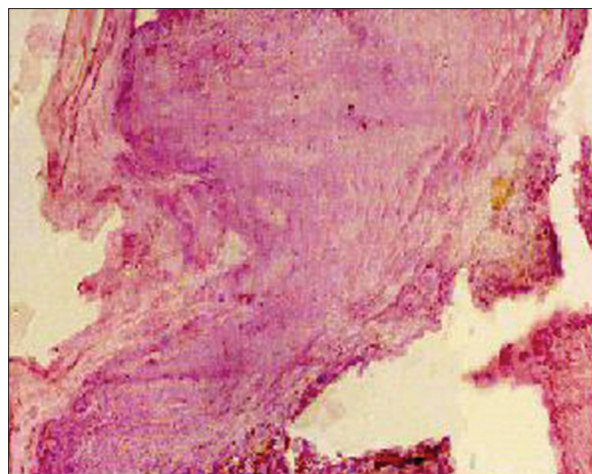


Figure 4: Biopsy showing hyperkeratinization, acanthosis and parakeratin plugging

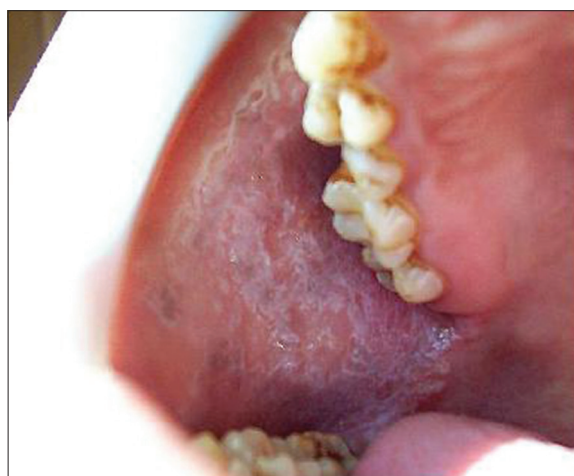

Figure 5: Before *Triphala* rinsing

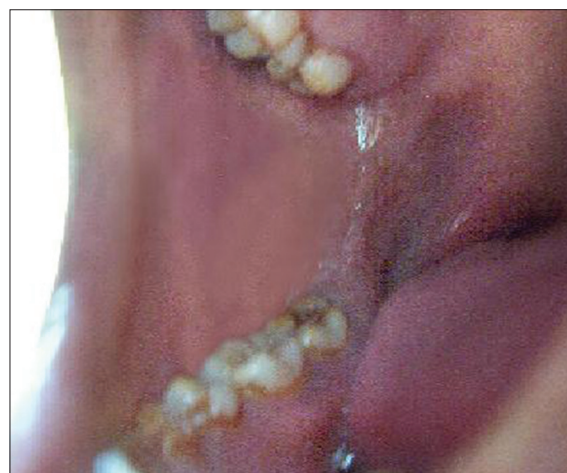

Figure 6: After *Triphala* rinsing

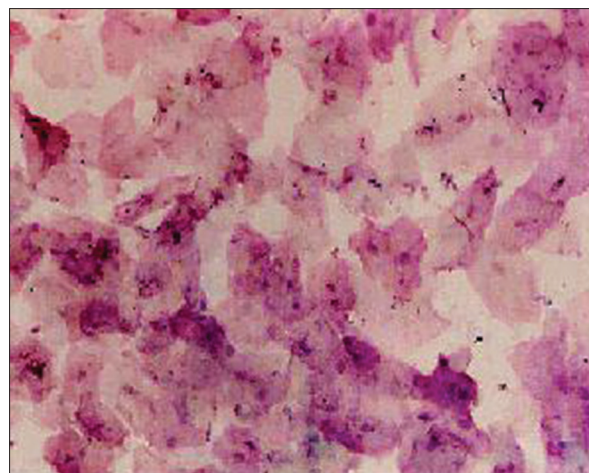


Figure 7: Smear showing normal features

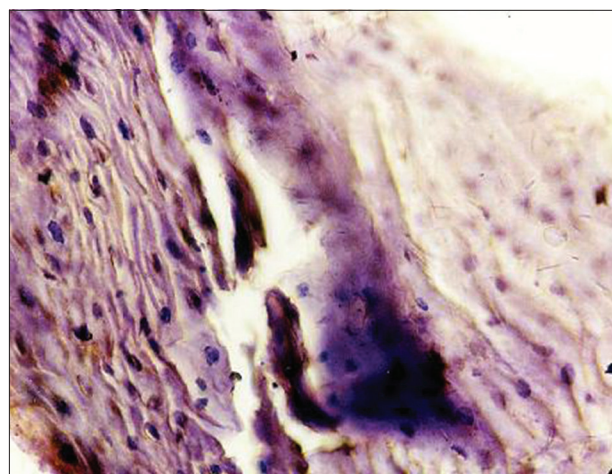


Figure 8: Biopsy showing normal features

reported that more than 51% of high school students in the US in 1995 had consumed at least one alcoholic beverage in the preceding 30 days.^[16] Only 1 of the 27 alcohol consumers showed acetowhite positive lesion in this study. In contrast, researcher found alcohol consumption to be more implicated

factor in etiology of oral cancer than tobacco.^[17] The association was statistically significant ($P < 0.05$) in relation to the teenagers of lowest income family thus showing the increased prevalence of oral mucosal and pre-cancerous lesions in low socio-economic population. In agreement to this study, another

study also have reported that oral problems are more common in lower socioeconomic group.^[18]

Site of the lesion

The subjects detected with the lesions gave a history of the placement of tobacco in the same area where the mucosa was found altered. In previous study researchers also reported that 80% of the patients with oral cavity carcinoma developed their cancers in areas where the wad of tobacco was held.^[19] Alcohol and tobacco has site specificity in the etiology of oral cancer and found alcohol consumption to be more in patients with highest cancer incidence in floor of mouth, tongue and buccal mucosa.^[17] Out of 127 smokeless tobacco users, 29 (22.8%) had an oral lesion at the time of examination.^[20] Of these lesions, 23 (79.3%) were hyperkeratotic and 6 (20.7%) were epithelial dysplasia. Researcher studied prevalence of oral lichen planus and oral leukoplakia in 112 patients with oral squamous cell carcinoma.^[21] The tongue and floor of the mouth were the most common locations and oral squamous cell carcinoma was seen to be strongly associated with these lesions.

Smeard lesions

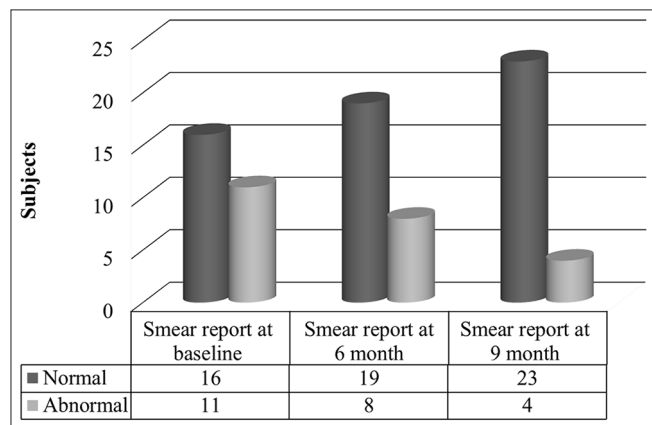
Similar to presented study, a previous study evaluated the use of exfoliative cytology for the early diagnosis of oral cancers and its role for in education and private practice.^[22] Exfoliative cytology may be used as an important aid in the early detection of oral cancers. Researcher studied the use of biopsy in the diagnosis and management of oral soft-tissue lesions.^[23] Study stated that immediate biopsy should be done as a confirmatory diagnosis. An international seminar in 1983 agreed that leukoplakia is strongly associated with the use of tobacco.^[12] In presented study, out of 34 acetowhite positive, 30 were consuming some form of tobacco and 26 out of 27 acetowhite positive lesions showed alarming changes on histological staging [Graph 1]. Unfortunately, a major impediment to treating oral cancer is that diagnosis is not usually established until 3 months after the onset of symptoms, which affects the treatments selected and the prognosis.^[24] Late diagnosis of oral cancer is attributable to numerous factors, including insufficient oral cancer screening examinations performed in the elderly, patient procrastination and improper diagnosis of oral lesions.^[24] The biochemical changes in cell-surface glycoproteins and glycolipids that take place during malignant transformation which has been found of clinical utility of total and lipid bound sialic acid in patients

with oral pre-cancer and oral cancer. Mean values of serum sialic acid (total and lipid bound) in oral cancer were significantly higher than control and the pre-cancer group ($P < 0.001$). Serum sialic acid levels can differentiate between patients with oral pre-cancer and oral cancer. It could be used as an adjunct to diagnosis, monitor response to therapy and assess the staging of cancer.^[25] The focus on young adult population has to be established to accomplish the objective of tumor down staging. Consequently, at the time of diagnosis, patients are twice as likely to have an advanced tumor compared to a localized lesion.

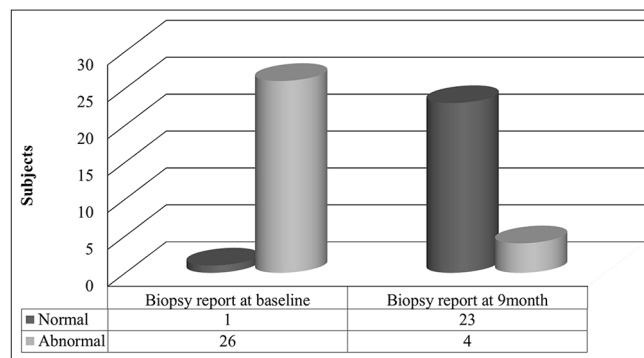
Post-rinse histology report

Histological findings after 9 month use of *Triphala* mouth rinse revealed no changes in cells in 23 (85.2%), hyperkeratinization in 2 (7.4%). Hyperkeratinization and spongiosis was evident in 1 (3.7%), mild pleomorphism in 1 (3.7%) [Table 2 and Graph 2]. Comparative evaluation from 0 to 9 month showed high statistically significant correlation on Linear-by-Linear Association by Chi-square test ($P < 0.01$) [Table 2]. A clinicopathologic study of 3256 oral leukoplakias showed that 80.1% of leukoplakias were varying combination of hyperorthokeratosis, hyperparakeratosis and acanthosis without evidence of epithelial dysplasia.^[26] Mild to moderate epithelial dysplasias was noted in 12.2% of specimens and severe epithelial dysplasia or carcinoma *in situ* was found in 4.5%. Another researcher also described “smokeless tobacco lesions” histologically characterized by hyperkeratinization and vacuolization of the epithelium, acanthosis and proliferation of inflammatory cells.^[27]

The results were quite evident and showed the reversal of the lesions with *Triphala* mouthwash. This can be attributed to its anti-oxidant property combined with various other beneficial properties like anti-bacterial properties,^[28] exerts heart protective and cardiotoxic effect,^[29,30] anti-mutagenic properties,^[31,32] anti-cancer properties.^[33] Researchers in another study also proved that all three fruits have antioxidant property.^[4] Each of the constituents of *Triphala* is equally efficient in scavenging superoxide and peroxide radicals, thus working synergistically to create a powerful antioxidant and detoxifier.^[5,6] Thus the direct application of herbal medicine, *Triphala* and rinsing with it can definitely be of great help in downstaging of pre-cancerous lesions. Although it was a small group of population screened the percentage of lesions detected was 3.1% of the total 1095 teenage population, figure that develops apprehension for the health professionals. The 25% of the teenage population involved in some or the other form of tobacco is also quiet astonishing. Thus with



Graph 1: Comparative evaluation of smear report at baseline, 6 month and 9 months



Graph 2: Comparative evaluation of biopsy report at baseline and 9 months

the results discussed above it shows that India needs a simple and low resource screening method for early detection and downstaging of pre-cancerous lesion and cancers and also to create awareness in the young adults who are the future of our society.

Conclusions

- Significant number of children with positive acetowhite lesions (3.1%) indicates the importance of early prevention and intervention in adolescents
- Adolescents are highly vulnerable to injurious habits as 25.0% were tobacco users
- A definite association is present in these young adults with various risk factors
- Low resource screening method should be mandatory for all health personals to learn and be applied in all settings
- *Triphala*, the indigenous mouth rinse proved to be effective in reversal of the lesions and confirmed the promise of triphala as a potential chemopreventive and/or anticancer drug.

In the view of present findings in small population the increased percentage use of smokeless tobacco in young population is quite alarming. Thus, India being a developing country with limited funds needs such screening programs on a large scale to develop awareness, prevention and protection of this young population of India. The indigenous and cost-effective *Triphala* mouth rinse has proved to be a key tool in prevention and reversal of the pre-cancerous lesions, which is also another feather in the cap along with wide repertoire of treatment options available. However, the herbs need to be evaluated by long-term multicentric clinical trials.

Acknowledgments

The authors would like to thank Dr. Usha Arora, Senior Pathologist, Mariampur Hospital, Kanpur, for her skillful assistance in preparing and diagnosing the histopathological slides.

References

- Neville BW, Day TA. Oral cancer and precancerous lesions. *CA Cancer J Clin* 2002;52:195-215.
- Youth tobacco surveillance – United States, 1998-1999. *MMWR CDC Surveill Summ* 2000;49:1-94.
- Tierra M. The wonders of Triphala. *East West School of Herbology*. 2008. Available from: <http://www.planetherbs.com/articles/triphala.html>. [Last cited on 2009 Jul 18].
- Takagi N, Sanashiro T. Health foods containing antioxidative and anti-allergy food materials. *Jpn Kokai Tokkyo Koho* 1996; 10:070, Jan 6th.
- Sandhya T, Lathika KM, Pandey BN, Mishra KP. Potential of traditional ayurvedic formulation, *Triphala*, as a novel anticancer drug. *Cancer Lett* 2006;231:206-14.
- Wongnoppavich A, Jaijoi K, Sireeratawong S. *Triphala*: The Thai traditional herbal formulation for cancer treatment. *Songklanakarin J Sci Technol* 2009;31:139-49.
- Jagetia GC, Baliga MS, Malagi KJ, Sethukumar Kamath M. The evaluation of the radioprotective effect of *Triphala* (an ayurvedic rejuvenating drug) in the mice exposed to gamma-radiation. *Phytomedicine* 2002;9:99-108.
- Maurya U, Srivastava S. Traditional Indian herbal medicine used as antipyretic, antiulcer, anti-diabetic and anticancer: A review. *Int J Res Pharm Chem* 2011;1:1152.
- Denny L, Kuhn L, Pollack A, Wainwright H, Wright TC Jr. Evaluation of alternative methods of cervical cancer screening for resource-poor settings. *Cancer* 2000;89:826-33.
- Visual inspection with acetic acid for cervical-cancer screening: Test qualities in a primary-care setting. University of Zimbabwe/JHPIEGO Cervical Cancer Project. *Lancet* 1999;353:869-73.
- Scully C, Porter S. Orofacial disease: Update for the dental clinical team: 3. White lesions. *Dent Update* 1999;26:123-9.
- World Health Organisation Collaborating Reference Centre for Oral Precancerous Lesions. Definition of leukoplakia and related lesions: An aid to studies on oral precancer. *Oral Surg* 1985;14:559.
- Gupta PC, Hebert JR, Bhonsle RB, Murti PR, Mehta H, Mehta FS. Influence of dietary factors on oral precancerous lesions in a population-based case-control study in Kerala, India. *Cancer* 1999;85:1885-93.
- Chaturvedi P. Squamous cell carcinomas of the head and neck. Precancerous lesions in oral cavity of Indian schoolchildren may hint at epidemic. *BMJ* 2003;326:282.
- Reichart PA, Kirchheim A, Löchte KH. Tobacco and oral health. Questionnaire about knowledge, practices, and opinions among dentists in Berlin. *Mund Kiefer Gesichtschir* 2000;4:45-9.
- Kann L, Warren CW, Harris WA, Collins JL, Williams BI, Ross JG, et al. Youth risk behavioral surveillance – United States. *Morb Mortal Wkly Rep* 1995;45 Suppl 4:1-86.
- Adewole RA. Alcohol, smoking and oral cancer. A 10-year retrospective study at Base Hospital, Yaba. *West Afr J Med* 2002;21:142-5.
- Doifode VV, Ambadekar NN, Lanewar AG. Assessment of oral health status and its association with some epidemiological factors in population of Nagpur, India. *Indian J Med Sci* 2000;54:261-9.
- Wray A, McGuirt WF. Smokeless tobacco usage associated with oral carcinoma. Incidence, treatment, outcome. *Arch Otolaryngol Head Neck Surg* 1993;119:929-33.
- Kaugars GE, Brandt RB, Chan W, Carcaise-Edinboro P. Evaluation of risk factors in smokeless tobacco-associated oral lesions. *Oral Surg Oral Med Oral Pathol* 1991;72:326-31.
- Haya Fernández MC, Bagán Sebastián JV, Basterra Alegría J, Lloria de Miguel E. Prevalence of oral lichen planus and oral leukoplakia in 112 patients with oral squamous cell carcinoma. *Acta Otorrinolaringol Esp* 2001;52:239-43.
- Kaugars GE, Silverman S Jr, Ray AK, Page DG, Abbey LM, Burns JC, et al. The use of exfoliative cytology for the early diagnosis of oral cancers: Is there a role for it in education and private practice? *J Cancer Educ* 1998;13:85-9.
- Handlers JP. Diagnosis and management of oral soft-tissue lesions: The use of biopsy, toluidine blue staining, and brush biopsy. *J Calif Dent Assoc* 2001;29:602-6.
- Silverman S Jr. *Oral Cancer*. 4th ed. Hamilton, (NY): B.C. Decker Inc.; 1998.
- Taqi SA. Clinical evaluation of total and lipid bound sialic acid levels in oral precancer and oral cancer. *Indian J Med Paediatr Oncol* 2012;33:36-41.
- Waldron CA, Shafer WG. Leukoplakia revisited. A clinicopathologic study 3256 oral leukoplakias. *Cancer* 1975;36:1386-92.
- Axéll T. A prevalence study of oral mucosal lesions in an adult Swedish population. *Odontol Revy Suppl* 1976;36:1-103.
- Khorana ML, Rao MR, Siddiqui HH. Antibacterial and antifungal activity of *Phyllanthus emblica* Linn. *Indian J Pharm* 1959;21:331.
- Hussain SJ. Screening of some Unani cardiotoxic drugs'. D.U.M., Thesis. Aligarh: Aligarh Muslim University; 1975.
- Tariq M, Hussain SJ, Asif M, Jahan M. Protective effect of fruit extracts of *Emblica officinalis* (Gaertn.) and *Terminalia bellerica* (Roxb.) in experimental myocardial necrosis in rats. *Indian J Exp Biol* 1977;15:485-6.
- Niiawa M, Fu A. Effects of Chinese medicinal plant extracts on mutagenicity of Trp-P-1. *Nat Med* 1995;49:329-31.
- Rani G, Bala S, Grover IS. Anti-mutagenic studies of diethyl ether extract and tannin fractions of *emblica myroblan* (*Emblica officinalis*) in Ames assay. *J Plant Sci Res* 1994;10:1-4.
- Tokura K, Kagawa S. Anticancer agents containing chebulanin from *Terminalia chebula*. *Jpn Kokai Tokkyo Koho* 1995; 07:138,165.

How to cite this article: Deshpande A, Tandon S, Deshpande N. Low resource screening method of pre-cancerous lesions and its reversal by *Triphala* in teen-age Indian population. *Ayu* 2014;35:160-7.

Source of Support: Nil, **Conflict of Interest:** None declared.

हिन्दी सारांश

पूर्व कैंसर घावों का न्यूनतम विधि से निदान एवं भारतीय किशोरों में त्रिफला का प्रभाव

अनशुला देशपांडे, शोभा टण्डन, नीरज देशपांडे

कैंसर स्क्रीनिंग एक पूर्व आक्रामक या पूर्व घातक स्तर पर कैंसर का जल्दी पता लगाने के लिए मुख्य हथियार हैं। यह १२ लाख से अधिक लोगों में उच्च जोखिम वाले कारकों में से एक है और इसलिए विश्वव्यापी समस्या बन गया है, जिसका कारण तंबाकू का किसी न किसी रूप में उपयोग बताया गया है। वर्तमान अध्ययन का उद्देश्य सुलभ विधि द्वारा प्रारंभिक अवस्था में इस रोग का प्रभावी निदान (स्क्रीनिंग) का मूल्यांकन करना और पूर्व कैंसर घावों के उत्क्रमण में स्वदेशी माउथवॉश के प्रभाव का मूल्यांकन करना है। सामाजिक आर्थिक स्थिति से संबंधित किशोरों के लिए स्क्रीनिंग किया गया था। उत्तर भारत के १३-१९ साल की उम्र के कामकाजी बच्चों को अध्ययन के लिए चुना गया। संदिग्ध किशोरों को आयुर्वेदिक माउथवॉश के इस्तेमाल से घावों के उत्क्रमण के लिए मूल्यांकन किया गया। कैंसर स्क्रीनिंग एसिटिक एसिड के साथ नई विधि - दृश्य निरीक्षण द्वारा किया गया। सकारात्मक विषयों में आगे पैप स्मीयर द्वारा जांच की गई और इस की पुष्टि बायोप्सी लेकर उत्तकविकृतिविज्ञानी के रिपोर्ट से की गयी। दूसरे चरण में सकारात्मक घावों के साथ रुग्णों में स्वदेशी कैंसर विरोधी माउथवॉश (त्रिफला माउथवॉश) का प्रयोग सूचित किया गया और उसके प्रभाव का मूल्यांकन कुल्ला करने की सलाह देने के ६ और ९ माह के बाद किया गया। तंबाकू और सुपारी के विभिन्न रूपों का प्रयोग मुख कैंसर और कैंसर घावों में घनिष्ठ संबंध दिखता है। त्रिफला में इन घावों के उत्क्रमण की काफी संभावना देखी गई।