

# Traumatic main airway rupture successfully rescued by extracorporeal membrane oxygenation: A case report

LIJUN CAO<sup>1</sup>, JUN XU<sup>1</sup>, LINFENG TANG<sup>1</sup>, YULI ZHOU<sup>1</sup> and XIANHUA XIANG<sup>2</sup>

<sup>1</sup>Emergency Department, Jiaxing First Hospital; <sup>2</sup>Outpatient Department, SUNTO Women and Children's Hospital, Jiaxing, Zhejiang 314000, P.R. China

Received April 13, 2023; Accepted October 3, 2023

DOI: 10.3892/etm.2023.12265

**Abstract.** The chest is a common site for traumatic injury; however, rupture of the main airway after chest trauma is a rare and potentially fatal condition. The present study demonstrated that extracorporeal membrane oxygenation (ECMO) may serve a crucial role in the effective conventional treatment of patients with severe chest trauma, ECMO was used before tracheal repair surgery to prevent hypoxia during surgery. When effective ventilation of the patient cannot occur without assistance, ECMO support is considered to be essential in ensuring effective gas exchange. This rescue procedure can provide guidance for the treatment of patients suffering from traumatic tracheal rupture and respiratory failure. To summarize, ECMO may be able to improve the treatment experience of patients with traumatic tracheal rupture and increase the treatment success rate of such patients.

## Introduction

The chest is a vulnerable site for injury, but rupture of the main airway after chest trauma is a rare and potentially fatal occurrence (1). The incidence of tracheal injury after trauma is 0.5-2% and the mortality rate is ~9% (2). Often, physical airway obstruction is caused by a collapse of the main airway due to tremendous kinetic energy caused by the injury. This high-energy trauma is combined with fractures of the ribs and sternum, which alter the intrathoracic pressure state through paradoxical breathing, thereby affecting the stability of the thorax. The combination of massive pneumothorax and extensive lung contusion can potentially result in death from respiratory failure (3). In order to alleviate airway obstruction and restore thoracic stability, such patients often require active surgical procedures (4).

Extracorporeal membrane oxygenation (ECMO), also known as artificial lung, is a modified extracorporeal circulation technique that can effectively replace the heart and pulmonary function to maintain the body's circulation and gas exchange, which allows time for the recovery of cardiopulmonary function (5). For decades, ECMO has been a useful supportive therapy for severe cardiopulmonary disease (6). Cardiopulmonary support for traumatic tracheo-bronchial injury in adults was first described in 2012 (7). The present case report provides details on the diagnosis and treatment process of a 39-year-old male patient who underwent airway reconstruction in order to relieve airway obstruction under ECMO support.

## Case report

A 39-year-old man was crushed by an excavator during the course of his work in July 2022. The patient experienced severe chest pain immediately after the injury, as well as chest tightness and shortness of breath, dyspnea and continuous hemoptysis, without hematemesis. The patient presented to the emergency room of Jiashan First People's Hospital (Jiaxing, China) 30 min after the injury occurred, where they were admitted with clear consciousness and dysphoria, a body temperature of 36.2°C, heart rate of 112 beats/min (bpm), respiration rate of 38 breaths/min, blood pressure of 107/72 mmHg and oxygen saturation (SPO<sub>2</sub>) of 92%. Upon examination of the patient, there was swelling and bruising in the neck, massive subcutaneous emphysema on both sides of the chest wall and beneath the abdominal wall, drum sounds on percussion of both lungs and a loss of breath sounds on auscultation. On physical examination, the patient's oxygen saturation had declined to <80%, tracheal intubation was performed immediately and CT was performed. CT examination demonstrated multiple air accumulations in the cerebral sulcus, cerebral fissure and ventricles, collapse of the main bronchus, bronchial occlusion on both sides, pneumothorax on both sides with partial lung tissue inflation, 70% lung compression, multiple rib fractures on both sides, massive subcutaneous emphysema on both sides of the chest wall, fracture of the right scapula and fracture of the right clavicle (Figs. 1 and 2). The results of the blood gas analysis were as follows: Partial pressure of oxygen (PaO<sub>2</sub>), 51.3 mmHg (normal range: 80-100 mmHg); partial pressure of carbon dioxide, 67.2 mmHg (normal range: 35-45 mmHg);

---

*Correspondence to:* Ms. Xianhua Xiang, Outpatient Department, SUNTO Women and Children's Hospital, 666 Ji Chuan Road, Nanhu, Jiaxing, Zhejiang 314000, P.R. China  
E-mail: 15024333657@139.com

**Key words:** extracorporeal membrane oxygenation, airway rupture, airway reconstruction

base excess, -8.4 mmol/l (normal range: -3-+3 mmol/l); pH, 7.15 (normal range: 7.35-7.45); lactate level, 4.5 mmol/l (normal range: 0.5-2.2 mmol/l); and hemoglobin level, 104 g/l (normal range: 130-175 g/l).

The preliminary diagnosis was as follows: Main bronchial rupture, bilateral hemopneumothorax, pulmonary contusion, multiple rib fractures and respiratory failure. After the course of CT examination, the patient became unconscious and ceased to respond to calls, SPO<sub>2</sub> gradually decreased to 65% and the heart rate slowed to 23 bpm. The monitor indicated ventricular escape rhythm; therefore, the patient was immediately administered cardiopulmonary compressions, bilateral closed chest drainage and epinephrine 1 mg was administered intravenously for cardiac stimulation. Tranexamic acid 1 g was administered by intravenous drip to stop bleeding and pethidine 50 mg was injected intramuscularly for pain relief. The patient also received lactate Ringer's solution 2,000 ml intravenous infusion to replenish the blood volume and Propofol 0.5 g micropump injection for sedation. The patient achieved return of spontaneous circulation 10 min after resuscitation. Combined with the previous CT report, respiratory arrest due to acute respiratory failure caused by collapse of the main airway was considered. After the multidisciplinary team (MDT) of the regional trauma center (Jiaxing First Hospital Trauma Center; Jiaxing China), was invited for remote consultation, it was decided to perform main airway repair to improve the patient's ventilation and oxygen supply.

The operation could not be performed immediately, as the emergency operating room of Jiashan First People's Hospital's (Jiaxing, China) was occupied at the time due to an ongoing surgery. The second hour after the injury, no improvement in the patient's condition was observed after endotracheal intubation. Subcutaneous emphysema developed and SPO<sub>2</sub> continued to decline after endotracheal intubation. Under volume control mode (tidal volume, 8 ml/kg; respiratory rate, 42 breaths/min; positive end-expiratory pressure, 10 mmHg; oxygen concentration, 100%), the patient's oxygenation index (PaO<sub>2</sub>/fraction of inspired oxygen) continued to fall <50 mmHg and blood lactate rose to 8.2 mmol/l; therefore, the patient's condition had reached the level where ECMO support was required (5).

The operating room was occupied; therefore, the operation could not be carried out after the arrival of the MDT specialist cardiothoracic surgeon. The cardiothoracic surgeon performed a tracheoscopy. Immediate tracheoscopy showed no tracheal prominences and indicated that the main airway was broken. Veno-venous-ECMO (VV-ECMO) was performed on the right femoral vein and the right internal jugular vein. Under ultrasound guidance, a 20Fr introducer catheter was placed through the right femoral vein and a 19Fr return catheter through the right internal jugular vein at the puncture point using the Seldinger technique (8). The initial catheter position was adjusted through transepigastric ultrasound. Upon completion of the procedure, a bedside X-ray confirmed the placement of the head of the femoral vein at the opening between the inferior vena cava and right atrium (data not shown). A ROTAFLOW centrifugal pump (Maquet Cardiopulmonary GmbH) and a QUADROX PLS oxygenator (Maquet Cardiopulmonary GmbH) were used to pre-flush the ECMO line with 5,000 units heparin. After flushing, the catheter was connected to the patient. Treatment parameters

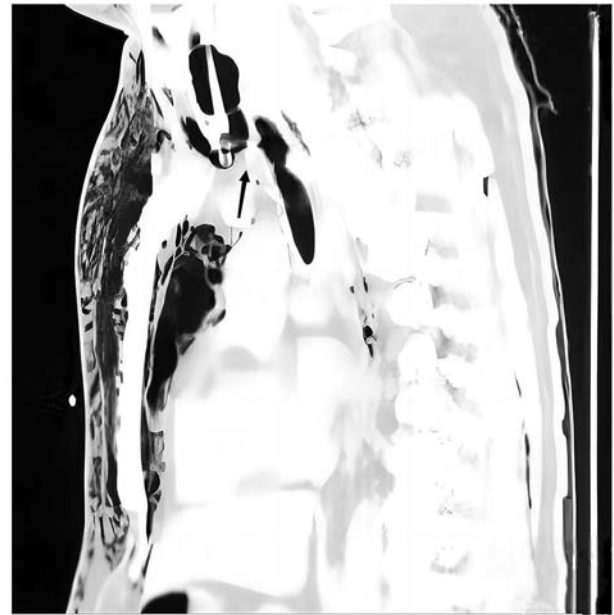


Figure 1. CT scan images of the patient's chest upon hospital admission (sagittal view). The black arrow indicates complete rupture of the main trachea.

were set as follows: Speed, 685 x g; blood flow, 4 l/min; and oxygen flow, 4 l/min. Patient SPO<sub>2</sub> was maintained at ~90%.

Five hours after the injury, the patient was escorted in an ambulance to Jiaxing First Hospital Trauma Center (Jiaxing, China) with support for ECMO and ventilator. After arrival, the patient underwent emergency tracheal repair at the cardiothoracic surgery department, while maintaining an SPO<sub>2</sub> of ~93% with ECMO support. A median cervical incision was made, and a complete dissection of the tracheal membrane was observed intraoperatively between the first and second tracheal cartilages. ECMO was used in place of intraoperative ventilator support and pulmonary ventilation was terminated. As part of the tracheal reconstruction procedure, the upper and lower severed ends were explored, and the broken membrane was sutured to the anterior tracheal cartilage. Following the ECMO procedure, the patient was transported to the Emergency Intensive Care Unit, where heparin anticoagulation was administered. Heparin speed was maintained at 125-375 U/h, activated clotting time at 100-140 sec and hemoglobin at 85-101 g/l. On the second day after surgery, the ECMO parameters were as follows: Rotational speed, 3,200 r/min; blood flow, 3.1 l/min; oxygen flow, 2.3 l/min; and SPO<sub>2</sub>, ~93%. The mean arterial pressure was ~60 mmHg before norepinephrine administration and increased to 80-90 mmHg with norepinephrine norepinephrine (0.1-0.2 µg/kg/min), SPO<sub>2</sub> was >93%. ECMO flow was adjusted according to blood gas analysis; the rotational speed was reduced by ~5 x g per day. PaO<sub>2</sub> fluctuated between 95 and 234 mmHg, and the partial pressure of carbon dioxide was within the 35-45 mmHg (normal range: 35-45 mmHg). After 5 days, ECMO parameters were as follows: Rotational speed, 224 x g; blood flow, 2.2 l/min; oxygen flow, 1.2 l/min; and SPO<sub>2</sub>, >95%. The patient's condition improved with stable blood circulation and ECMO was terminated. No further surgery was performed for rib, scapula and clavicle.

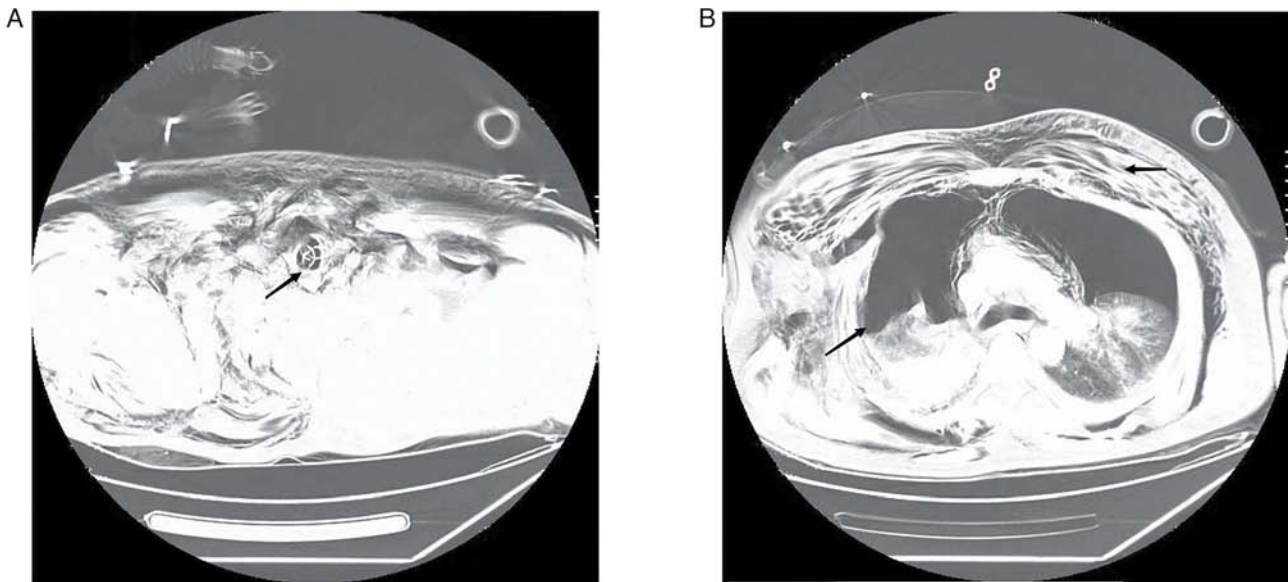


Figure 2. CT scan of the patient's chest on admission (axial view). (A) The black arrow indicates collapse of the main bronchus. (B) The black arrow indicates pneumothorax, lung compression and massive subcutaneous emphysema of the chest wall.

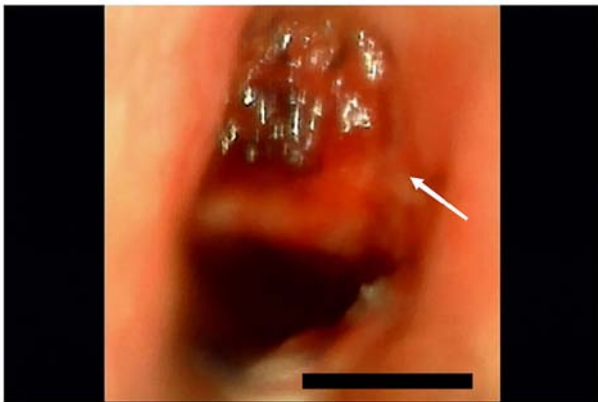

Figure 3. Image obtained during fiberoptic bronchoscopy. The white arrow indicates tracheal cartilage collapse and airway stenosis.

After ECMO decannulation, ventilator therapy was used under volume control mode (tidal volume, 8 ml/kg; respiratory rate, 25 breaths/min; positive end-expiratory pressure, 5 mmHg; oxygen concentration, 50%). Following the withdrawal of the ECMO machine, a chest CT was performed. Bilateral lung effusion and pleural effusion were reduced, and pneumothorax and subcutaneous emphysema was partially absorbed in the chest wall compared with the patient's condition at the time of admission. At 7 days after the injury, the patient's consciousness was similar to that on arrival at the trauma center, which may be related to craniocerebral injury or cerebral anoxia due to ventricular escape rhythm, and expectoration was poor. When the tracheal catheter was used for sputum aspiration, only ~20 cm of the sputum aspiration tube could be inserted. A fiberoptic bronchoscopy was performed and when the fiberoptic tracheoscope probe was inserted into the tracheal repair site, it was found that the tracheal cartilage had collapsed, resulting in airway stenosis (Fig. 3). In consultation with the Department of Otolaryngology, Jiaying First Hospital, a

tracheotomy was recommended. A tracheal tube was placed under the inferior tracheal cartilage through a median cervical incision. The patient was treated with high-flow oxygen therapy after tracheotomy and was then transferred to a general ward for rehabilitation. On the 10th day after injury, chest CT indicated that lungs were not compressed, and the pneumothorax and subcutaneous emphysema had been absorbed (Fig. 4). After 24 days of hospitalization, the patient's consciousness had improved; however, they could not take care of themselves. The patient was transferred back to the hospital of the first presentation, Jiashan First People's Hospital (Jiaying, China), for rehabilitation treatment. The patient was discharged after 58 days of rehabilitation. In January 2023, the patient is off the ventilator, but is unconscious, bedridden and unable to care for themselves.

## Discussion

ECMO is a valuable clinical tool used for cardiopulmonary support, allowing effective gas exchange when ventilation is not possible in certain situations, such as heart or respiratory failure. According to the blood flow pathway, there are two types of ECMO: VV- and veno-arterial (VA)-ECMO. As VA-ECMO improves oxygenation and provides cardiac support, it is primarily used in cases of severe heart failure or heart transplantation. However, VV-ECMO has a relatively low impact on circulation since the patient's own cardiac function maintains the blood flow (5). Therefore, VV-ECMO is primarily used in patients with non-cardiac acute respiratory failure in order to improve oxygenation by adjusting oxygenation parameters (9). Although the use of ECMO in patients with severe chest trauma has been controversial due to trauma-induced coagulopathy and higher bleeding risk (10), there is increasing evidence that ECMO can serve a crucial role in the case of ineffective conventional treatment of patients with severe chest trauma (11-13). In order to improve the chance of survival of the patient presented in the current

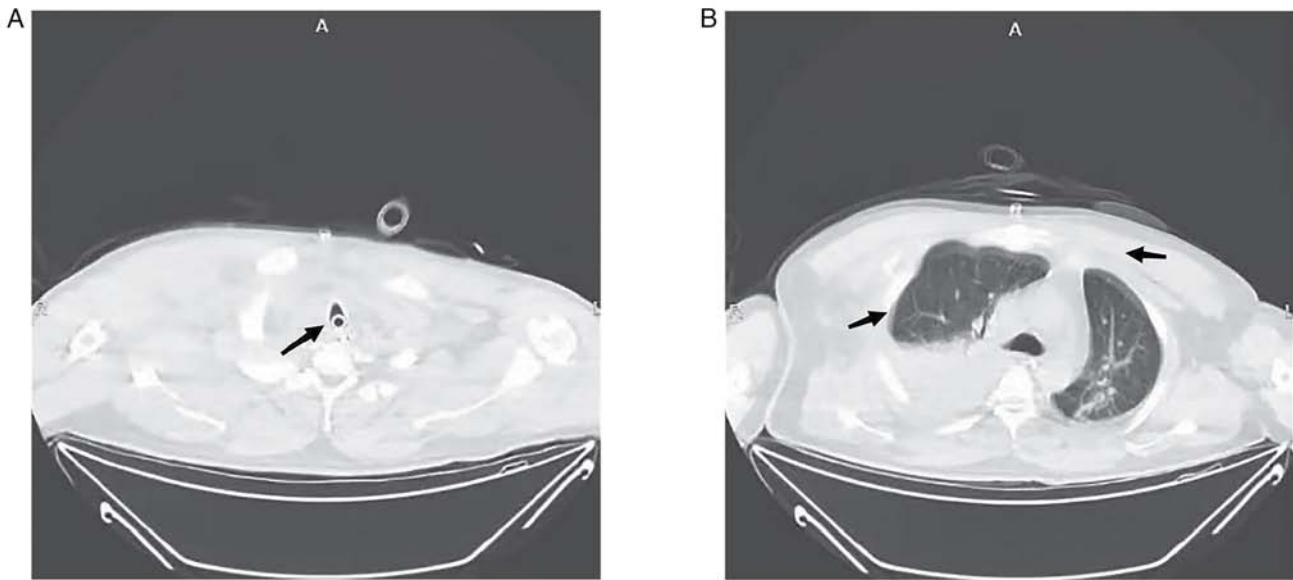


Figure 4. CT scan of the chest 10 days after injury (axial view). (A) The black arrow indicates the main bronchus did not collapse after tracheotomy. (B) The black arrow indicates lungs were not compressed, and the pneumothorax and subcutaneous emphysema had been absorbed.

case report during surgery, the multidisciplinary trauma team decided to apply the VV-ECMO treatment model.

The repair of the trachea is a demanding and difficult procedure, which requires optimal exposure of the surgical field and adequate oxygenation of the tissues during the reconstruction of the airway. In order to maintain oxygen supply during bronchial repair, a catheter is often used to ventilate the distal airway, or high-frequency jet ventilation or high-flow oxygen is instilled into the tracheal intubation catheter (14,15). Alternatively, a double-lumen tracheal intubation catheter can be used, where the lung tissue on the affected side is prevented from being ventilated, while the lung tissue on the healthy side is ventilated (16). In the present case report, the lung ventilation-blood flow ratio was imbalanced due to the dissection of the main airway and incomplete expansion of both lungs; therefore, intraoperative oxygenation could not provide adequate oxygen if administered exclusively through tracheal intubation. When effective ventilation cannot be assured, ECMO support is considered to be essential in ensuring effective gas exchange. The purpose of this procedure is to prevent hypoxia in the patient caused by inadequate intrapulmonary ventilation during surgery (17).

In order to prevent the development of thrombosis in the membrane oxygenator during ECMO therapy, appropriate anticoagulation measures should be taken (5). However, in trauma and surgical patients, anticoagulation therapy may lead to severe bleeding, and heparinization management during ECMO therapy in post-trauma patients has been a focus of current research (18). The high speed of the ECMO centrifugal pump, the high blood flow generated during surgery and the biological layer used on the inner surface of the line (Bioline coating), the main components of which are macromolecule heparin and therapeutic peptide molecules, have resulted in a reduction of the risk of blood clotting in the device (19,20). A previous study reported that there was no heparinization management prescribed for 5 days following the membrane oxygenator therapy, which may result in apparent clotting

spots and thrombosis-related complications (20). In this case, ECMO coagulation was not observed and organ bleeding due to anticoagulation therapy was avoided by closely monitoring changes in hemoglobin, lactate and vital signs, and administering low-dose heparin anticoagulation postoperatively.

In the present study, despite the patient undergoing an airway reconstruction in order to relieve airway obstruction under ECMO support, the recovery of brain function was slow as a result of cerebral ischemia and hypoxia. In addition, the narrowing of the trachea for subsidence of the tracheal reconstruction prevented the discharge of airway secretions, which can cause pulmonary atelectasis and lung infection (21). However, although tracheotomy is a mandatory procedure, the location of tracheal rupture overlapped with the location of airway reconstruction. Tracheotomy was performed between the tracheal cartilage rings below the airway reconstruction following consultation with an otorhinolaryngologist. To date, previous studies examining the timing of tracheotomies in trauma patients have focused on subgroups of patients, such as those suffering from traumatic brain injuries and burns (22,23). A previous study by Zhang *et al* (24) concluded that early tracheotomy may improve the 28-day survival in patients with multiple rib fractures. However, a better predictive model is required to assess the timing of tracheotomy in patients with post-traumatic tracheal rupture.

The procedures presented in the current study may provide guidance for the diagnosis and treatment of future patients with traumatic tracheal rupture and respiratory failure. The use of ECMO during tracheal repair surgery has a major advantage of maintaining adequate gas exchange during the procedure to avoid the poor prognosis commonly associated with inadequate ventilation during conventional surgery. Due to the working characteristics of ECMO and the lines with Bioline coating, combined with close bleeding risk monitoring and a highly specialized disciplinary team, the risk of bleeding during ECMO support in trauma patients is significantly reduced with low anticoagulation intensity compared with standard anticoagulation therapy regimens. In these patients, timing of the tracheotomy

needs to be further discussed, and performing the tracheotomy earlier to be completed during airway reconstruction is an additional option to improve the treatment of such patients.

The present case report demonstrated that ECMO could replace lung function in a patient with chest trauma during an emergency condition to save time for surgery and reduce the potential adverse outcomes of the patient. In summary, to improve oxygenation and assist in airway reconstruction surgery, ECMO therapy in patients with traumatic tracheal ruptures is a potential successful treatment method, and could be considered during the diagnosis and management of related conditions.

### Acknowledgements

Not applicable.

### Funding

This study was supported by a project from the Scientific Research Fund of Zhejiang Provincial Education Department (grant no. Y202249584).

### Availability of data and materials

The datasets used and/or analyzed during the current study are available from the corresponding author on reasonable request.

### Authors' contributions

LC and XX designed and supervised the study. LC, JX and LT performed data collection and analysis. LC and YZ performed data analysis and interpretation. All authors confirm the authenticity of all the raw data. All authors have read and approved the final version of the manuscript.

### Ethics approval and consent to participate

Not applicable.

### Patient consent for publication

The patient provided written informed consent for publication of this case report and the accompanying images.

### Competing interests

The authors declare that they have no competing interests.

### References

- Lafferty PM, Anavian J, Will RE and Cole PA: Operative treatment of chest wall injuries: Indications, technique, and outcomes. *J Bone Joint Surg Am* 93: 97-110, 2011.
- Prokakis C, Koletsis EN, Dedelias P, Fligou F, Filos K and Dougenis D: Airway trauma: A review on epidemiology, mechanisms of injury, diagnosis and treatment. *J Cardiothorac Surg* 9: 117, 2014.
- Gao JM, Li H, Du DY, Yang J, Kong LW, Wang JB, He P and Wei GB: Management and outcome of bronchial trauma due to blunt versus penetrating injuries. *World J Clin Cases* 10: 5185-5195, 2022.
- Lin WT, Su SY, Hsieh CF, Lai CC and Chao CM: Traumatic thoracic burst fracture associated with bronchial rupture. *J Emerg Med* 53: 260-261, 2017.
- Wrisinger WC and Thompson SL: Basics of extracorporeal membrane oxygenation. *Surg Clin North Am* 102: 23-35, 2022.
- Abrams D and Brodie D: Novel uses of extracorporeal membrane oxygenation in adults. *Clin Chest Med* 36: 373-384, 2015.
- Walker JL, Wiersch J, Benson C, Young HA, Dearmond DT and Johnson SB: The successful use of cardiopulmonary support for a transected bronchus. *Perfusion* 27: 34-38, 2012.
- Patel AR, Patel AR, Singh S, Singh S and Munn NJ: Venovenous extracorporeal membrane oxygenation therapy in adults. *Cureus* 11: e5365, 2019.
- Squiers JJ, Lima B and Dimaio JM: Contemporary extracorporeal membrane oxygenation therapy in adults: Fundamental principles and systematic review of the evidence. *J Thorac Cardiovasc Surg* 152: 20-32, 2016.
- Lee OJ, Cho YH, Hwang J, Yoon I, Kim YH and Cho J: Long-term extracorporeal membrane oxygenation after severe blunt traumatic lung injury in a child. *Acute Crit Care* 34: 223-227, 2019.
- Bosarge PL, Raff LA, McGwin G Jr, Carroll SL, Bellot SC, Diaz-Guzman E and Kerby JD: Early initiation of extracorporeal membrane oxygenation improves survival in adult trauma patients with severe adult respiratory distress syndrome. *J Trauma Acute Care Surg* 81: 236-243, 2016.
- Zhang LY, Qin CN, Zhang Q, Liu XD, Tian RB and Hei FL: The Application of Extracorporeal Membrane Oxygenation in the Treatment of Lung Injury. *J Chin Extracorp Cardiocirc* 18: 328-332, 2020 (In Chinese).
- Aprile V, Korasidis S, Ambrogi MC and Lucchi M: Extracorporeal membrane oxygenation in traumatic tracheal injuries: A bold life-saving option. *J Thorac Dis* 11: 2660-2663, 2019.
- Abouarab AA, Elsayed HH, Elkhayat H, Mostafa A, Cleveland DC and Nori AE: Current solutions for long-segment tracheal reconstruction. *Ann Thorac Cardiovasc Surg* 23: 66-75, 2017.
- Ahmed N, Naseem K and Rafiq M: Anesthetic challenges in tracheal resection and reconstruction surgery. *Anaesth Pain Intensi* 22: 323-329, 2018.
- Wanat-Hawthorne A, Stubblefield J, Lynch I, Dellaria S and Kernstine K: Successful use of a double lumen endotracheal tube and bronchial blocker for lung isolation in pulmonary mucormycosis. *J Cardiothorac Vasc Anesth* 33: 776-780, 2019.
- Carretta A, Ciriaco P, Bandiera A, Muriana P, Pappalardo F, Broman LM, Montisci A and Negri G: Veno-venous extracorporeal membrane oxygenation in the surgical management of post-traumatic intrathoracic tracheal transection. *J Thorac Dis* 10: 7045-7051, 2018.
- Wu MY, Chou PL, Wu TI and Lin PJ: Predictors of hospital mortality in adult trauma patients receiving extracorporeal membrane oxygenation for advanced life support: A retrospective cohort study. *Scand J Trauma Resusc Emerg Med* 26: 14, 2018.
- Zhang Y, Deng L, Feng XL, Li Y, Song ML, Wang Y, Chang L and Zhou P: Analysis of different anticoagulation strategies and complications in extracorporeal membrane oxygenation therapy. *Chin J Critical Care Med* 41: 630-634, 2021 (In Chinese).
- Yu HJ, Zhu XY, Xu XQ and Cao WZ: Resuscitation of Severe Pulmonary Contusion with Hemoptysis by Heparin-free Anticoagulation Extracorporeal Membrane Oxygenation. *Chin J Emerg Med* 29: 1480-1482, 2020 (In Chinese).
- Cheng J, Shi JY, Sun P, Zhu H, Li XO and Liu D: Application of extracorporeal membrane oxygenation in bronchoscopic interventional surgery for patients with severe airway stenosis and literature review. *Chin J Respir Crit Care Med* 21: 498-504, 2022 (In Chinese).
- Robba C, Galimberti S, Graziano F, Wieggers EJA, Lingsma HF, Iaquaniello C, Stocchetti N, Menon D and Citerio G: CENTER-TBI ICU Participants and Investigators: Tracheostomy practice and timing in traumatic brain-injured patients: A CENTER-TBI study. *Intensive Care Med* 46: 983-994, 2020.
- Tsuchiya A, Yamana H, Kawahara T, Tsutsumi Y, Matsui H, Fushimi K and Yasunaga H: Tracheostomy and mortality in patients with severe burns: A nationwide observational study. *Burns* 44: 1954-1961, 2018.
- Zhang B, Li GK, Wang YR, Wu F, Shi SQ, Feng QL, Hang X, Miao RF, Xia L, Duan C, *et al*: Analysis of timing and prognostic factors of early tracheotomy in patients with multiple rib fractures. *Chin J Trauma* 37: 646-652, 2021 (In Chinese).



Copyright © 2023 Cao et al. This work is licensed under a Creative Commons Attribution-NonCommercial-NoDerivatives 4.0 International (CC BY-NC-ND 4.0) License.