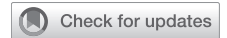



Since January 2020 Elsevier has created a COVID-19 resource centre with free information in English and Mandarin on the novel coronavirus COVID-19. The COVID-19 resource centre is hosted on Elsevier Connect, the company's public news and information website.

Elsevier hereby grants permission to make all its COVID-19-related research that is available on the COVID-19 resource centre - including this research content - immediately available in PubMed Central and other publicly funded repositories, such as the WHO COVID database with rights for unrestricted research re-use and analyses in any form or by any means with acknowledgement of the original source. These permissions are granted for free by Elsevier for as long as the COVID-19 resource centre remains active.

Spontaneous Hemoptysis in a Patient With COVID-19



Shirisha Pasula, MD; and Pranatharthi Chandrasekar, MD

CASE PRESENTATION: A 65-year-old man presented with shortness of breath, gradually worsening for the previous 2 weeks, associated with dry cough, sore throat, and diarrhea. He denied fever, chills, chest pain, abdominal pain, nausea, or vomiting. He did not have any sick contacts or travel history outside of Michigan. His medical history included hypertension, diabetes mellitus, chronic kidney disease, morbid obesity, paroxysmal atrial fibrillation, and tobacco use. He was taking amiodarone, carvedilol, furosemide, pregabalin, and insulin. The patient appeared to be in mild respiratory distress. He was afebrile and had saturation at 93% on 3 L of oxygen, heart rate of 105 beats/min, BP of 145/99 mm Hg, and respiratory rate of 18 breaths/min. On auscultation, there were crackles on bilateral lung bases and chronic bilateral leg swelling with hyperpigmented changes. His WBC count was 6.0 K/cumm (3.5 to 10.6 K/cumm) with absolute lymphocyte count 0.7 K/cumm (1.0 to 3.8 K/cumm); serum creatinine was 2.81 mg/dL (0.7 to 1.3 mg/dL). He had elevated inflammatory markers (serum ferritin, C-reactive protein, lactate dehydrogenase, D-dimer, and creatinine phosphokinase). Chest radiography showed bilateral pulmonary opacities that were suggestive of multifocal pneumonia (Fig 1). Nasopharyngeal swab for SARS-CoV-2 was positive. Therapy was started with ceftriaxone, doxycycline, hydroxychloroquine, and methylprednisolone 1 mg/kg IV for 3 days. By day 3 of hospitalization, he required endotracheal intubation, vasopressor support, and continuous renal replacement. Blood cultures were negative; respiratory cultures revealed only normal oral flora, so antibiotic therapy was discontinued. On day 10, WBC count increased to 28 K/cumm, and chest radiography showed persistent bilateral opacities with left lower lobe consolidation. Repeat respiratory cultures grew *Pseudomonas aeruginosa* (Table 1). Antibiotic therapy with IV meropenem was started. His condition steadily improved; eventually by day 20, he was off vasopressors and was extubated. However, on day 23, he experienced significant hemoptysis that required reintubation and vasopressor support.

CHEST 2021; 160(1):e39-e44

Physical Examination Findings

The patient was sedated and intubated. Vital signs included BP 126/63 mm Hg, heart rate 93 beats/min, respiratory rate 18 breaths/min, and temperature 37.4°C. On auscultation, there was decreased breath sounds throughout right lung with rhonchi. Heart rate was regular with no gallop or murmur. Abdomen was

soft and nontender. Lower extremities had grade 2 pedal edema bilaterally.

Diagnostic Studies

WBC count was 6.1 K/cumm (3.5 to 10.6 K/cumm), hemoglobin 8.4 g/d (13.3 to 17.1 gm/dL), platelet count

AFFILIATIONS: From the Department of Internal Medicine, Division of Infectious Diseases, Wayne State University, Detroit, MI.

CORRESPONDENCE TO: Shirisha Pasula, MD; email: spasula@med.wayne.edu

Copyright © 2021 American College of Chest Physicians. Published by Elsevier Inc. All rights reserved.

DOI: <https://doi.org/10.1016/j.chest.2021.01.069>

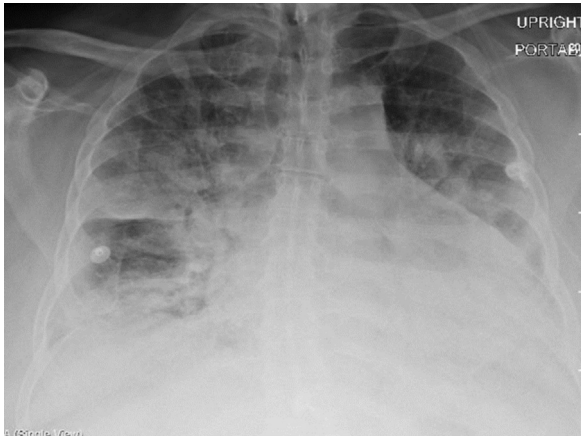


Figure 1 – Chest radiograph on presentation: bilateral pulmonary opacities suggestive of multifocal pneumonia

209 K/cumm(150 to 450K/cumm), creatinine 1.36 mg/dL (0.7 to 1.3 mg/dL). Chest radiography revealed right upper lobe collapse (Fig 2).

On day 23, repeat respiratory cultures showed *Pseudomonas aeruginosa*, which was resistant to meropenem (antibiotic susceptibilities provided in Table 1), and antibiotic therapy was switched to IV ceftolozane-tazobactam. Blood cultures showed no

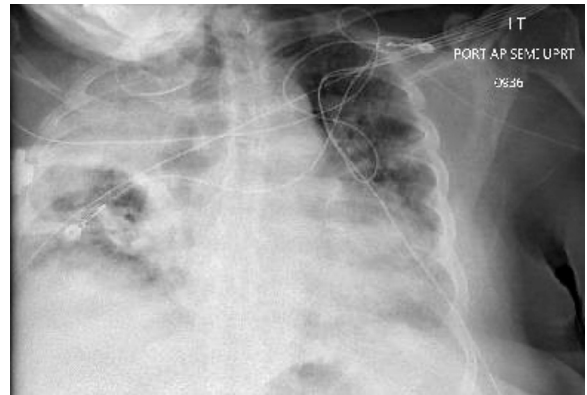


Figure 2 – Chest radiograph: right upper lobe collapse

growth. There was no clinical improvement, despite the antibiotic change. On day 29, serum *Aspergillus* galactomannan was elevated to 5.65 (0 to 0.49), and serum beta-D glucan was 137 pg/mL (0 to 59 pg/mL). Respiratory fungal culture revealed *A niger*. A CT scan of the chest showed patchy airspace opacities throughout both lungs, cavitary lesions in upper lobes bilaterally, and right lung base. Cavitary lesion in the right lung base measured 6.5 × 5.3 cm and demonstrated an air-crescent sign (Fig 3).

TABLE 1] Antibiotic Susceptibilities of *Pseudomonas aeruginosa*

Antibiotic	Day 10		Day 23			
	Minimum Inhibitory Concentration	Minimum Inhibitory Concentration Interpretation	Minimum Inhibitory Concentration	Minimum Inhibitory Concentration Interpretation	Epsilometer Test	Epsilometer Test Interpretation
Aztreonam	16	MS	>16	R
Cefepime	8	S	16	MS
Ceftazidime	4	S	16	MS
Imipenem	2	S	>8	R
Meropenem	0.5	S	>8	R
Piperacillin/ Tazobactam	16/4	S	32/4	MS
Tobramycin	1	S	1	S
Ceftazidime/ Avibactam	4	S
Ceftolozane/ Tazobactam	1	S

MS = moderately susceptible; R = resistant; S = susceptible.

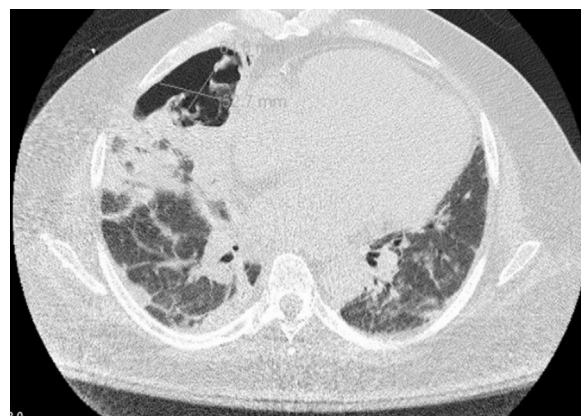

Figure 3 – CT scan of the thorax: right lung base consolidation and cavitary lesion with air-crescent sign

What is the diagnosis?

Diagnosis: Invasive pulmonary aspergillosis due to *A niger* in an immunocompetent patient with COVID-19 pneumonia

Discussion

Invasive pulmonary aspergillosis (IPA) is a serious infection and typically occurs in the immunocompromised population. It may develop in ICU patients without classic host risk factors, such as neutropenia, solid organ, or hematopoietic stem cell transplantation and long-term steroid use. Incidence of IPA in ICU setting ranges from 0.3% to 5.8%. Chronic obstructive lung disease, liver cirrhosis, malnutrition, and prolonged ICU stay (>7 days) are recognized as possible risk factors. Normal pulmonary defense mechanisms to protect against the growth of *Aspergillus* conidia in the respiratory tract are likely impaired in critically ill patients. Reduced mucociliary clearance from endotracheal intubation, reduced function of pulmonary macrophages and neutrophils from bacterial pneumonia or multiorgan failure, and steroid use might promote hyphal growth and angioinvasion that leads to invasive aspergillosis. Diagnosis of IPA in immunocompetent patients in ICU is challenging because the differentiation between colonization of the respiratory tract vs infection is difficult. *AspICU* clinical algorithm has been developed to diagnose IPA in ICU patients with and without classic host risk factors.

There are few case series and retrospective observational studies reported from China and Europe that describe IPA as an emerging complication in critically ill patients with COVID-19 called as COVID-19-associated pulmonary aspergillosis (CAPA). Prevalence is reported up to 20% to 35%.

Pathogenetic mechanism for CAPA is not understood completely. Two possible immunologic mechanisms were described that involved danger-associated molecular patterns and recognition pathways. Danger-associated molecular patterns are signal molecules released by dying or damaged cells that act as endogenous danger signals to promote and exacerbate the immune and inflammatory response that leads to lung injury, and they have also been shown to regulate inflammation in fungal disease. The collateral effects of recognition pathways required for the activation of antiviral immunity that may contribute paradoxically to an inflammatory environment that favors secondary infections. The early hyperactivation of the IL-1 pathway that is induced by the SARS-CoV-2 infection may be a

major factor that establishes a highly permissive inflammatory environment that favors fungal pathogenesis. Besides IL-1, increased levels of IL-6 have been observed in severe cases of COVID-19, and enhanced production of IL-6 by epithelial cells infected with *A fumigatus* has been observed, which suggests that, at least in some patients, the coinfection may contribute to the increased levels of this cytokine, particularly in patients with severe COVID-19. However, the use of tocilizumab (IL-6 antagonist) to improve ARDS in patients with COVID-19 paradoxically could enhance predisposition to CAPA. At this point, pathogenesis of CAPA is multifactorial and involves profound lymphopenia, dysregulation of immunity, cytokine storm, disruption of respiratory mucosal integrity from COVID-19 infection and use of steroids; IL-6 antagonists may add to the risk of the development of CAPA.

Diagnosing CAPA is also challenging because aspergillus from respiratory specimens may be considered a colonizing organism in ICU patients. Cases of CAPA may be missed if diagnosis is based on European organization for Research and Treatment of Cancer Mycoses Study Group consensus criteria because of absence of classic host factors. The modified *AspICU* algorithm for patients with influenza might be the most useful criteria in diagnosing CAPA. Bronchoscopy with biopsy, BAL fungal culture, and BAL galactomannan are standard for diagnosis of IPA but may not be feasible in patients with COVID-19 pneumonia because bronchoscopy is considered to be an aerosolizing procedure and may increase the risk of infection to health care personnel. Bronchoscopy is relatively contraindicated in patients with suspected and confirmed COVID-19. Serum aspergillus galactomannan has been studied extensively in immunocompromised populations with sensitivity of approximately 70%. However, in patients who are not neutropenic, serum galactomannan sensitivity of approximately 25% has been reported. Finding an elevated serum galactomannan level was the turning point in our management to initiate antifungal treatment promptly and perform further investigation. Further research is required to investigate efficacy of serologic assays in patients who are not neutropenic and have COVID-19.

Most of the reported cases of CAPA are due to *A fumigatus* and very few to *A flavus*. *A niger* is an uncommon species to cause invasive pulmonary disease and not reported so far as a cause of CAPA. Respiratory

culture positive for any mold should investigate further work up and not to be dismissed as airway colonization.

There is a high mortality rate associated with critically ill patients with COVID-19, and the risk increases with superinfection, especially fungal infections that are hard to diagnose. High index of suspicion, early investigation, and prompt treatment are necessary to improve mortality rates.

Clinical Course

Spontaneous hemoptysis, elevated serum levels of galactomannan and beta-D glucan, respiratory fungal culture that shows *A niger*, and radiologic evidence of cavitory lesion with air-crescent sign in this critically ill patient with COVID-19 strongly support the diagnosis of IPA. These features met the criteria for IPA according to the modified AspICU algorithm for patients with influenza.

Therapy with IV voriconazole was started on day 29. A 10-day course of antibiotic ceftolozane-tazobactam was completed. Within 5 days of starting antifungal treatment, the patient's respiratory status significantly improved, and he underwent extubation. Serum voriconazole trough level was 2.8 µg/mL (therapeutic range, 1 to 5 µg/mL). On day 40, IV voriconazole was switched to oral therapy. Follow-up serum galactomannan level gradually improved to 1.27 and 0.17 (0-0.49) over the next 2 weeks. The patient was discharged to a rehabilitation facility on day 58. Follow-up CT chest scan at 5 weeks of therapy showed improving bilateral cavitory lesions (Fig 4). Voriconazole was continued for total of 6 weeks.

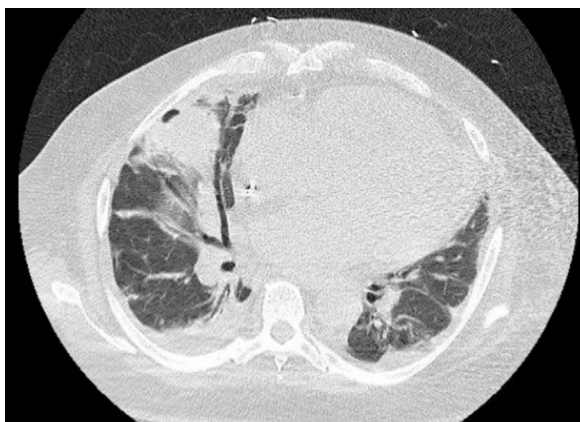


Figure 4 – CT scan of the thorax: right lung base cavitory lesion significantly reduced

Clinical Pearls

1. Patients with COVID-19 with worsening pulmonary status despite therapy are candidates at risk for pulmonary aspergillosis, and appropriate work up should be initiated.
2. Patients with COVID-19 with sputum culture positive for *Aspergillus* should be evaluated carefully to differentiate colonization from infection. The use of the modified AspICU algorithm for diagnosis of CAPA is most useful because critically ill patients can have invasive aspergillosis in the absence of traditional host risk factors that are required by other consensus criteria.
3. Chest radiologic features (radiography; CT scan) suggestive of cavitory lesion should raise suspicion for superimposed infections with bacteria such as *Staphylococcus aureus*, *Pseudomonas aeruginosa*, or anaerobes, and fungi-like *Aspergillus* species or Mucorales.
4. Elevated serum galactomannan levels, chest imaging with diagnostic features, and respiratory culture positive for *Aspergillus* species should be adequate to initiate treatment for pulmonary aspergillosis. Bronchoscopy is to be avoided to minimize aerosolization in patients with COVID-19, unless absolutely needed. It is indicated only if alternative diagnosis that would change treatment is suspected or as a lifesaving procedure.

Acknowledgments

Financial/nonfinancial disclosures: None declared.

Other contributions: CHEST worked with the authors to ensure that the Journal policies on patient consent to report information were met.

Suggested Readings

Blot SI, Taccone FS, Van den Abeele AM, et al. A clinical algorithm to diagnose invasive pulmonary aspergillosis in critically ill patients [published correction appears in *Am J Respir Crit Care Med*. 2012;186(8):808]. *Am J Respir Crit Care Med*. 2012;186(1):56-64.

Patterson TF, Thompson GR III, Denning DW, et al. Practice Guidelines for the Diagnosis and Management of Aspergillosis: 2016 Update by the Infectious Diseases Society of America. *Clin Infect Dis*. 2016;63(4):e1-e60.

Bassetti M, Bouza E. Invasive mould infections in the ICU setting: complexities and solutions. *J Antimicrob Chemother*. 2017;72(suppl_1):i39-i47.

Schauwvlieghe AFAD, Rijnders BJA, Philips N, et al. Invasive aspergillosis in patients admitted to the intensive care unit with severe influenza: a retrospective cohort study. *Lancet Respir Med*. 2018;6(10):782-792.

Alanio A, Dellièrè S, Fodil S, Bretagne S, Mégarbane B. Prevalence of putative invasive pulmonary aspergillosis in critically ill patients with COVID-19. *Lancet Respir Med*. 2020;8(6):e48-e49.

Arastehfar A, Carvalho A, van de Veerdonk FL, et al. COVID-19 associated pulmonary aspergillosis (CAPA)-from immunology to treatment. *J Fungi (Basel)*. 2020;6(2):91.

Meijer EFJ, Dofferhoff ASM, Hoiting O, Buil JB, Meis JF. Azole-Resistant COVID-19-associated pulmonary aspergillosis in an immunocompetent host: a case report. *J Fungi (Basel)*. 2020;6(2):79.

Prattes J, Valentin T, Hoenigl M, Talakic E, Reisinger AC, Eller P. Invasive pulmonary aspergillosis complicating COVID-19 in the ICU—a case report. *Med Mycol Case Rep.* 2021;31:2-5.

Wahidi MM, Lamb C, Murgu S, et al. American Association for Bronchology and Interventional Pulmonology (AABIP) statement on the use of bronchoscopy and respiratory specimen collection in

patients with suspected or confirmed COVID-19 infection. *J Bronchology Interv Pulmonol.* 2020;27(4):e52-e54.

Wang J, Yang Q, Zhang P, Sheng J, Zhou J, Qu T. Clinical characteristics of invasive pulmonary aspergillosis in patients with COVID-19 in Zhejiang, China: a retrospective case series. *Crit Care.* 2020;24(1):299.