

Donor cornea preparation in partial big bubble deep anterior lamellar keratoplasty

Li Lim¹

Samuel Wen Yan Lim²

¹Corneal and External Eye Disease Service, Singapore National Eye Centre, ²Yong Loo Lin School of Medicine, National University of Singapore, Singapore



Correspondence: Li Lim
Singapore National Eye Centre,
11 Third Hospital Avenue,
Singapore 168751
Tel +65 6227 7255
Email lim.li@snecc.com.sg

Background: The purpose of this paper is to describe a technique of donor cornea preparation to ensure good graft-host apposition in incomplete big bubble deep anterior lamellar keratoplasty.

Methods: Following a partial-thickness trephination, manual dissection and excision of corneal stroma was performed. Anwar's big-bubble technique involving a deep stromal air injection was then initiated. However, the big bubble could not extend to the trephination edge and the peripheral residual corneal stroma could not be removed. Donor cornea preparation involving trimming of the posterior lip of the corneal button was then performed and good graft-host apposition was obtained without graft over-ride.

Results: We performed peripheral donor cornea trimming prior to allograft placement in order to ensure good graft-host apposition. Postoperatively, best-corrected visual acuity in both eyes was 6/7.5.

Conclusion: Donor cornea preparation involving trimming of the posterior lip of the corneal button is a useful technique in instances where the big bubble does not extend to the trephination edge and ensures good graft-host apposition.

Keywords: deep anterior lamellar keratoplasty, incomplete Anwar big bubble deep anterior lamellar keratoplasty, donor cornea preparation

Introduction

Over the last few years, there has been a move from penetrating keratoplasty toward lamellar keratoplasty for the treatment of keratoconus. The advantage of lamellar keratoplasty is that it preserves the host Descemet's membrane (DM) and endothelium, thereby reducing the risk of graft rejection.¹

Deep anterior lamellar keratoplasty (DALK) involves allograft replacement of the anterior layers of the cornea (epithelium, Bowman's layer, and corneal stroma).² Using Anwar's big-bubble technique,³ rapid exposure of the DM is achieved by deep stromal air injection following partial-thickness trephination. Exposing the DM provides a smooth surface for placement of the lamella graft with superior visual outcomes for keratoconus.⁴ However, there are instances where the big bubble does not extend fully to the trephination diameter, leaving behind an adherent peripheral rim of corneal stroma that is difficult to remove and therefore left behind. This may pose difficulties with graft-host apposition due to over-riding of the graft. We recommend a technique of donor corneal preparation which provides a better graft-host apposition in cases where only a partial bubble is obtained and there is incomplete removal of the recipient stroma.

Surgical technique

Partial-thickness trephination of the cornea is performed up to 300 μm depth (60%–80% corneal depth) using a Hanna trephine (Moria, Antony, France). The diameter of the trephination varies according to the size of the cone in patients with keratoconus (in this case 8 mm). Following this, manual dissection and excision of the anterior stroma is performed using a crescent blade (2.25 mm; BD Visitec, Bidford on Avon, UK). Anwar's big-bubble technique is then performed by inserting a bent 27-gauge needle bevel down deep in the corneal groove. Subsequently, the Tan DALK cannula (Asico, Westmont, IL, USA) with an air-filled syringe attached is advanced and the plunger is pressed with some force. The big bubble appears recognizable by a white circular band. Typically, the big bubble extends to the trephination edge. However, in some cases, the big bubble could not extend to the trephination edge despite several attempts (Figure 1A and B).

A paracentesis is done peripheral to the bubble and the aqueous fluid egressed. A small bubble is injected into the anterior chamber to confirm the presence of the big bubble.⁵ The cavity of the bubble is penetrated with a blade and the bubble collapsed. Blunt-tipped corneal scissors (Anwar corneal scissors; Duckworth and Kent, Baldock, UK) are inserted

into the opening to enlarge the incision. A Teichmann grooved spatula (Duckworth and Kent) is inserted into the opening and sharp blades used to incise the stroma. The corneal stroma is divided into four quadrants and removed with Anwar scissors. A peripheral rim of stroma is left behind due to the inadequate air bubble being unable to expose the DM to the trephination edge (Figure 2). Trimming of the residual corneal stroma is performed with Vannas scissors (Katena Products, Inc., Denville, NJ, USA). A donor cornea of 0.25 mm oversize (in this case 8.25 mm) is trephined and the DM removed. The posterior lip of the corneal button is trimmed with Vannas scissors to approximately one-third of the corneal thickness. This creates a donor graft with a tapered end to match the recipient bed with the peripheral rim of residual stroma (Figure 3A–D). The donor is sutured to the recipient with 10–0 nylon sutures. This technique ensures good graft-host apposition (Figure 4).

Case report

The patient was a 20-year-old Indian male with bilateral advanced keratoconus and previous hydrops in the right eye resulting in corneal scarring (Figure 5). DALK was performed in the right eye and subsequently performed 1 year later in the left eye following intolerance of contact lens wear. Intraoperatively, an Anwar big bubble was attempted in

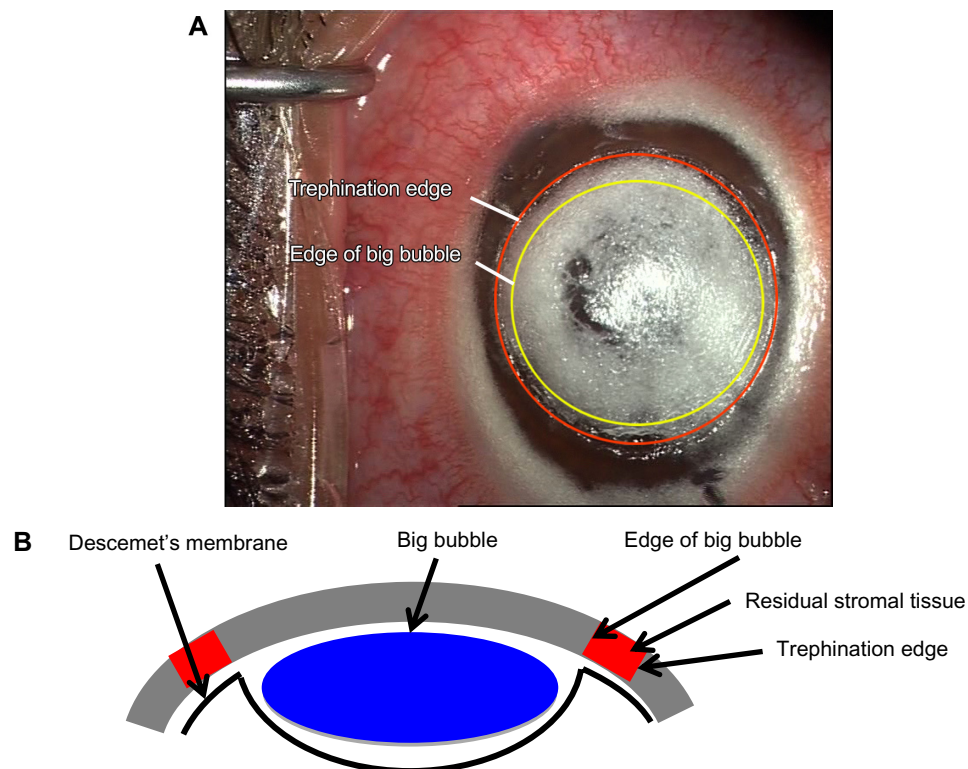


Figure 1 (A) Intraoperative photograph showing the big bubble being unable to extend to the trephination edge. (B) Schematic diagram in cross-section showing the big bubble being unable to extend to the trephination edge.

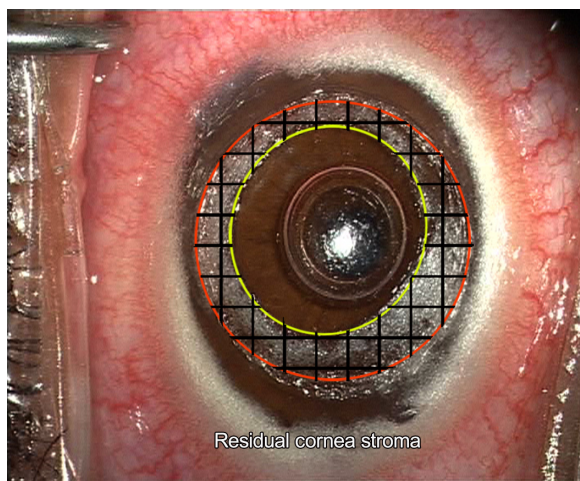


Figure 2 Intraoperative photograph showing peripheral residual corneal stroma.

both eyes after initial manual lamellar dissection, but only a partial central bubble was obtained in both eyes. In the right eye especially, the full-thickness corneal scar due to previous hydrops prevented full extension of the big bubble to the trephination edge. Therefore, the donor cornea was prepared

with a tapered edge to facilitate graft-host apposition as described above. The postoperative recovery was uneventful (see Table 1 for visual outcome). The postoperative result shows excellent graft-host apposition on anterior segment ocular computed tomography (Visante, Zeiss, Munich, Germany; Figure 6A and B) The graft with the tapered ends matches the recipient bed with the peripheral rim of residual corneal stroma from incomplete corneal stroma removal.

Discussion

Lamellar keratoplasty has a number of significant benefits over penetrating keratoplasty, including a very low allograft rejection rate, reduction in steroid use postoperatively, low rate of endothelial cell loss, and maintenance of globe integrity.^{6,7} Another advantage is that the donor endothelial cell count is not important, and this is an advantage especially in countries with limited access to corneal tissue. While manual lamellar keratoplasty is associated with a poorer visual outcome, recent studies of DALK have shown visual outcomes comparable with penetrating keratoplasty.⁸⁻¹³

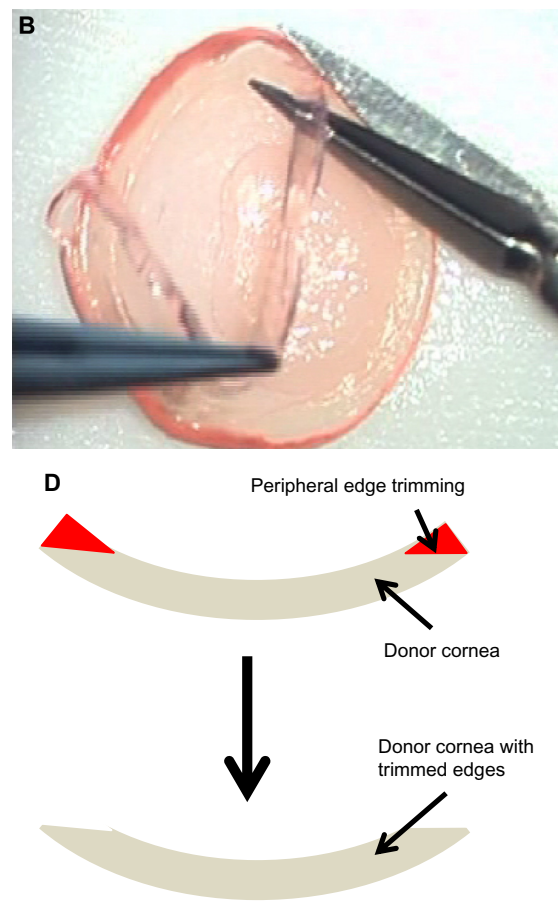
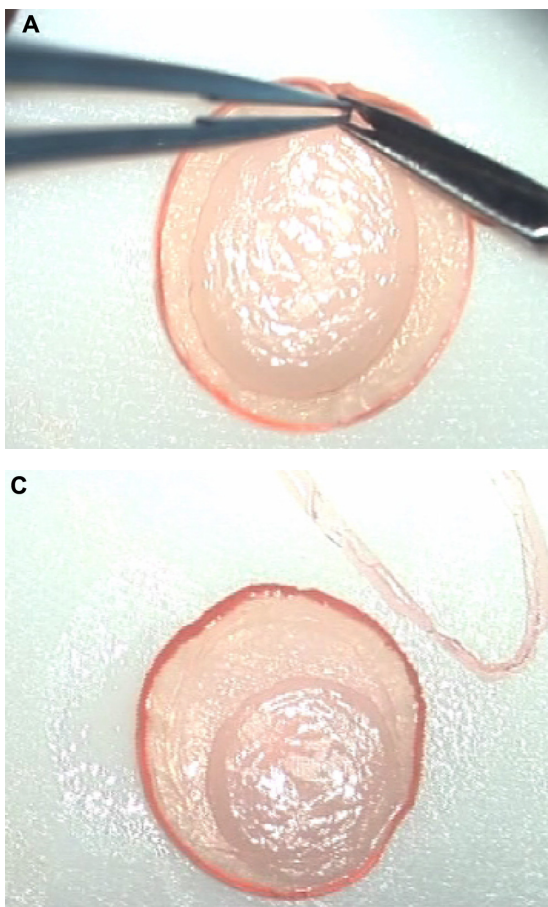


Figure 3 (A–C) Donor cornea preparation: the posterior lip of the corneal button is trimmed with Vannas scissors. **(D)** Schematic diagram showing donor cornea preparation.

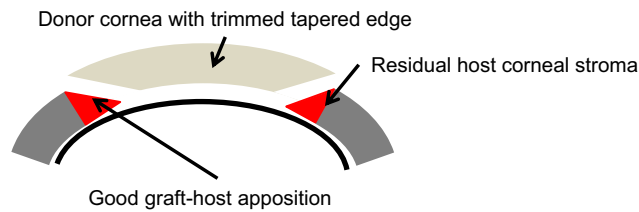


Figure 4 Schematic diagram showing good graft-host apposition as a result of donor cornea preparation.

The Anwar big-bubble technique bares the DM, ensuring a smooth optical interface and superior visual outcome. However, in advanced keratoconus, especially with previous corneal scarring due to hydrops (as in our case), it might not be possible to inject a complete big bubble which extends to the trephination edge. As long as baring of the DM is achieved over the visual axis, a good visual outcome is achievable, as in our case, since the peripheral residual corneal stroma does not affect visual outcome. In corneas without scarring from previous hydrops, peripheral dissection may be attempted by injecting viscoelastic substance into the opening and carefully advancing to the periphery before removal of four quadrants of the cornea stroma. A blunt spatula can be used to help separate the adherent peripheral rim. However, these techniques are associated with an increased risk of perforation of the DM.

To ensure good graft-host apposition, the donor cornea is prepared by trimming the posterior lip of the corneal button to match the recipient bed. While it might not be possible to match the recipient’s peripheral residual stromal bed exactly, graft over-ride can be avoided. It is not certain if this technique of trimming the donor cornea would induce more astigmatism, and more cases need to be analyzed to

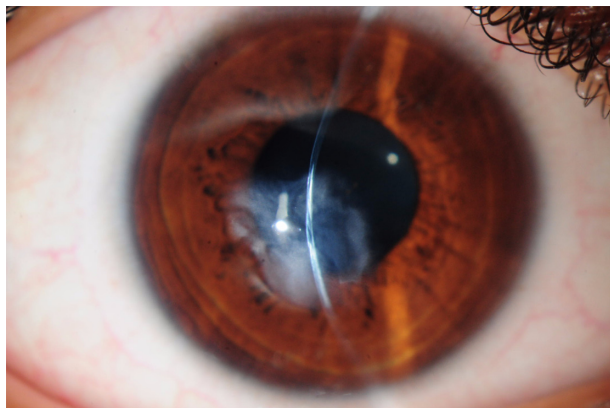


Figure 5 Preoperative slit-lamp photograph of the right eye showing advanced keratoconus with a full-thickness central corneal scar from previous hydrops.

Table 1 Preoperative and postoperative BCVA in the right and left eye for a patient who underwent deep anterior lamellar keratoplasty with a partial big bubble

	Preoperative BCVA (contact lens)	Postoperative BCVA (glasses)	Postoperative refraction
Right eye	6/120	6/7.5 (1 year’s duration)	-4.00/-5.00x5°
Left eye	6/7.5 (intolerant to contact lenses)	6/7.5 (6 months’ duration)	-10.50/-1.25x45°

Abbreviation: BCVA, best-corrected visual acuity.

determine its effect on astigmatism. Our study is limited in that it is a case report. Further studies can be performed to compare the visual outcome of this technique with the standard technique.

Conclusion

The Anwar big-bubble technique for DALK enables baring of the DM, in turn ensuring a smooth optical interface and superior visual outcome. However, there are cases where the big bubble is unable to extend to the trephination edge, and consequently, the peripheral residual corneal stroma

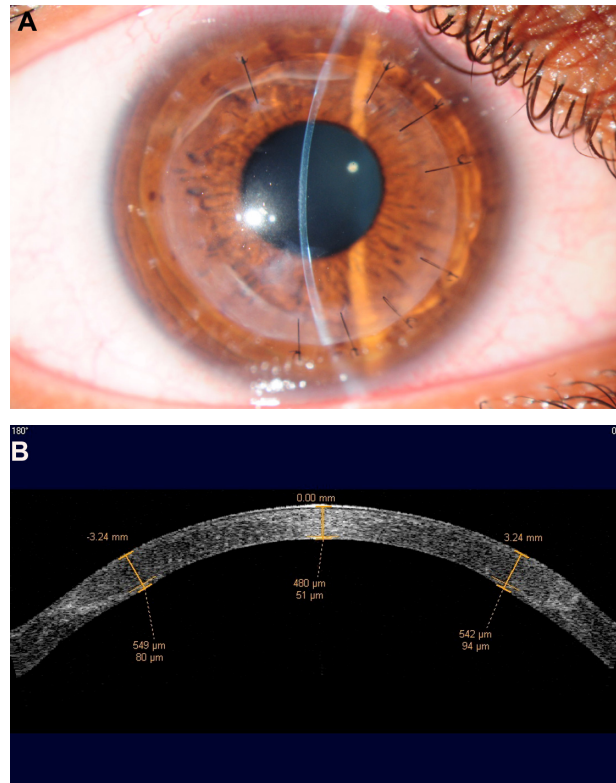


Figure 6 (A) One-year postoperative slit-lamp photograph of the right eye showing a clear graft. Some residual stromal scarring can be seen. **(B)** One-year postoperative optical coherence tomographic image of the right eye showing good graft-host apposition. Note the graft with tapered ends to match the recipient residual stromal bed.

cannot be completely removed and this may adversely affect graft-host apposition. Our technique demonstrates donor corneal preparation for good graft-host apposition.

Disclosure

The authors report no conflicts of interest in this work.

References

1. Jhanji V, Sharma N, Vajpayee RB. Management of keratoconus: current scenario. *Br J Ophthalmol*. 2011;95:1044–1050.
2. Melles GR, Lander F, Rietveld FJ, Remeijer L, Beekhuis WH, Binder PS. A new surgical technique for deep stromal, anterior lamellar keratoplasty. *Br J Ophthalmol*. 1999;83:327–333.
3. Anwar M, Teichmann KD. Big-bubble technique to bare Descemet's membrane in anterior lamellar keratoplasty. *J Cataract Refract Surg*. 2002;28:398–403.
4. Anwar M, Teichmann KD. Deep lamellar keratoplasty: surgical techniques for anterior lamellar keratoplasty with and without baring of Descemet's membrane. *Cornea*. 2002;21:374–383.
5. Parthasarathy A, Por YM, Tan DTH. Use of a "small-bubble technique" to increase the success of Anwar's "big-bubble technique" for deep lamellar keratoplasty with complete baring of Descemet's membrane. *Br J Ophthalmol*. 2007;91:1369–1373.
6. Sugita J, Kondo J. Deep lamellar keratoplasty with complete removal of pathological stroma for vision improvement. *Br J Ophthalmol*. 1997;81:184–188.
7. Morris E, Kirwan JF, Sujatha S, Rostron CK. Corneal endothelial specular microscopy following deep lamellar keratoplasty with lyophilised tissue. *Eye*. 1998;12:619–622.
8. Funnell CL, Ball J, Noble BA. Comparative cohort study of the outcomes of deep lamellar keratoplasty and penetrating keratoplasty for keratoconus. *Eye*. 2006;20:527–532.
9. Kawashima M, Kawakita T, Den S, Shimmura S, Tsubota K, Shimazaki J. Comparison of deep lamellar keratoplasty and penetrating keratoplasty for lattice and macular corneal dystrophies. *Am J Ophthalmol*. 2006;142:304–309.
10. Watson SL, Ramsay A, Dart JK, Bunce C, Craig E. Comparison of deep lamellar keratoplasty and penetrating keratoplasty in patients with keratoconus. *Ophthalmology*. 2004;111:1676–1682.
11. Shimazaki J, Shimmura S, Ishioka M, Tsubota K. Randomized clinical trial of deep lamellar keratoplasty vs penetrating keratoplasty. *Am J Ophthalmol*. 2002;134:159–165.
12. Panda A, Bageshwar LM, Ray M, Singh JP, Kumar A. Deep lamellar keratoplasty versus penetrating keratoplasty for corneal lesions. *Cornea*. 1999;18:172–175.
13. Han DC, Mehta JS, Por YM, Htoon HM, Tan DT. Comparison of outcomes of lamellar keratoplasty and penetrating keratoplasty in keratoconus. *Am J Ophthalmol*. 2009;148:744–751.

Clinical Ophthalmology

Publish your work in this journal

Clinical Ophthalmology is an international, peer-reviewed journal covering all subspecialties within ophthalmology. Key topics include: Optometry; Visual science; Pharmacology and drug therapy in eye diseases; Basic Sciences; Primary and Secondary eye care; Patient Safety and Quality of Care Improvements. This journal is indexed on

Submit your manuscript here: <http://www.dovepress.com/clinical-ophthalmology-journal>

Dovepress

PubMed Central and CAS, and is the official journal of The Society of Clinical Ophthalmology (SCO). The manuscript management system is completely online and includes a very quick and fair peer-review system, which is all easy to use. Visit <http://www.dovepress.com/testimonials.php> to read real quotes from published authors.