

# Imaging in retroperitoneal soft tissue sarcoma

Christina Messiou<sup>1</sup>  | Carlo Morosi<sup>2</sup>

<sup>1</sup> Department of Radiology, The Royal Marsden Hospital London and The Institute of Cancer Research, London, UK

<sup>2</sup> Department of Radiology, Fondazione IRCCS Istituto Nazionale Tumori Milan, Milan, Italy

## Correspondence

Christina Messiou, MD, Department of Radiology, The Royal Marsden Hospital London and The Institute of Cancer Research London, UK.

Email: christina.messiou@rmh.nhs.uk

## Funding information

NHS funding to the NIHR Biomedical Research Centre at The Royal Marsden Hospital London

Patients with retroperitoneal sarcoma can present to a variety of clinicians with non-specific symptoms and retroperitoneal sarcomas can be incidental findings. Failure to recognize retroperitoneal sarcomas on imaging can lead to inappropriate management in non-specialist centers. Therefore it is critical that the possibility of retroperitoneal sarcoma should be considered with prompt referral to a soft tissue sarcoma unit. This review guides clinicians through a diagnostic pathway, introduces concepts in response assessment and new imaging developments.

## KEYWORDS

CT, diagnosis, MRI, retroperitoneum, soft tissue sarcoma

## 1 | INTRODUCTION

Retroperitoneal soft tissue sarcomas (RPS) are frequently incidental findings on imaging for non-related symptoms or diseases and can grow to a large size in the retroperitoneum before symptoms or signs of abdominal pain, back pain, bowel obstruction or a palpable abdominal mass develop. RPS are rare and account for approximately 12-15% of all soft tissue sarcomas with a mean incidence of 2.7 per million.<sup>1,2,3</sup> Therefore the radiologist and clinicians involved in the patients care at presentation may not have experience of the imaging appearances. Failure to recognize RPS on imaging can lead to inappropriate management in inexperienced centres. This can have catastrophic consequences due to incomplete resections or contamination of the patients peritoneal cavity with tumor which jeopardizes the patients chance of a curative operation.<sup>1,4-7</sup> After tumor grade, the long-term survival following RPS resection is most dependent on the completeness of surgical resection. Other important factors are patient age, tumor subtype, tumor size, multifocality, and centralized multidisciplinary management in a specialist sarcoma center.<sup>1,4,5,7-14</sup> Therefore early referral is advisable.

## 2 | DIAGNOSTIC IMAGING TECHNIQUES

### 2.1 | Computed tomography (CT)

CT allows confirmation of site and origin of the mass and often tissue composition ie, lipomatous elements, calcifications or myxoid elements. Particularly where large masses distort anatomy, distinction between peritoneal and retroperitoneal masses can be challenging however displacement of retroperitoneal organs is a useful indicator that a tumor is retroperitoneal.<sup>15,16</sup> Assessment of local soft tissue infiltration and the relationship to critical neurovascular structures and the presence of metastatic disease are essential for surgical planning. Therefore contrast-enhanced computed tomography (CT) is the most useful primary imaging investigation with the additional benefit of wide availability. However it has been shown that with the exception of well differentiated liposarcoma and angiomyolipoma, the correct diagnosis of a retroperitoneal mass based on imaging alone is very challenging.<sup>2</sup> Percutaneous core needle biopsy usually confirms the diagnosis and is the gold standard, but rarely lesions are not amenable or high risk for biopsy and the differential diagnosis based on imaging becomes crucial.

This is an open access article under the terms of the Creative Commons Attribution-NonCommercial-NoDerivs License, which permits use and distribution in any medium, provided the original work is properly cited, the use is non-commercial and no modifications or adaptations are made.

© 2017 The Authors. *Journal of Surgical Oncology* Published by Wiley Periodicals, Inc.

## 2.2 | Magnetic resonance imaging (MRI)

MRI is reserved for patients with allergy to iodinated contrast agents or problem solving where for example muscle, bone, or foraminal involvement is equivocal on CT. MRI may also be useful for delineating disease in the pelvis. For patients where radiotherapy (RT) is considered, MRI can be useful for assessing local tumor extent and surrounding edema, which is optimally included in the treatment volume.<sup>17</sup>

## 2.3 | Fluorodeoxyglucose positron emission tomography (FDG PET/CT)

Due to the variability of histology and tumor grade, FDG PET/CT has no routine role for diagnosis. A meta-analysis found significant differences between intermediate/high grade lesions and low grade/benign lesions but critically no difference between low grade and benign lesions.<sup>18</sup> However for extremely heterogeneous tumors FDG PET/CT may be used to help guide biopsy which can be targeted to the most FDG avid component. This is because Glut-1 expression and glucose metabolism have been shown to correlate with tumor grade in sarcoma.<sup>19</sup> FDG PET/CT has also been found to be helpful in identification of malignant peripheral nerve sheath tumors in patients with neurofibromatosis<sup>120</sup> or rarely to evaluate possible multifocal disease.<sup>21</sup>

## 3 | IMAGE GUIDED BIOPSY

The retroperitoneum can host a multitude of benign or malignant pathologies. Image-guided percutaneous coaxial core needle biopsy (14 or 16 gauge) is the most accurate diagnostic modality and the preferred method to establish a histological diagnosis.<sup>12</sup> Several RPS have necrotic or even cystic areas, and image guidance provides the opportunity to obtain tissue material from solid tumor areas. A histological diagnosis is essential to discriminate benign retroperitoneal tumors or other malignant processes from sarcomas, to identify chemosensitive pathology, diagnose tumors in which neoadjuvant therapy is indicated, and to diagnose metastatic disease presenting as a retroperitoneal mass. Core needle biopsy of a retroperitoneal sarcoma (RPS) is safe, reliable and must be strongly recommended unless the imaging is pathognomonic of a dedifferentiated/well-differentiated liposarcoma and no preoperative neoadjuvant treatment is planned. Multiple needle cores (ideally 4-5) through a solitary skin puncture site should be obtained to allow for histologic and molecular subtyping. The retroperitoneal route should be the preferred route and the transperitoneal approach only utilized when the tumor is inaccessible for biopsy by the retroperitoneal route. Risk of needle track seeding is minimal and core needle biopsy does not negatively influence the oncological outcome.<sup>22,23</sup> The transperitoneal approach should be the last resort and only performed after specialist sarcoma multidisciplinary team discussion.

Fine-needle aspiration (FNA) cytology rarely yields diagnostic information. An open or laparoscopic surgical incision biopsy of a

retroperitoneal mass must be strongly discouraged as it requires an unnecessary operation, exposes the peritoneal cavity to contamination by sarcoma, distorts subsequent planes of dissection, may put vital neurovascular structures at risk and may not provide representative diagnostic tissue due to lack of three-dimensional image guidance.<sup>23,24</sup> In rare circumstances biopsy under endoscopic ultrasound guidance can be used.<sup>25</sup>

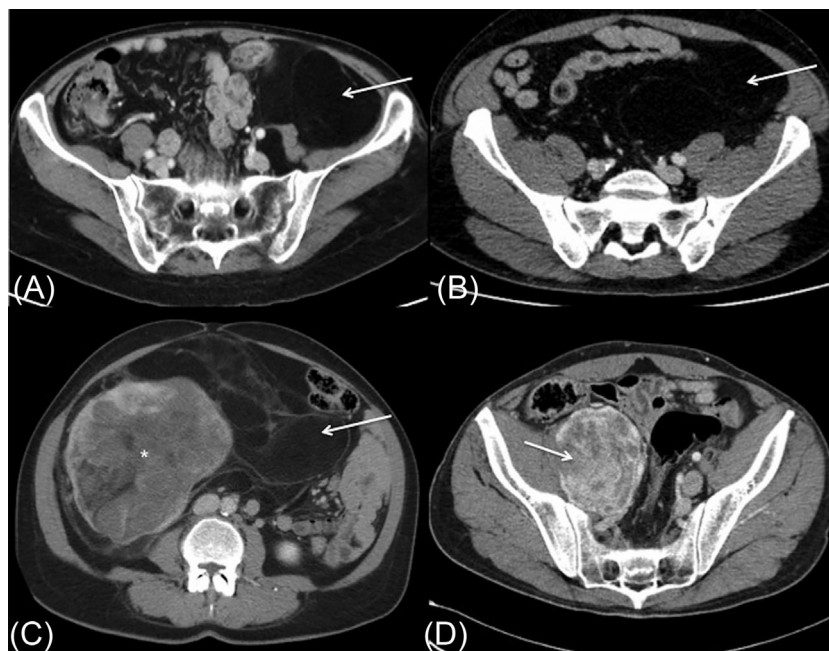
Grading of STS is one of the most important prognostic factors. Although grading of most adult STS on biopsies correlates highly with the final grading on the excision specimen, it should be noted that for leiomyosarcomas there is a grade difference of 68%, all cases showing an increase in grade from biopsy to excision specimen.<sup>26</sup>

## 4 | DIFFERENTIAL DIAGNOSIS

The most frequent sarcoma subtypes in the retroperitoneum in adults over 55 are well-differentiated liposarcoma (WDL) and dedifferentiated liposarcoma (DDL) (40%) and leiomyosarcoma (LMS) (27%). In younger age groups leiomyosarcoma supercedes liposarcoma.<sup>8</sup> Other less common subtypes occurring in the retroperitoneum include solitary fibrous tumor (SFT), undifferentiated pleomorphic sarcoma (UPS), malignant peripheral nerve sheath tumor, synovial sarcoma, and extraosseous Ewing's sarcoma. However, because soft tissue sarcoma accounts for only a third of retroperitoneal tumors, other diagnoses must be considered.<sup>7,27</sup>

Although retroperitoneal sarcomas are rare, the majority (70%) are liposarcomas and therefore interrogation of a retroperitoneal mass should begin with a search for the presence of abnormal fat (Figure 1). Sometimes the fat containing mass originates from the kidney or adrenal leading to a diagnosis of renal angiomyolipoma (AML) or adrenal myelolipoma (ML) respectively (Figure 2). The presence of renal cortical defects and prominent vessels strengthens diagnosis of the AML<sup>27,28</sup> and adrenal ML tend to be more well defined than RP liposarcoma, with a frosted glass aspect which is related to the bone marrow inside the fat. If the lipomatous mass is not clearly arising from the solid abdominal viscera the diagnosis of retroperitoneal liposarcoma should be considered and referral to a soft tissue sarcoma unit made where percutaneous biopsy will be performed. Expansile macroscopic fat external to the solid abdominal viscera is highly suspicious for well differentiated liposarcoma and the presence of solid enhancing elements suggests dedifferentiation. Calcifications can be present and can indicate dedifferentiation and poor prognosis or may represent sclerosing or inflammatory variants of WDL.<sup>29,30</sup> Although rare in the retroperitoneum, benign fat-containing extragonadal dermoids, hibernomas, extramedullary haematopoiesis, and lipomas can also mimic RP liposarcomas. Therefore biopsy must always be performed (Figure 1).

The presence of fat is not always clear and a careful search is essential. Failure to recognize the presence of abnormal fat is the commonest reason for misdiagnosis and mismanagement. If the well differentiated component is not recognized incomplete resection may result which deprives the patient of curative surgery. Furthermore,



**FIGURE 1** Spectrum of retroperitoneal lipoma and liposarcoma appearances on contrast enhanced CT. Although rare, retroperitoneal lipoma can be seen as a relatively bland retroperitoneal mass (A, arrow). This appearance is not dissimilar to the bland fat density appearance of a well differentiated liposarcoma (B, arrow) and therefore biopsy is essential to confirm the diagnosis. Areas of differentiation appear as solid areas (C, \*) which can sometimes be seen within areas of well differentiated tumor (C, arrow). Occasionally the whole mass can be dedifferentiated with no macroscopic fat evident (D, arrow)

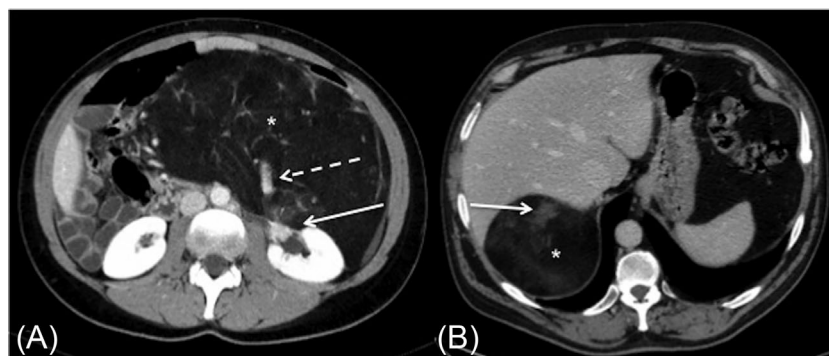
several foci of dedifferentiation can be misinterpreted as multifocal disease contraindicating surgery or leading to piecemeal resection, however in reality this is usually separate foci of dedifferentiation within a single contiguous liposarcoma with well differentiated elements between the solid masses. This is treated as unifocal disease.<sup>24</sup>

Absence of macroscopic fat in a retroperitoneal mass does not exclude a diagnosis of RP liposarcoma. This may represent disease that has dedifferentiated throughout or a sclerosing subtype.

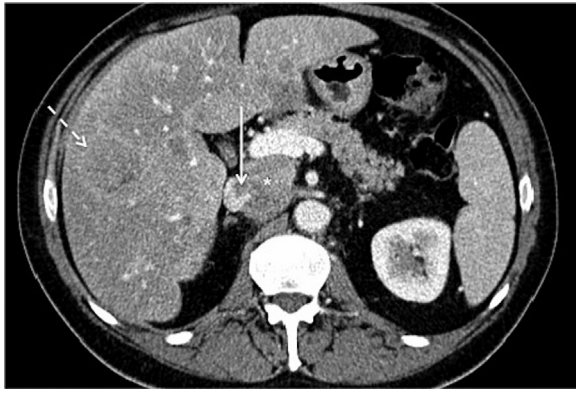
The presence of a large, heterogeneously enhancing, necrotic retroperitoneal mass contiguous with a vessel is highly suggestive of a venous LMS which is the second most common sarcoma encountered

in the RP (Figure 3). These usually arise from the IVC below the level of the hepatic veins but they do also arise from smaller vessels such as the renal veins or less commonly the gonadal veins.<sup>31</sup> They commonly have an exophytic component, which can make differentiation from extrinsic compression challenging.

A previous history of malignancy or positive serum markers may suggest a diagnosis of metastatic adenocarcinoma, melanoma or germ cell tumor. Testicular ultrasound and serum markers can also be considered in younger male patients with indeterminate retroperitoneal mass lesions. Clinical history or urinary catecholamine measurements may suggest extra-adrenal pheochromocytoma. Although rare, retroperitoneal fibrosis may also be considered especially where there is symmetrical ureteric involvement. With the rare exception of epithelioid



**FIGURE 2** Contrast enhanced CT appearances of retroperitoneal liposarcoma mimics. If a fat density retroperitoneal mass is associated with a renal cortical defect (A, arrow) and prominent vessels (A, dashed arrow) renal angiomyolipoma should be considered. Suprarenal fatty masses (B, arrow) with ground glass changes (B,\*) may represent an adrenal myelolipoma

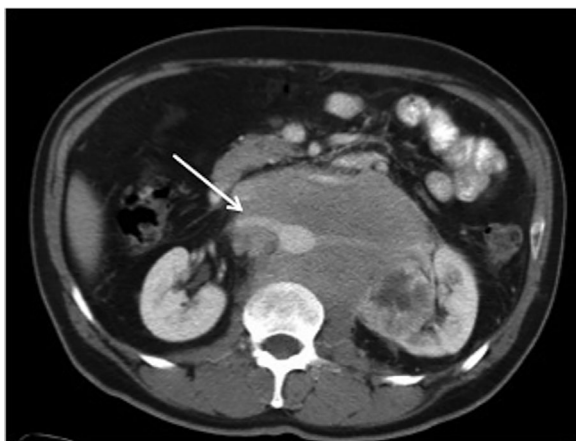

**FIGURE 3** Contrast enhanced CT of a leiomyosarcoma of the inferior vena cava. Both an intraluminal (arrow) and exophytic component (\*) are evident. Hepatic metastases (dashed arrow) are also seen

sarcomas, rhabdomyosarcomas and clear cell sarcomas, sarcomas almost never spread to lymph nodes. Therefore the presence of lymph nodes should raise the possibility of an alternative diagnosis such as metastatic disease or lymphoma. Retroperitoneal lymphoma has classic imaging appearances of a homogeneous mass which encases and displaces rather than effaces vessels (Figure 4).

The finding of a large, well circumscribed solid, vascular tumor, particularly with prominent feeding vessels should introduce the possibility of solitary fibrous tumor (Figure 5). Lipomatous hemangiopericytoma is a subtype of SFT that contains fat.<sup>32</sup>

Benign nerve or nerve sheath tumors are also encountered in the retroperitoneum. These are usually rounded and well defined but malignant peripheral nerve sheath tumor is an important differential due to its aggressive biology and poor prognosis. Frequently MPNSTs arise from neurofibromas and 50% occur in the setting of neurofibromatosis type I.<sup>32,33</sup> Clinically, pain is a classic presenting symptom in patients with MPNST. Radiologically, MPNSTs and neurofibromas may appear indistinguishable as both neurofibromas and MPNSTs may



**FIGURE 4** Contrast enhanced CT demonstrates typical appearances of retroperitoneal lymphoma. There is a bland retroperitoneal soft tissue mass which encases and displaces the renal vein (arrow) but does not efface it

contain areas of low attenuation however only MPNSTs show invasion of local structures, rapid growth, and onset of pain<sup>34</sup> (Figure 5). The characteristic dumbbell lesion that expands the intervertebral foramina is more easily diagnosed as a neurofibroma.

Some sarcoma subtypes such as synovial sarcoma typically have cystic looking elements and can be mistaken for either abscess or even haematoma. Careful interrogation for solid enhancing elements in combination with correlation with clinical history is paramount but in cases of uncertainty biopsy is essential.

## 5 | ASSESSING OPERABILITY AND MINIMUM REPORTING REQUIREMENTS

Patient selection for curative surgery should include an assessment of technical resectability, taking into account tumor biology and behavior, response to treatment and the likelihood of obtaining local tumor control weighed against morbidity of radical resection.<sup>35</sup> Full staging CT including CT thorax is required to assess for the presence of metastatic disease. This is particularly important for patients with leiomyosarcoma where up to 50% have pulmonary metastases at presentation.<sup>31</sup>

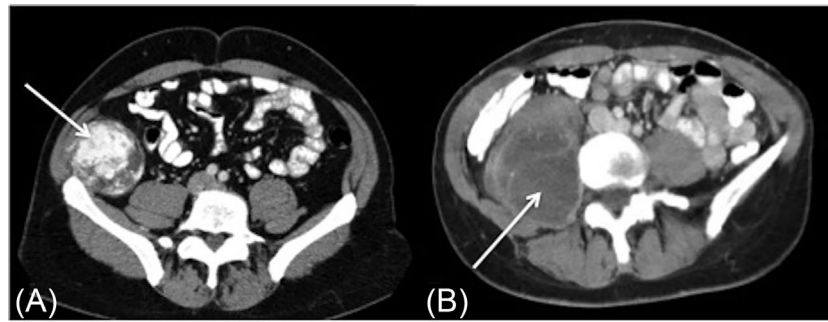
The aim of surgical resection should be to achieve a macroscopic complete R0/R1 resection and an important aspect of this is patient selection using preoperative imaging. Inadequate preoperative evaluation and planning may lead to inadequate incisions, tumor rupture, incomplete resections, and underestimation of involvement of organs, critical nerves and blood vessels resulting in excessive bleeding, or unplanned organ or nerve damage.<sup>12,13</sup>

The tumor size, location, and relationship (ie, adjacent, encasement or invasion) to adjacent viscera, parietal wall, bone, and neurovascular structures must be defined to plan for possible adjacent visceral resection. Multivisceral resection including resection of the ipsilateral kidney and adjacent hemicolon is often required and any abnormality of the contralateral kidney or involvement of the contralateral renal vein should be reported.<sup>22</sup> Multifocality is a poor prognostic sign and should be noted but should not be confused with large tumors consisting of areas of different grade, necrosis, and differentiation.<sup>35</sup>

Common causes for nonresectability or contraindications to resectability are bilateral renal involvement, metastases, encasement of the celiac axis, porta hepatis, and superior mesenteric vessels or extensive involvement of bone or spinal cord.<sup>24</sup> For IVC leiomyosarcomas specifically, the extent of inferior vena cava involvement and relationship to the renal and retrohepatic veins and any intraluminal component must also be described. Lumbar vessels and collateral veins in the retroperitoneum can be a source of significant intra-operative blood loss and should be identified on the preoperative CT scan. Compressive venous effects increase the risk for venous thromboembolism and the pulmonary artery tree should also be assessed for pulmonary embolism.

Possible extension of tumors outside the abdominal cavity through the diaphragmatic hiatus, inguinal canal, sciatic notch or obturator foramen should be described in order for surgical planning to





**FIGURE 5** Other retroperitoneal sarcoma subtypes. An avidly enhancing retroperitoneal mass (A, arrow) should raise suspicion for solitary fibrous tumor. The soft tissue mass (B) which invades psoas muscle (B, arrow) indicates the aggressive nature. This was biopsy proven malignant peripheral nerve sheath tumor

encompass the extension into an en bloc resection.<sup>24</sup> This is most commonly encountered in liposarcomas where the inguinal component can be mistaken for an inguinal hernia<sup>36</sup> (Figure 6).

## 6 | RESPONSE ASSESSMENT

### 6.1 | Assessing response to systemic therapy

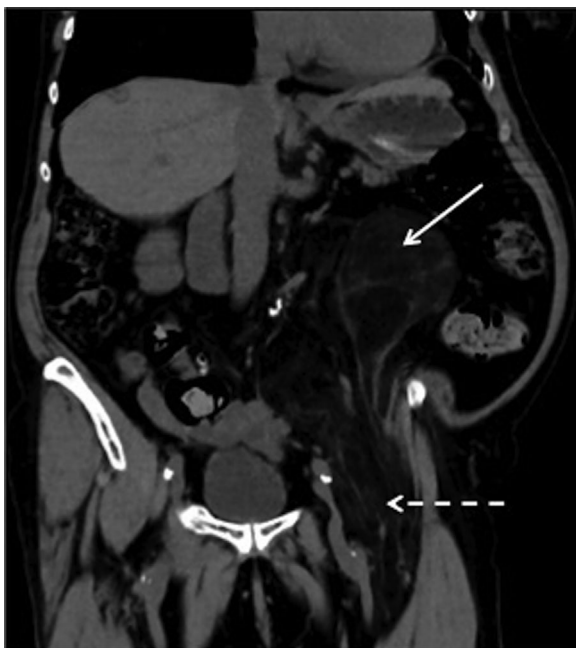Conventionally response to systemic treatment is evaluated by Response Evaluation Criteria in Solid Tumors 1.1<sup>37</sup> which is based on size measurements. Where the sarcoma subtype in question is liposarcoma it is important that the dedifferentiated elements are selected as target lesions for measurement as well differentiated elements would not be expected to change on treatment.

However for some time it has been recognized that size is not an accurate reflection of tumor activity. In the abdomen this is

widely reported in GISTs treated with imatinib where tumors can remain stable or even increase in size despite reduction in FDG uptake on FDG PET/CT.<sup>38</sup> This led to the development of Choi criteria for GISTs which incorporated both size and tumor density on CT as markers of response.<sup>39</sup> More recently a pilot study has also suggested that tumor density may complement tumor size in other sarcoma subtypes.<sup>40</sup> Limitations of tumor size measurements has led to some pilot studies of FDG PET/CT and several show promising results although large scale evidence is challenging in this rare and heterogeneous group of tumors. Diffusion weighted MRI which is a simple, robust and non-invasive technique has also been shown to detect and quantify early treatment in many tumor types but has not yet been proven in RPS although trials are underway.<sup>41</sup>

### 6.2 | Assessing response to radiotherapy

Currently imaging of the primary tumor during and immediately post radiotherapy should be avoided as the complex imaging features in this setting can be misleading. Although in future the need for imaging in the early post RT setting may change to guide adaptive radiotherapy, presently imaging should be performed as close to the surgical date as possible and most clinical protocols suggest an interval for surgery of 4-6 weeks following RT. Histopathological changes including necrosis, cystic change, haemorrhage, hyalinization, and fibrosis which occur following RT may cause tumors to increase in size resulting in pseudoprogression. With the exception of myxoid liposarcomas significant dimensional radiologic responses after preoperative RT are rare and have been reported as low as 0%.<sup>41-43</sup> Miki et al<sup>44</sup> showed that 31% of tumors increased in size by more than 10% but this was not associated with deterioration in local recurrence free survival, event free survival or overall survival. Look et al<sup>45</sup> failed to show any correlation with RECIST and outcome measures and demonstrated that tumors could show significant reductions in size despite demonstrating predominantly viable tumor whereas stable or growing tumors could show dramatic histopathological response. Therefore with the exception of myxoid liposarcomas, size, and volume measurements should not be used alone to reflect histopathological response.



**FIGURE 6** Coronal CT demonstrates a left sided well differentiated retroperitoneal liposarcoma (arrow) with extension into the inguinal canal (dashed arrow)

The excellent tissue characterization capabilities of MRI make this a very attractive tool for imaging response to radiotherapy with the additional benefit of good anatomical detail. However it is important to assess signal characteristics from multiple MRI sequences in combination. For example diminished enhancement and reduction in size of restricted components/rising Apparent Diffusion Coefficient (ADC) on DWI may be interpreted as response.<sup>41</sup> Areas of new enhancement should be interpreted with caution as this can arise secondary to vascular disruption following radiotherapy and does not necessarily reflect progression. Areas reducing in ADC can reflect hemorrhage, and T1 and T2W MRI interpreted in combination can confirm the presence of blood products

## 7 | FOLLOW UP IMAGING

Follow up imaging is guided by histology. For example surveillance CT of the thorax is not usually necessary for patients with well differentiated liposarcoma. For more aggressive sarcomas however, following resection, surveillance with contrast-enhanced CT of the chest, abdomen, and pelvis is useful for detection of local recurrence or metastatic disease because recurrence on imaging may predate symptomatic recurrence by years. General consensus suggests an interval for follow up of every 3-6 months for the first 5 years followed by annual imaging thereafter. As risk of recurrence does not plateau, follow up should be at least 10 years or even indefinite.<sup>8</sup> Particularly for younger patients where the radiation risks from multiple CT examinations might cause concern, follow up can be performed with MRI of the abdomen and pelvis with low dose CT thorax.<sup>46,47</sup> Recurrences can be difficult to detect particularly if they are of small volume fat attenuation or associated with loops of bowel and for liposarcomas any new fat densities or changes in fat attenuation should be regarded with suspicion.<sup>47</sup> MRI or depending on sarcoma subtype FDG PET/CT, can be used to clarify indeterminate contrast enhanced CT. At recurrence both the extent and rate of progression are essential to inform management decisions.<sup>48</sup>

## 8 | NEW DEVELOPMENTS

Medical imaging is an established tool for RPS diagnosis, staging, and response assessments. Imaging provides a non-invasive global view of tumor, which includes heterogeneity. Conversely, tumor biopsies, which are invasive, are limited in sampling only a small volume of tumor. To date, the definition of "imaging phenotype" and its relationship with other tumor features such as genotype and response to treatment have been poorly explored, thus limiting integration of imaging into precision medicine pathways. Although, these imaging data are readily available and routinely acquired for most patients, failure to fully understand how they relate to tumor biology represents a missed opportunity for image based theranostics.

"Radiomics" describes the activity of extracting "features" from images that can be quantified, and then searching for correlations between these features and clinical variables of interest. Imaging

features can thus be quantified and integrated into risk stratification.

Automated extraction of radiomic features from standard imaging have potential for increased diagnostic accuracy and prediction of clinical outcomes and improved accuracy compared with the established clinical risk models in patients with retroperitoneal sarcoma but this has yet to be explored. Radiomics studies in other tumor types have shown extremely promising results. Radiomic data extracted from CT images of lung tumors have been linked with prognosis, local control, and distant metastases. Radiomic features from Glioblastoma Multiforme tumors have been associated with semantic features and with survival and molecular subgroups.<sup>49</sup>

Although multiparametric MRI is also likely to be extremely informative in RPS its translation into routine practise had been hindered by time consuming and sometimes complex analysis. Data informatics and Machine Learning techniques can be used to manage and analyse large data sets and to present the data in a clinically meaningful manner. For example 3-D tumor models depicting and quantifying tumor heterogeneity and response can be used for radiotherapy planning, adaptive regimens and response assessments.

The combination of radiology expertise and advanced computational science holds vast potential for improving the lives of patients with cancer.


## 9 | CONCLUSION

Although RPS are rare, the most common subtypes LPS (70%) and LMS (15%) have characteristic imaging appearances. Therefore, recognition of abnormal fat in the retroperitoneum is most helpful for the diagnosis of the most common RPS which is liposarcoma, and masses originating from vessels may indicate the second most common subtype leiomyosarcoma. However because of the spectrum of pathologies which can occur in the retroperitoneum biopsy in liaison with a specialized soft tissue sarcoma centre should always be performed. It is essential that patients with suspected RPS are referred as early as possible to a high-volume sarcoma centre where they can be diagnosed and treated using a multidisciplinary team approach.

## ACKNOWLEDGMENT

Christina Messiou is supported by NHS funding to the NIHR Biomedical Research Centre at The Royal Marsden Hospital London, UK.

## ORCID

Christina Messiou  <http://orcid.org/0000-0002-0557-9379>

## REFERENCES

1. Bonvalot S, Rivoire M, Castaing M, et al. Primary retroperitoneal sarcomas: a multivariate analysis of surgical factors associated with local control. *J Clin Oncol*. 2009;27:31-37.

2. Morosi C, Stacchiotti S, Marchianò A, et al. Correlation between radiological assessment and histopathological diagnosis in retroperitoneal tumors: analysis of 291 consecutive patients at a tertiary reference sarcoma center. *Eur J Surg Oncol*. 2014;40:1662–1670.
3. Mullinax JE, Zager JS, Gonzalez RJ, et al. Current diagnosis and management of retroperitoneal sarcoma. *Cancer Control*. 2011;18:177–187.
4. Bonvalot S, Miceli R, Berselli M, et al. Aggressive surgery in retroperitoneal soft tissue sarcoma carried out at high-volume centers is safe and is associated with improved local control. *Ann Surg Oncol*. 2010;17:1507–1514.
5. Gronchi A, Lo Vullo S, Fiore M, et al. Aggressive surgical policies in a retrospectively reviewed single-institution case series of retroperitoneal soft tissue sarcoma patients. *J Clin Oncol*. 2009;27:24–30.
6. Gronchi A, Miceli R, Colombo C, et al. Frontline extended surgery is associated with improved survival in retroperitoneal low- to intermediate-grade soft tissue sarcomas. *Ann Oncol*. 2012;23:1067–1073.
7. Strauss DC, Hayes AJ, Thway K, et al. Surgical management of primary retroperitoneal sarcoma. *Br J Surg*. 2010;97:698–706.
8. Trans-Atlantic RPSWG. Management of primary retroperitoneal sarcoma (RPS) in the adult: a consensus approach from the Trans-Atlantic RPS Working Group. *Ann Surg Oncol*. 2015;22:256–263.
9. Anaya DA, Lahat G, Wang X, et al. Establishing prognosis in retroperitoneal sarcoma: a new histology-based paradigm. *Ann Surg Oncol*. 2009;16:667–675.
10. Anaya DA, De Lev, Pollock RE. The role of surgical margin status in retroperitoneal sarcoma. *J Surg Oncol*. 2008;98:607–610.
11. Brennan MF. Local recurrence in soft tissue sarcoma: more about the tumor, less about the surgeon. *Ann Surg Oncol*. 2007;14:1528–1529.
12. Gutierrez JC, Perez EA, Moffat FL, et al. Should soft tissue sarcomas be treated at high-volume centers? An analysis of 4205 patients. *Ann Surg*. 2007;245:952–958.
13. Hassan I, Park SZ, Donohue JH, et al. Operative management of primary retroperitoneal sarcomas: a reappraisal of an institutional experience. *Ann Surg*. 2004;239:244–250.
14. Lehnert T, Cardona S, Hinz U, et al. Primary and locally recurrent retroperitoneal soft-tissue sarcoma: local control and survival. *Eur J Surg Oncol*. 2009;35:986–993.
15. Tirkes T, Sandrasegaran K, Patel AA, et al. Peritoneal and retroperitoneal anatomy and its relevance for cross-sectional imaging. *Radiographics*. 2012;32:437–451.
16. Federle MP, Rosado de Christenson ML, Woodward PJ, Abbott GF, Shaaban AM. Retroperitoneum. Osborn, editor *Diagnostic and Surgical Imaging Anatomy: Chest, Abdomen, Pelvis*. Salt Lake City, UT: Amirsys; 2006:p 400.aaa
17. White LM, Wunder JS, Bell RS, et al. Histological assessment of peritumoral edema in soft tissue sarcoma. *Int J Radiat Oncol Biol Phys*. 2005;61:439–445.
18. Ioannidis JPA, Lau J. 18 F-FDG for the diagnosis and grading of soft-tissue sarcoma: a meta-analysis. *J Nucl Med*. 2003;44:717–724.
19. Tateishi U, Yamaguchi U, Seki K, Terauchi T, Arai Y, Hasegawa T. Glut-1 expression and enhanced glucose metabolism are associated with tumour grade in bone and soft tissue sarcomas: a prospective evaluation by <sup>18</sup>F-fluorodeoxyglucose positron emission tomography. *Eur J Nucl Med Mol Imaging* 2006;33:683–691.
20. Treglia G, Taralli S, Bertagna F, et al. Usefulness of Whole-Body Fluorine-18-Fluorodeoxyglucose positron emission tomography in patients with neurofibromatosis type 1: a systematic review. *Radiol Res Pract*. 2012;1–9.
21. Rodriguez-Alfonso B, Rasilla J, Casanovas M, et al. 18F-FDG-PET-CT in soft tissue sarcomas: when to image? *Rev Esp Med Nucl Imagen Mol*. 2014;33:43–49.
22. Miah AB, Hannay J, Benson C, et al. Optimal management of primary retroperitoneal sarcoma: an update. *Expert Rev Anticancer Ther*. 2014;14:565–579.
23. Wilkinson MJ, Martin JL, Khan AA, Hayes AJ, Thomas JM, Strauss DC. Percutaneous core needle biopsy in retroperitoneal sarcomas does not influence local recurrence or overall survival. *Ann Surg Oncol*. 2015;853–858.
24. Bonvalot S, Raut CP, Pollock RE, et al. Technical considerations in surgery for retroperitoneal sarcomas: position paper from E-surg, a master class in sarcoma surgery, and EORTC-STBSG. *Ann Surg Oncol*. 2012;19:2981–2991.
25. Sofi AA, Thekdi AD, Nawras A. EUS-FNA for the diagnosis of retroperitoneal primitive neuroectodermal tumor. *Diagn Ther Endosc*. 2011;2011:198029. <https://doi.org/10.1155/2011/198029>. Epub 2011 Apr 6.
26. Schneider N, Strauss DC, Smith MJ, et al. The adequacy of core biopsy in the assessment of smooth muscle neoplasms of soft tissues: implications for treatment and prognosis. *Am J Surg Pathol*. 2017;41:923–931.
27. Messiou C, Moskovic E, Vanel D, et al. Primary retroperitoneal soft tissue sarcoma: imaging appearances, pitfalls and diagnostic algorithm. *Eur J Surg Oncol*. 2017;43:1191–1198.
28. Katabathina VS, Vikram R, Nagar AM, et al. Mesenchymal neoplasms of the kidney in adults: imaging spectrum with radiologic-pathologic correlation. *Radiographics*. 2010;30:1525–1540.
29. Craig WD, Fanburg-Smith JC, Henry LR, et al. Fat-containing lesions of the retroperitoneum: radiologic-pathologic correlation. *Radiographics*. 2009;29:261–290.
30. Lahat G, Madewell JE, Anaya DA, et al. Computed tomography scan-driven selection of treatment for retroperitoneal liposarcoma histologic subtypes. *Cancer*. 2009;115:1081–1090.
31. Ganeshalingam S, Rajeswaran G, Jones RL, et al. Leiomyosarcomas of the IVC: diagnostic features on cross-sectional imaging. *Clin Radiol*. 2011;66:50–56.
32. Wignall O, Moskovic E, Thway K, Thomas M. Solitary fibrous tumours of the soft tissues: review of the imaging and clinical features with histopathologic correlation. *Am J Roentgenol*. 2010;195:W55–W62.
33. Danid NL, Hiroko O, Otmar DW, et al. WHO classification of tumors—pathology and genetics of tumors of the nervous system; 4th Edition. WHO. 2007:160.
34. Hrehorovich P, Franke H, Maximin S, Caracta P. Malignant peripheral nerve sheath tumor. *Am J Roentgenol*. 2003;23:790–794.
35. Gronchi A, Strauss DC, Miceli R, et al. Variability in patterns of recurrence after resection of primary retroperitoneal sarcoma (RPS): a report on 1007 patients from the multi-institutional collaborative RPS working group. *Ann Surg*. 2016;263:1002–1009.
36. Ap Dafydd D, Messiou C, Thway K, et al. Paratesticular sarcoma: typical presentation, imaging features, and clinical challenges. *Urology*. 2017;100:163–168.
37. Eisenhauer EA, Therasse P, Bogaerts J, et al. New response evaluation criteria in solid tumours: revised RECIST guideline (version 1.1). *Eur J Cancer*. 2009;45:228–247.
38. Choi H, Charnsangavej C, Faria S, et al. CT evaluation of the response of gastrointestinal stromal tumours after imatinib mesylate treatment: a quantitative analysis correlated with FDG PET findings. *Am J Roentgenol*. 2004;183:1619–1628.
39. Choi H, Charnsangavej C, Faria SC, et al. Correlation of computed tomography and positron emission tomography in patients with metastatic gastrointestinal stromal tumor treated at a single institution with imatinib mesylate: proposal of new computed tomography response criteria. *J Clin Oncol*. 2007;25:1753–1759.
40. Stacchiotti S, Verderio P, Messina A, et al. Tumor response assessment by modified Choi criteria in localized high-risk soft tissue sarcoma treated with chemotherapy. *Cancer*. 2012;118:5857–5866.

41. Messiou C, Bonvalot S, Gronchi A, et al. Evaluation of response after pre-operative radiotherapy in soft tissue sarcomas; the european organization for research and treatment of cancer – soft tissue and bone sarcoma group (eortc-stbsg) and imaging group recommendations for radiological examination and reporting with an emphasis on magnetic resonance imaging. *Eur J Cancer*. 2016;56:37–44.
42. Roberge D, Skamene T, Nahal A, et al. Radiological and pathological response following pre-operative radiotherapy for soft-tissue sarcoma. *Radiother Oncol*. 2010;97:404–407.
43. Canter RJ, Martinez SR, Tamurian RM, et al. Radiographic and histologic response to neoadjuvant radiotherapy in patients with soft tissue sarcoma. *Ann Surg Onc*. 2010;17:2578–2584.
44. Miki Y, Ngan S, Clark JCM, et al. The significance of size change of soft tissue sarcoma during preoperative radiotherapy. *Eur J Surg Oncol*. 2010;36:678–683.
45. Look Hong NJ, Hornicek FJ, Harmon DC, et al. Neoadjuvant chemoradiotherapy for patients with high-risk extremity and truncal sarcomas: a 10-year single institution retrospective study. *Eur J Cancer*. 2013;49:875–883.
46. Brenner DJ, Hall EJ. Computed Tomography- an increasing source of radiation exposure. *N Engl J Med*. 2007;357:2277–2284.
47. Kim EY, Kim SJ, Choi D, et al. Recurrence of retroperitoneal liposarcoma: imaging findings and growth rates at follow-up CT. *Am J Roentgenol*. 2008;191:1841–1846.
48. Swallow C. Management of recurrent retroperitoneal sarcoma (RPS) in the adult. A consensus approach from the Trans-Atlantic RPS Working Group (TARPSWG). *Ann Surg Onc*. 2015;22:256–263.
49. Aerts H. The potential of radiomic based phenotyping in precision medicine. *JAMA Oncology*. 2016;2:1636–1642.

**How to cite this article:** Messiou C, Morosi C. Imaging in retroperitoneal soft tissue sarcoma. *J Surg Oncol*. 2018;117:25–32. <https://doi.org/10.1002/jso.24891>