

Report on a rare single coronary artery anomaly: Need for comprehensive investigations

Rishi Tuhin Guria¹, Utkarsh Gupta¹

¹Department of Medicine, Rajendra Institute of Medical Sciences, Ranchi, Jharkhand, India

ABSTRACT

Single coronary artery anomaly (SCAA) is a very rare disorder with an incidence of about 0.024%–0.066% which presents with the diverse feature but is mostly asymptomatic. It has found to be one of the pathological states to cause sudden death. We report a case of R-III type of SCAA as classified by Lipton *et al.* which is only about 15% of all the cases of SCAA which makes it even rarer. Hypoxic environment is thought to be an important cause for the development of such anomalies which gives us clues to determine the predisposing factors to be ruled out in patient's history. Coronary angiography is the key toward definitive diagnosis which can be later supported by computed tomography scan and determination of its subtypes. Depending on the findings and physical state of the patient, medical or surgical treatment can be defined but only after correct diagnosis by comprehensive investigations.

Keywords: Computed tomography, coronary angiography, single coronary artery anomaly, sudden death

Introduction

Single coronary artery anomaly (SCAA) was first identified by Fantoni in 1699 while performing an autopsy but was antemortem identification was only possible following the advent of conventional angiography in 1967.^[1] It is among the very less frequently occurring rare anomaly in the cardiovascular system and in which a single vessel originating from a solitary ostium giving rise to the whole coronary system.^[2] The single origin site can be from either right or left sinus of Valsalva with varied presentation and distribution of the vessel and its branches.

Isolated SCAA occurs with an incidence of 0.024%–0.066% among the patients going for coronary angiography.^[2] It is rare occurrence presenting with varied distribution and branching made it necessary for a discreet classification and hence they were classified broadly in three groups described by Lipton *et al.* as follows: (1) Group I (R-I, L-I), (2) Group II (R-II-A/B/P, L-II-A/B/P), and (3) Group III (R-III) where R and L stands for

location of ostium in right or left sinus of Valsalva, respectively.^[1] These groups are sometimes further organized in mixed (M), septal (S), and combined (C) patterns.^[1] In group I, a single vessel arises from either right or left coronary cusp with terminating right or left branches after following a normal course whereas in group II the right coronary artery (RCA) as well as left coronary artery (LCA) together arises from either right or left coronary sinus, i.e., here, the contralateral vessel are formed too.^[1,2] In Group II, the alphabets A is used if aberrant artery is anterior to pulmonary trunk, B if the aberrant artery courses between aorta and pulmonary trunk and P if it is posterior to aortic trunk.^[1] If a single trunk arises from right cusp and left anterior descending (LAD) and left circumflex (LCx) artery arises from the proximal part of the trunk with the absence of LCA, then it is R-III type of SCAA.^[1,2]

Patients may or may not have associated cardiac abnormalities, but association affects the prognosis in them.^[3] They are usually asymptomatic and are detected accidentally during coronary angiography but sometimes they present with angina and syncope or may rarely lead to sudden cardiac death as

Address for correspondence: Dr. Utkarsh Gupta, Apex House, Lower Boreya Road, Arsande, Kanke, Ranchi - 834 006, Jharkhand, India. E-mail: utkarshgupta.neuro@gmail.com

Access this article online

Quick Response Code:



Website:
www.jfmpc.com

DOI:
10.4103/2249-4863.220013

This is an open access article distributed under the terms of the Creative Commons Attribution-NonCommercial-ShareAlike 3.0 License, which allows others to remix, tweak, and build upon the work non-commercially, as long as the author is credited and the new creations are licensed under the identical terms.

For reprints contact: reprints@medknow.com

How to cite this article: Guria RT, Gupta U. Report on a rare single coronary artery anomaly: Need for comprehensive investigations. J Family Med Prim Care 2017;6:424-6.

well.^[3,4] Considering various other factors such patients are given symptomatic medicinal treatment or are opted for the surgical management through procedure such as coronary artery bypass grafting (CABG) or transpositioning of aberrant artery to its respective sinus of Valsalva.^[4] It is important for a thorough line of investigation and clinical examination to rule out such anomalies as they can turn out to be serious medical stigmas. Keeping these in mind, we report a case of SCAA of type R-III.

Case Report

A 30-year-old female had an episode of chest pain which lasted for 13 h which was associated with few episodes of vomiting. Following that she complained of chest heaviness, dyspnea on exertion and sweating for about 3–4 h in an on and off pattern. After 5 days of first episode of chest pain, she again suffered from chest pain, feeble pulse, and cool periphery. Immediate electrocardiogram (ECG) showed ST depression in V1–V4 and was suspected for possible anterior wall myocardial infarction. She was treated with a loading dose of antiplatelets and statins and inotropic supports (augmentin duo 625 mg × 3 days). She also had a history fever associated vomiting, but malarial parasites were negative. Conservative management with antibiotics and antimalarial was given. Following this coronary angiography was performed which showed single coronary artery origin. A month later, chest X-ray was done which showed normal study; ECG showed normal axis, 75 bpm with T inversion in lead I and lead augmented vector left (aVL). Echocardiogram showed no regional wall motion abnormalities (RWMA), good biventricular function, no mitral regurgitation, tricuspid regurgitation, pulmonary arterial hypertension, no clots, vegetation or effusion, and no mechanical complications. Coronary angiogram showed that RCA originates from the right cusp. Computed tomography (CT) with three-dimensional (3D) image reconstruction [Figure 1] was done which showed that RCA was dominant giving rise to posterior descending artery and posterior left ventricular (LV) which were free of disease. LAD and LCx arose from proximal RCA [Figure 2]. LAD showed intramyocardial course and supplies interventricular septum and apex and was free from disease. LCx is nondominant small vessel. Single vessel disease involving nondominant LCx was found. Color Doppler showed normal bilateral carotid and vertebral artery. Calcium score was zero and LV systolic function was good. She was advised to undergo a CABG and come for annual follow-up with gated spect Tc-99m sestamibi myocardial perfusion study. Till the last follow-up about 5 years since the last episode, the patient has yet not opted for CABG and normal Tc-99m myocardial perfusion study. Her current findings state the presence of single coronary artery (RCA) from right cusp which further gives LAD and LCx from its proximal part. LAD shows the presence of intramyocardial course and total occlusion of LCx.

Discussion

It was documented that a well-known professional basketball player collapsed while playing basketball even though he did not have any major clinical symptoms or pathognomonic

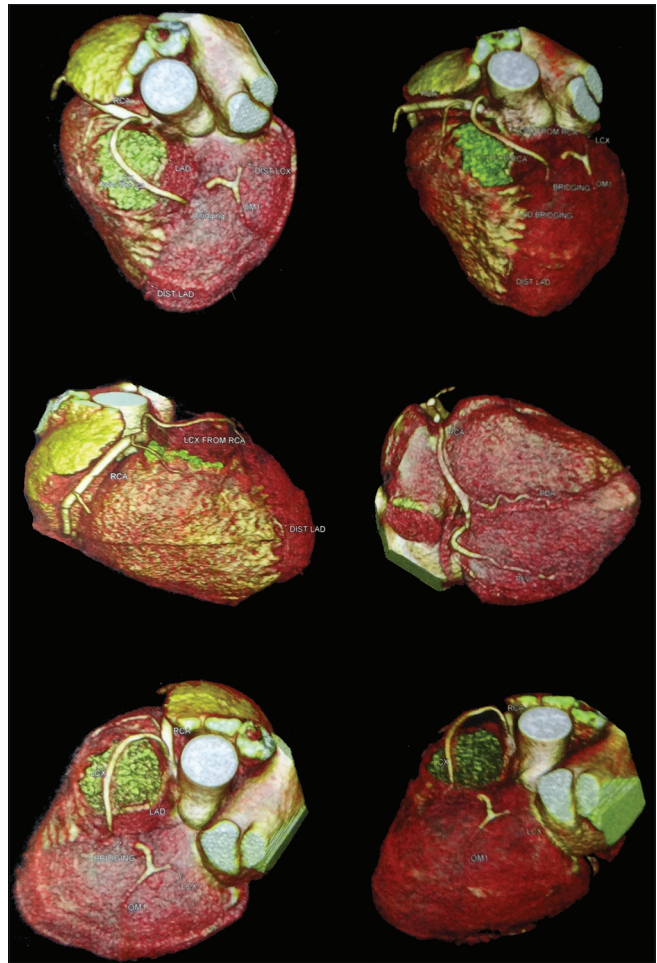


Figure 1: Three-dimensional image reconstruction from computed tomography scan showing the anomaly

feature that might have been helpful in eliciting any particular disease that might have caused it. After performing autopsy, it was found that the athlete had single coronary artery arising from right sinus of Valsalva.^[5] Among the diverse presentation of coronary anomaly, single coronary anomaly is an important rare anomaly that has been frequently associated with sudden death. There have been controversies regarding the prognosis following medical treatment or surgical treatment. Some studies have reported that there is no difference between the efficacy in medical and surgical treatment.^[6]

In a recent study done by Wikenheiser *et al.* suggested that pattern of major coronary vessels are determined by the certain template of hypoxic tissue in which the severity of hypoxia was assessed by tissues being positive for indicators such as fluorinated derivative of the 2-nitroimidazole etanidazole (EF-5) and hypoxia inducible factor-1 alpha.^[7] Smoking behavior of mother, high altitude, and an environment with a high concentration of carbon monoxide creates hypoxic stress which if present during the development of coronary vessel leads to anomalies.^[7] Prevention from exposed to such environment can be an aid to decreased incidence of such anomalies. We discussed a case of R-III type of SCAA which

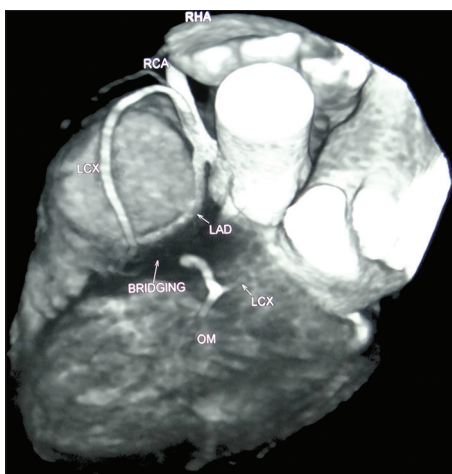


Figure 2: Single coronary artery from right sinus valsalva

has been found to be only about 15% of total cases of SCAA in other studies which is rarer than most of the other types.^[8]

The incidence of sudden death caused by SCAA prompts us to discuss on the various investigation modalities to reduce it. As most of the SCAA are asymptomatic, they are incidentally found during coronary angiography. If symptomatic, they are usually documented to have comorbidities such as hypertension and hypercholesterolemia with the presentation of atypical chest pain.^[9] The anomaly is easily visualized during this procedure and is sufficient to diagnose the anomaly. Apart from routine checkup for cardiovascular system, such as ECG, echocardiography, treadmill test, and others, we can particularly perform ventriculography to assess the functioning of ventricles which frequently comes out to be normal.^[5] After determining the anomaly, the recent advancement of diagnostic techniques such as multislice CT and 3D construction if images are highly recommended to evaluate and confirm the subtypes and definitive anomaly that is present in a patient.^[10]

Conclusion

Knowing the risk of sudden death even though the patient may be asymptomatic is what drives us to have a thorough investigation plan for individuals. With the increase in trend of unhealthy lifestyle like smoking and junk food, people are getting more and more prone to cardiovascular maladies. It is nothing but just to advise every individual to have a routine check-up at frequent intervals. Coronary angiography is a frequently done intervention giving important findings with minimal risks. Symptomatic patients are diagnosed earlier and treated medically or surgically,

but the asymptomatic patients are vulnerable to sudden death. We would suggest coronary angiography in patients with even a single predisposing factor such as mother's smoking habit, living in high altitude, other hypoxic state, or any cardiovascular comorbidity. Once diagnosed, a refined investigation like CT scan should be performed, and even though patients do not give consent for treatment as they are mostly asymptomatic, immediate medical or surgical management should be strongly suggested during their counseling giving them a detailed idea of the risks to avoid unseen heralds of such anomaly.

Financial support and sponsorship

Nil.

Conflicts of interest

There are no conflicts of interest.

References

1. Mandal S, Tadros SS, Soni S, Madan S. Single coronary artery anomaly: Classification and evaluation using multidetector computed tomography and magnetic resonance angiography. *Pediatr Cardiol* 2014;35:441-9.
2. Ozyurtlu F, Acet H, Bilik MZ, Tasal A. A rare coronary artery anomaly: Single coronary artery originate from right sinus valsalva R-IIP sub-group type. *Cardiol Res* 2012;3:140-2.
3. Sharbaugh AH, White RS. Single coronary artery. Analysis of the anatomic variation, clinical importance, and report of five cases. *JAMA* 1974;230:243-6.
4. Mohanty A. A review on 'single coronary artery'. *J Imaging Interv Radiol* 2015;1:1-3.
5. Corbett M, Powers J, King S, Quinn M, Harris D. Single coronary artery. *Images in cardiology. J Am Coll Cardiol* 2009;53:455.
6. Gersh BJ. Pathophysiology and treatment of single-vessel coronary artery disease. *Am J Cardiol* 1997;80:2f-10f.
7. Wikenheiser J, Wolfram JA, Gargasha M, Yang K, Karunamuni G, Wilson DL, *et al*. Altered hypoxia-inducible factor-1 alpha expression levels correlate with coronary vessel anomalies. *Dev Dyn* 2009;238:2688-700.
8. Turkmen S, Yolcu M, Sertcelik A, Ipek E, Dokumaci B, Batyraliev T. Single coronary artery incidence in 215,140 patients undergoing coronary angiography. *Folia Morphol (Warsz)* 2014;73:469-74.
9. Braun MU, Stolte D, Rauwolf T, Strasser RH. Single coronary artery with anomalous origin from the right sinus Valsalva. *Clin Res Cardiol* 2006;95:119-21.
10. Canbay A, Ozcan O, Aydogdu S, Diker E. Single coronary artery anomaly: A report of three cases. *Turk Kardiyol Dern Ars* 2008;36:473-5.