

## *Ab interno* suture tube occlusion of the Baerveldt glaucoma implant for management of postoperative hypotony: A case series



André S. Pollmann\*, Amit V. Mishra, Maria Gabriela Campos-Baniak, R. Rishi Gupta, Brennan D. Eadie

Department of Ophthalmology and Visual Sciences, Dalhousie University, 1276 South Park, Street, Room 2035D, 2 West Victoria Building, Halifax, Nova Scotia, B3H 2Y9, Canada

### ARTICLE INFO

#### Keywords:

Aqueous shunt  
Baerveldt glaucoma implant  
Glaucoma  
Hypotony

### ABSTRACT

**Purpose:** Delayed hypotony can be a vision threatening complication following aqueous shunt surgery in patients with glaucoma. Multiple medical and surgical management strategies have been utilized, but results have been inconsistent. The present case series describes management of delayed hypotony associated with the Baerveldt glaucoma implant (BGI) by surgically introducing 4-0 polypropylene suture into the tube lumen.

**Observations:** The cases of four patients who presented with hypotony following BGI surgery were reviewed. Following BGI tube lumen occlusion with suture, sustained intraocular pressure increase (mean 7.25 mmHg, range 4–14) was noted in all patients and visual acuity improved in three cases.

**Conclusions and importance:** This is the first report of *ab interno* suture occlusion of the BGI for management of post-operative hypotony. Further studies are required to determine the utility of this procedure, but our results suggest that in select patients, *ab interno* suture occlusion be advantageous in managing delayed hypotony refractory to medical therapy.

### 1. Introduction

The Baerveldt glaucoma implant (BGI; Abbott Medical Optics, Inc., Santa Ana, CA) is commonly employed in the surgical management of glaucoma with the goal of lowering the intraocular pressure (IOP). BGI devices are particularly useful when prior surgical interventions have failed to sufficiently lower the IOP.<sup>1</sup> These devices feature a silicone tube, which typically is inserted into the anterior chamber, that is connected to an end plate positioned underneath the conjunctiva, Tenon's capsule, and extraocular muscles. By creation of this alternate aqueous humor outflow pathway, the IOP can be effectively lowered.

The BGI, in contrast to the Ahmed glaucoma valve (AGV), is a non-valved device that allows aqueous humor to flow freely through the tube and out the device endplate. Temporary restriction of aqueous flow via tube ligation (commonly with a 7-0 Vicryl suture with or without a rip cord suture) is required at the time of BGI surgery to avoid early postoperative hypotony. After four to six weeks, a fibrous capsule has formed around the BGI end plate, preventing hypotony when the Vicryl suture dissolves and flow is initiated.<sup>2</sup>

One serious complication of BGI surgery is delayed hypotony (defined as IOP  $\leq$  5 mmHg) that can develop in 3–5% of cases when the

Vicryl suture dissolves and aqueous humor flow commences.<sup>3,4</sup> Reasons for this include varied wound healing time between patients, device over-filtration, and wound leak. Hypotony places patients at risk of vision loss due to hypotony maculopathy, choroidal effusion, suprachoroidal hemorrhage, corneal decompensation, and phthisis bulbi.<sup>4,5</sup> Unfortunately, management of delayed hypotony is challenging and there are limited effective interventions.

The following case series is, to our knowledge, the first to present the use of a 4-0 polypropylene suture for partial occlusion of the BGI lumen from an *ab interno* approach in the management of delayed hypotony following BGI insertion (Table 1).

#### 1.1. Procedure

Surgeries were performed by RG or BE for the treatment of refractory delayed hypotony following previous BGI (model BG 101–350) surgery. Variations in technique were needed based on the specific case features, such as additional surgical procedures performed, but the general steps were similar and are outlined here.

Following preparation and anesthesia (typically topical, but peribulbar anesthesia for case 2 which also required pars plana vitrectomy),

\* Corresponding author. Department of Ophthalmology & Visual Sciences, Dalhousie University, 1276 South Park Street, Room 2035D, 2 West Victoria Building, Halifax, Nova Scotia, B3H 2Y9, Canada.

E-mail address: [andre.p@dal.ca](mailto:andre.p@dal.ca) (A.S. Pollmann).

<https://doi.org/10.1016/j.ajoc.2020.100752>

Received 22 April 2020; Received in revised form 12 May 2020; Accepted 20 May 2020

Available online 30 May 2020

2451-9936/© 2020 The Authors. Published by Elsevier Inc. This is an open access article under the CC BY-NC-ND license

(<http://creativecommons.org/licenses/by-nc-nd/4.0/>).

**Table 1**

Summary of demographics and results of four patients with Baerveldt glaucoma implant-related hypotony who were treated with suture occlusion of the aqueous shunt tube lumen. BCVA, best-corrected visual acuity; HM, hand motion; IOP, intraocular pressure.

	Case 1	Case 2	Case 3	Case 4
Age	70	83	66	80
Sex	Female	Female	Male	Male
Glaucoma type	Pseudoexfoliation	Pseudoexfoliation	Aniridia	Pseudoexfoliation
Additional combined surgical procedures	None	Vitreotomy, intraocular lens exchange, drainage of choroidal effusions	None	None
Pre-operative BCVA	20/200-1	20/400	HM	20/60-2
Last post-operative BCVA	20/40	20/80 + 1	HM	20/30-2
Pre-operative IOP (mmHg)	1	4	3	5
Last post-operative IOP (mmHg)	15	10	7	10
Months of follow-up	26	2	5	2
Post-operative complications	None	Vitreous hemorrhage	None	None

the BGI tube was measured with calipers from the end plate to the tube opening. A 4-0 polypropylene suture (Prolene, Ethicon Inc, Somerville, NJ) suture was then cut to the corresponding length with a tapered bevel edge on one end. Next, two paracenteses wounds were fashioned superonasally and inferonasally with a #75 micro sharp blade and the anterior chamber was filled with viscoelastic (DisCoVisc, Alcon Laboratories Inc., Fort Worth, TX). Using micrograspers, the cut 4-0 polypropylene suture was carefully fed into the lumen of the BGI tube to partially occlude it. Adjustments to the length of polypropylene suture were made, with the goal of having 0.5–1.0 mm of the suture remaining external to the tube opening, within the anterior chamber. The eye was left with a partial fill of viscoelastic material, and the incisions were hydrated and confirmed to be watertight. All IOP measurements were determined using Goldmann applanation tonometry.

## 2. Findings

### 2.1. Case 1

A 70-year-old phakic female followed for a history of progressive pseudoexfoliative glaucoma in the left eye was seen for consideration of incisional glaucoma surgery. Previous interventions in the left eye included a remote history of trabeculectomy and placement of an Ex-PRESS shunt (Alcon Laboratories Inc., Fort Worth, TX). Medical therapy consisted of brinzolamide/timolol twice daily.

The best-corrected visual acuity (BCVA) was 20/25-2 in both eyes and IOP was 23 mmHg in the right eye and 39 mmHg in the left eye. Examination of the left eye showed an open angle on gonioscopy, pseudoexfoliative material on the lens, and nuclear sclerotic cataract. The Ex-PRESS shunt was visible in the left superotemporal anterior chamber with a corresponding shallow conjunctival bleb. Posterior pole examination revealed advanced glaucomatous optic neuropathy.

Combined phacoemulsification with posterior chamber intraocular lens (IOL) implantation and aqueous shunt surgery with scleral patch graft were performed on the left eye. A BGI was placed and a single loop of 7-0 Vicryl suture was tied as a ligature around the proximal end of the tube. One month post-operatively, BCVA was 20/20 and IOP was 20 mmHg on topical therapy consisting of brinzolamide, timolol, and prednisolone twice daily.

Forty-two days post-operatively the patient presented with left eye blurred vision, pain, and subjective complaint of shimmering lights. Her BCVA was 20/30 and IOP was 4 mmHg. Slit-lamp examination showed a shallow anterior chamber, an injected conjunctival bleb, and 3+ anterior chamber cells. Topical atropine and antibiotic drops were initiated, and the frequency of prednisolone drops was increased to every 2 h while awake. Topical glaucoma therapy was discontinued. Four days later, exam showed visual acuity of 20/400, IOP of 2 mmHg, persistent shallow anterior chamber, and the development of inferior and nasal choroidal effusions.

On post-operative day 62, the BGI was revised with a ligature of 7-0 Vicryl suture around the tube lumen and the anterior chamber was

reformed with viscoelastic. On post-operative day one, BCVA was 20/100 and IOP was 11 mmHg. However, by post-operative day seven, the IOP had again decreased to 1 mmHg. Although the choroidal effusions had resolved, choroidal folds around the optic nerve and macula were noted. There was no evidence of bleb leak. A clinical diagnosis of hyperfiltration and hypotony maculopathy was made and frequent prednisolone therapy continued. Over the subsequent two weeks, vision and IOP did not improve.

Thirty days following attempted revision, the patient was taken to the operating room to occlude the BGI shunt lumen with 4-0 polypropylene suture. On post-operative day one the BCVA was 20/60 and IOP was 21 mmHg, with a formed anterior chamber. On post-operative days 10 and 22, BCVA remained stable at 20/60 and IOP measured 9 mmHg on both days. At last follow-up, 26 months following BGI shunt occlusion, the suture remained inside the tube lumen. The BCVA measured 20/40 and IOP was 15 mmHg, with examination showing resolved choroidal folds but some retinal pigment epithelial hyperpigmentation in keeping with sequelae of hypotony maculopathy.

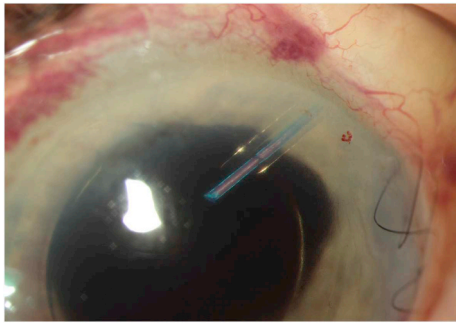
### 2.2. Case 2

An 83-year-old phakic woman with a history of bilateral advanced pseudoexfoliative glaucoma was referred for consideration of glaucoma surgery after treatment with maximum medical therapy and repeated laser trabeculectomy failed to sufficiently lower her IOP. Topical medications were travoprost and timolol/brimonidine. Her ocular history was significant for bilateral non-granulomatous anterior uveitis, for which previous systemic investigations had been negative. Medical history was significant for cognitive impairment secondary to dementia.

Examination showed BCVA of 20/40 and 20/60 and IOP measurements of 23 mmHg and 25 mmHg in the right and left eyes, respectively. Slit-lamp exam showed pseudoexfoliation material in the anterior segment, 2+ nuclear sclerosis of both lenses, and 3+ anterior chamber cells bilaterally. Optic nerve examination showed deep glaucomatous excavation of the optic nerves.

Due to active uveitis, the patient was started on topical prednisolone every 2 h, nightly dexamethasone ointment, and twice daily atropine. Her uveitis resolved bilaterally over a one-month period. At a follow-up visit four months later a significant decline in vision to count fingers (CF) at four feet was noted in the left eye. Her IOP had increased to 42 mmHg in the right eye and 50 mmHg in the left eye, despite ongoing topical glaucoma therapy and no prednisolone use. Given the history of intraocular inflammation BGI surgery was performed in conjunction with cataract extraction via phacoemulsification, in the left eye. The BGI tube was ligated with a 7-0 Vicryl suture. Anterior vitrectomy was required for posterior capsule rupture and a 3-piece IOL was placed in the sulcus with optic capture.

On post-operative day 28, the left eye BCVA had improved to 20/100 and the IOP was 22 mmHg, on topical travoprost, brimonidine/timolol, and prednisolone four times daily. On day 47 following BGI surgery, the patient presented with decreased vision (20/400) and



**Fig. 1.** Case 2 anterior segment slit lamp photo showing the left eye two months on post-operative following occlusion of the Baerveldt glaucoma implant tube with 4-0 polypropylene suture.

hypotony (IOP 4 mmHg) in the operated eye. Exam showed a shallow anterior chamber with fibrin, corectopia, and a tilted 3-piece IOL. B-scan ultrasonography showed large near-appositional choroidal effusions.

The patient was taken to the operating room for external drainage of choroidal effusions, 23-gauge pars plana vitrectomy, IOL exchange with placement of an anterior chamber IOL, and partial occlusion of the BGI tube with 4-0 polypropylene suture. On post-operative day one, visual acuity was hand-motions (HM) and was IOP 10 mmHg. Vitreous hemorrhage precluded the view to the posterior segment. B-scan ultrasonography did not demonstrate any evidence of retinal detachment or recurrence of choroidal detachment.

Eight days following vitrectomy and BGI tube occlusion, the patient was taken back to the operating room for management of vitreous hemorrhage with anterior chamber washout, pars plana vitrectomy, and fluid-air exchange. When examined on post-operative day seven, the air bubble had resorbed, the BCVA had improved to 20/150, and the IOP was 11 mmHg. At the last visit, 55 days following suture occlusion of the BGI tube, BCVA was 20/80 + 1 and IOP was 10 mmHg (Fig. 1). There was no recurrence of choroidal detachment.

### 2.3. Case 3

A 66-year-old man was referred for management of chronic hypotony in his only seeing right eye. Past ocular history in the right eye was significant for aniridia, glaucoma, scleral-sutured posterior chamber IOL, penetrating keratoplasty, and limbal stem cell deficiency with resultant neovascularization and scarring in the corneal graft. Additionally, a BGI had been placed 17 years prior for uncontrolled IOP.

Reduced IOP had been present for the past 13 years, with measurements documented between 5 and 8 mmHg. BCVA during this time period was stable at CF. At the time of referral to our service, vision and IOP were noted to be decreasing further and optimization of the IOP was desired in order for consideration of repeat penetrating keratoplasty. Topical medications were prednisolone drops every 2 h while awake and atropine twice daily.

The BCVA was HM at 1 m and the IOP was 3 mmHg. The anterior segment examination showed diffuse scarring and neovascularization of the corneal graft and a BGI tube was visible in the superotemporal quadrant with no tube-cornea touch noted.

The patient was brought to the operating room for occlusion of the BGI tube with 4-0 polypropylene suture. On post-operative day one, the IOP was 2 mmHg and the visual acuity was HM. Examination found a formed anterior chamber and the suture in stable position within the BGI tube lumen. One week post-operatively, the vision was HM and IOP was 7 mmHg. At the last follow-up, five months post-surgery, vision remained HM secondary to corneal graft scarring. This patient continues to be jointly followed by the cornea service for future

consideration of repeat penetrating keratoplasty.

### 2.4. Case 4

A 80-year-old pseudophakic man was referred for consideration of surgical management of pseudoexfoliative glaucoma progressing despite maximal tolerated medical therapy consisting of latanoprost and brimonidine/brinzolamide. Initial evaluation of the affected left eye showed BCVA of 20/30-2, IOP of 18 mmHg, an excavated and cupped optic nerve, and superonasal visual field loss in the central 10°.

The patient underwent left trabeculectomy with intraoperative use of mitomycin C. Although a successful conjunctival bleb formed initially following laser suture lysis, two months later the bleb flattened and IOP increased to 19 mmHg, while on topical prednisolone four times daily. Four months following trabeculectomy, internal revision with 5-fluorouracil was carried out. Six weeks later scarring of the trabeculectomy developed and the IOP remained above target at 25 mmHg on brinzolamide, latanoprost, and prednisolone once daily.

Given failure of the trabeculectomy, BGI surgery was performed without complications seven months after initial trabeculectomy. The BGI tube was ligated with 7-0 Vicryl suture. Two weeks post-operatively, the BGI tube remained ligated and BCVA was 20/30 and IOP was 21 mmHg on topical prednisolone every 2 h while awake, atropine twice daily, ofloxacin, brinzolamide, and latanoprost.

At follow-up 52 days after BGI surgery, the left eye was found to be hypotonous. Exam showed BCVA of 20/60-1, IOP of 1 mmHg, and shallow choroidal effusions. Glaucoma therapy was immediately stopped in the left eye and topical prednisolone and atropine were initiated, both instilled twice daily. The hypotony failed to resolve over two weeks with conservative medical therapy and so the patient was taken to the operating room for BGI tube occlusion with 4-0 polypropylene suture. On post-operative day one, IOP increased to 15 mmHg. At the last follow-up two months later, BCVA was 20/30-2 and IOP was 10 mmHg on topical therapy with prednisolone four times daily.

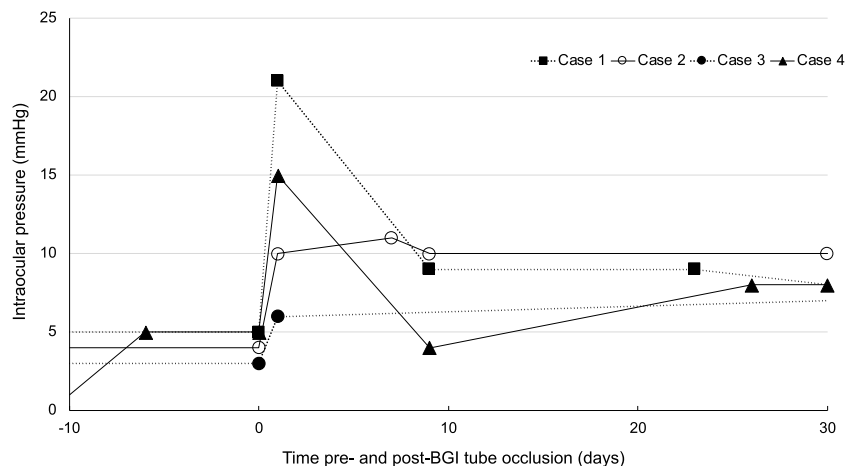
### 3. Discussion

Post-operative hypotony is a well-documented complication of aqueous shunt glaucoma surgery. The risk of post-operative delayed hypotony appears to be higher with the use of BGI compared to AGV devices.<sup>3,6,7</sup>

Several different strategies have been employed to reduce early hypotony following aqueous shunt placement. A two-staged procedure has been described, wherein the BGI end-plate is positioned first, followed by insertion of the tube into the anterior chamber four to six weeks later.<sup>8</sup> As this technique requires two surgeries, it has not gained widespread acceptance. Other methods include temporary ligation of the BGI tube with a Vicryl or nylon suture,<sup>9</sup> temporary internal tube occlusion with a suture stent,<sup>5</sup> or a combination of these methods.<sup>10,11</sup> After 4–6 weeks, the Vicryl suture has dissolved, whereas nylon sutures are removed via argon laser or a conjunctival-based office procedure to activate a “rip cord” or other releasable occluding system.<sup>12</sup> These suture ligation methods effectively mitigate early post-operative hypotony, but 3–5% of patients will develop delayed hypotony several weeks following BGI surgery when ligation sutures are no longer present.

There is a lack of clinically validated approaches for managing delayed hypotony following aqueous shunt surgery. Medical therapy with topical corticosteroids and cycloplegia may help in some cases. Surgical management options include temporarily reforming the anterior chamber with high-viscosity ophthalmic viscoelastic devices, repeating suture ligation of the BGI tube,<sup>9</sup> BGI end-plate truncation,<sup>13</sup> or complete removal of the implant. Each of these options has unique drawbacks, including imprecise effect and invasive conjunctival surgery.

Suture stent placement into aqueous shunts have also been



**Fig. 2.** Intraocular pressure measurements before and after Baerveldt glaucoma implant tube occlusion with 4-0 polypropylene suture. Trendlines are truncated at day 30.

described to help manage hypotony. One report<sup>14</sup> of two patients describes the use of a 5 mm 3-0 polypropylene suture with a single knot on one end to temporarily plug the BGI tube in the setting of unexpected hypotony during phacoemulsification, thus preventing anterior chamber collapse. Lim and Hwang<sup>15</sup> described temporary *ab interno* tube occlusion in the setting of hypotony two weeks following AGV surgery. A corneal incision was made opposite to the tube and two 5-0 nylon sutures were threaded into the tube lumen. The resulting effect on IOP was satisfactory, and the sutures were removed 30 days later.

Feinstein et al.<sup>16</sup> previously reported on management of post-operative hypotony in one patient 10 months following AGV implantation. A corneal incision was fashioned opposite the aqueous shunt, viscoelastic was injected, and a 4-0 polypropylene suture was inserted into the tube lumen and trimmed. The IOP improved from 4 mmHg pre-operatively, to 7 mmHg at 12-month follow-up, with resolution of choroidal folds and improvement in BCVA. The authors also estimated the effect of different suture sizes on IOP following occlusion of the AGV or BGI, calculating that 4-0 and 3-0 polypropylene sutures would reduce outflow facility of the aqueous shunt by 62% and 97%, respectively.

To the best of our knowledge, this is the first report of permanent *ab interno* intraluminal suture placement to manage hypotony following BGI surgery, adopting the technique previously described by Feinstein et al. for the AGV. The patients developed clinically significant hypotony on days 42, 47, and 52 following BGI surgery, with one patient (case 3) having a history of chronic hypotony following remote BGI surgery (Fig. 2). In the absence of wound leak, the time frame of hypotony onset of 42–52 days suggests inadequate formation of a capsule around the BGI end plate and subsequent hyperfiltration. Our series identified limited utility in the use of conservative, non-surgical interventions in managing hypotony, as topical corticosteroids and cycloplegics did not raise the IOP. Owing in part to patients' medical comorbidities, a trial of oral corticosteroid therapy was not used in our cohort. Following intraluminal stenting of the BGI tube, IOP improved in all four patients (mean 7.25 mmHg, range 4–14 mmHg), with results in case 1 stable at two-year follow-up. None of the patients developed complications related to tube occlusion and all sutures remained in stable position at last follow-up.

*Ab interno* suture occlusion offers several advantages over other strategies in the management of hypotony. First, it avoids removal of the BGI and an associated recurrence of elevated IOP. Second, the relatively non-invasive approach prevents further conjunctival incisions and development of scar tissue, which could complicate future

glaucoma surgeries if needed. Third, the technique is reversible and modifiable should the IOP rise too high following suture occlusion.

Several limitations of this case series should be noted. The surgical technique was not uniform across all cases, owing to unique surgical needs for each patient leading to combination procedures in one case. Our patients had complex ocular comorbidities, making it challenging to draw conclusions about the effect of this technique. In case 3, factors such as chronicity of hypotony and possible ciliary body shut down, make interpretation of the effect of BGI tube occlusion less clear. Furthermore, in case 3 the history of penetrating keratoplasty can make Goldmann applanation tonometry inaccurate, although measurements with this technique were reproducible over time. Further studies are needed to more reliably assess the outcomes of this procedure in terms of success rate and predictability of IOP response with use of different suture sizes.

## Conclusions

Intraluminal suture occlusion may be a useful surgical option for management of delayed hypotony following BGI surgery. The procedure could offer advantages over previously described methods and should be considered for management of aqueous shunt related hypotony refractive to medical therapy.

## Patient consent

Written consent to publish this case has not been obtained. This report does not contain any personal identifying information.

## Funding

No funding or grant support.

## Authorship

All authors attest that they meet the current ICMJE criteria for Authorship.

## Declaration of competing interest

The following authors have no financial disclosures: AP, AM, MC, RG, BE.

## Acknowledgements

None.

## References

1. Minckler DS, Francis BA, Hodapp EA, et al. Aqueous shunts in glaucoma: a report by the American Academy of Ophthalmology. *Ophthalmology*. 2008;115(6):1089–1098.
2. Sarkisian SR. Tube shunt complications and their prevention. *Curr Opin Ophthalmol*. 2009;20(2):126–130.
3. Christakis PG, Zhang D, Budenz DL, et al. Five-year pooled data analysis of the Ahmed Baerveldt comparison study and the Ahmed versus Baerveldt study. *Am J Ophthalmol*. 2017;176:118–126.
4. Wang Q, Thau A, Levin AV, Lee D. Ocular hypotony: a comprehensive review. *Surv Ophthalmol*. 2019;64(5):619–638.
5. Nguyen QH. Avoiding and managing complications of glaucoma drainage implants. *Curr Opin Ophthalmol*. 2004;15(2):147–150.
6. Christakis PG, Kalenak JW, Tsai JC, et al. The Ahmed versus Baerveldt study: five-year treatment outcomes. *Ophthalmology*. 2016;123(10):2093–2102.
7. Budenz DL, Barton K, Gedde SJ, et al. Five-year treatment outcomes in the Ahmed Baerveldt comparison study. *Ophthalmology*. 2015;122(2):308–316.
8. Molteno ACB, Van Biljon G, Ancker E. Two-stage insertion of glaucoma drainage implants. *Trans Ophthalmol Soc N Z*. 1979;31:17–26.
9. Stein JD, McCoy AN, Asrani S, Herndon LW, et al. Surgical management of hypotony owing to overfiltration in eyes receiving glaucoma drainage devices. *J Glaucoma*. 2009;18:638–641.
10. Latina MA. Single stage Molteno implant with combination internal occlusion and external ligature. *Ophthalmic Surg*. 1990;21(6):444–446.
11. Sharkawi E, Artes PH, Oleszczuk JD, et al. Systematic occlusion of shunts: control of early postoperative IOP and hypotony-related complications following glaucoma shunt surgery. *J Glaucoma*. 2016;25(1):54–61.
12. Moura Filho ER, Sit AJ. The use of nonabsorbable suture ligatures for glaucoma drainage devices. *Arch Ophthalmol*. 2010;128(5):624–627.
13. Chen PP. Truncation of in situ Baerveldt glaucoma drainage device for treatment of late persistent postoperative hypotony. *J Glaucoma*. 2017;26(2):e113–e114.
14. Fechter HP. Improvised 3-0 polypropylene plug for the glaucoma drainage tube during phacoemulsification. *Ophthalmic Surg Laser Imag*. 2008;39(1):86–87.
15. Lim SH, Hwang YH. Management of postoperative ocular hypotony after tube surgery by stenting using two 5-0 nylon threads. *Kor J Ophthalmol*. 2018;32(6):523–524.
16. Feinstein M, Moussa K, Han Y. Ab interno tube occlusion for postoperative hypotony in a patient with an Ahmed glaucoma drainage device. *J Glaucoma*. 2018;27(3):e61–e63.