Epilepsy & Behavior Case Reports 9 (2018) 22–25

Contents lists available at ScienceDirect

Epilepsy & Behavior Case Reports

journal homepage: www.elsevier.com/locate/ebcr

Case Report

Sub-lobar dysplasia — A comprehensive evaluation with neuroimaging, magnetoencephalography and histopathology

Kenchaiah Raghavendra [a], Ganne Chaitanya [a,b], Bhargava Goutham [a,b], Anita Mahadevan [c], Ravindranadh Chowdary Mundlamuri [a], Rose Dawn Bharath [d], Mariyappa Narayannan [a], Malla Bhaskar Rao [e], Arimappamagan Arivazhagan [e], Parthasarthy Satishchandra [a], Sanjib Sinha [a,*]

[a] Department of Neurology, National Institute of Mental Health and Neurosciences (NIMHANS), Hosur Road, Bangalore 560029, India
[b] Department of Clinical Neurosciences, National Institute of Mental Health and Neurosciences (NIMHANS), Hosur Road, Bangalore 560029, India
[c] Department of Neuropathology, National Institute of Mental Health and Neurosciences (NIMHANS), Hosur Road, Bangalore 560029, India
[d] Department of Neuroimaging and Interventional Radiology, National Institute of Mental Health and Neurosciences (NIMHANS), Hosur Road, Bangalore 560029, India
[e] Department of Neurosurgery, National Institute of Mental Health and Neurosciences (NIMHANS), Hosur Road, Bangalore 560029, India

ARTICLE INFO

Article history:
Received 17 August 2017
Received in revised form 11 November 2017
Accepted 22 November 2017
Available online 5 December 2017

Keywords:
Sublobar dysplasia
Temporal lobe epilepsy
Tractography
Magnetoencephalography
Histopathology

ABSTRACT

Sublobar dysplasia, a rare cortical malformation has been defined in only 8 patients to date. It was identified on the basis of histopathological features and MRI findings. We report a right temporal sublobar dysplasia, with detailed evaluation including neuroimaging, magnetoencephalography and histopathology to further characterize the pathology. Additional pathological features included a deep collateral sulcus in the basal right temporal lobe, thinned out right corticospinal tract, and bilateral asymmetric basal ganglia changes. Magnetoencephalograpy localized the seizure focus to the posterior margin of the dysplasia. Histopathological evaluation helped exclude other types of dysplasia. Similar to a previous study, the child had Engel 1a outcome.

© 2017 Published by Elsevier Inc. This is an open access article under the CC BY-NC-ND license (http://creativecommons.org/licenses/by-nc-nd/4.0/).

1. Introduction

Sublobar dysplasia (SLD) is a rare type of malformation of cortical development (MCD) reported in only 8 patients around the world, reportedly localized to one cerebral hemisphere or lobe and separated from the remainder of the affected lobe or hemisphere by one or more deep infolding(s) of cortex resulting in a lobe within a lobe appearance on imaging [1,2]. Debate on the developmental origin for SLD inclines more towards the possibility of a neuronal migration disorder rather than a disorder of stem cell differentiation [1,2].

We report a patient with drug resistant TLE due to SLD to highlight the detailed MRI observations, source localization of magnetoencephalography (MEG) dipoles and neuropathological findings in comparison with the previous published studies.

2. Clinical case

A 3-year, 10-month old girl presented with a history of seizures since 3 months of age. There were no perinatal complications historically. Development was normal during the first 3–5 months, followed by psychomotor developmental delay. The seizures were characterized by behavioral arrest with subsequent, extension of the left elbow and adduction at shoulder. This occurred with bilateral lower limb extension and adduction-inversion of the feet, followed by purposeless repetitive movements of the right upper limb followed by postictal weakness of left upper and lower limbs. Focal seizures would occasionally evolve to generalized motor seizures. Seizure frequency was reduced from 4 to 5/day to 1 per month on carbamazepine (15 mg/kg), valproate (28 mg/kg) and clobazam (10 mg/day). There was no history of regression of milestones, systemic comorbidities or family history of epilepsy or congenital anomalies. Examination showed apaucity of movements of left upper limbs and dragging the left foot while walking. There was atrophy and spasticity of left upper and lower limbs and mild left facial muscle weakness with brisk deep tendon reflexes on the left side.

Video-EEG telemetry showed abnormal asymmetric background activity and poorly formed right-sided alpha activity. Independent multifocal interictal discharges were seen involving the right hemisphere predominantly, anterior temporal region (F8–T6) and right lateral frontal lobe (F4–F8).

Seisures were characterized by an arrest of ongoing activity, hypomotor state followed by forced deviation of eyes to left side,

* Corresponding author at: NIMHANS, 1st Floor, Faculty Block, Hosur Road, Bangalore 560029, India.
E-mail address: sanjib_sinha2004@yahoo.co.in (S. Sinha).

https://doi.org/10.1016/j.ebcr.2017.11.002
2213-3232/© 2017 Published by Elsevier Inc. This is an open access article under the CC BY-NC-ND license (http://creativecommons.org/licenses/by-nc-nd/4.0/).

uncoordinated jerky movements of the left upper limb and adduction at right shoulder and extension at the right elbow culminating in secondary generalization. The ictal EEG changes were characterized by a build-up of low voltage fast activity over right frontal rapidly involving the right temporal electrodes. By about the mid-seizure, there were prominent spike-and-slow wave discharges of <1 Hz occurring in the right frontal region.

2.1. Neuroimaging (MRI and DTI) and magnetoencephalography (Fig. A)

MRI of brain showed dysplastic antero-medial temporal lobe separated from the rest of the temporal lobe by a deep collateral sulcus. The splenium of corpus callosum was thinner. T2W and T1W hyperintense signal changes were noted in bilateral globus pallidus and lateral thalami nuclei. T2W/FLAIR hyperintensity was noted in right parietal subcortical white mater. The right cerebral hemisphere was atrophic compared to the left, with exvacuo dilatation of the atrium and occipito-temporal horns of right lateral ventricle. Tractography showed gross atrophy of the right corticospinal tract with hyperintense changes up to the ventral nuclei of pons (Fig. A.1 and 2).

MEG showed infrequent IEDs in the right posterior temporo-occipital region. Source localisation with Equivalent Cluster Dipole (ECD) modeling showed dipoles in the right posterior temporal–occipital region at the margin of the abnormality and the deepest part of the sulcus.

2.2. Other investigations

Routine blood investigations and metabolic workup were normal. Muscle biopsy was performed to rule out mitochondrial disorders. Enzyme histochemical stains for mitochondria (succinate dehydrogenease, Cox stains) and assay for respiratory chain enzyme did not reveal any abnormality.

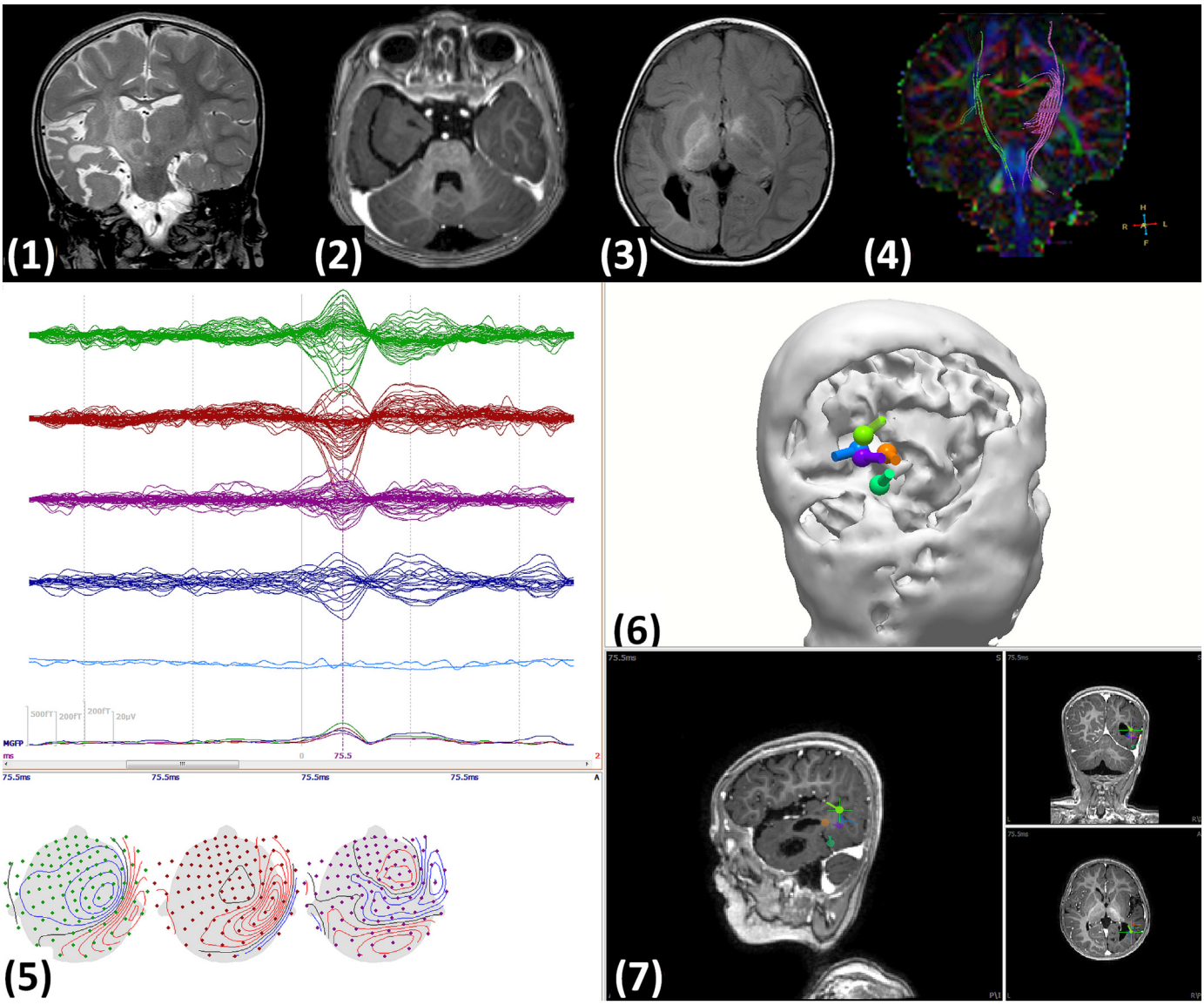

Fig. A. (1) Coronal T2W image — shows a grossly distorted right temporal lobe with a large fissure extending from the inferior surface to the medial temporal lobe. Large complex cortical dysplasia involving the right medial temporal lobe with dysplastic parenchyma separated from rest of the temporal lobe by deep collateral sulcus which bifurcates the anterior part of the temporal lobe, (2) gadolinium contrast axial images — large deep collateral sulcus dividing medial and the lateral temporal lobes, (3) T2W FLIAR axial — hemispheric asymmetry, exvacuo dilation of the ipsilateral lateral ventricle, hyper-intensity of bilateral basal ganglia and involvement of the insular region and internal capsule, (4) DTI tractography shows grossly reduced thickness of the corticospinal tracts (right CST — green, left CST — pink), (5) shows the butterfly plots of the averaged spikes in magnetometers and x and y — planar gradiometers and simultaneous scalp EEG channels, (6 & 7) shows the dipoles, obtained from the ECD modeling of the averaged IEDs, on patient's rendered structural MRI and on the planar sections. The dipoles localized to the posterior margins of the dysplasia.

2.3. Surgical planning and procedure

The epileptogenic zone was considered to be dysplastic right temporal lobe extending to preoptic notch with the sympotomatic zone localized to the right temporal lobe, the irritative zone involved the right fronto-temporal and posterior temporo-occipital regions as seen by EEG and MEG and the lesion involved the right temporal lobe. Based on this and the fact that it was the non-dominant temporal lobe, we performed a generous of right temporal lobectomy with posterior quadrant disconnection of the epileptogenic zone of the dysplastic temporal lobe extending up to the preoptic notch.

Intraoperatively, the right temporal lobe was bulky with increased surface vascularity and on corticectomy the dysplastic brain matter felt firm. The gross examination of the lobectomy specimen showed congested leptomeninges and the surface having a "Moroccan leather" appearance (Fig. B.1, *). Dysplastic parenchyma was separated from the antero-medial temporal lobe by a deep collateral sulcus. The superior and middle temporal gyri appeared to be thinned out and closely opposed to each other, without features suggestive of polymicrogyria (consistent with SLD). Subcortical gliosis and thickening of the inferior temporal gyri were noted. The hippocampus was markedly shrunken, firm, and atrophic.

Histopathology (Fig. B) evaluation showed closely opposed and atrophic gyri with shallow sulci. The cortical surface was undulating with short stubby subpial excrescences. The smooth outline of subpial zone was interrupted by small cortical excrescences with nodular heterotopic collections of neurons. The underlying cortex revealed complete dyslamination. The neurons in layers II & III were still discernible. In lower layers, an admixture of small immature granule and pyramidal neurons were seen arranged in groups or as layers beneath the gyral convolutions but absent along the sulci. The sulci were short with pial vessels surrounded by gliotic bands and reactive astrocytosis extending from the surface into the superficial cortical layers probably representing fused sulci. There were nodular heterotrophic islands of small immature neurons in subpial excrescences and at the gray-white junction. Some revealed accumulation of phosphorylated neurofilaments in the cytoplasm (dysmorphic changes). There was florid hypertrophic reactive astrocytosis, seen diffusely distributed throughout the gray–white matter obscuring gray–white distinction. Luxol fast blue stains for myelin highlighted extensive degree of demyelination with gliosis. There was subpial gliosis with hypertrophic astrocytes clustering along the subpial zone. Vascularity was high with the proliferating vessels in gray and white matter. No balloon cells were identified. Leukocyte common antigen immunostain revealed focal collection of lymphocytes in cortex and around parenchymal vessels. HLA-DR (Human Leukocyte Antigen — antigen D Related) highlights activated microglia forming, nodular aggregates of ramified microglia and seen diffusely in gray and white matter reminiscent of Rasmussen like encephalitis. The overall features were consistent with sublobar dysplasia of the right temporal lobe.

The hippocampus revealed prominent dispersion of granule neurons in the dentate gyrus with duplication, and at places triple/multiple layering. The Ammon's horn pyramidal neurons revealed preserved density in CA4, CA3 and CA2 subfields. Focal depletion of neurons was

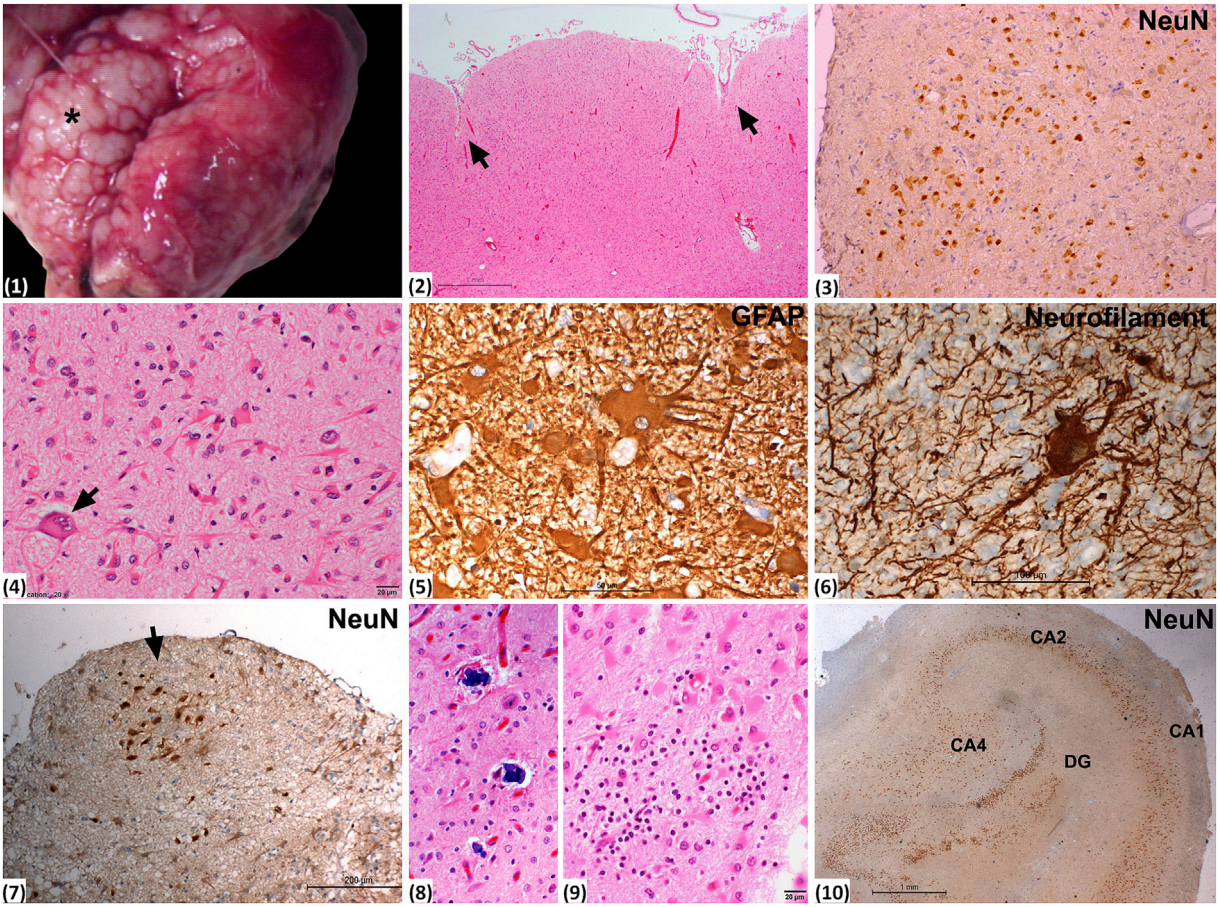

Fig. B. (1) Gross specimen shows peculiar corrugated gyral surface (*) that on histopathology reveals undulating gyral surface with short shallow sulci (2, arrows). There was marked cortical dyslamination (3) and atrophy on NeuN stains. Florid reactive astrocytosis and gliosis was seen with dysmorphic neurons (4, arrow) highlighted by GFAP stains (5). Dysmorphic neurons show accumulation of phosphorylated neurofilament (6). Subpial excrescences along cortical surface show collections of dysmorphic neurons (7, arrow). Foci of parenchymal calcification (8) and occasional microglial nodules are present (9). Hippocampus showed preservation of neuronal density in Ammon's horn (10) (2, 4, 8, 9 — H&E; 3, 5, 7, 10 — immunoperoxidase. Magnification = scale bar).

seen in the CA1 subfield with relative preservation in the subiculum and uncus. The subicular and parahippocampal gyrus revealed florid reactive astrocytosis and gliosis with focal perivascular lymphocytic infiltration.

Postoperatively, the child has been seizure-free for two years. EEG at 3 and 6 months and 1 year did not show any interictal discharges.

3. Discussion

This report provides detailed evaluation of an anatomically and histopathologically distinct dysplastic lesion in a child with drug resistant TLE due to sublobar dysplasia, who was seizure free following surgery. The pathological features are highlighted in view of its rarity.

SLD is a rare malformation which was first described by Barkovich and Peacock in 1998, who believe it to be a localized variant of hemimegalencephaly. This entity was initially classified under the other unclassified malformations group (class IV) but with subsequent report of detailed histopathological findings, it was reclassified as class II C as the majority of these features correspond to abnormal cell migration [1]. These abnormalities were initially thought to occur secondary to abnormal neuronal migration probably as part of localized abnormalities of transmantle migration, or due to abnormal terminal migration/defects in pial limiting membrane [4].

Histopathological findings reported in SLD (as also seen in this case) include a combination of findings (dyslamination, subcortical and leptomeningeal heterotopia and dysmorphic changes in the neurons) that can be correlated to abnormalities in almost every stage of neuronal development. The presence of cortical lamination abnormalities and dysmorphic neurons without presence of balloon cells points to a disorder of postmigrational development (group III), whereas the presence of heterotopias would fit in with abnormalities at the stage of neuronal migration (group II). Presence of dyslamination/dysmorphic changes along with heterotopias preludes its classification as focal cortical dysplasia [6,7]. Due to the similarity of pathology to the localized variant of megalencephaly (absence of space occupying), SLD has been reclassified under group II (abnormalities in neuronal migration) of the new developmental classification of MCDs and removed from group IV (other unclassified malformations) [2]. This report emphasizes the need for an extensive pre-surgical evaluation of temporal SLD with subsequent Engel 1a seizure outcome. Previously, a frontal SLD was also reported to have an Engel 1a seizure outcome at 7 years postoperatively [5].

Our patient manifested with drug-resistant infantile onset temporal lobe epilepsy. Neuroimaging showed dysplastic parenchyma of medial temporal lobe, which was separated from the rest of the temporal lobe by a deep collateral sulcus, consistent with the definition of the sublobar dysplasia. In previous reports, the lesions were confined to single lobe, more commonly the frontal lobe, followed by one each in the temporal, occipital and parietal lobe [2–5]. The cortical surface showed cortical thickening with reduced gyrification in those cases. Our subject also had an additional MRI finding of increased T2 signal along a blurred gray–white matter junction similar to that reported by Tuxhorn et al., which correlated in our study with florid reactive hypertrophic astrocytosis. Consistent with previous reports, there was atrophy of cerebellar vermis and splenium of the corpus callosum [2], but did not have midline malformation or any significant external malformation [2,3,5]. Tractography demonstrated the anterior part of the splenium contains mainly the late myelinating fibers of the mesial and inferior temporal regions. Neurodevelopmentally, the mesial temporal region and the lateral temporal regions have different origins, with the mesial regions developing from the main telencephalon while the flanking portions form the lateral temporal regions. As the lesion in this study grossly marks the developmental distinction of the temporal lobe, anomalous tracts emanating thereof might be responsible for the thin corpus callosum [8]. The descending corticospinal tracts are also atrophied, which means that the homotopic and heterotopic callosal axons originating from this region are also likely to be involved. The proximity of the sensorimotor fibers and the temporal fibers in the posterior part of the corpus callosum might consequentially explain the thinning of the splenium and compartments 3 and 5 of corpus callosum [9,10]. Additional changes included, T2/FLAIR hyperintensity of bilateral globus pallidus and lateral aspect of the thalami with visually evident hypoplasia of these structures on MRI. These additional features have not been noted in the previous reports [1–5] and might be secondary to concomitant hypoxic–ischemic changes affecting even the right corticospinal tracts.

In this study, MEG dipoles were source localized to the suspected epileptogenic zone, adding strength to the pre-surgical localization

4. Conclusion

It's imperative to identify this syndrome mostly from a surgical view point with the distinct histopathology, where the electrographic seizure focus tends to be more focal despite the widespread abnormality. A unique patient specific evaluation process, neuroimaging and electrophysiology findings, proir to surgical management of a patient can provide excellent postsurgical seizure outcome.

Funding

This research did not receive any specific grant from funding agencies in the public, commercial, or non-profit sectors.

Conflict of interest

None of the authors have any conflicts of interest to disclose.

Ethical statement

We confirm that we have read the Journal's position on issues involved in ethical publication and affirm that this report is consistent with those guidelines.

References

[1] Barkovich AJ, Peacock W. Sublobar dysplasia: a new malformation of cortical development. Neurology 1998;50:1383–7.
[2] Barkovich AJ, Guerrini R, Kuzniecky RI, et al. A developmental and genetic classification for malformations of cortical development: update 2012. Brain 2012;135:1348–69.
[3] Dorfmüller G, Ferrand-Sorbets S, Fohlen M, et al. Outcome of surgery in children with focal cortical dysplasia younger than 5 years explored by stereoelectroencephalography. Childs Nerv Syst 2014;30:1875–83.
[4] Pascual Castroviejo I, Pascual Pascual SI, Via o J, et al. Malformations of cortical development and their clinical repercussions in a series of 144 cases. Rev Neurol 2003;37:327–44.
[5] Tuxhorn I, Woermann FG, Pannek HW, et al. Sublobar dysplasia—a clinicopathologic report after successful epilepsy surgery. Epilepsia 2009;50:2652–7.
[6] Palmini A, Najm I, Avanzini G, et al. Terminology and classification of the cortical dysplasias. Neurology 2004;62:S2–8.
[7] Blumcke I, Thom M, Aronica E, et al. The clinicopathologic spectrum of focal cortical dysplasias: a consensus classification proposed by an ad hoc Task Force of the ILAE Diagnostic Methods Commission. Epilepsia 2011;52:158–74.
[8] Herron TJ, Kang X, Woods DL. Automated measurement of the human corpus callosum using MRI. Front Neuroinform 2012;6:1–15.
[9] Wahl M, Strominger Z, Jeremy RJ, et al. Variability of homotopic and heterotopic callosal connectivity in partial agenesis of the corpus callosum: a 3T diffusion tensor imaging and Q-ball tractography study. Am J Neuroradiol February 2009;30:282–9.
[10] Hua K, Zhang J, Wakana S, H, et al. Tract probability maps in stereotaxic spaces: analyses of white matter anatomy and tract-specific quantification. Neuroimage 2008;39:336–47.