

Metallosis: CT findings in a total hip arthroplasty

Jared R. Kirkham, Jonelle M. Petscavage, MD, and Michael L. Richardson, MD

We report a case of a 50-year-old man with extensive metallosis 20 years after right total hip arthroplasty. CT demonstrated osteolysis and radiodense debris surrounding the right hip joint. Although the radiographic appearance of metallosis has been well documented in the literature, the CT appearance of metallosis after total hip arthroplasty has been only sparsely described.

Case report

A 50-year-old man with sickle cell disease and a 20-year history of bilateral total hip arthroplasties for avascular necrosis presented with progressive worsening of right hip pain and stiffness. When initially evaluated in the orthopedic clinic, he walked with a trendelenburg gait on the right and limited range of motion in his right hip compared to the left.

At that time, radiographs of the pelvis demonstrated complete wear of the polyethylene acetabular liner of the right hip arthroplasty, with extensive osteolysis. There were also fractures of the greater trochanter, lesser trochanter, and right superior and inferior pubic rami (Fig. 1). Noncontrast CT of the pelvis further demonstrated the extent of the osteolysis and fractures. CT also showed non-x-ray-apparent fluid-attenuation collections with high-density-material rims along the synovial margins of the right hip joint (Figs. 2 and 3).

Due to the failure of his right hip arthroplasty, the patient subsequently underwent surgical revision. Operative notes document full wear-through of the polyethylene acetabular liner with abnormal metal-on-metal articulation and significant metallic and granulomatous debris staining the

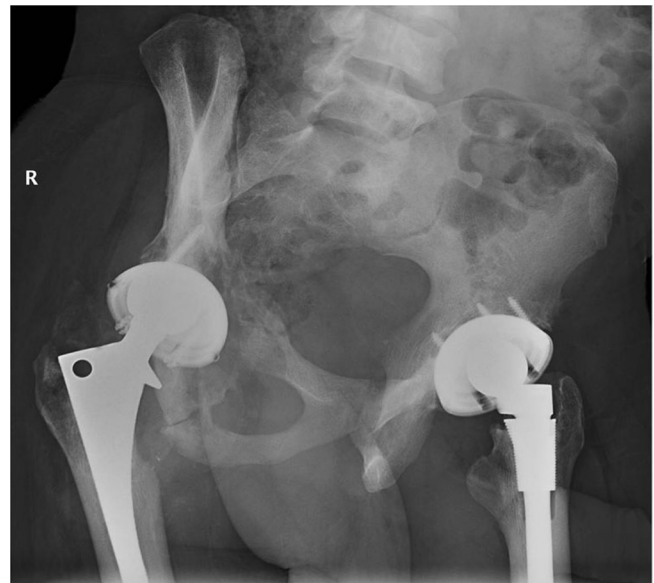


Figure 1. 50-year-old man with extensive metallosis. Judet view of the pelvis shows bilateral total hip arthroplasties. There is osteolysis of the right greater and lesser trochanters and acetabulum. Also seen are fractures of the right superior and inferior pubic rami.

surrounding tissues. However, the metal acetabular cup and femoral components were well fixed. Therefore, the revision consisted of an exchange of the acetabular polyethylene liner and femoral head, with debridement of the surrounding metallic stained tissue.

The patient functionally did well for six months. However, he returned with progressively worsening deep lateral right thigh pain, to the point of needing crutches for ambulation. Laboratory evaluation confirmed no evidence of infection. Radiographs and noncontrast CT of the pelvis

Citation: Kirkham JR, Petscavage JM, Richardson ML. Metallosis: CT findings in a total hip arthroplasty. *Radiology Case Reports*. [Online] 2010;5:410.

Copyright: © 2010 The Authors. This is an open-access article distributed under the terms of the Creative Commons Attribution-NonCommercial-NoDerivs 2.5 License, which permits reproduction and distribution, provided the original work is properly cited. Commercial use and derivative works are not permitted.

Jared Kirkham is a medical student, Dr. Petscavage is a Senior Fellow in Musculoskeletal Radiology, and Dr. Richardson is a Professor of Musculoskeletal Radiology, all at the University of Washington School of Medicine, Seattle WA, USA. Contact Mr. Kirkham at jrk@uw.edu.

Competing Interests: The authors have declared that no competing interests exist.

DOI: 10.2484/rcr.v5i2.410

Metallosis: CT findings in a total hip arthroplasty

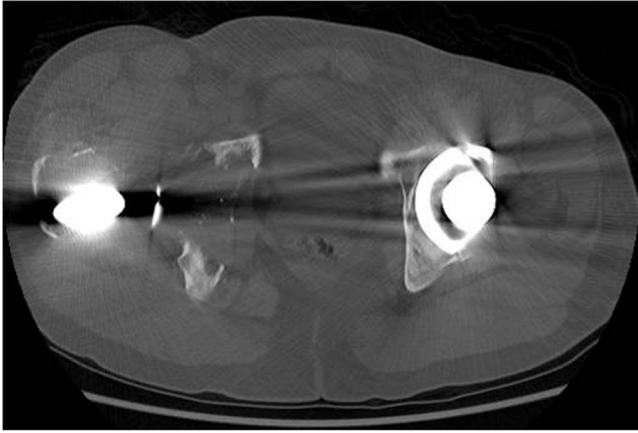


Figure 2. 50-year-old man with extensive metallosis. Axial CT of the pelvis in bone windows shows osteolysis of the right acetabulum with foci of small metallic debris. The medial acetabular wall is completely destroyed.

revealed a new fracture of the right acetabulum with significant superior subluxation of the hip and extensive surrounding osteolysis (Fig. 4). Numerous round, soft-tissue

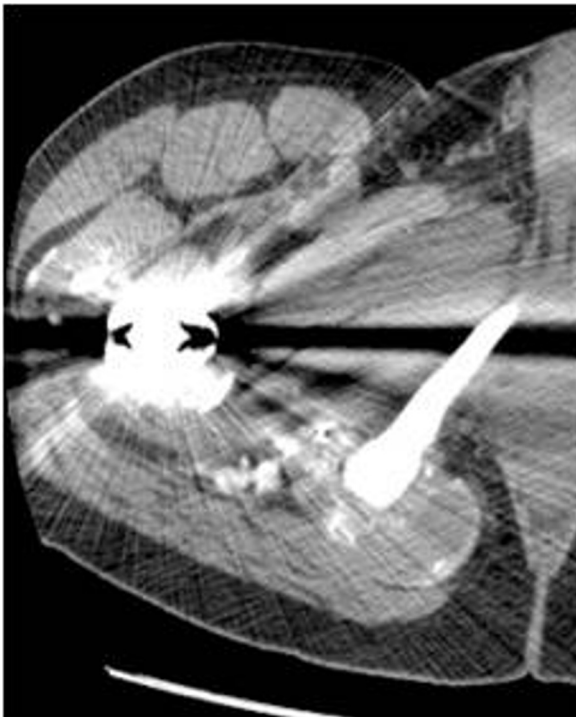


Figure 3. 50-year-old man with extensive metallosis. Non-contrast CT of the right hip joint, at the level of the inferior pubic ramus, shows several round, fluid-density collections with high-density peripheral rims, which are located both anterolaterally and posteromedially along the capsule of the right hip joint. Artifact from right hip prostheses is also present.

masses with high-density walls were again seen outlining the right hip joint.

Due to the presence of multiple soft-tissue ulcers, surgery was not performed. Repeat CT six months later showed further progression of prosthesis failure, with worsening osteolysis of both the anterior and posterior columns of the right acetabulum. There was also further accumulation of radiodense debris, and increased size and number of

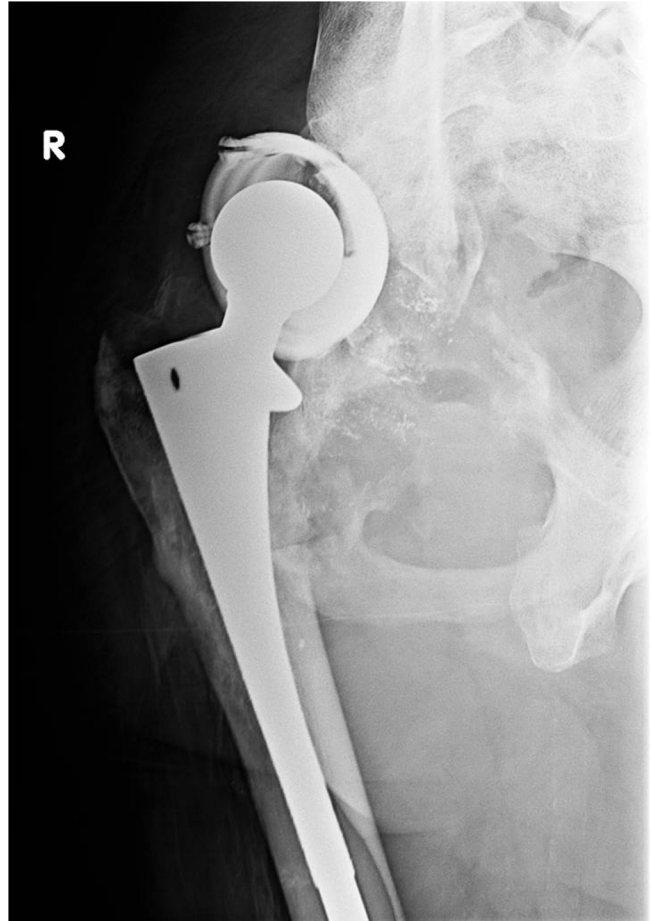


Figure 4. 50-year-old man with extensive metallosis. Radiograph of the right hip shows further osteolysis of the greater and lesser trochanters and right acetabulum. A new fracture of the superior acetabular wall is present with superior migration of the femur. Small metallic particles are now seen on radiographs surrounding the hip prosthesis.

metallic-rimmed fluid collections. Findings were consistent with advanced metallosis (Figs. 5, 6, and 7).

Discussion

Metallosis is a rare condition defined by infiltration of periprosthetic soft tissues and bone by metallic debris resulting from wear of joint arthroplasties (1). The accumulation of metallic debris can further accelerate wear and loosen-

Metallosis: CT findings in a total hip arthroplasty

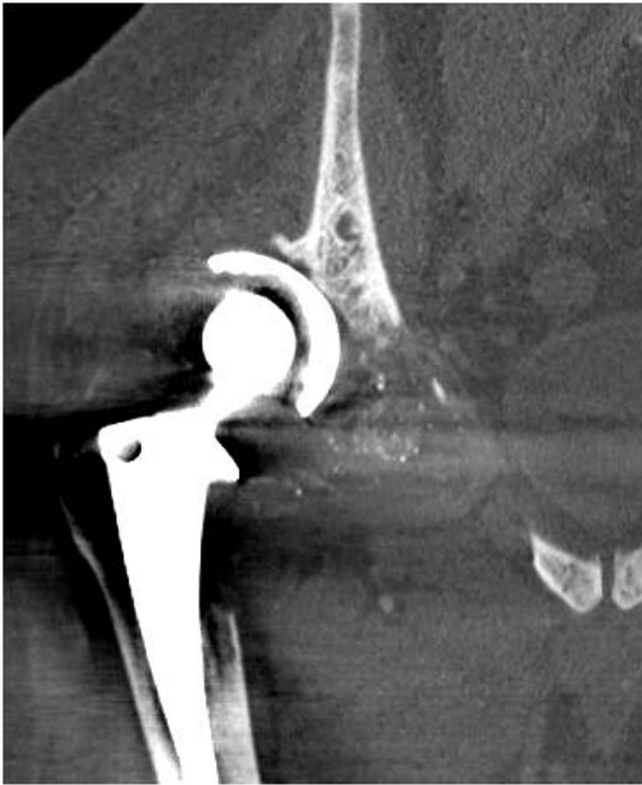

Figure 5. 50-year-old man with extensive metallosis. Coronal reformatted CT of the pelvis without contrast in bone algorithm shows complete osteolysis of the right acetabulum with the space replaced by soft-tissue density and multiple foci of metallic debris, suggestive of advanced metallosis. The right femur is superiorly subluxated.

ing of the hardware components by instigating a local inflammatory response with synovitis and cytokine-mediated osteolysis (2-4). In the setting of total hip arthroplasty (THA), metallosis can occur by a variety of mechanisms. For metal-on-metal THAs, the metal femoral head may wear against the weight-bearing surface of the metal acetabular component (5, 6). Alternatively, if the implant is improperly positioned, the femoral neck may impinge on the acetabular cup (7).

As in this case, metallosis may also occur in THAs that have been constructed with polyethylene liners. The polyethylene liner may fracture or wear down from overuse, resulting in abnormal metal-on-metal contact and the dispersion of metal particles within the joint (8-11). In a review of 418 THAs, the overall incidence of metallosis as the cause of THA failures was approximately 5.3% (12).

There are several characteristic radiographic features of metallosis in THA. On plain films, eccentric alignment of the femoral head in the acetabular cup may suggest wear, fracture, or breakdown of the polyethylene liner. Another finding is the bubble sign, seen as bubble-like hyperdensities representing deposited metallic debris outlining the joint space (13). The cloud sign is described as amorphous

cloudy radiodensities in the periprosthetic tissues (14). In advanced cases such as this one, metallosis may be seen as gross metallic particulate matter in the periprosthetic tissues, which may lead to extensive osteolysis in the surrounding bone.

Unfortunately, these radiographic signs may be absent in over half of cases (12). Therefore, CT may aid in diagnosis. Cases demonstrating the imaging findings of metallosis on CT are sparsely documented in the literature. Findings include high-density material outlining the joint capsule or

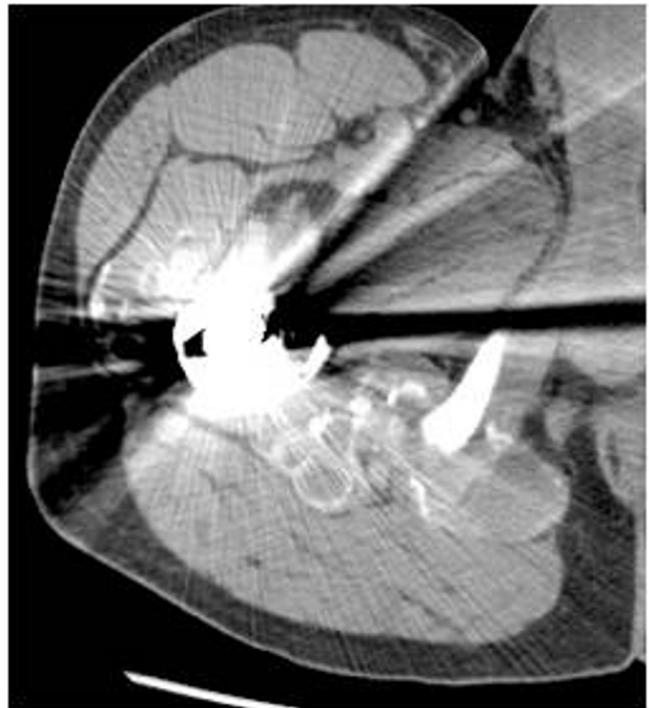

Figure 6. 50-year-old man with extensive metallosis. Axial image from noncontrast CT of the pelvis shows more round, fluid-density lesions with metallic-density peripheral rims. The lesions are anteromedial and posterolateral to the prosthesis, along the hip joint capsule.

bursa (1, 15). Our case report further documents the imaging appearance of metallosis on CT, with the unique findings of metallic debris in addition to high-density material outlining the hip joint capsule. This case of metallosis is particularly unusual in that it occurs in the context of sickle cell disease, which is associated with a high incidence of polyethylene wear and osteolysis requiring re-operation (16, 17).

Due to the severe consequences of metallosis, including chronic inflammation, osteolysis, and prosthetic loosening, as well as the inconsistent appearance of metallosis on plain film, we recommend CT in conjunction with plain films when evaluating the integrity of total hip arthroplasties. This will allow timely detection of metallosis, prompt revision arthroplasty, and minimization of osteolysis.

Metallosis: CT findings in a total hip arthroplasty

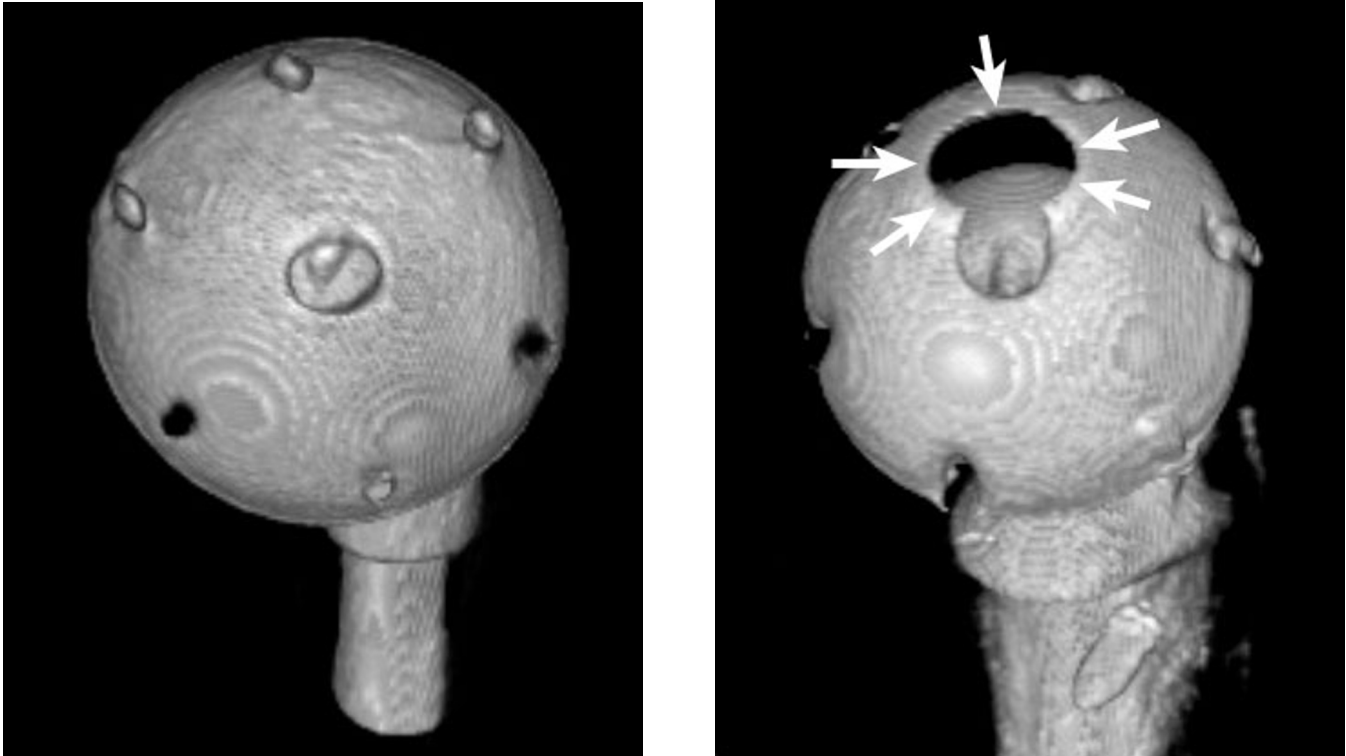


Figure 7. Volume-rendered 3D reformation of CT of prostheses. Left: Medial surface of left acetabular component. Right: Medial surface of the displaced right acetabular component. The abnormal articulation between this component and the ilium has worn a circular hole (arrows) in the component. In addition: [QuickTime 3D movie](#) (893 kB) of both prostheses.

References

1. Heffernan EJ, Alkubaidan FO, Nielsen TO, Munk PL. The imaging appearances of metallosis. *Skeletal Radiol.* 2008 Jan; 37(1):59-62. [\[PubMed\]](#)
2. Keel JB, Kuster MS. Massive wear of an incompatible metal-on-metal articulation in total hip arthroplasty. *J Arthroplasty* 2004 Aug; 19(5): 638–642. [\[PubMed\]](#)
3. Sanchis-Alfonso V. Severe metallosis after unicompartmental knee arthroplasty. *Knee Surg Sports Traumatol Arthrosc* 2007 Apr; 15(4): 361–364. [\[PubMed\]](#)
4. Milosev L, Antolic V, Minovic A. Extensive metallosis and necrosis in failed prostheses with cemented titanium-alloy stems and ceramic heads. *J Bone Joint Surg Br.* 2000 Apr; 82(3): 352–357. [\[PubMed\]](#)
5. Korovessis P, Petsinis G, Repanti M, Repantis T. Metallosis after contemporary metal-on-metal total hip arthroplasty. Five to nine-year follow-up. *J Bone Joint Surg Am.* 2006 Jun; 88(6): 1183-91. [\[PubMed\]](#)
6. Cipriano CA, Issack PS, Beksac B, Della Valle AG, Sculco TP, Salvati EA. Metallosis after metal-on-polyethylene total hip arthroplasty. *Am J Orthop* (Belle Mead NJ). 2008 Feb; 37(2): E18-25. [\[PubMed\]](#)
7. Onda K, Nagoya S, Kaya M, Yamashita T. Cup-neck impingement due to the malposition of the implant as a possible mechanism for metallosis in metal-on-metal total hip arthroplasty. *Orthopedics.* 2008 Apr; 31(4):396. [\[PubMed\]](#)
8. Mariconda M, Silvestro A, Mansueto G, Marinò D. Complete polyethylene wear-through and secondary breakage of the expansion cup in a ceramic-polyethylene total hip arthroplasty. *Arch Orthop Trauma Surg.* 2009 Feb 26. [Epub ahead of print]. [\[PubMed\]](#)
9. Engh CA Jr, Hopper RH, Engh CA, McAuley JP. Wear-through of a modular polyethylene liner: four case reports. *Clin Orthop Relat Res.* 2001 Feb; (383):175-82. [\[PubMed\]](#)
10. Malizos K, Roidis NT, Poultsides L, Basdekis G, Moraitis T, Xenakis T. Protrusion of a ceramic femoral head through the acetabular metallic shell, extensive metallosis and 'bubble sign'. *Orthopedics.* 2009 Feb; 32(2):128. [\[PubMed\]](#)
11. Khan RJ, Wimhurst J, Foroughi S, Toms A. The natural history of metallosis from catastrophic failure of a polyethylene liner in a total hip. *J Arthroplasty.* 2009 Oct; 24(7):1144.e1-4. [\[PubMed\]](#)
12. Chang JD, Lee SS, Hur M, Seo EM, Chung YK, Lee CJ. Revision total hip arthroplasty in hip joints with metallosis: a single-center experience with 31 cases. *J Arthroplasty.* 2005 Aug; 20(5):568-73. [\[PubMed\]](#)

Metallosis: CT findings in a total hip arthroplasty

13. Su EP, Callander PW, Salvati EA. The bubble sign: a new radiographic sign in total hip arthroplasty. *J Arthroplasty*. 2003 Jan; 18(1):110-2. [\[PubMed\]](#)
14. Paydar A, Chew FS, Manner PA. Severe periprosthetic metallosis and polyethylene liner failure complicating total hip replacement: the cloud sign. *Radiology Case Reports*. [Online] 2007; 2:115.
15. Chew FS, Ramsdell MG, Keel SB. Metallosis after total knee replacement. *AJR Am J Roentgenol* 1998 Jun; 170(6): 1556. [\[PubMed\]](#)
16. Hickman JM, Lachiewicz PF. Results and complications of total hip arthroplasties in patients with sickle-cell hemoglobinopathies. Role of cementless components. *J Arthroplasty*. 1997 Jun; 12(4):420-5. [\[PubMed\]](#)
17. Moran MC, Huo MH, Garvin KL, Pellicci PM, Salvati EA. Total hip arthroplasty in sickle cell hemoglobinopathy. *Clin Orthop Relat Res*. 1993 Sep; (294):140-8. [\[PubMed\]](#)