


# Teres major muscle – insertion footprint

Malte Dancker,<sup>1</sup> Simon Lambert<sup>2</sup> and Erich Brenner<sup>1</sup> 

<sup>1</sup>Division of Clinical and Functional Anatomy, Medical University of Innsbruck, Innsbruck, Austria

<sup>2</sup>Spire Bushey Hospital, Bushey, UK

## Abstract

Teres major muscle (TM) and latissimus dorsi muscle (LD) are frequently used in muscle transfers around the shoulder girdle. Some authors have suggested harvesting techniques in which the muscle is detached in continuity with a bone segment. Information on the bony attachment footprint of these muscles is lacking. The purpose of this study was to investigate the region of attachment of the TM to facilitate safe and complete harvesting with a bone segment where it is indicated, and to determine the relationship of the TM footprint with that of the LD. Twenty-eight upper extremities of 14 human cadavers (six female, eight male) were investigated during the students' dissection course in the winter term 2012. The attachment footprints were photographed and the images were processed with IMAGEJ Version 1.46r. The TM attachment footprint at the crest of the lesser tubercle had an average dimension of  $187 \pm 89 \text{ mm}^2$ . It was  $49.6 \pm 7.9 \text{ mm}$  long and  $7.4 \pm 2.5 \text{ mm}$  wide. The bony attachment of the LD within the bicipital groove, just below the tendon of the long head of the biceps muscle, had an area of  $94 \pm 37 \text{ mm}^2$ . It was  $36.5 \pm 8 \text{ mm}$  long and  $3.7 \pm 1.2 \text{ mm}$  wide. Both muscles were separated by  $4.4 \pm 1.7 \text{ mm}$  and their attachments overlapped in the craniocaudal direction by  $24.4 \pm 12.4 \text{ mm}$ . Earlier studies have investigated the dimensions of the muscles' tendons close to the attachment not the bony attachment itself. The dimension of the attachment of the TM was larger than that of the LD. The ratio between the footprint areas was approximately 2:1. This information should be considered by surgeons undertaking transfers, which include a bony segment of the muscle insertion.

**Key words:** axillary nerve; bicipital groove; crest of the lesser tubercle; latissimus dorsi muscle; radial nerve; teres major muscle.

## Introduction

Transfer of the teres major muscle (TM) or the latissimus dorsi muscle (LD) tendon, either combined or isolated, has been frequently reported in patients with massive irreparable postero-superior tears of the rotator cuff (Celli et al. 1998; Codi et al. 2007; Moursy et al. 2009; Zafra et al. 2009; Tauber et al. 2010). The transfer of the TM was indicated for cases with irreversibly damaged infraspinatus muscle, no major degenerative osteoarticular alteration, residual passive external rotation (at least  $40^\circ$ ) and an intact supraspinatus muscle (Celli et al. 1998). The TM tendon

together with the periosteum was detached from its insertion and anchored into the greater tuberosity with transosseous sutures, thus improving the range of motion and decreasing shoulder pain (Celli et al. 1998). After transfer, TM is activated in correspondence with its new anatomical function, which was supportive for the improved arm function (Steenbrink et al. 2010). A transfer in patients with irreparable subscapularis tears has also been suggested (Elhassan, 2015).

Earlier investigations on the TM and LD anatomy have focused on the dimensions of the tendons close to the insertion (Cleeman et al. 2003; Pearle et al. 2006; Buijze et al. 2007; Giessler et al. 2007; Morelli et al. 2008; Alagöz et al. 2009). This information meets current needs only partially. Some authors have suggested harvesting techniques, in which the muscle is detached with a segment of bone (Moursy et al. 2009; Tauber et al. 2010). To our knowledge, information on the footprints' dimensions and area, comparable to existing information about the rotator cuff footprint (Dugas et al. 2002), is incomplete but necessary for further improvement and development in TM and LD transfers.

Information about the neurovascular supply of the TM has been discussed in detail in a previous publication (Dancker et al. 2015).

### Correspondence

Univ.Prof. Dr.med.univ. Erich Brenner, MME, Division for Clinical and Functional Anatomy, Innsbruck Medical University, Müllerstrasse 59, 6020 Innsbruck, Austria. T: +43 512 9003 71121; F: +43 512 9003 73112; E: erich.brenner@i-med.ac.at

This paper is based on the diploma thesis of the first author (Dancker, 2013).

Level of evidence: basic science.

Subject areas: functional human anatomy, musculoskeletal system.

Accepted for publication 13 December 2016

Article published online 9 February 2017

The purpose of this study was to investigate the dimension of the TM and LD bony attachment footprint, its relation to surrounding neurovascular structures and to make this information available for use in clinical practice.

## Materials and methods

This study was performed using 28 forequarter specimens of 14 human cadavers (eight male and six female) with an average age of  $87 \pm 6$  years (range 74.25–98.16 years). The bodies were donated to the Division of Clinical and Functional Anatomy of the Medical University of Innsbruck by people who had given their informed consent to use their bodies for scientific purposes prior to death (McHanwell et al. 2008; Riederer et al. 2012). All cadavers were preserved using a formaldehyde-phenol solution (Platzer et al. 1978). A recent analysis showed that bodies donated to our institution are a representative sample of the general Austrian population at the age of death (Konschake & Brenner, 2014).

The investigation took place during the topographical dissection course at the Medical University of Innsbruck in the winter term 2012.

Macroscopic measurements were performed with the arm in neutral ( $0^\circ$  abduction) position. All measurements were performed by the first author (MD) using a digital slide caliper (Lidl, Germany). A Sony DSLR-A450 camera with a Sony SAL-1855 objective lens was used for photo-documentation. The data were initially recorded on a measuring sheet during the dissection. After completion of the dissections the data were entered into a Microsoft Office Excel 2007 spreadsheet.

## Dissections

The skin, subcutaneous tissue, and pectoralis major and minor muscles were removed by the students during their dissection course.

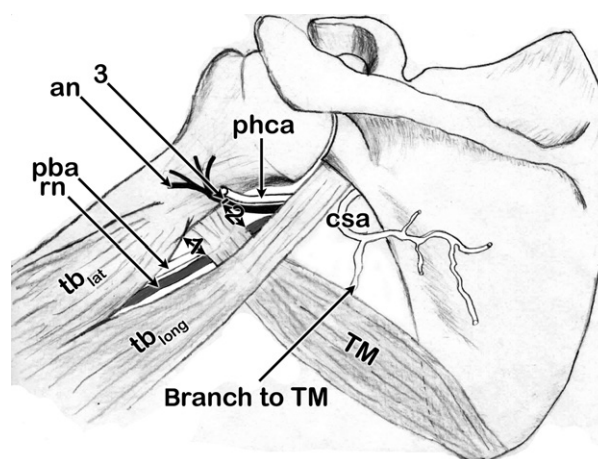
First the axillary nerve (AN), the radial nerve (RN), and the posterior humeral circumflex artery and vein were identified. The measurements describing the TM relationship with the RN and AN were based on the methods performed by Pearle et al. (2006). The distances between the medial borderline of the humerus and the RN at the TM tendon's superior and inferior margin were measured. The distances from the AN to the proximal border of the TM at the medial borderline of the humerus were recorded (Fig. 1).

We dissected the TM's proximal and distal margin to investigate any interconnection to the teres minor muscle or the LD. Connections were differentiated as tendinous or muscular types.

After completion of these measurements the upper extremities were detached. To separate the upper extremity from the thorax the LD was separated from its thoracolumbar origin, the anterior serratus muscle was separated from the ribs and the neurovascular pedicle of the arm was severed immediately below the clavicle and the clavicle was divided.

The distance between the proximal border of the TM tendon and the cartilage rim of the articular surface of the humeral head along the crest of the lesser tubercle was defined as the tendon–cartilage distance (TCD) by Pouliart & Gagey (2005). We quantified the TCD for the TM (Table 1). Therefore, we cut the capsule of the glenohumeral joint to determine the exact location of the cartilage rim.

The LD was then incised 5 cm medial to its humeral attachment. The LD and TM were separated, if they were associated by connections. The TM was then also incised.



**Fig. 1** Schematic drawing of the topographical measurements. The distances between the medial borderline of the humerus and the radial nerve (RN) at the teres major muscle (TM) tendon's distal (1) and proximal (2) margin. (3) Distance from the axillary nerve (AN) to the proximal border of the TM at the medial borderline of the humerus. TM, teres major muscle; csa, circumflex scapular artery; phca, posterior humeral circumflex artery; pba, profunda brachii artery; an, axillary nerve; rn, radial nerve;  $tb_{lat}$ , lateral head of the triceps brachii muscle;  $tb_{long}$ , long head of the triceps brachii muscle.

We marked the peripheral margin of the attachments of both TM and LD on the humerus with a black pencil. The existence of an additional head of the TM was documented. The LD and the TM were dissected sharply from the bone. The dimensions of the insertion footprint remained visible. The length and maximal width of the footprints were measured. We also measured the distance between the two attachments and the size of the overlapping area (Table 1).

The attachment footprints of all 28 shoulders were photographed. The images were preprocessed using 'GIMP – GNU Image Manipulation Program', Version 2.6.8, (Natterer et al. 2012) and then entered into 'IMAGEJ', Version 1.46r (Rasband, 1997–2012; Abràmoff et al. 2004; Schneider et al. 2012) to calculate the area of each insertion footprint (Fig. 2).

## Results

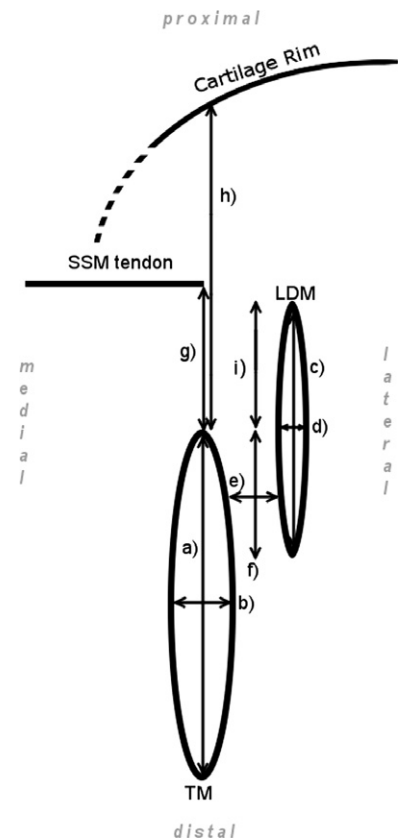
### Topographical location

After removing the skin, the superficial tissue and the pectoralis major muscle, the tendons of the LD and TM were readily identified.

The brachial plexus and its branches were located in close relationship to the tendons. The RN crossed the TM and LD tendons anteriorly in a slightly oblique course. It was located  $14.9 \pm 6.2$  mm (range 3–28 mm) medial to the humerus with reference to the superior edge of the TM tendon. At the inferior edge, the RN was  $12.5 \pm 3.4$  mm (range 7–21 mm) medial of the humerus. The AN was  $7.0 \pm 3.1$  mm (range 2–12 mm) proximal of the TM's proximal border.

**Table 1** Insertion footprints' measurements (TM and LDM).

	$\bar{\varnothing} \pm \text{SD}$	Range
(a) TM's attachment width	$42.4 \pm 8.7$	30–60
(b) TM's attachment thickness	$7.4 \pm 2.5$	3–14
TM's attachment area (mm <sup>2</sup> )	$187 \pm 89$	57–389
(c) LD's attachment width	$36.5 \pm 8.0$	17–52
(d) LD's attachment thickness	$3.7 \pm 1.2$	2–7
LD's attachment area (mm <sup>2</sup> )	$94 \pm 37$	44–204
(e) Distance between TM and LD (gap)	$4.4 \pm 1.7$	2–8
(f) Size of overlapping	$24.4 \pm 12.4$	0–45
(g) Distance between TM and SSM inferior margin	$16.8 \pm 6.2$	9–36
(h) TCD TM	$49.6 \pm 7.9$	37–69
(i) Distance between proximal margin of TM and proximal margin of LD	$12.1 \pm 7.3$	2–26



All data in mm;  $\bar{\varnothing}$ , mean; SD, standard deviation; TCD, tendon–cartilage distance; TM, teres major muscle; SSM, subscapularis muscle; LD, latissimus dorsi muscle.

### Attachments

The TM and LD inserted separately in all cases. The tendons of both muscles were in a close relationship. The TM tendon inserted directly on the crest of the lesser tubercle. The LD tendon inserted anteriorly to the TM tendon. The LD tendon attachment footprint was located more lateral ( $4.4 \pm 1.7$  mm; range 2–8 mm) in the bicipital groove, under the tendon of the long head of the biceps muscle. The attachments were longitudinally offset too. The proximal edge of the LD was found  $12.1 \pm 7.3$  mm (range 2–26 mm) more proximal than the TM proximal edge. The TM attachment appeared to be partially hidden behind, and overlapped by, the LD due to the longitudinal offset. Overall,  $58.2 \pm 26.7\%$  (range 0–100%) of the TM proximal attachment was covered by the LD (Fig. 3). In one left-sided specimen the two attachments were longitudinally fully apart (overlapping = 0%). In two specimens the TM was fully covered (overlapping = 100%) by the LD (Table 1).

The tendons of TM and LD could be separated easily. In eight (28.5%) of 28 shoulders connections existed between

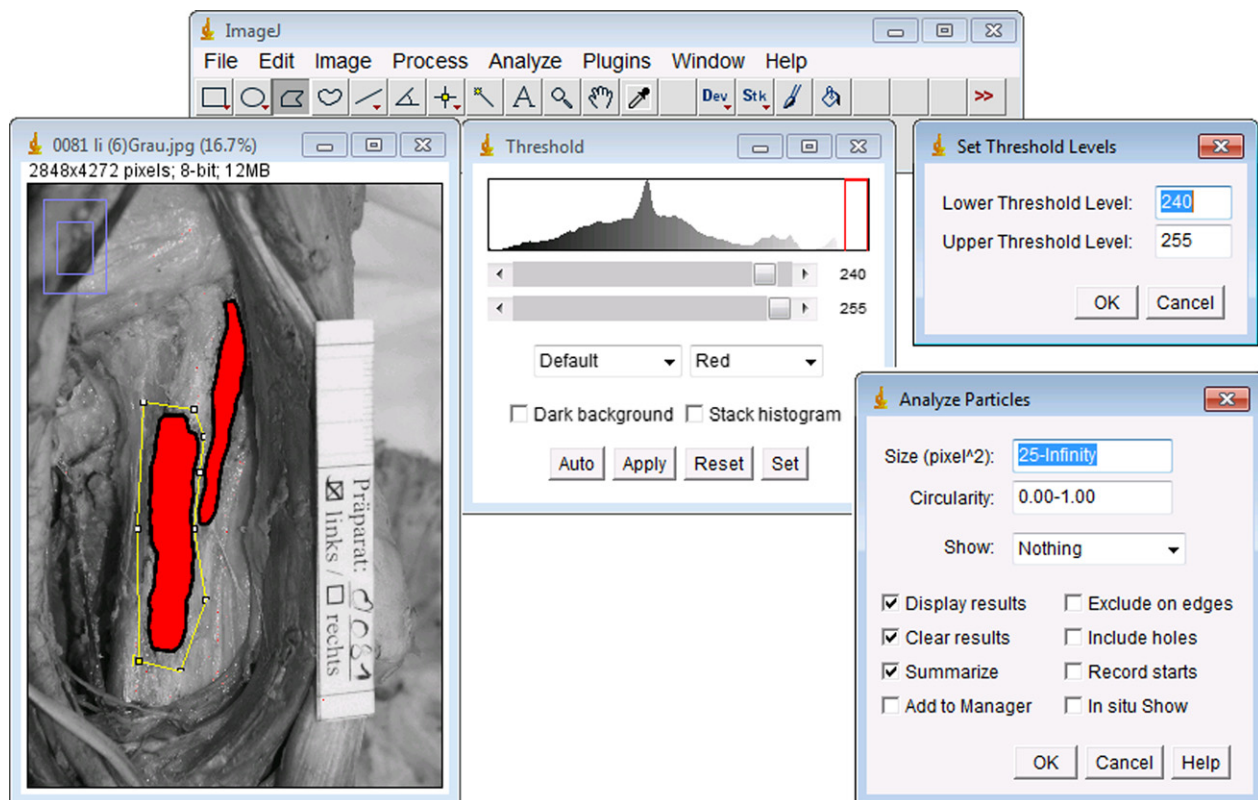
TM and LD. Seven of these (25%) connections were located between the two tendons. In one case (3.5%), the connection was between the LD tendon and the TM transition zone (between the tendinous and muscular fibers of the TM). The connections were mainly located at the distal borderline of the TM. All connections were separated sharply without difficulty.

There were no connections between the teres minor muscle and the TM. After dissecting the muscles off the humerus, the attachment footprints on the humerus were readily identified by the roughening of the bone surface.

The TM attachment dimension ( $187 \pm 89$  mm<sup>2</sup>; range 57–389 mm<sup>2</sup>) was larger than that of the LD ( $94 \pm 37$  mm<sup>2</sup>; range 44–204 mm<sup>2</sup>; Fig. 3).

### Teres major accessorius – new observation

In half of the specimens the attachment footprint of the TM was particularly wide at its proximal part. The footprint did not increase in width continuously: there was an abrupt



**Fig. 2** Steps of processing the images with IMAGEJ – Version 1.46r. (1) Open the gray-scaled and by GIMP processed image; (2) calibrate the scale according to the ruler included within the image; (3) set the lower threshold level at 240 and the upper at 255; (4) choose 'Polygon selection' and surround the teres major muscle (TM) approximately; (5) select 'Analyze particles', set 'Show (pixel<sup>2</sup>)' by "25 – Infinity", Set "Circularity" by 0.00–1.00"; (6) perform steps 4 and 5 for the latissimus dorsi muscle's (LD's) attachment again.

increase in width similar to an edge between the main body of the TM attachment and the cranial, larger component. This was clearer when the TM was turned laterally. Medial to the proximal third of the TM tendon lay a strand of muscular fibers of considerable thickness that was attached to the humerus separately by a very short tendon (< 3 mm; Fig. 4).

This appeared to be a separate attachment of a hitherto undescribed, small, additional 'proximal' head of the TM.

## Discussion

To perform safe harvesting and transfer of the TM muscle, an exact knowledge of the dimensions of the zone of bony attachment and possible variations, and neighboring neurovascular structures, is necessary to avoid any damage.

### Topographical location

There is a close relationship between the TM, the AN and the RN.

The RN crosses the tendons of TM and LD anteriorly, following a slight lateral inclination. This is shown in the present study and by Pearle et al. (2006). In the present

investigation, the RN was about 1 cm closer to the humerus than Pearle et al. (2006) showed.

To identify the muscle attachments during an anterior surgical approach, we suggest staying close to the medial border of the humerus to avoid harm to the RN, which is found about 1.5 cm medial to the humerus.

The AN was found closer to the superior edge of the TM than was previously described by Pearle et al. (2006). These differences can be explained by different measuring techniques and by different methods of dissection. The location of the AN should be considered when transferring the muscle to a more proximal location because this could lead to a compression or impingement of the nerve (Elhassan, 2015).

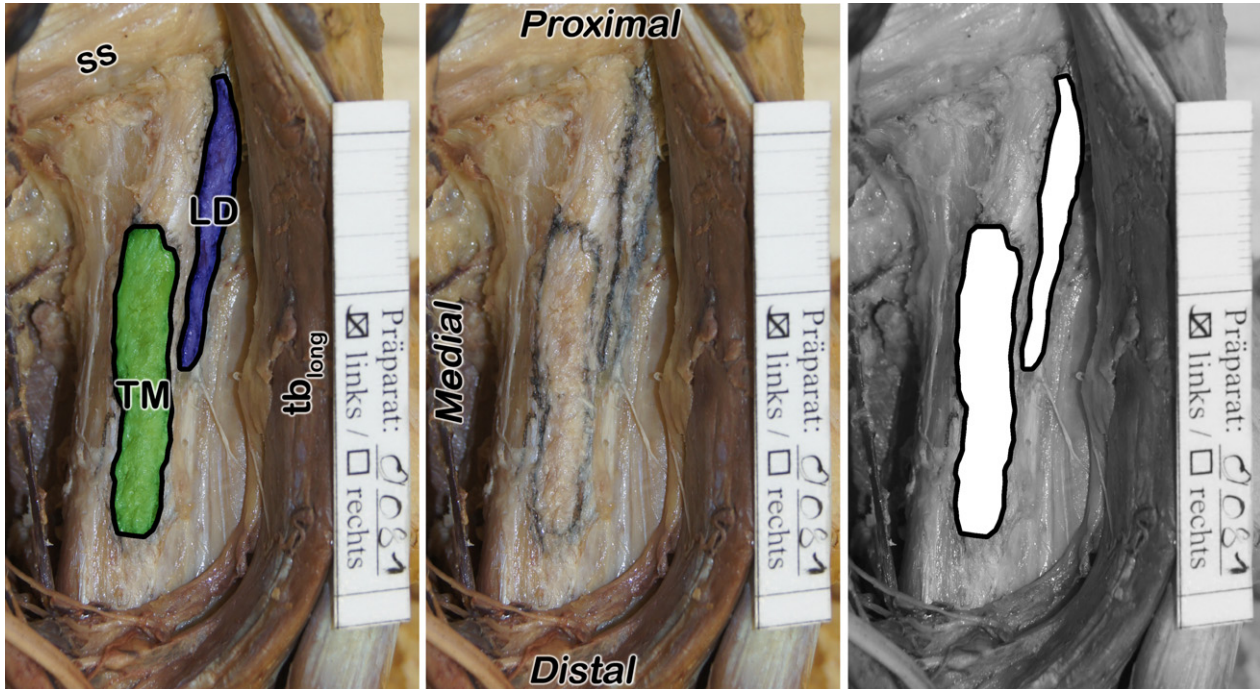
### Attachments

The TM and LD muscles do not insert at the same location. The TM attaches on the crest of the lesser tubercle. This has been consistently described in different anatomical textbooks and was confirmed during the present cadaver investigation (Table 2). The LD attaches more laterally within the bicipital groove. This is only mentioned in the textbooks of Williams et al. (1989) and Martini et al. (2012). Between the

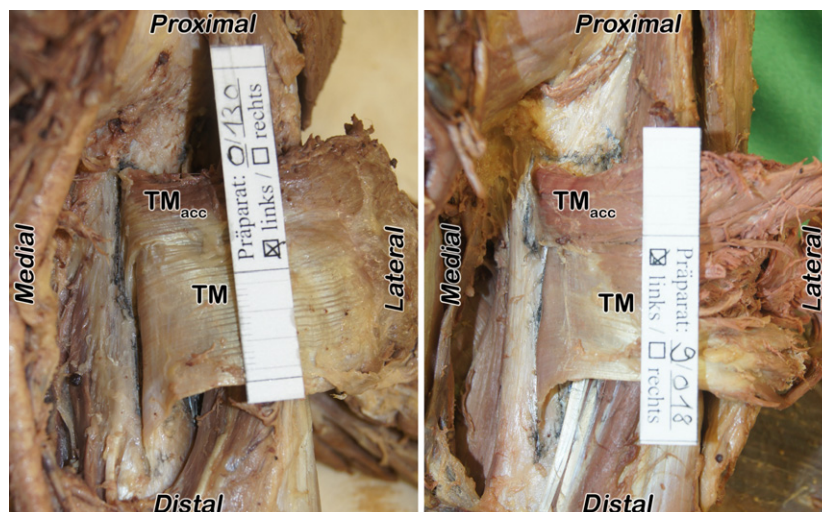
two muscle attachments, there is a gap of some millimeters (Fig. 2; Table 1). Beck & Hoffer (1989) measured this as about 1 cm, and Cleeman et al. (2003) described the gap as 0.7 cm. We found the gap to be smaller.

The knowledge that these two muscles are inserting at different locations on the humerus is important. If one of

these muscles is harvested for transfer, the attachment footprint of the other muscle should (and can) stay intact. We have shown these muscles do have separate tendons. Nevertheless, connections between these two tendons may exist. The presence of connection has been outlined by various authors (Celli et al. 1998; Wang et al. 1999; Pouliart &



**Fig. 3** Attachment footprints – average relation. In the center is the original image of the attachment footprints of a left specimen after the teres major muscle (TM) and the latissimus dorsi muscle (LD) were removed. In the left image the attachment footprints were colored using GIMP. It gives a better impression of the relation and location. The right image shows the gray-scale image that was used for processing in IMAGEJ (Fig. 1). ss, subscapularis muscle;  $tb_{long}$ , long head of the biceps muscle.



**Fig. 4** Additional head – teres major accessorius muscle. Two left specimens, presenting the teres major accessorius muscle ( $TM_{acc}$ ). The teres major muscle (TM) is still attached to the humeral bone but cut and turned laterally. The additional head is visible on the posterior surface within the proximal third. The separate insertion and the short tendon in comparison to the TM's main tendon can especially be seen in the right picture.

**Table 2** Description of TM's and LD's attachments in various anatomical textbooks.

Author	TM's attachment	LD's attachment
Aumüller et al. (2007)	Crest of lesser tubercle (p. 404)	Crest of lesser tubercle (p. 404)
Schünke et al. (2009)	Crest of lesser tubercle (p. 300)	Crest of lesser tubercle (p. 300)
Martini et al. (2012)	Crest of lesser tubercle (p. 320)	Bottom bicipital groove (p. 318); crest of lesser tubercle (p. 320)
Tillmann & Töndury (1987)	Crest of lesser tubercle (p. 371)	Crest of lesser tubercle (p. 372)
Paulsen & Waschke (2010a)	Crest of lesser tubercle (medial of LD) (p. 40)	Crest of lesser tubercle (p. 40)
Paulsen & Waschke (2010b)	Crest of lesser tubercle (p. 169)	Crest of lesser tubercle (p. 169)
Williams et al. (1989)	Crest of lesser tubercle (p. 614)	Floor of the humeral intertubercular sulcus (p. 610)
Lippert (1990)	Crest of lesser tubercle (p. 659f)	Crest of lesser tubercle (p. 660)
Benninghoff & Drenckhahn (2003)	Crest of lesser tubercle (p. 298)	Crest of lesser tubercle (p. 290)
Fanghänel et al. (2009)	Crest of lesser tubercle (p. 696)	Crest of lesser tubercle (p. 696)
Sieglbauer (1947)	Crest of lesser tubercle (p. 240)	Crest of lesser tubercle (p. 240)
Platzer (2009)	Crest of lesser tubercle (p. 140)	Crest of lesser tubercle (p. 140)
Hafferl & Thiel (1969)	Crest of lesser tubercle (p. 707)	Crest of lesser tubercle (p. 706)
von Lanz et al. (2004)	Crest of lesser tubercle (p. 56)	Crest of lesser tubercle (p. 56)

Gagey, 2005; Pearle et al. 2006), and especially by Beck & Hoffer (1989). A frequency of this variation has not been previously described. It was found in 25% of cases during this investigation.

Cleeman et al. (2003) showed that 39% of the TM attachment overlapped with the LD. We noted that half of the proximal TM insertion is usually covered by the LD. Nevertheless, there is a wide range from no overlapping to complete overlapping. Complete overlapping was described as a variation by Cleeman et al. (2003) and was found in two of our cases (7.1%). In contrast, a complete longitudinal offset can also exist (3.6%). Pouliart & Gagey (2005) measured the distance between the proximal borders of the two tendons. Our data are similar, but the range of measurement is wider. In our study the TM tendon reached up to 37 mm more distal than the LD attachment. This is almost double the extent being described by Pouliart & Gagey (2005). Our results concerning the TCD differ by about 1 cm to the average described by Pouliart & Gagey (2005). Because of a higher number of specimens, the significance of the results of Pouliart & Gagey (2005) may be greater.

For muscle transfers including a bony segment, exact knowledge of the attachment footprint and not only the tendon dimension is helpful. There is no previous information about the area of the TM attachment footprint in literature. Earlier studies (Cleeman et al. 2003; Pearle et al. 2006; Buijze et al. 2007; Giessler et al. 2007; Morelli et al. 2008; Alagöz et al. 2009) investigated the tendon dimension immediately proximal to the attachment footprint without evaluation of the footprint itself. The present study has shown that the ratio between the area of the TM attachment and the LD attachment is approximately 2:1 (Table 1). It is bigger than previously expected.

### Teres major accessorius – new observation

Wang et al. (1999) mentioned that the 'TM tendon was partially covered posteriorly by muscle fibers that attached directly to the periosteum of the humerus'. This result only corresponds partially with the results of this study.

In our cases the additional strand of muscle fibers was of considerable thickness and inserted separately to the bone by a short tendon. Therefore, we decided to describe these additional muscular fibers as an additional head of the TM (Fig. 4) and named it the teres major accessorius muscle.

The knowledge of this additional head is clinically relevant, especially if a posterior approach is performed during reconstructive shoulder surgery: the TM's tendon can appear shorter than it actually is.

### Conclusion

The TM attaches on the crest of the lesser tubercle on the humeral bone. Its attachment is medial to and separate from the LD attachment. The LD inserts within the bicipital groove. Between the attachments, there exists a small gap. Half of the TM attachment footprint is usually overlapped by the LD.

The attachment footprint of the TM is considerably bigger than the LD (average relation TM:LD = 2:1).

Dorsally to the proximal third of the TM tendon, a separate strand of muscular fibers exists in 50% of all cases. This additional head inserts on the humerus with a short (< 3 mm) tendon.

The TM is located about 15 mm distal to the subscapularis attachment and about 40 mm distal to the articular cartilage margin of the humeral head.

The RN crosses the TM and LD tendon anteriorly and medial to the humerus. The AN is found about 10 mm proximal to the cranial border of the TM.

Connections can exist between the TM and LD tendons near the attachment footprint of the TM. These connections can be separated sharply.

## Acknowledgements

The authors wish to thank the medical students Florian Fritz, Florian Kellermann, Katharina R uth and Stefan Siegert for their invaluable help with the dissections. The authors also wish to thank those individuals who donated their bodies and tissues for the advancement of education and research. The authors have no conflict of interests to declare.

## Authors' contributions

Concept/design: MD, SL, EB; acquisition of data: MD; data analysis/interpretation: MD, EB; drafting of the manuscript: MD; critical revision of the manuscript: MD, SL, EB; approval of the manuscript: MD, SL, EB.

## Disclaimer

No funding was provided for this study.

## Ethical statement

The bodies came from people who had given their informed consent to use their bodies for scientific purposes prior to death.

## References

- Abramoff MD, Magalhaes PJ, Ram SJ (2004) Image processing with ImageJ. *Biophotonics Int* **11**, 36–42.
- Alag z MS, Alag z AN, Orbay H, et al. (2009) The utilization of teres major muscle in facial paralysis reanimation: an anatomic study. *J Craniofac Surg* **20**, 926–929.
- Aum ller G, Aust G, Doll A, et al. (2007) *Duale Reihe Anatomie*. Stuttgart: Thieme.
- Beck PA, Hoffer MM (1989) Latissimus dorsi and teres major tendons: separate or conjoint tendons? *J Pediatr Orthop* **9**, 308–309.
- Benninghoff A, Drenckhahn D (2003) *Anatomie, Band 1: Zellen- und Gewebelehre, Entwicklungslehre, Skelett- und Muskelsystem, Atemsystem, Verdauungssystem, Harn- und Genitalsystem*. M nchen: Urban & Fischer.
- Buijze GA, Keereweer S, Jennings G, et al. (2007) Musculotendinous transfer as a treatment option for irreparable posterosuperior rotator cuff tears: teres major or latissimus dorsi? *Clin Anat* **20**, 919–923.
- Celli L, Rovesta C, Marongiu MC, et al. (1998) Transplantation of teres major muscle for infraspinatus muscle in irreparable rotator cuff tears. *J Shoulder Elbow Surg* **7**, 485–490.
- Cleeman E, Hazrati Y, Auerbach JD, et al. (2003) Latissimus dorsi tendon transfer for massive rotator cuff tears: a cadaveric study. *J Shoulder Elbow Surg* **12**, 539–543.
- Codsi MJ, Hennigan S, Herzog R, et al. (2007) Latissimus dorsi tendon transfer for irreparable posterosuperior rotator cuff tears. Surgical technique. *J Bone Joint Surg Am* **89**(Suppl 2 Pt. 1), 1–9.
- Dancker M (2013) The clinical-functional anatomy of the teres major muscle. Thesis: *Division for Clinical and Functional Anatomy*. pp. 64. Innsbruck: Innsbruck Medical University.
- Dancker M, Lambert S, Brenner E (2015) The neurovascular anatomy of the teres major muscle. *J Shoulder Elbow Surg* **24**, e57–e67.
- Dugas JR, Campbell DA, Warren RF, et al. (2002) Anatomy and dimensions of rotator cuff insertions. *J Shoulder Elbow Surg* **11**, 498–503.
- Elhassan BT (2015) Feasibility of latissimus and teres major transfer to reconstruct irreparable subscapularis tendon tear: an anatomic study. *J Shoulder Elbow Surg* **24**, e102–e103.
- Fangh nel J, Pera F, Anderhuber F, et al. (2009) *Waldeyer – Anatomie des Menschen*. Berlin: Walter de Gruyter.
- Giessler GA, Doll S, Germann G (2007) Macroscopic and microangiographic anatomy of the teres major muscle: a new free functional muscle flap? *Plast Reconstr Surg* **119**, 941–949.
- Hafferl A, Thiel W (1969) *Lehrbuch der Topographischen Anatomie*. Berlin: Springer.
- Konschake M, Brenner E (2014) ‘‘Mors auxilium vitae’’ – causes of death of body donors in an Austrian anatomical department. *Ann Anat* **196**, 387–393.
- von Lanz T, Lang J, Wachsmuth W (2004) *Praktische Anatomie – Teil 3*, Vol. 1. Berlin: Arm Springer.
- Lippert H (1990) *Lehrbuch Anatomie*. M nchen: Urban & Fischer, Wien.
- Martini F, Timmons MJ, Tallitsch RB (2012) *Anatomie*. M nchen: Pearson.
- McHanwell S, Brenner E, Chirculescu ARM, et al. (2008) The legal and ethical framework governing body donation in Europe – a review of current practice and recommendations for good practice. *Eur J Anat* **12**, 1–24.
- Morelli M, Nagamori J, Gilbert M, et al. (2008) Latissimus dorsi tendon transfer for massive irreparable cuff tears: an anatomic study. *J Shoulder Elbow Surg* **17**, 139–143.
- Moursy M, Forstner R, Koller H, et al. (2009) Latissimus dorsi tendon transfer for irreparable rotator cuff tears: a modified technique to improve tendon transfer integrity. *J Bone Joint Surg Am* **91**, 1924–1931.
- Natterer M, Neumann S, the GIMP Development Team (2012) GIMP – GNU Image Manipulation Program. <http://www.gimp.org/>.
- Paulsen F, Waschke J (2010a) *Sobotta Tabellen: Tabellen zu Muskeln, Gelenken und Nerven*. M nchen: Urban & Fischer.
- Paulsen F, Waschke J (2010b) *Sobotta, Atlas der Anatomie des Menschen Teil 1: Allgemeine Anatomie und Bewegungsapparat*. M nchen: Urban & Fischer.
- Pearle AD, Kelly BT, Voos JE, et al. (2006) Surgical technique and anatomic study of latissimus dorsi and teres major transfers. *J Bone Joint Surg Am* **88**, 1524–1531.
- Platzer W (2009) *Taschenatlas Anatomie, Band 1: Bewegungsapparat*. Thieme, Stuttgart.
- Platzer W, Putz R, Poisel S (1978) New system for the preservation and storage of anatomical matter. *Acta Anat (Basel)* **102**, 60–67.
- Pouliart N, Gagey O (2005) Significance of the latissimus dorsi for shoulder instability. I. Variations in its anatomy around the humerus and scapula. *Clin Anat* **18**, 493–499.
- Rasband WS (1997–2012) ImageJ. Bethesda, MD, USA: US National Institutes of Health. <http://rsbweb.nih.gov/ij/>
- Riederer BM, Bolt S, Brenner E, et al. (2012) The legal and ethical framework governing body donation in Europe – 1st update on current practice. *Eur J Anat* **16**, 1–21.

- Schneider CA, Rasband WS, Eliceiri KW** (2012) NIH Image to ImageJ: 25 years of image analysis. *Nat Methods* **9**, 671–675.
- Schünke M, Schulte E, Schumacher U, et al.** (2009) *Prometheus Lernatlas der Anatomie – Allgemeine Anatomie und Bewegungssystem*. Stuttgart: Thieme.
- Sieglbauer F** (1947) *Normale Anatomie des Menschen*. Berlin: Urban & Schwarzenberg, Wien.
- Steenbrink F, Nelissen RG, Meskers CG, et al.** (2010) Teres major muscle activation relates to clinical outcome in tendon transfer surgery. *Clin Biomech (Bristol, Avon)* **25**, 187–193.
- Tauber M, Moursy M, Forstner R, et al.** (2010) Latissimus dorsi tendon transfer for irreparable rotator cuff tears: a modified technique to improve tendon transfer integrity: surgical technique. *J Bone Joint Surg Am* **92**(Suppl 1 Pt 2), 226–239.
- Tillmann B, Töndury G** (1987) Rauber/Kopsch Anatomie des Menschen, Band I: Bewegungsapparat. In: *Rauber/Kopsch: Anatomie des Menschen, Lehrbuch und Atlas*. (eds Leonhardt H, Tillmann B, Töndury G, Zilles K). Stuttgart: Thieme.
- Wang AA, Strauch RJ, Flatow EL, et al.** (1999) The teres major muscle: an anatomic study of its use as a tendon transfer. *J Shoulder Elbow Surg* **8**, 334–338.
- Williams PL, Warwick R, Dyson M, et al.** (1989) *Gray's Anatomy*. Edinburgh: Churchill Livingstone.
- Zafra M, Carpintero P, Carrasco C** (2009) Latissimus dorsi transfer for the treatment of massive tears of the rotator cuff. *Int Orthop* **33**, 457–462.