

Distal Patellar Tendon SpeedBridge Repair



Mark T. Rose, D.O., Paul E. Caldwell III, M.D., Scott Vizzi, M.D., and Sara E. Pearson, Ph.D.

Abstract: Patellar tendon ruptures are rare injuries in young athletes, resulting in disruption of the extensor mechanism, and require surgery for functional recovery. Several techniques have been reported, including end-to-end repair and single-row suture anchor constructs. The strength of these repairs has been questioned, and they are commonly augmented. We endorse a double-row repair technique that provides an anatomic restoration of the footprint, has high fixation strength, eliminates the need for graft augmentation, and allows early motion.

Injuries to the knee joint are relatively common in adolescents and often involve fractures of the bone as well as ruptures of the ligaments. Quadriceps and patellar tendon injuries are rare, especially in the younger population.¹ Despite the infrequent nature of extensor mechanism injuries, case reports document that ruptures can occur proximally as sleeve fractures, in the midsubstance of the tendon, or distally as avulsion fractures.² Multiple classification systems have been published describing injury patterns, locations, and acute or chronic injuries.³ The mechanism of injury is typically rapid flexion of the knee against the opposing quadriceps force,⁴ which commonly occurs during the initiation of jumping or during landing.

Patellar tendon ruptures disrupt the extensor mechanism of the knee and necessitate surgical treatment. Numerous repair techniques have been described, including end-to-end suture repair with or without cerclage reinforcement.^{2,5} Additionally, suture anchors have been used for primary repair, with good functional outcomes reported.⁶ The goal of surgical treatment is to re-establish the extensor mechanism using a repair technique that is strong enough to permit early

mobilization to prevent quadriceps atrophy and knee stiffness.^{7,8} Currently, there is no universally accepted repair technique owing to the infrequent nature of the injury and the lack of data for direct comparison. We present our preferred repair technique for distal patellar tendon avulsion using a SpeedBridge construct.

Surgical Technique

Our technique uses the traditional supine position on a well-padded operating table ([Video 1](#)). Prior to preparation and draping of the operative extremity, measurement of the contralateral patellar tendon is an important part of preparation for repair of the injured side. After the knee is prepared and draped in the standard surgical fashion with the inflation of a proximal tourniquet, the knee is approached through the standard anterior midline approach. This approach allows wide exposure of the patella and tibial tubercle with allowance for extension ([Table 1](#)). A hematoma is often encountered directly under the subcutaneous tissue owing to the traumatic nature of the injury. This is evacuated for visualization of the tendon, as well as any additional tibial tubercle bony fragments ([Fig 1](#)).

From Orthopaedic Research of Virginia, Richmond, Virginia, U.S.A. (M.T.R., P.E.C., S.V., S.E.P.); and Tuckahoe Orthopaedic Associates (P.E.C.), Richmond, Virginia, U.S.A.

The authors report the following potential conflicts of interest or sources of funding: The following entities have provided grant funding to Orthopaedic Research of Virginia for fellowship support: Acumed, Arthrex, ConMed/LinVatec, DJO, DePuy Synthes, and Smith & Nephew. M.T.R. receives fellowship support from Acumed, Arthrex, ConMed Linvatec, DJO, DePuy Synthes, and Smith & Nephew, outside the submitted work. P.E.C. receives fellowship support from Acumed, Arthrex, ConMed Linvatec, DJO, DePuy Synthes, and Smith & Nephew, outside the submitted work; and receives personal fees (consulting fees) from Arthrex, JRF, and Vericel. S.V. receives fellowship support from Acumed, Arthrex, ConMed Linvatec, DJO, DePuy Synthes, and Smith & Nephew, outside the

submitted work. S.E.P. receives fellowship support from Acumed, Arthrex, ConMed Linvatec, DJO, DePuy Synthes, and Smith & Nephew, outside the submitted work. Full ICMJE author disclosure forms are available for this article online, as [supplementary material](#).

Received May 18, 2020; accepted September 10, 2020.

Address correspondence to Paul E. Caldwell III, M.D., Tuckahoe Orthopaedic Associates, 1501 Maple Ave, Ste 200, Richmond, VA 23226, U.S.A. E-mail: fellowship@orv.com

© 2020 by the Arthroscopy Association of North America. Published by Elsevier. This is an open access article under the CC BY-NC-ND license (<http://creativecommons.org/licenses/by-nc-nd/4.0/>).

2212-6287/20966

<https://doi.org/10.1016/j.eats.2020.09.003>

Table 1. Key Steps in Distal Patellar Tendon SpeedBridge Repair

1. Identify and Preserve the Distal end of the patellar Tendon, Bone Fragments, and Footprint.
2. Establish adequate exposure for a proximal row and distal row of anchors.
3. Use a drill, awl, and tap in dense bone for optimal purchase of the biocomposite implant.
4. Reduce the tendon to the footprint to ensure the tension-length relation prior to passing the proximal row of sutures.
5. Use reinforcing suture techniques such as rip-stop, crisscross, and double-pulley techniques to provide maximum fixation.
6. Range the knee after repair to establish safe rehabilitation guidelines.

Deep self-retaining retractors (Specialty Surgical Instrumentation, Nashville, TN) are placed to maintain exposure.

The patellar tendon is initially evaluated to determine repair options. Bony fragments from the tibial tubercle are identified and preserved to facilitate reduction and to re-establish tendon length.

Attention is then turned to identifying the tibial tubercle and the patellar tendon footprint to place our proximal row of anchors in preparation for repair. Given the density of the bone, we mark our insertion sites with a starter 4.5-mm Corkscrew awl (Arthrex, Naples, FL) and complete our insertion socket with a 4.0-mm drill (Arthrex). Once the socket has been created, a 4.5-mm Corkscrew tap (Arthrex) is used to ensure ease of anchor insertion in the dense bone. A free FiberTape (Arthrex) is then loaded within the eyelet of a 4.75-mm double-loaded Bio-SwiveLock anchor (Arthrex) and inserted with the aid of a mallet into the predrilled socket (Fig 2). Once the eyelet is well seated, the paddle is grasped and maintained in position with one hand and the handle is turned clockwise with gentle pressure to screw the anchor into the bone with the other hand. Great care is taken to ensure that the same angle is used to drill and then to insert the anchor

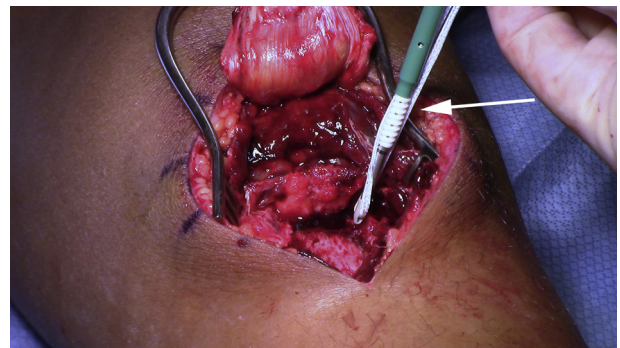


Fig 2. Insertion of the first anchor (white arrow) of the proximal row in the proximal tibia during distal patellar tendon SpeedBridge repair. The anterior aspect of the left knee is shown in extension after a midline approach.

for optimal placement and purchase. The procedure is repeated for our second proximal-row anchor, which provides a total of 8 No. 2 FiberWires (Arthrex) and 4 FiberTapes for repair.

The FiberWire and FiberTape ends are passed through the distal end of the patellar tendon using a free needle (Anchor Products, Addison, IL). Our preference is to pass the FiberWire sutures in a horizontal mattress configuration and the FiberTape in a more proximal position to provide a biomechanical rip-stop design. We prefer to tie the proximal FiberWire mattress row of sutures but leave the FiberTape untied (Fig 3).

Once the proximal row has been secured, attention is turned to the distal row of anchors. The insertion sites for the distal 2 anchors are again marked with an awl and drilled. The free ends of the FiberWire and FiberTape are then loaded within the eyelets of the distal SwiveLock anchors and inserted in the same fashion to complete the repair. Our preference to insert the sutures from the more medially based proximal-row anchor into the more laterally based distal-row anchor and vice versa in an effort to create a crisscross pattern for tendon repair and optimize potential compression

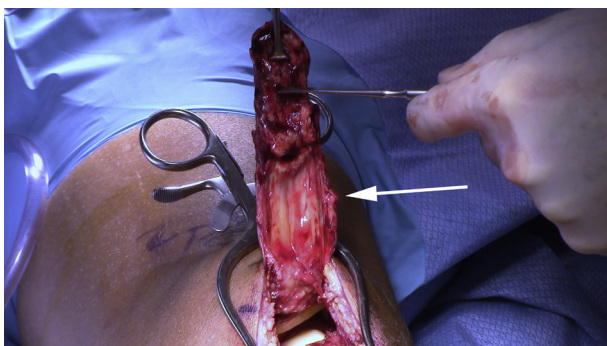


Fig 1. Posterior aspect of the distal patellar tendon (white arrow) after avulsion in preparation for distal patellar tendon SpeedBridge repair. The anterior aspect of the left knee is shown in extension after a midline approach.

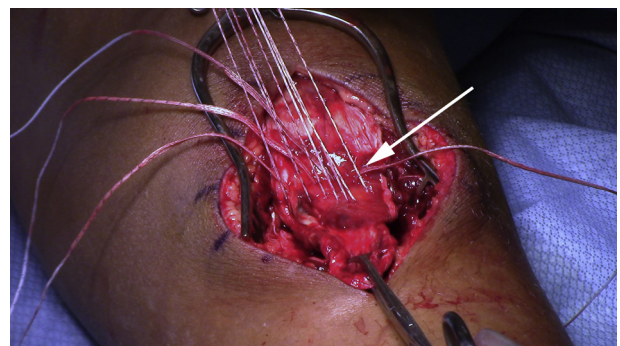


Fig 3. Proximal-row sutures and tape (white arrow) passed through the distal patellar tendon during distal patellar tendon SpeedBridge repair. The anterior aspect of the left knee is shown in extension after a midline approach.

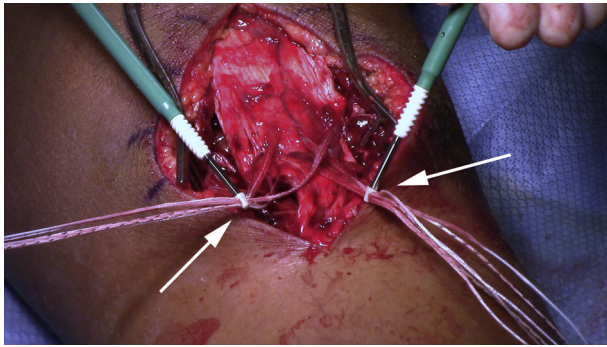


Fig 4. Insertion of the 2 distal-row anchors (white arrows) in the proximal tibia using a crisscross suture configuration during distal patellar tendon SpeedBridge repair. The anterior aspect of the left knee is shown in extension after a midline approach.

(Fig 4). We then use a double-pulley technique⁹ to tie the free ends of the No. 2 FiberWire safety suture from each distal anchor to provide additional compression to the distal end of the patellar tendon (Fig 5). Once the repair is completed, the free suture ends from the distal row are cut flush with the bone with a knife to ensure a low-profile repair (Fig 6). The knee is taken through a gentle range of motion to establish safe postoperative range-of-motion restrictions and confirm the strength of fixation. The length of the patellar tendon is measured to compare it with the length previously measured on the contralateral side. Copious irrigation and meticulous hemostasis are performed prior to a layered closure. A dry sterile dressing is applied, along with a brace locked in full extension (DJO Global, Lewisville, TX).

Rehabilitation

Postoperatively, the patient is allowed to bear weight as tolerated in a hinged brace locked in full extension. Supervised physical therapy starts at 7 to 10 days after surgery to focus on regaining range of motion and strength. Prone flexion from 0° to 70° is allowed for the

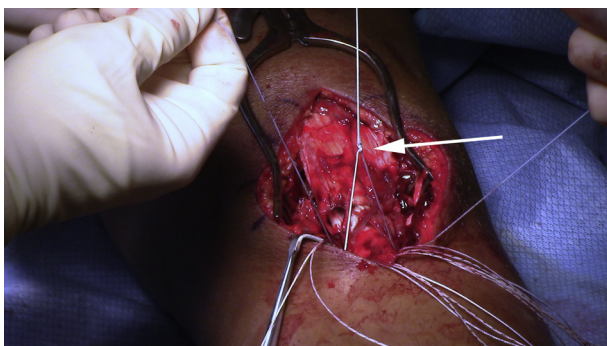


Fig 5. Double-pulley technique (white arrow) to secure the distal end of the patellar tendon during distal patellar tendon SpeedBridge repair. The anterior aspect of the left knee is shown in extension after a midline approach.

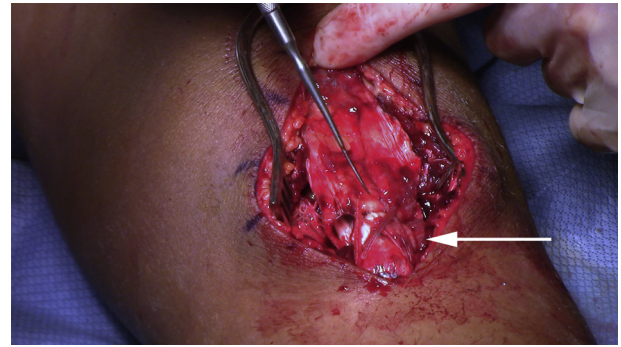


Fig 6. Final double-row SpeedBridge repair of a distal patellar tendon avulsion (white arrow). The anterior aspect of the left knee is shown in extension after a midline approach.

first 4 weeks. Flexion is progressed to 0° to 110° from weeks 4 to 8 and 0° to full flexion from weeks 8 to 12. The brace is discontinued at 12 weeks if the patient has adequate quadriceps control. A full return to sports is permitted at 6 months postoperatively.

Discussion

Avulsion fractures of the tibial tubercle with associated distal patellar tendon ruptures are rare injuries in the athletic adolescent population.¹⁰ Mayba¹¹ first described this injury pattern in 1982 in a 15-year-old long jumper. The majority of these injuries are due to jumping activities or direct trauma to the knee. Kaneko et al.¹² described the mechanism as an eccentric contraction of the quadriceps that causes an initial avulsion fracture of the tuberosity, which progresses to rupture of the patellar tendon with continued force. Biomechanical studies have shown that forces across the extensor mechanism are highest at 60° of flexion and that up to 17.5 times body weight in force is necessary to cause patellar tendon rupture.^{3,13}

The Ogden classification is commonly used to describe these injuries and their variations in intra-articular extension, tuberosity comminution, and displacement.¹⁴ Frankl et al.¹⁵ modified the classification to add a subtype with associated distal patellar tendon avulsion. Additionally, the Siwek and Rao classification¹⁶ of patellar tendon ruptures divides the injuries into acute and chronic groups, which can be helpful in predicting outcomes because early intervention has been shown to lead to improved function.^{2,3}

Table 2. Advantages and Disadvantages of Distal Patellar Tendon SpeedBridge Repair

Advantages
Standard approach and familiar implants to sports-specific surgeon
Low-profile self-reinforcing repair
Excellent strength for early rehabilitation
Disadvantages
Risk of over-tensioning of repair
Risk of type 2 failure
Expense of implants

The evolution of suture anchors and their improved designs have changed the way surgeons are able to approach tendon repair. Mirroring the advances in rotator cuff repair, the innovation of modern suture anchors and high-strength suture material has allowed the use of strong repair constructs for injuries to other tendons such as the Achilles and triceps. Our speed-bridge technique for repair of distal patellar tendon avulsion injuries offers the benefits of a double-row suture anchor construct, which restores the anatomic footprint, uses familiar technology, and provides a strong repair, allowing early active motion.

Variations in patterns of patellar tendon injury make standardized treatment difficult, and many surgical treatments have been described. End-to-end suture repair is possible in midsubstance tears, but concern regarding the strength of the repair during healing has led some authors to recommend cerclage augmentation with wire or graft material.^{1,2} Single-row suture anchor repair techniques have also been reported.¹⁷ However, the strength of these repairs has likewise been questioned, and augmentation with cerclage is commonly recommended.³ The use of graft augmentation carries associated concerns such as autograft harvest—site pain and infection and graft failure with allografts.

Recent biomechanical studies have shown the benefits of double-row suture anchor tendon repair techniques.^{4,18} Such methods promote compression of tendon to bone at the anatomic footprint, which has been shown to encourage early revascularization at the tendon-bone interface in a rabbit rotator cuff model.¹⁹ Suture bridge—type repair offers a strong construct to support early motion during the healing phase, limits surgical time by eliminating Krackow-type sutures, and avoids the need for graft augmentation. Additionally, wider suture tape can be incorporated in a rip-stop fashion with conventional sutures to provide increased compression and overall strength.²⁰

Anatomic double-row repairs have been shown to have higher fixation strength than single-row and point-fixation constructs in triceps and rotator cuff repair.^{3,21} These methods also show minimal gap formation and favorable loads to failure. We endorse SpeedBridge repair of distal patellar tendon avulsion injuries, which provides numerous benefits over traditional methods (Table 2). Our technique provides an anatomic repair with secure fixation of the patellar tendon at the footprint without the need for graft augmentation, bony tunnels, multiple whipstitches, or prominent suture knots.

As with any surgical technique, the limitations should be considered. First and foremost, the cost of the repair with multiple anchors and high-strength sutures exceeds that of simpler methods using only sutures passed through bone tunnels. The potential for a type 2 failure pattern with rerupture is a concern owing to the

strength and configuration of the repair. Iatrogenic fracture of the tibial tuberosity is another unfortunate possibility if careful attention is not paid to adequately spacing the anchors at diverging angles. Despite these limitations, we believe the risks are minimal and support the technique for the multiple potential benefits.

References

1. Muratli HH, Celebi L, Hapa O, Biçimoglu A. Bilateral patellar tendon rupture in a child: A case report. *Knee Surg Sports Traumatol Arthrosc* 2005;13:677-682.
2. Miyamoto S, Otsuka M, Hasue F, et al. Acute traumatic patellar tendon rupture at the tibial tuberosity attachment without avulsion fracture. *Case Rep Orthop* 2017;2017:2537028.
3. Samagh SP, Huyke FA, Buchler L, Terry MA, Tjong VK. Treatment of a neglected patellar tendon rupture with a modified surgical technique: Ipsilateral semitendinosus autograft reconstruction with suture tape augmentation. *Case Rep Orthop* 2018;2018:2037638.
4. Webb LX, Toby EB. Bilateral rupture of the patella tendon in an otherwise healthy male patient following minor trauma. *J Trauma* 1986;26:1045-1048.
5. Pereira AL, Faria ÂRV, Campos TVO, Andrade MAP, Silva GMAE. Tibial tubercle fracture associated with distal rupture of the patellar tendon: Case report. *Rev Bras Ortop* 2018;53:510-513.
6. Bushnell BD, Tennant JN, Rubright JH, Creighton RA. Repair of patellar tendon rupture using suture anchors. *J Knee Surg* 2008;21:122-129.
7. Bhargava SP, Hynes MC, Dowell JK. Traumatic patella tendon rupture: Early mobilisation following surgical repair. *Injury* 2004;35:76-79.
8. West JL, Keene JS, Kaplan LD. Early motion after quadriceps and patellar tendon repairs: Outcomes with single-suture augmentation. *Am J Sports Med* 2008;36:316-323.
9. Arrigoni P, Brady PC, Burkhart SS. The double-pulley technique for double-row rotator cuff repair. *Arthroscopy* 2007;23:675.e1-675.e4.
10. Pendse AD, Bruce D, Chennagiri R, Kankate R. An alternative technique for repair of patellar ligament ruptures with associated tibial tuberosity avulsion fracture. *Int J Orthop* 2016;3:647-649.
11. Mayba II. Avulsion fracture of the tibial tubercle apophysis with avulsion of patellar ligament. *J Pediatr Orthop* 1982;2:303-305.
12. Kaneko K, Miyazaki H, Yamaguchi T. Avulsion fracture of the tibial tubercle with avulsion of the patellar ligament in an adolescent female athlete. *Clin J Sport Med* 2000;10:144-145.
13. Zernicke RF, Garhammer J, Jobe FW. Human patellar-tendon rupture. *J Bone Joint Surg Am* 1977;59:179-183.
14. Ogden JA, Tross RB, Murphy MJ. Fractures of the tibial tuberosity in adolescents. *J Bone Joint Surg Am* 1980;62:205-215.
15. Frankl U, Wasilewski SA, Healy WL. Avulsion fracture of the tibial tubercle with avulsion of the patellar ligament. Report of two cases. *J Bone Joint Surg Am* 1990;72:1411-1413.

16. Siwek CW, Rao JP. Ruptures of the extensor mechanism of the knee joint. *J Bone Joint Surg Am* 1981;63:932-937.
17. McMains MC, Virk S, Fisk E, Fajolu O, Flanigan DC. Simultaneous rupture of patella tendon with tibial tubercle avulsion fracture, anterior cruciate ligament avulsion fracture of the tibial spine in a skeletally mature patient: A case report. *Sport Exerc Med Open J* 2015;1:22-26.
18. Park MC, Pirolo JM, Park CJ, Tibone JE, McGarry MH, Lee TQ. The effect of abduction and rotation on footprint contact for single-row, double-row, and modified double row rotator cuff repair techniques. *Am J Sports Med* 2009;37:1599-1608.
19. Uthoff HK, Sano H, Trudel G, Ishii H. Early reactions after reimplantation of the tendon of supraspinatus into bone: A study in rabbits. *J Bone Joint Surg Br* 2000;82:1072-1076.
20. Burkhart SS, Denard PJ, Konicek J, Hanypsiak BT. Biomechanical validation of load-sharing rip-stop fixation for the repair of tissue-deficient rotator cuff tears. *Am J Sports Med* 2014;42:457-462.
21. Clark J, Obopilwe E, Rizzi A, et al. Distal triceps knotless anatomic footprint repair is superior to transosseous cruciate repair: A biomechanical comparison. *Arthroscopy* 2014;30:1254-1260.