

A Rare Treatable and Under Recognized Cause of Recurrent Convexity Subarachnoid Hemorrhage: Lupus Anticoagulant Hypoprothombinemia Syndrome

Sir,

Convexity subarachnoid hemorrhage (cSAH) is an unusual presentation of subarachnoid bleeding, in which bleeding is localized to the convexities of brain without involvement of adjacent parenchyma or extension into the interhemispheric fissures, basal cisterns, or ventricles. Diverse etiologies are postulated which includes cortical vein occlusion, posterior reversible leukoencephalopathy syndrome (PRES), reversible cerebral vasoconstriction syndrome (RCVS), coagulopathies,

cocaine use, lupus vasculitis, cavernoma, brain abscess, and cerebral amyloid angiopathy (CAA).^[1] Non aneurysmal recurrent convexity subarachnoid haemorrhages are rare in childhood, and presents with headache and may be associated with transient and focal neurological deficits. Here we report a child with recurrent SAH subsequently diagnosed with lupus anticoagulant hypoprothombinemia syndrome.

A thirteen year old girl presented with one and half month history of alternating paucity of movements involving upper

limbs associated with sensory symptoms characterized by numbness and heaviness. Weakness was acute, first involving right upper limb with spontaneous resolution in 2-3 weeks followed by involvement of left upper limb and resolution within 2 weeks. There was no associated loss of consciousness, seizures or trauma at the onset of symptoms. There was no history of rash, photosensitivity, joint pain, alopecia or weight loss. There was no past history of any neuropsychiatric morbidity, or long term drug intake. There was history of recurrent migrainous headache for last two years. Headaches were unilateral occurring on either side, aggravated by light and sound, and used to resolve with analgesics. During menarche at around 11 years of age, she had excessive menorrhagia requiring blood transfusion once. Menorrhagia was not evaluated further as it resolved spontaneously.

She was second born to non-consanguineously married parents. There were no adverse perinatal events and developmental milestones were age appropriate. Family history was non-contributory for significant bleeding and thrombotic disorders. On examination, her general physical examination and neurological examination were normal.

MRI brain done at the onset for recurrent headaches was reportedly normal. They were unavailable for review here. MRI brain repeated at our institution revealed curvilinear hypointensity along the sulci in bilateral fronto-parietal regions in T2W images and blooming in corresponding susceptibility weighted sequence consistent with hemosiderin deposition along the sulci. Post contrast images revealed reactive thickening and enhancement of the overlying dura. Dynamic MR Venogram showed normal venous sinuses and cortical veins and Magnetic Resonance Angiography was also normal [Figure 1]. Differentials considered in view of previous history of recurrent migrainous headaches, convexity subarachnoid hemorrhage and current episodes of transient focal motor and sensory symptoms were vascular malformations, cortical venous thrombosis, coagulation abnormalities and autoimmune disorders. Pertinent lab investigations done are tabulated [Table 1]. Overall lab features confirmed that she has systemic lupus erythematosus based on ANA, dsDNA positivity with hypocomplementemia along with lupus anticoagulant hypoprothrombinemia syndrome with recurrent bleeding manifestations and antiphospholipid antibody positivity.

She was started on high dose prednisolone (2 mg/kg/day) and azathioprine as steroid sparing agent (75 mg/day) and hydroxychloroquine (300 mg/day), along with aspirin at antiplatelet dosage. Her steroids were tapered slowly over next three months and she was continued on azathioprine. After 3 months on treatment, PT was 10.0 secs while aPTT reduced to 40.5 secs. On follow up for the next 11 months, there were no thrombotic or bleeding episodes. Her coagulation profile and complement levels normalized, although dsDNA, anticardiolipin levels and lupus anticoagulant remained abnormal while continuing on azathioprine and hydroxychloroquine.

Convexity subarachnoid hemorrhage (cSAH) is a subtype of subarachnoid bleeding. Cerebral amyloid angiopathy is the commonest cause of cSAH in patients over 60 years of age, while reversible vasoconstriction syndrome is commonest in less than 60 years.^[1,2] Although rare in children and adolescents, various etiologies like posterior reversible leukoencephalopathy syndrome (PRES), reversible cerebral vasoconstriction syndrome (RCVS), lupus vasculitis, infections and brain neoplasm have been reported.^[3-6] Recurrent subarachnoid haemorrhage usually presents with headache, and may be associated with transient and focal neurological events. When the bleeding is chronic, hemosiderin is deposited in the subpial layer of the brain causing superficial siderosis.^[7] Our patient presented with recurrent neurological events and her MRI brain showed residual subarachnoid hemorrhage with hemosiderin deposition along bilateral parietal convexities.

Lupus anticoagulant-hypoprothrombinemia syndrome (LAHS) is the rare association of acquired factor II deficiency and lupus anticoagulant, and it predisposes not only to thrombosis but also to severe bleeding manifestations. LAHS associated with infections appears to be transient, and hemorrhagic manifestations rarely occur. Conversely, LAHS associated with autoimmune diseases, such as SLE, APLA syndrome, or with lymphoma, is more persistent and hemorrhagic complications are a common feature. Prolongation of both PT and aPTT is a pointer towards LAHS, as opposed to antiphospholipid antibody syndrome where there is isolated prolongation of aPTT. Mazodier *et al.* reported 74 patients with LAHS where 58% were females and aged < 15 years at disease onset.^[8] The study also concluded that bleeding was the initial symptom leading to diagnosis of LAHS in 89% of patients, manifestations ranging from minor bleeding like epistaxis, ecchymoses, gingival bleeding and petechial purpura to more severe manifestations including gynaecologic or gastrointestinal bleeding, macroscopic hematuria, intracerebral and intramuscular hematomas. About 5-6% of patients with LAHS develop intracerebral hemorrhage.^[8,9] Our patient showed features suggestive of recurrent cSAH which is an uncommon presentation in children with LAHS and occurred in the absence of significant systemic bleeding manifestations except for one incidence of menorrhagia in the past requiring blood transfusion.

Markers for LAHS diagnosis are positive lupus anticoagulant, prolonged partial thromboplastin time (APTT) and prothrombin time (PT), low levels of Factor II; inhibitor screening positive (mix test) and identification of an anti-prothrombin antibody.^[10] The initial coagulation workup in our patient showed prolongation of both PT/INR and aPTT raising the suspicion of LAHS, whereas antiphospholipid antibody syndrome (APLA) causes isolated elevation of aPTT. LAHS in our patient was further confirmed by markedly elevated lupus anticoagulant and coagulation profile revealing low factor II levels. Our patient was also positive for anticardiolipin antibodies (aCL) and antibodies to B2- Glycoprotein I

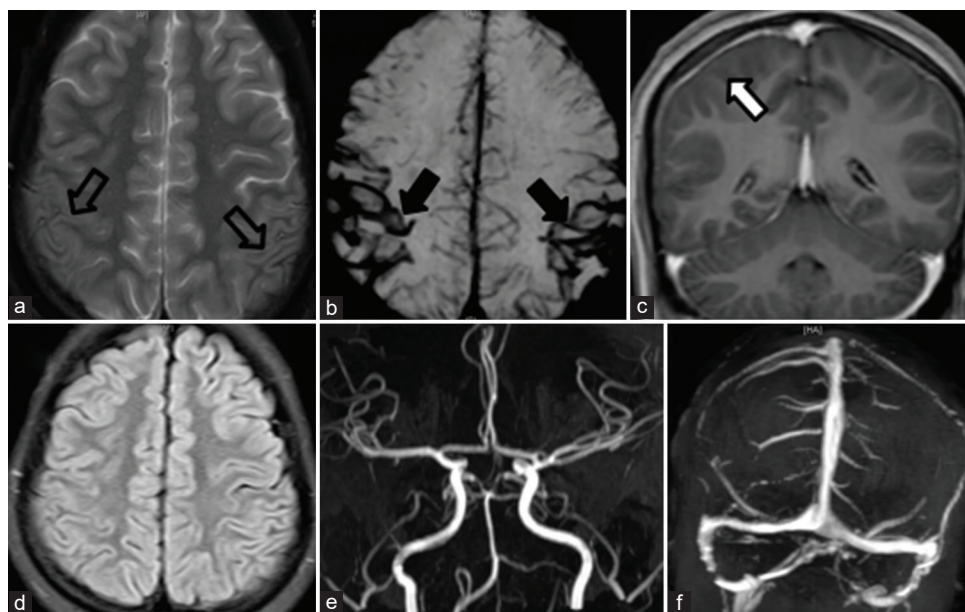


Figure 1: (a) T2W axial image showing curvilinear hypointensity (open black arrows) along the sulci in bilateral frontoparietal regions, consistent with hemosiderin, 'blooming' on the SWI sequence (solid black arrows) (b). (c) On T1W post-contrast sequence, the overlying dura shows reactive thickening and enhancement (white arrow), as a sequel of previous haemorrhage. (d) Corresponding FLAIR axial section did not show any parenchymal signal changes. (e) TOF MR angiogram with normal course and calibre of intracranial arteries. (f) Dynamic MR venogram showed normal venous sinuses and cortical veins

Table 1: Laboratory investigations of the patient

Parameter	Patient value	Normal range (units)
PT	14.7	9.8-12 (secs)
aPTT	61.6	26.5-35.3 (secs)
Hemoglobin	10.6	11-15 (g/dl)
Hematocrit	33.1	35-46 (%)
Platelet count	194000	1,50,000-4,50,000 (mm ³)
DS DNA	260	<100 (IU/ml)
Anti SSA	1	<20 (Ru/ml)
Anti SSB	2	<20(Ru/ml)
Serum complement	<60%	80-96%
C3 Complement	33.8	90-180 (mg/dl)
C4 Complement	<6.75	10-40 (mg/dl)
ANA	Positive	Negative
Anti - PR3	<2	<20 RU/ml
Anti - MPO	2.2	<20 RU/ml
Lupus Anticoagulant	Markedly positive	Negative
IgM Antibodies to B2- Glycoprotein I Complex	33	<20 (RU/ml)
IgG Antibodies to B2- Glycoprotein I complex	>200	<20 (RU/ml)
Anticardiolipin	High positive	<12 GPL
Factor II	11.2%	50-150%
Factor VII	78.7%	50-150%
Factor VIII: C	142%	50-150%
Factor IX: C	103.5%	50-150%
Factor X	89.3%	50-150%
Factor XI	83.2%	50-150%
(LA) Lupus Inhibitor Screen	160.2	28.3-38.3 (secs)
(LA) Lupus Inhibitor Confirm	66.5	27.2-33.6 (secs)
Screen/confirm ratio	2.40	

complex (anti- β 2GPI). Mazodier *et al.* also found aCL and anti- β 2GPI positivity in 33 of 47 cases (70%) and in 8 of

11 cases (73%), respectively. Systemic lupus erythematosus was considered based on positive ANA and dsDNA along with

hypocomplementemia. A recent literature on LAHS associated with systemic lupus erythematosus in children also concluded that LAHS is an uncommon cause of bleeding in patients with SLE and must be suspected in cases with prolongation of both PT and aPTT.^[11]

Management of LAHS presents a unique challenge as these individuals are at risk for both bleeding and thrombotic manifestations. Corticosteroids prescribed at an initial dose of 1 mg/kg/day is usually considered as the first-line treatment. The median delay of PT and/or factor II level normalization on corticosteroids is found to be 25 days (Range from 3 to 120 days).^[8] Alternative therapeutic strategies such as azathioprine, cyclophosphamide, rituximab, or intravenous immunoglobulin have also been tried in few patients.^[12] It is also important to note that the risk of thrombosis increases during initial treatment, as the improvement of PT and prothrombin levels shifts the balance from a pro-hemorrhagic hypoprothrombinemia to a prothrombotic LA state and hence addition of antiplatelets is recommended.

To the best of our knowledge, recurrent and isolated cSAH in LAHS has not been described in the past. We emphasize that LAHS should be considered in the etiological workup of convexity subarachnoid haemorrhage. High index of suspicion is needed in children and young females presenting with recurrent cSAH for evaluation towards LAHS as it is treatable with immunomodulation and further invasive workup including angiography could potentially be avoided.

Declaration of patient consent

The authors certify that they have obtained all appropriate patient consent forms. In the form the patient (s) has/have given his/her/their consent for his/her/their images and other clinical information to be reported in the journal. The patients understand that their names and initials will not be published and due efforts will be made to conceal their identity, but anonymity cannot be guaranteed.

Financial support and sponsorship

Nil.

Conflicts of interest

There are no conflicts of interest.

Shikha Jain¹, Karthik Muthusamy¹, Bernice T S², Himanshu Pansuriya¹, Anu Punnen³, Sathish Kumar³, Maya Mary Thomas¹

¹Division of Paediatric Neurology, Department of Neurological Sciences,

²Department of Radio-diagnosis, ³Division of Pediatric Rheumatology, Department of Paediatrics, Christian Medical College, Vellore, Tamil Nadu, India

Address for correspondence: Dr. Maya Mary Thomas,

Division of Paediatric Neurology, Dept. of Neurological Sciences, Christian Medical College, Vellore - 632 004, Tamil Nadu, India.

E-mail: maya@cmcvellore.ac.in

REFERENCES

1. Kumar S, Goddeau RP Jr, Selim MH, Thomas A, Schlaug G, Alhazzani A, *et al.* Atraumatic convexal subarachnoid hemorrhage: Clinical presentation, imaging patterns, and etiologies. *Neurology* 2010;74:893-9.
2. Khurram A, Kleinig T, Leyden J. Clinical associations and causes of convexity subarachnoid hemorrhage. *Stroke* 2014;45:1151-3.
3. Yoshioka S, Takano T, Ryujin F, Takeuchi Y. A pediatric case of reversible cerebral vasoconstriction syndrome with cortical subarachnoid haemorrhage. *Brain Dev* 2012;34:796-8.
4. Ducros A, Boukobza M, Porcher R, Sarov M, Valade D, Bousser MG. The clinical and radiological spectrum of reversible cerebral vasoconstriction syndrome: A prospective series of 67 patients. *Brain* 2007;130:3091-101.
5. Cuvinciu V, Viguier A, Calviere L, Raposo N, Larrue V, Cognard C, *et al.* Isolated acute nontraumatic cortical subarachnoid hemorrhage. *Am J Neuroradiol* 2010;31:1355-62.
6. Refai D, Botros JA, Strom RG, Derdeyn CP, Sharma A, Zipfel GJ. Spontaneous isolated convexity subarachnoid hemorrhage: Presentation, radiological findings, differential diagnosis, and clinical course. *J Neurosurg* 2008;109:1034-41.
7. Levy M, Turtzo C, Llinas RH. Superficial siderosis: A case report and review of the literature. *Nat Clin Pract Neurol* 2007;3:54-8.
8. Mazodier K, Arnaud L, Mathian A, Costedoat-Chalumeau N, Haroche J, Frances C, *et al.* Lupus anticoagulant-hypoprothrombinemia syndrome: Report of 8 cases and review of the literature. *Medicine (Baltimore)* 2012;91:251-60.
9. Mulliez SM, De Keyser F, Verbist C, Vantilborgh A, Wijns W, Beukinga I, *et al.* Lupus anticoagulant-hypoprothrombinemia syndrome: Report of two cases and review of the literature. *Lupus* 2015;24:736-45.
10. Carvalho C, Viveiro C, Maia P, Rezende T. Acquired antiprothrombin antibodies: An unusual cause of bleeding. *BMJ Case Rep* 2013;2013:bcr2012007948.
11. Paliana RK, Suri D, Jindal AK, Kumar N, Sharma A, Sharma P, *et al.* Lupus anticoagulant hypoprothrombinemia syndrome associated with systemic lupus erythematosus in children: Report of two cases and systematic review of the literature. *Rheumatol Int* 2018;38:1933-40.
12. Shah M.D. Lupus Anticoagulant-hypoprothrombinemia syndrome (LAHPS). In: Teruya J, editor. *Management of Bleeding Patients*. Switzerland: Springer international publishing; 2016. p. 163-8.

Submitted: 25-Jul-2020 **Revised:** 21-Aug-2020 **Accepted:** 28-Sep-2020

Published: 14-Apr-2021

This is an open access journal, and articles are distributed under the terms of the Creative Commons Attribution-NonCommercial-ShareAlike 4.0 License, which allows others to remix, tweak, and build upon the work non-commercially, as long as appropriate credit is given and the new creations are licensed under the identical terms.

DOI: 10.4103/aian.AIAN_804_20