



Ashish K. Jain, Vishal K. Chitikeshi, Pritha Nayyar,
Nitin Dayal, Anuja Anand



Max Super Speciality Hospital, Saket, New Delhi, India.



vishal.chitikeshi@gmail.com

Granulomatous reaction in a patient with lung cancer: should we treat it?

Case report

Cite as: Jain AK, Chitikeshi VK, Nayyar P, *et al.* Granulomatous reaction in a patient with lung cancer: should we treat it? *Breathe* 2018; 14: e94–e99.

Introduction

The presence of granulomatous reaction and lung cancer at the same time is a rare occurrence, which confuses clinicians in deciding the line of treatment. In tuberculosis (TB) endemic regions, the dilemma of considering the presence of TB adds a further complication.

Sampling of mediastinal lymph nodes should be undertaken for staging the disease in a patient with lung cancer, as this is the most important predictor of survival [1]. If granulomas are seen on the cytology specimens, it alerts the clinician to consider TB especially in endemic countries. Other causes would include: sarcoidosis; autoimmune, toxic, drug or allergic responses; fungal infections; and reaction to neoplastic diseases [2]. The presence of granulomas in the lymph nodes draining lung cancer is an unusual phenomenon [3]. Their presence should be carefully examined since the patient could be misdiagnosed with coexistent TB if insufficient work-up for the infection was undertaken and if awareness of such reactions in neoplastic diseases is lacking among the clinicians. Here we report a case of squamous cell carcinoma of the lung with granulomatous reaction in subcarinal lymph node.

2-fluoro-2-deoxy-D-glucose (FDG) avidity of the subcarinal lymph node reduced after the patient underwent treatment for lung cancer and not for TB.

Case presentation

A 63-year-old male presented to the outpatient clinic with complaints of cough with expectoration, weight loss and streaky haemoptysis. He had a smoking history of 25 pack-years. Chest radiography showed an ill-defined opacity at the left hilum with irregular margins and widened mediastinum. We could not perform spirometry since the patient had haemoptysis. A computed tomography (CT) scan of the chest showed a lobulated heterogeneously enhancing necrotic mass in the left hilar region with foci of calcifications and spiculated margins completely encasing the left upper lobe bronchus (figure 1a). There is post-obstructive atelectasis in the lingular segment of left lung. There are enlarged nodes seen in the prevascular, pretracheal, paratracheal, bilateral hilar, carinal and subcarinal region. The patient underwent a positron emission tomography (PET)-CT scan of whole body which showed an FDG avid (maximum standardised uptake value (SUV):14.5), heterogeneously



@ERSpublications

In TB endemic regions, granulomatous inflammation in the samples from a tumour in the lung or in the draining lymph nodes will not be sufficient to diagnose TB as granulomas can also arise as a reaction to tumour cells <http://ow.ly/tOTm30kSFAY>



© ERS 2018

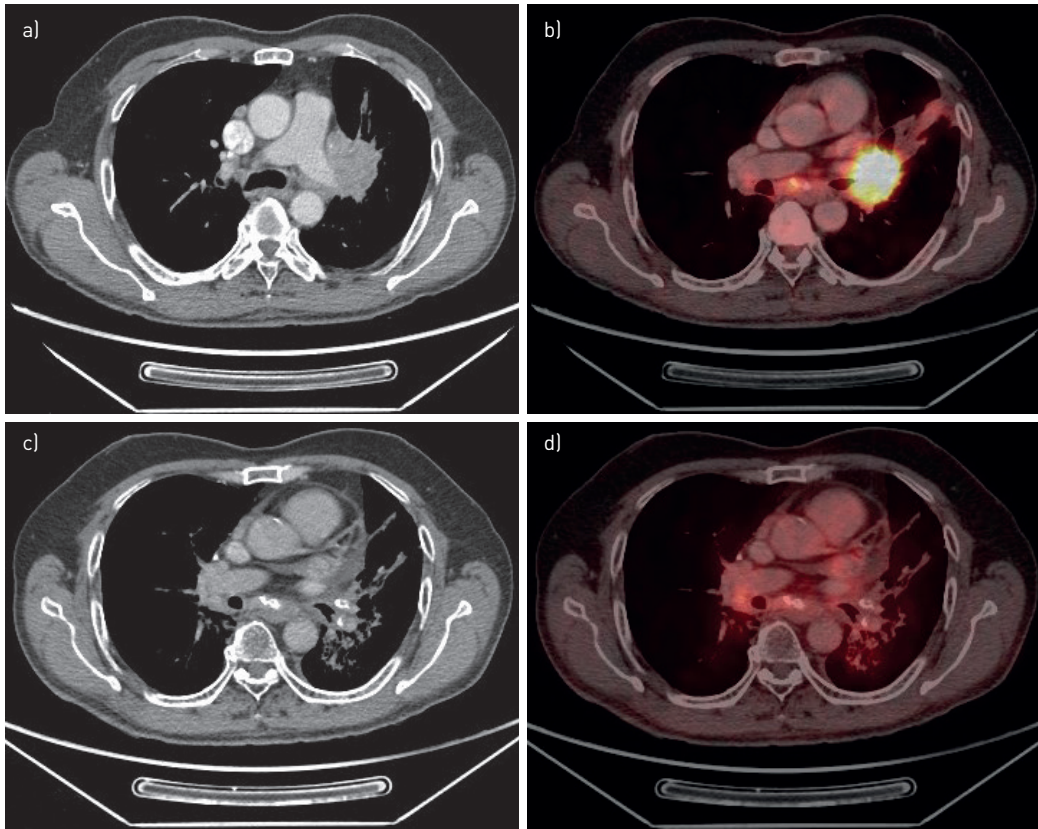


Figure 1 a) Chest CT showing a lobulated necrotic mass in left hilar region with foci of calcifications and spiculated margins at the time of diagnosis. b) PET-CT carried out at the time of diagnosis showing FDG uptake with a SUV of 14.5; an FDG avid (SUV 5.9) subcarinal lymph node is also shown in the image. c) CT carried out 12 months later showing resolution of the hilar mass. d) PET-CT carried out 12 months later showing reduced uptake in the subcarinal lymph node.

enhancing mass lesion with spiculated margins in the left hilar region, encasing the left upper lobe and lingular lobe bronchus, superior pulmonary vein and left pulmonary artery. FDG avid (maximum SUV: 5.9) lymph nodes were noted in the prevascular, pretracheal, paratracheal, subcarinal, right hilar and bilateral tracheobronchial region (figure 1b).

Task 1

At this stage, what is your approach in this patient?

- CT-guided biopsy of left hilar lymph node
- Fibre-optic bronchoscopy with transbronchial needle aspiration (TBNA)
- Fibre-optic bronchoscopy followed by mediastinoscopy
- Fibre-optic bronchoscopy followed by endobronchial ultrasound-guided (EBUS-) TBNA

Answer 1

d) Fibre-optic bronchoscopy followed by EBUS-TBNA

Fibre-optic bronchoscopy was performed and a mass was seen at the level of the left lower lobe bronchus. The mass was extending into the mucosa of left main bronchus. Endobronchial biopsy was carried out and histopathological examination confirmed squamous cell carcinoma of lung (figure 2). The patient underwent endobronchial ultrasound-guided transbronchial needle aspiration (EBUS-TBNA) of the mediastinal lymph nodes along with rapid on-site evaluation (ROSE). In the cytological evaluation, the left hilar lymph nodes

(station 10) showed evidence of malignant cells and the subcarinal lymph node (station 7) revealed epithelioid cell granuloma with polymorphous lymphoid cells and occasional multinucleated giant cells (figure 2). The other group of lymph nodes did not show any evidence of malignant cells.

Task 2

What is the staging of the patient?

- a) Stage IIA
- b) Stage IIB
- c) Stage IIIA
- d) Stage IV
- e) Stage IIIB

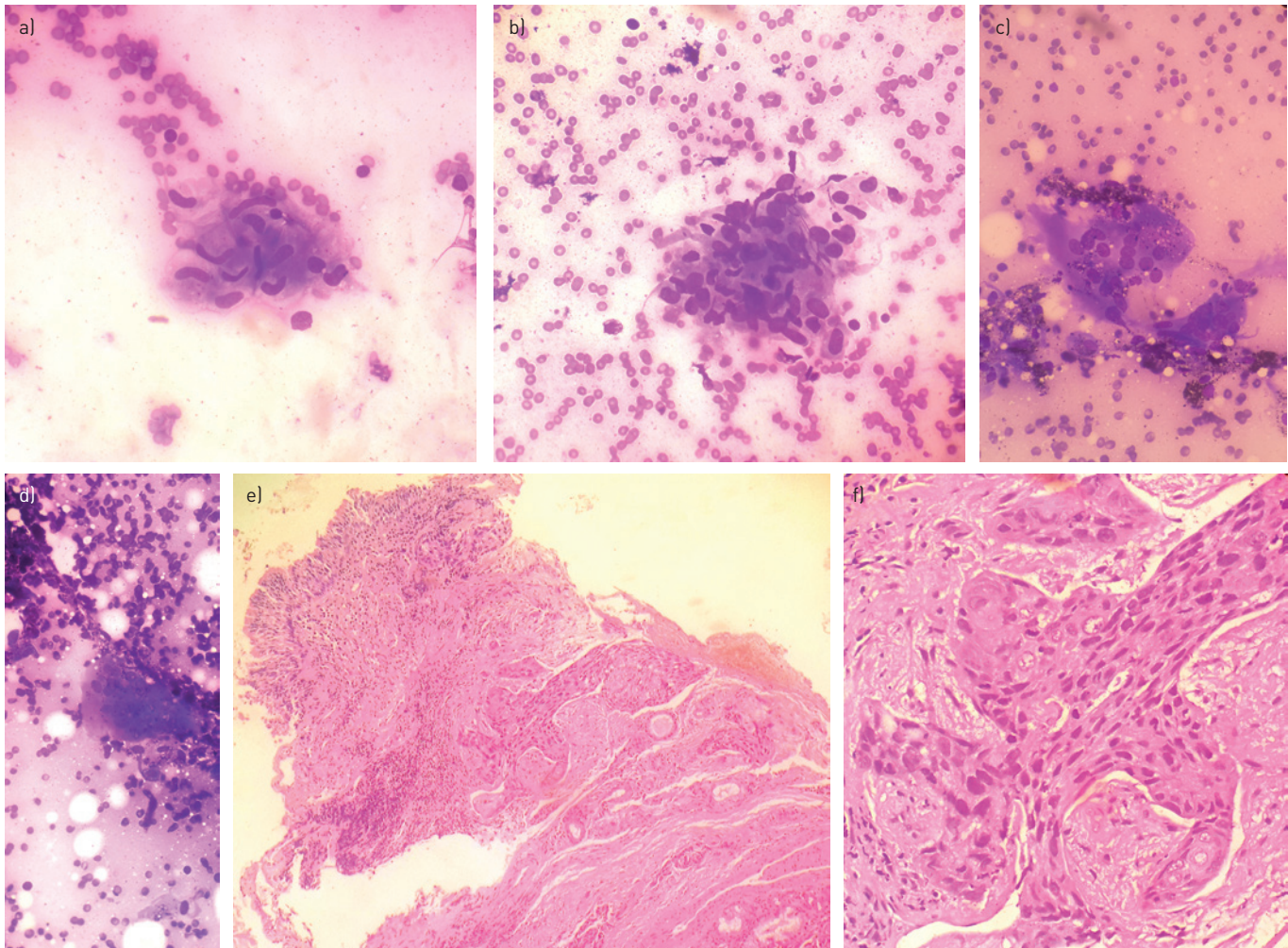


Figure 2 In EBUS-TBNA smears scattered epithelioid cell granulomas (panels a and b) were seen along with occasional multinucleated giant cells (panels c and d). e) Bronchial biopsy showed a normal bronchial epithelial lining with invasive squamous cell carcinoma in the submucosal area. f) The invasive component of squamous cell carcinoma shown in high power.

Answer 2

c) Stage IIIA

According to TNM (tumour, node, metastasis) staging, the patient was staged as T4N1M0 because major vessels were involved and the ipsilateral hilar nodes were positive, and there was no evidence of separate tumour nodules in contralateral lobes or pleural or pericardial effusion and no distant metastasis was found [3].

Task 3

What is the treatment approach for this patient?

- a) Concurrent chemoradiotherapy
- b) Neo-adjuvant chemotherapy followed by surgery
- c) Concurrent chemoradiotherapy along with anti-tubercular treatment
- d) Palliative chemotherapy
- e) Anti-tubercular treatment followed by chemoradiotherapy
- f) Surgery followed by adjuvant chemotherapy

Answer 3

a) Concurrent chemoradiotherapy. Stage IIIA can be given treatment options like surgery after neoadjuvant chemotherapy or surgery followed by adjuvant chemotherapy; however, in this patient since Tumour staging is T4, as major vessels were involved, surgery has very little role. Hence the patient was treated with concurrent chemoradiotherapy [4]. Presence of granuloma in the subcarinal lymph node could be a reaction to cancer cells and anti-tubercular treatment is not necessary even in TB endemic countries. In addition, the work-up for the presence of TB was negative. The TBNA aspirate was negative for acid-fast bacilli (AFB) by staining, culture and molecular-based methods (Hain test; bioMérieux SA, Marcy l'Etoile, France). Also work-up for fungal infections and systemic sarcoidosis was negative. Hence we did not consider the coexistence of TB or any other cause of granulomatous infection and the patient was advised to undergo treatment for lung cancer.

The patient was staged as IIIA and treated with concurrent chemoradiotherapy and followed up in remission. After 12 months of follow up, a PET-CT scan was carried out and showed no increase in size or uptake of the lymph nodes (figure 1d).

Discussion

In TB endemic regions, like India, the presence of granuloma in a specimen is usually considered TB unless proven otherwise due to lack of resources. The coexistence of granulomatous reaction and lung cancer, either in the same specimen or in the draining lymph nodes, has been rarely reported and the explanation for the granulomatous reaction was probably an immunological reaction to the cancer cells [5, 6]. Some of the causes listed were idiopathic, foreign body reaction to tumour cells, therapy related, metastasis, and associated TB or sarcoidosis [6]. DAGAONKAR *et al.* [7] described this phenomenon as a “sarcoid like reaction” to the tumour antigens and concluded that these specimens should be tested for AFB by staining and culture methods before subjecting the patient to chemotherapy. They also said that, even in

endemic countries, it is not necessary to treat this unless cultures are positive [7]. In our case, we advised the patient to undergo treatment for lung cancer and did not treat for TB at the same time.

KENNEDY *et al.* [8] reported that 17 out of 153 consecutive patients with lung cancer undergoing EBUS-TBNA showed granuloma, out of which eight showed sarcoidosis, another eight showed sarcoid-like lymphadenopathy and one showed nontuberculous mycobacteria. There are also case reports which showed the presence of granulomas as well as malignant cells in the same specimen [9]. By contrast, in our case, the draining lymph node, *i.e.* the subcarinal lymph node, showed only granuloma and no malignant cells.

The prognostic importance of this reaction in the draining lymph nodes in lung cancer was studied by following up patients after surgery. It was observed that the prognosis of such patients is same as those without granuloma and hence the presence of granuloma was concluded to have no prognostic importance [10].

Methods to differentiate malignant nodes from nonmalignant nodes have been studied: FDG PET-CT is not a good option since false positive results are seen with infection or inflammation in these nodes. The ideal way to differentiate the two is to sample the nodes using EBUS-TBNA or mediastinoscopy [11]. Further, to identify TB samples undergo immunohistochemical analysis to identify the increased expression of interleukin-10 and tumour necrosis factor- α , which suggest tubercular lymphadenitis; however, these methods need further studies and standardisation [12].

Here we present a case report of a patient diagnosed to have squamous cell carcinoma of lung with N1 node positivity. EBUS-TBNA sampling of the subcarinal lymph node showed granulomas with multinucleated giant cells. Sample examination for AFB and fungal stain did not show any evidence of infection and hence the patient was followed up on concurrent chemoradiotherapy. A follow-up PET-CT scan did not show any increase in size or uptake, concluding that this was probably a sarcoid-like reaction. Therefore, whenever a granulomatous reaction is seen in cancer specimens, or in the draining lymph nodes or in the surrounding stroma, it should be kept in mind that these granulomas could be a result of an immunological reaction to the tumour cells and may not always be due to infection.

Conflict of interest

None declared.

References

1. Goldstraw P, Crowley J, Chansky K, *et al.* The IASLC lung cancer staging project: proposals for the revision of the TNM stage groupings in the forthcoming (seventh) edition of the TNM classification of malignant tumours. *J Thorac Oncol* 2007; 2: 706-714.
2. Shah KK, Pritt BS, Alexander MP. Histopathologic review of granulomatous inflammation. *J Clin Tuberc Mycobact Dis* 2017; 7: 1-12.
3. Kay FU, Kandathil A, Batra K, *et al.* Revisions to the Tumor, Node, Metastasis staging of lung cancer (8th edition):

- Rationale, radiologic findings and clinical implications. *World J Radiol* 2017; 9: 269–279.
4. Ettinger DS, Wood DE, Aisner DL, *et al.* Non-Small Cell Lung Cancer, Version 5.2017, NCCN Clinical Practice Guidelines in Oncology. *J Natl Compr Cancer Netw* 2017; 15: 504–535.
 5. Abin VT, Arjun P, Ameer KA, *et al.* Coexistent pulmonary tuberculosis and carcinoma lung diagnosed from the same clinical specimen – a case report. *J Pulm Respir Med* 2015; 5: 274.
 6. Dasgupta A, Singh N, Bhatia A. Abdominal tuberculosis: a histopathological study with special reference to intestinal perforation and mesenteric vasculopathy. *J Lab Physicians* 2009; 1: 56–61.
 7. Dagaonkar RS, Choong CV, Asmat AB, *et al.* Significance of coexistent granulomatous inflammation and lung cancer. *J Clin Pathol* 2017; 70: 337–341.
 8. Kennedy MP, Jimenez CA, Mhatre AD, *et al.* Clinical implications of granulomatous inflammation detected by endobronchial ultrasound transbronchial needle aspiration in patients with suspected cancer recurrence in the mediastinum. *J Cardiothorac Surg* 2008; 3: 8.
 9. Coyne JD. Necrobiotic palisading granulomas associated with breast carcinoma. *J Clin Pathol* 2005; 58: 1290–1293.
 10. Tomimaru Y, Higashiyama M, Okami J, *et al.* Surgical results of lung cancer with sarcoid reaction in regional lymph nodes. *Jpn J Clin Oncol* 2007; 37: 90–95.
 11. Rosenbaum SJ, Lind T, Antoch G, *et al.* False-positive FDG PET uptake—the role of PET/CT. *Eur Radiol* 2006; 16: 1054–1065.
 12. Mustafa T, Mogga SJ, Mfinanga SGM, *et al.* Immunohistochemical analysis of cytokines and apoptosis in tuberculous lymphadenitis. *Immunology* 2006; 117: 454–462.