



## Aspergillosis in free-ranging aquatic birds

Aryse Martins Melo<sup>a,b,g,\*</sup>, Rodolfo Pinho da Silva-Filho<sup>b</sup>, Vanice Rodrigues Poester<sup>c</sup>,  
 Andrea von Groll<sup>c</sup>, Cristina Gevehr Fernandes<sup>d</sup>, David A. Stevens<sup>e,f</sup>, Raquel Sabino<sup>g</sup>,  
 Melissa Orzechowski Xavier<sup>a,c,f</sup>

<sup>a</sup> Programa de Pós-Graduação em Microbiologia e Parasitologia, Instituto de Biologia, Universidade Federal de Pelotas, Avenida Eliseu Maciel, S/n, Pelotas, RS, Brazil

<sup>b</sup> Centro de Recuperação de Animais Marinhos, Universidade Federal do Rio Grande, Rio Grande, RS, Brazil

<sup>c</sup> Programa de Pós-Graduação em Ciências da Saúde, Faculdade de Medicina, Universidade Federal do Rio Grande, Rua General Osório, 1109, Rio Grande, RS, Brazil

<sup>d</sup> Faculdade de Veterinária, Universidade Federal de Pelotas, Avenida Eliseu Maciel, S/n, Pelotas, RS, Brazil

<sup>e</sup> Division of Infectious Diseases and Geographic Medicine, Stanford University Medical School, Stanford, CA, USA

<sup>f</sup> California Institute for Medical Research, San Jose, CA, USA

<sup>g</sup> Department of Infectious Diseases/ Reference Unit for Parasitic and Fungal Infections, National Institute of Health, Dr. Ricardo Jorge, Lisbon, Portugal



### ARTICLE INFO

#### Keywords:

*Procellaria aequinoctialis*  
*Chroicocephalus maculipennis*  
*Nannopterum brasilianus*  
 Sequencing  
*Aspergillus fumigatus*

### ABSTRACT

**Background:** Due to the difficulty in the access to free-ranging birds, data regarding *Aspergillus* infections in wild avian species is rare compared to captive wild and domestic birds. **Objective:** report three cases of *Aspergillus* section *Fumigati* causing fungal disease in free-ranging aquatic birds, with the identification of the causal agent to the species level. **Case reports:** The diagnosis of aspergillosis was performed by macroscopic lesions found during the necropsy and confirmed by culture. Molecular identification by partial sequencing of the *calM* and *benA* genes allowed to confirm *Aspergillus fumigatus sensu stricto* as the etiological agent of aspergillosis in *Procellaria aequinoctialis* (White-chinned petrel) (n = 1), *Nannopterum brasilianus* (Neotropical cormorant) (n = 1) and *Chroicocephalus maculipennis* (Brown-hooded gull) (n = 1). **Conclusion:** Larger studies regarding the importance of aspergillosis in free-ranging aquatic birds are necessary, as well as its potential role in the One Health context.

### 1. Introduction

Aspergillosis is a common fungal disease in birds, mainly due to their physiological and anatomical characteristics of the respiratory system [1]. This mycosis is widely reported in captive [1–3], but less frequently in free-living birds [4].

Aquatic birds are species that live in marine or freshwater environments mainly for foraging activities. *Procellaria aequinoctialis* (White-chinned petrel), classified as vulnerable according to Red List of the International Union for Conservation of Nature (IUCN), has a circumpolar distribution, breeds in sub-Antarctic oceanic islands, and migrates to the southern Brazilian ocean to feed, mainly during non-breeding season, in the austral winter. *Chroicocephalus maculipennis* (Brown-hooded gull) is classified as a “least concern” resident species according to IUCN. In Brazil, it breeds in the interior of the country and migrates to the coast in the non-breeding period. *Nannopterum brasilianus* (Neotropical cormorant) is, according to IUCN, a “least concern” species, non-migrant, with distribution from South America to southern United States [5,6].

Due to the difficulty in the access to free-ranging birds, data about *Aspergillus* infections in wild avian species is scarce. There are some reports of epizootic deaths related to feeding of contaminated food as moldy corn and rotten silage [4], beyond this, reports of aspergillosis in aquatic birds are less common than those in terrestrial birds [4].

Given that migration is a natural behavior in some species, birds could be associated with the introduction of new and foreign fungal strains in distinct regions. Since fungal reproductive structures are commonly produced in air sacs of these animals, it is possible that they can exhale conidia during breathing [1]. It is also possible that transmission could occur from decaying cadavers. Additional information about aspergillosis in free-ranging birds is an important tool for a better comprehension and monitoring of the disease in nature. Therefore, this study aimed to describe three cases of the *Aspergillus* infection in free-ranging aquatic birds, with the molecular identification of the causal agent to species level.

\* Corresponding author. Programa de Pós-Graduação em Microbiologia e Parasitologia, Instituto de Biologia, Universidade Federal de Pelotas, Avenida Eliseu Maciel, s/n, Pelotas, RS, Brazil..

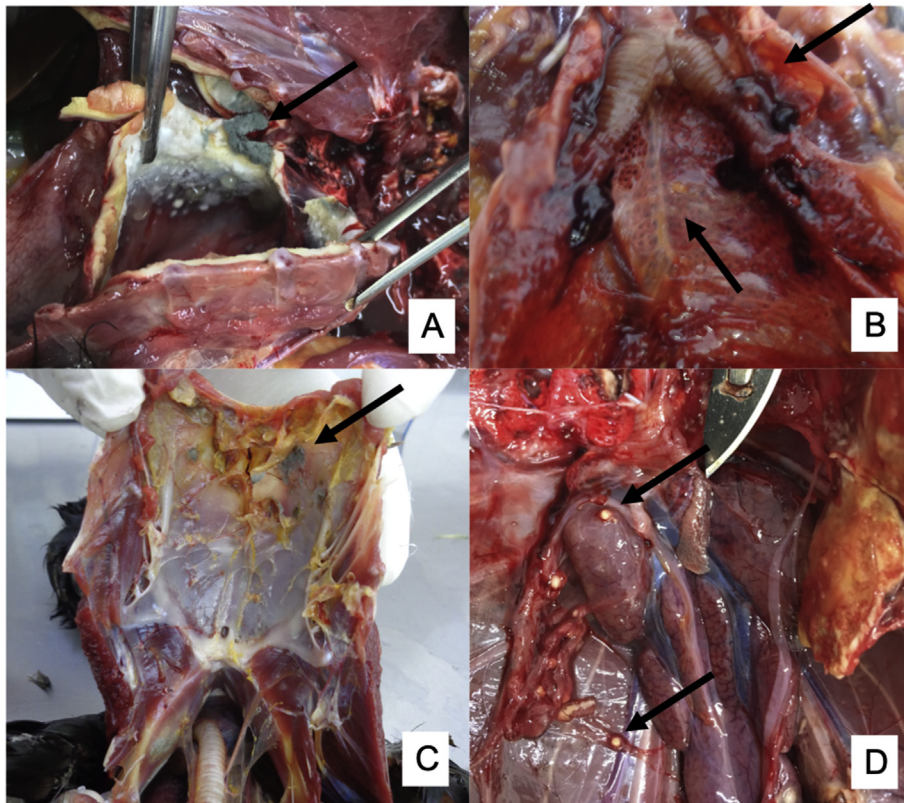
E-mail address: [arysemartins@gmail.com](mailto:arysemartins@gmail.com) (A.M. Melo).

<https://doi.org/10.1016/j.mmcr.2020.04.005>

Received 23 March 2020; Received in revised form 14 April 2020; Accepted 17 April 2020

Available online 28 April 2020

2211-7539/ © 2020 The Authors. Published by Elsevier B.V. on behalf of International Society for Human and Animal Mycology. This is an open access article under the CC BY-NC-ND license (<http://creativecommons.org/licenses/by-nc-nd/4.0/>).



**Fig. 1.** Macroscopic lesions of aspergillosis in free-birds: A) Fungal colonies in the air sacs of *Procelleria aequinoctialis*; B) White-yellow granulomas in the lungs and air sacs in *Chroicocephalus maculipennis*; C) Fungal colonies in air sacs in *Nannopterum brasilianus*; D) White-yellow granulomas in kidney and peritoneum of *Procelleria aequinoctialis*. (For interpretation of the references to colour in this figure legend, the reader is referred to the Web version of this article.)

## 2. Cases

During the years 2017 and 2018, three fatal proven cases of aspergillosis in free-ranging aquatic birds from three distinct species were diagnosed in the Center of Recovery of Marine Animals (CRAM-FURG) in Rio Grande, Rio Grande do Sul, South Brazil. The three birds were severely ill, were gathered in Cassino beach (32° 9'40.71"S e 52° 5'51.71"O), Rio Grande, Rio Grande do Sul, South Brazil and died during their transportation to the Center.

Infected avian individuals were a male *N. brasilianus* weighing 840 g (reference weight 1200–1400g), a female *P. aequinoctialis* weighing 762 g (reference weight 1020–1550g), and a male *C. maculipennis* weighing 308 g (reference weight 290–360g). The three birds were adult and none of them showed evidence of traumatic lesions during the carcass examination.

White-yellow granulomas (ranging from 0.1cm to 0.5cm) were found in the air sacs and in the lungs of the three birds. The petrel and the cormorant showed thickening of air sacs and fungal colonies in the air sacs and in the bronchi. In addition, granulomas were also found in the kidneys of the petrel. (Fig. 1).

Tissue samples from the three birds were cultured on Sabouraud Dextrose Agar and pure blue-green fungal colonies were obtained after 48h incubation at 30 °C. Isolates were identified phenotypically (macro- and micromorphology) as *Aspergillus* section *Fumigati*. DNA extraction was performed and the identification of isolates at the species level was done by molecular sequencing of partial *calM* [7] and partial *benA* genes [8].

Sequencing of partial *benA* was performed by ACTGene Análises Moleculares Ltd. (Center for Biotechnology, UFRGS, Porto Alegre, RS, Brazil), and sequencing of partial *calM* was performed at National Institute of Health Dr. Ricardo Jorge, Lisbon, Portugal. Nucleotide sequences were aligned using the “Mega” software version 7.0 and species homology was defined by comparing the nucleotide sequences by BLAST on the website <https://blast.ncbi.nlm.nih.gov/Blast.cgi>. The sequencing data showed that *Aspergillus fumigatus sensu stricto* was the

etiological agent of aspergillosis in the three birds. Sequences obtained were deposited in GenBank data base [Accession numbers (*benA*: MN250367, MN250368 and MN250369) and (*calM*: MN746387, MN746388 and MN746389)].

## 3. Discussion

It is well established that aspergillosis is a highly prevalent disease in captive birds [2,9]. However, there is no agreement in the scientific literature about the importance of this disease in free-living birds. While some authors consider aspergillosis as rare in free birds [10], others affirm that this is the most common disease among medical conditions not induced by trauma [11,12]. Our studies, focused on three different aquatic avian species found in nature (in south Brazil) and infected by *Aspergillus* spp., indicate the need for more investigation about aspergillosis in free-ranging birds.

Both the petrel and the cormorant were in poor physical condition at the time of the diagnosis, but we cannot assume that this condition was a predisposing factor to aspergillosis development, since it could also be a consequence of the disease progression [13]. In contrast, the gull was in good general physical condition, and no evidence of a known predisposing factor was observed, suggesting that aspergillosis could have occurred as a primary disease in this bird [12].

Some species of aquatic birds travel for long periods during the migration, even crossing oceans, and are, therefore, difficult to access [14]. The occurrence of neotropical cormorants is more common among the Patos lagoon estuary (32° 02' 6.00" S/52° 05' 55.00" W), but groups of these birds in the Cassino beach are frequently observed. It is important to highlight that the region of Patos lagoon estuary is highly populated, with animals and humans sharing the same environment. Similarly, the brown-hooded gull occurs in both environments cited previously but in the open-air garbage dump too. On the other hand, the white-chinned petrel, a migrating oceanic bird, feeds in the Brazilian waters, and reproduces in sub Antarctic islands. The occurrence of these birds in the beaches may occur as consequence of injury,

debilitation, or diseases.

*Aspergillus fumigatus sensu stricto*, the etiologic agent of all the aspergillosis cases from our study, remains the main causal agent of the *Fumigati* section involved in avian aspergillosis [2,3,9], as well as in mammals affected by the disease [1]. Besides the production of gliotoxin, an immunosuppressive mycotoxin [15], the thermotolerance of *A. fumigatus sensu stricto* could be a factor that promotes a better fungal growth at avian body temperatures [16].

Our data, showing the occurrence of aspergillosis in free-living birds acquired in a natural environment, stress that the dissemination of pathogens by migrating birds should also be considered [17]. With the emergent concern regarding azole resistance in *Aspergillus fumigatus*, the environment plays an important role in this context. Since most environmental strains can infect and cause aspergillosis in susceptible hosts, without differences in virulence attributes of clinical *versus* environmental isolates [18], there is a need for thinking about the spread of potential pathogenic fungi as a global concern [19].

The human population in coastal areas is greater than inland [20], and humans share this environment with other animals, such as aquatic birds. In this context, and taking in consideration the previously mentioned concerns for *Aspergillus* resistance and the potential importance of dissemination of pathogens by migrating birds, free-ranging aquatic birds should be monitored for aspergillosis in order to increase the knowledge of *Aspergillus* epidemiology in the context of *One Health*, in which humans, animals and environments are understood to be all connected [19].

To our knowledge, this is the first report of aspergillosis in the bird species *Procellaria aequinoctialis*, *Chroicocephalus maculipennis* and *Nannopterum brasilianus*. The obtained data suggests that aspergillosis in wild birds could be more prevalent than previously thought.

#### Declaration of competing interest

There are none.

#### Acknowledgements

The authors would like to thank staff and volunteers from the Rehabilitation Center of Marine Animals (CRAM-FURG).

This study was supported by the International Cooperation Program financed by Brazilian Federal Agency for Support and Evaluation of Graduate Education within the Ministry of Education of Brazil (CAPES), under the Capes-Print Program and PDSE Program - Finance Code 001.

#### References

- [1] L.A. Tell, Aspergillosis in mammals and birds: impact on veterinary medicine, *Med. Mycol.* 43 (s1) (2005) 71–73.
- [2] J.J. Talbot, P. Thompson, L. Vogelneust, V.R. Barrs, Identification of pathogenic *Aspergillus* isolates from captive birds in Australia, *Med. Mycol.* 56 (8) (2018) 1038–1041.
- [3] R. Sabino, J. Burco, J. Valente, C. Veríssimo, K.V. Clemons, D.A. Stevens, et al., Molecular identification of clinical and environmental avian *Aspergillus* isolates, *Arch. Microbiol.* 201 (2) (2019) 253–257.
- [4] K. Converse, Aspergillosis, in: N. Thomas, D. Hunter, C. Atkinson (Eds.), *Infectious Diseases of Wild Birds*, 2008, pp. 360–374.
- [5] C.M. Vooren, L.F. Brusque, As Aves Do Ambiente Costeiro Do Brasil: biodiversidade E Conservação. Programa Nacional da Diversidade Biológica—PRONABIO, Subprojeto “Avaliação e Ações Prioritárias para a Zona Costeira e Marinha”, área temática “Aves marinhas”, *Aves marinhas* (1999) 182.
- [6] BirdLife International, *Procellaria Aequinoctialis*, *Chroicocephalus Maculipennis*, *Nannopterum Brasilianus*, The IUCN Red List of Threatened Species, 2018.
- [7] S.-B. Hong, S.-J. Go, H.-D. Shin, J.C. Frisvad, R.A. Samson, Polyphasic taxonomy of *Aspergillus fumigatus* and related species, *Mycologia* 97 (6) (2005) 1316–1329.
- [8] J.F. Staab, S.A. Balajee, K.A. Marr, *Aspergillus* section *Fumigati* typing by PCR-restriction fragment polymorphism, *J. Clin. Microbiol.* 47 (7) (2009) 2079–2083.
- [9] J.D. Burco, K.A. Etienne, J.G. Massey, M.H. Ziccardi, S.A. Balajee, Molecular subtyping suggests that the environment of rehabilitation centers may be a potential source of *Aspergillus fumigatus* infecting rehabilitating seabirds, *Med. Mycol.* 50 (1) (2012) 91–98.
- [10] M. Heidenreich, *Birds of prey: medicine and management/Krankheit der Greifvogel*, (1997).
- [11] D.C. Carrasco, N.A. Forbes, Aspergillosis: update on causes, diagnosis and treatment, *Companion Anim* 21 (1) (2016) 50–57.
- [12] P. Olias, A.D. Gruber, B. Winfried, H.M. Hafez, M. Lierz, Fungal pneumonia as a major cause of mortality in white stork (*Ciconia ciconia*) chicks, *Avian Dis Dig* 5 (1) (2010) e36–e37.
- [13] E.A. Young, T.E. Cornish, S.E. Little, Concomitant mycotic and verminous pneumonia in a blue jay from Georgia, *J. Wildl. Dis.* 34 (3) (1998) 625–628.
- [14] E.K. Mackley, R.A. Phillips, J.R.D. Silk, E.D. Wakefield, V. Afanasyev, R.W. Furness, At-sea activity patterns of breeding and nonbreeding white-chinned petrels *Procellaria aequinoctialis* from South Georgia, *Mar. Biol.* 158 (2) (2011) 429–438.
- [15] V.M. de Oca, S.E. Valdés, C. Segundo, G.G. Gómez, J. Ramírez, R.A. Cervantes, Aspergillosis, a natural infection in poultry: mycological and molecular characterization and determination of gliotoxin in *Aspergillus fumigatus* isolates, *Avian Dis.* 61 (1) (2017) 77–82.
- [16] J.C. Rhodes, *Aspergillus fumigatus*: growth and virulence, *Med. Mycol.* 44 (SUPPL. 1) (2006) 77–81.
- [17] G.-B. Mircea, D. Ioana, P. Em Ke, N. Mihaela, S. Marina, Wild birds as potential vectors for pathogen dissemination on migration routes in the Danube Delta Wetlands, *IntJCurrMicrobiolAppSci* 3 (5) (2014) 890–897.
- [18] P. Olias, A.D. Gruber, H.M. Hafez, M. Lierz, S. Slesiona, M. Brock, et al., Molecular epidemiology and virulence assessment of *Aspergillus fumigatus* isolates from white stork chicks and their environment, *Vet. Microbiol.* 148 (2–4) (2011) 348–355.
- [19] A. Chowdhary, J.F. Meis, Emergence of azole resistant *Aspergillus fumigatus* and One Health: time to implement environmental stewardship, *Environ. Microbiol.* 20 (2018) 1299–1301.
- [20] C. Small, R.J. Nicholls, A global analysis of human settlement in coastal zones, *J. Coast Res.* 19 (3) (2003) 584–599.