

Dieulafoy's lesion of the rectum: a case report and review of the literature



Authors

Mo Wang, Xiang Bu, Jing Zhang, Shanshan Zhu, Ying Zheng, Xinxing Tantai, Shiyang Ma

Institution

Division of Gastroenterology, The Second Affiliated Hospital, Xi'an Jiaotong University, Xi'an, Shaanxi 710004, PR China

submitted 16.1.2017

accepted after revision 2.5.2017

Bibliography

DOI <https://doi.org/10.1055/s-0043-114661> |
Endoscopy International Open 2017; 05: E939–E942
© Georg Thieme Verlag KG Stuttgart · New York
ISSN 2364-3722

Corresponding author

Shiyang Ma, MD, Division of Gastroenterology, The Second Affiliated Hospital, Xi'an Jiaotong University, No. 157, Xi Wu Road, Xi'an, Shaanxi 710004, PR China
Fax: +86-29-87679290
shiyangma@163.com

ABSTRACT

One patient with Dieulafoy's lesion (DL) of the rectum who had a history of anal receptive intercourse is described and the relevant literature reviewed. DL is rare in clinical practice and is extremely rare in the rectum. It often affects patients with no history of cirrhosis or gastrointestinal disease and occurs with abrupt or recurrent gastrointestinal bleeding. Visible vessels can usually be found by endoscopy and coinstantaneous treatments are essential while surgical interventions can occur when necessary. The diagnosis of DL is mainly based on clinical manifestations and endoscopic features, and endoscopic treatment is the first option for hemostasis.

Introduction

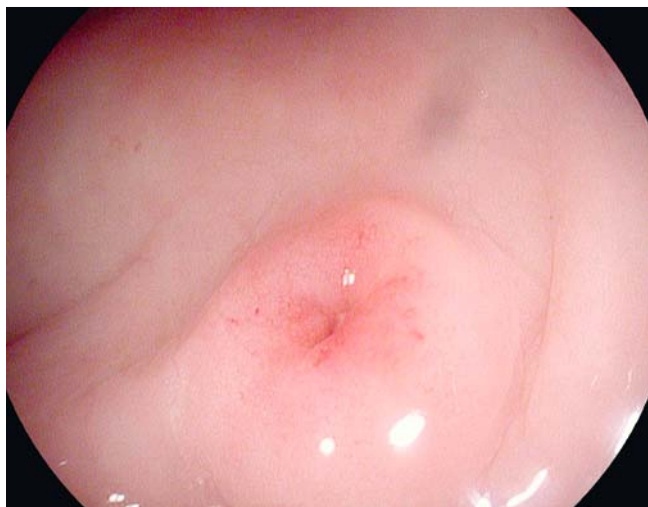Dieulafoy's lesion (DL), also called "caliber persistent artery", is a rare cause of gastrointestinal bleeding. It accounts for about 6% of gastrointestinal nonvariceal bleeding, and 1% to 2% of all acute gastrointestinal hemorrhages [1, 2]. The incidence of DL is potentially higher than reports suggest because of the difficulty of making the correct diagnosis. It was initially described as "miliary aneurysms in stomach" by Gallard in 1884, and given a more exact definition by French surgeon Georges Dieulafoy in 1898, on the basis of his study of alimentary tract hemorrhage in three young men. Since then, with the development of gastrointestinal endoscopy, more and more cases of DL have been reported worldwide. According to most of the reports, DL can occur in the stomach (71%), duodenum (15%), esophagus (8%), colon (2%), rectum (2%), jejunum-ileum (1%), and gastric anastomosis (1%) [3, 4].

We present a case of DL in a young man who had a history of anal receptive sexual intercourse.

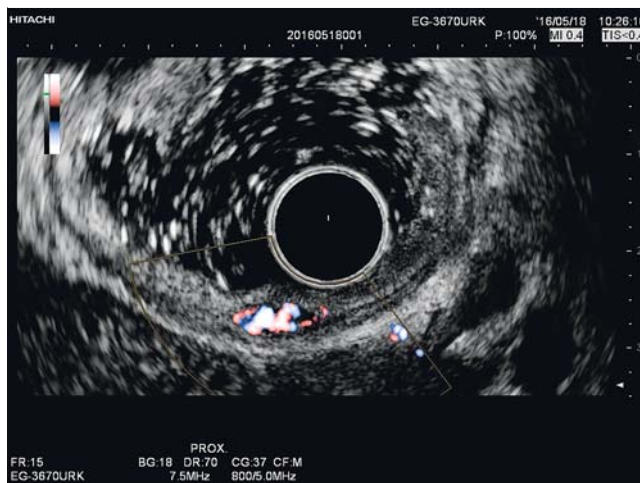Case report

A 21-year-old man was admitted to our digestive department because of intermittent bloody stool passage for a week. The patient did not suffer from abdominal pain, his vital signs were stable (heart rate 71 bpm, blood pressure 115/75 mmHg), and he had no other clinical manifestations apart from hematochezia. He had no history of gastrointestinal disease or liver disease, no history of alcohol, smoking or drug abuse, and was negative for *Helicobacter pylori* infection. The only point worth mentioning was a history of anal receptive intercourse.

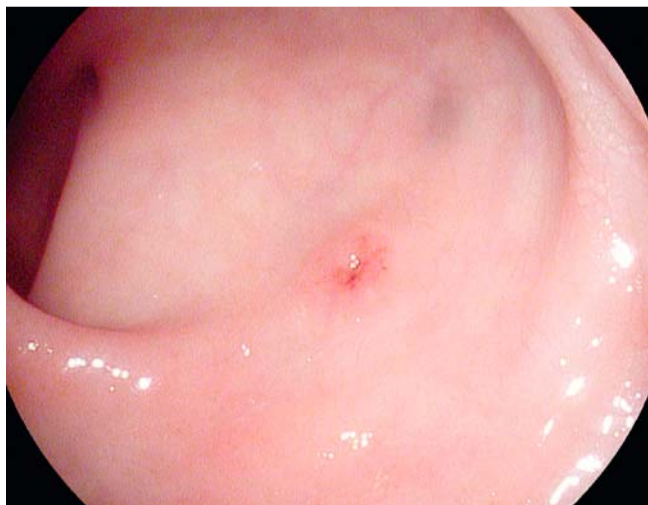
Physical examination did not reveal any significant alterations. Laboratory examination showed a normal hemoglobin level (13.5 g/dL), and platelet count and coagulation parameters were also normal. The patient underwent emergency colonoscopy after a cleansing enema, and a nipple-like protuberance (about 5 mm diameter) was discovered. The lesion was located in the rectum 5 cm away from the anal verge; it was concave at the top and was accompanied by hyperemia (► Fig. 1 and ► Fig. 2). Endoscopic ultrasound (EUS) did not find any occupancy lesions but a local vascular structure was present in the intestinal wall (► Fig. 3). The lesion was consistent with Dieula-



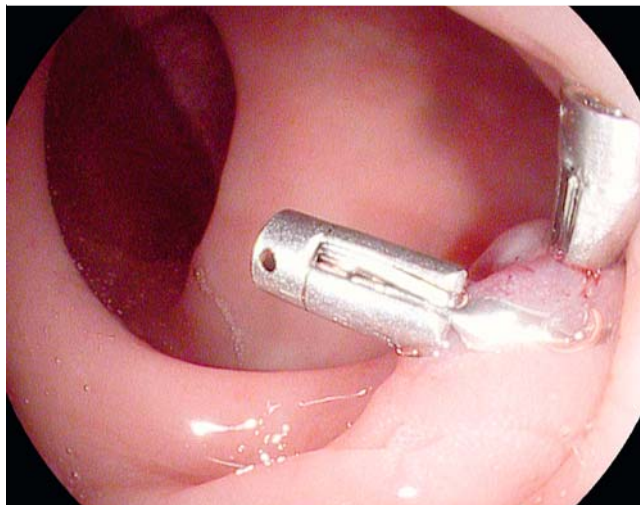
► **Fig. 1** Colonoscopic examination revealed a nipple-like protuberance (about 5 mm diameter), which was concave at the top and accompanied by hyperemia.



► **Fig. 3** Endoscopic ultrasound (EUS) showing the vascular structure passing through the intestinal wall from the subserosa to the mucosa, with a diameter of 1.5 mm. The Doppler signal was very clear, and the pulsed waveform indicated that it was an artery.



► **Fig. 2** Higher magnification view of Dieulafoy's lesion seen in Fig. 1.



► **Fig. 4** Two hemostatic clips were deployed, and the lesion showed no signs of bleeding.

foy's lesion (DL), and was treated with two hemostatic clips simultaneously (► **Fig. 4**). No further bleeding was recorded after the procedure, and the patient was discharged. A colonoscopy performed 1 month later did not demonstrate any abnormality but a residual hemostatic clip was present on the lesion. Furthermore, bloody stools have not recurred during a 6-month follow-up period.

Discussion

DL is an uncommon but well-recognized cause of gastrointestinal bleeding. This disease often occurs in males, and there is a wide range of age at time of occurrence, with reports of the lesion in infants as well as in a 93-year-old patient [5]. The majority of DLs are located in the proximal stomach within 6 cm of

the gastroesophageal junction; however, they can occur anywhere in the gastrointestinal tract, including the rectum [6]. Excessive alcohol intake and nonsteroidal anti-inflammatory drug use may increase the chances of bleeding from a gastric lesion by causing mucosal erosions [3]; however, some researchers report that there is no relationship between alcohol intake and DL [7]. In the colon, solid bowel contents may lead to ulceration with resultant exposure of an artery and hemorrhage [8], while in the rectum, anal receptive intercourse should be considered to be a direct cause as a result of the repeated mechanical stimulation which occurs in men during anal sexual intercourse. The sudden onset of extensive bleeding, which is usually intermittent and recurrent, is the same presentation in all ages. Since the bleeding is arterial, the amount of blood lost is usually massive. Depending upon the location of

bleeding and the amount, the manifestations can range from iron deficiency anemia to life-threatening hemorrhagic shock [9], which has been reported to occur in up to 87% of patients with DL [10].

The pathogenesis of DL is not yet clear. The normal gastroenteric vascular network narrows progressively as it reaches the mucosa, and forms a capillary network mostly in the submucosa. A DL is described as an arteriole, of which the diameter of the vascular network remains unchanged (1–3 mm) through the serosa and reaches the mucosa. The DL is generally 10–20 times thicker than a normal capillary, and is covered by a thin mucosal membrane without symptoms until the insidious onset of acute gastrointestinal bleeding begins [2, 3].

Patients with gastrointestinal bleeding as a result of DL usually have no history of chronic liver disease or gastrointestinal disease, while DL can actually be exacerbated by portal hypertension or liver transplantation [11]. Patients may or may not have taken non-steroidal anti-inflammatory drugs before. The typical location of DL is the proximal stomach, usually within 6 cm of the cardio-esophageal junction, and a variety of other sites including the esophagus, small bowel, and large bowel have been reported in the literature, including 2% in the colon, and 2% in the rectum. Hematochezia complicated by hypovolemic shock is the most important sign of a colorectal DL. Endoscopic examination is primarily preferred for diagnosis, and provides the following valuable diagnostic criteria: (1) micropulsatile bleeding from small (<3 mm) mucosal defects surrounded by normal mucosa; (2) the presence of protruding vessels; (3) fresh clots attached to a small mucosal defect or to normal mucosa [12]. The choice of gastroscopy, colonoscopy or enteroscopy mainly depends on the clinical manifestations and the doctor's experience. EUS may be valuable in identifying the unaltered vessel.

Endoscopic diagnosis can sometimes be delayed owing to the difficulty of localizing the bleeding site in situations with a small lesion, intermittent bleeding or poor visualization. Under these circumstances, emergent mesenteric angiography or CT angiography is an alternative. A typical angiographic image shows a caliber-persistent, convoluted artery in a position tangential to the lumen [13]. Multidetector row computed tomography, a noninvasive technique, could also help pinpoint potential bleeding therefore allowing the endoscopist to locate the lesion more accurately.

Hemostasis can be successfully achieved by endoscopic therapy in about 90% of patients with DL, and this has dramatically decreased the mortality rate [14]. Endoscopic treatments cover several major techniques including epinephrine and sclerotherapy injection, bipolar electro-coagulation (BICAP), and mechanical methods; however, in practice, neither the injection therapy nor BICAP are feasible because the hemostatic effect and rebleeding rate are unsatisfactory when compared to using mechanical methods. Thus, the mechanical methods currently used such as hemoclippping and band ligation are reliable and effective for the treatment of colonic DLs [15]. Repeated endoscopic treatment is strongly recommended when rebleeding occurs.

Arterial embolization is an alternative therapy in patients resistant to endoscopic treatment and patients who cannot endure surgery. Increasing evidence has suggested that EUS-guided treatment with vascular therapy and hemoclippping offers a less invasive and more practical option than surgery, on account of the precise delivery of thrombotic agent into the target vessel or endoscopic hemoclippping of DL [16, 17].

Emergent resection surgery, which plays a role in traditional therapy for the treatment of colorectal DL, is indicated on the occasions when patients are suffering from hemorrhagic shock, and bleeding cannot be successfully controlled by endoscopic or angiographic methods. It consists of resection of the bleeding bowel segment or subtotal colectomy if bleeding cannot be accurately localized. Laparoscopic resection with the assistance of endoscopy has been successfully applied in some patients.

In conclusion, in our case, Dieulafoy's lesion was diagnosed with the help of both colonoscopy and ultrasonography before successful treatment with hemostatic clips. A history of anal receptive intercourse may play a role in mechanical damage. Ultrasonography and fine flow Doppler should be used in the diagnosis of this disease and endoscopic hemostatic clips can be effective in controlling bleeding from a rectal Dieulafoy's lesion.

Competing interests

None

References

- [1] Jeon HK, Kim GH. Endoscopic management of Dieulafoy's lesion. *Clin Endosc* 2015; 48: 112–120
- [2] Shin HJ, Ju JS, Kim KD et al. Risk factors for Dieulafoy lesions in the upper gastrointestinal tract. *Clin Endosc* 2015; 48: 228
- [3] Baxter M, Aly EH. Dieulafoy's lesion: current trends in diagnosis and management. *Ann R Coll Surg Engl* 2010; 92: 548–554
- [4] Dogan U, Gomceli I, Koc U et al. Rectal dieulafoy lesions: a rare etiology of chronic lower gastrointestinal bleeding. *Case Rep Med* 2014: 180230
- [5] Chaer RA, Helton WS. Dieulafoy's disease. *J Am Coll Surg* 2003; 196: 290–296
- [6] Veldhuyzen van Zanten SJ, Bartelsman JF, Schipper ME et al. Recurrent massive haematemesis from Dieulafoy vascular malformations: a review of 101 cases. *Gut* 1986; 27: 213–222
- [7] Holleran G, Hussey M, Mcnamara D. Small bowel Dieulafoy lesions: An uncommon cause of obscure bleeding in cirrhosis. *World J Gastrointest Endosc* 2016; 8: 568
- [8] Barbier P, Luder P, Triller J et al. Colonic hemorrhage from a solitary minute ulcer: report of three cases. *Gastroenterology* 1985; 88: 1065–1068
- [9] Lara LF, Sreenarasimhaiah J, Tang SJ et al. Dieulafoy lesions of the GI tract: localization and therapeutic outcomes. *Dig Dis Sci* 2010; 55: 3436–3441
- [10] Nguyen DC, Jackson CS. The Dieulafoy's lesion: An update on evaluation, diagnosis, and management. *J Clin Gastroenterol* 2015; 49: 541–549

- [11] Apiratpracha W, Ho JK, Powell JJ et al. Acute lower gastrointestinal bleeding from a dieulafoy lesion proximal to the anorectal junction post-orthotopic liver transplant. *World J Gastroenterol* 2006; 12: 7547–7548
- [12] Al-Mishlab T, Amin AM, Ellul JP. Dieulafoy's lesion: an obscure cause of GI bleeding. *J R Coll Surg Edinb* 1999; 44: 222–225
- [13] Nunoo-Mensah JW, Alkari B, Murphy GJ et al. Rectal Dieulafoy lesions. *J Am Coll Surg* 2008; 206: 388–389
- [14] Lee YT, Walmsley RS, Leong RW et al. Dieulafoy's lesion. *Gastrointest Endosc* 2003; 58: 236–243
- [15] Chung I-K, Kim E-J, Lee M-S et al. Bleeding Dieulafoy's lesions and the choice of endoscopic method: comparing the hemostatic efficacy of mechanical and injection methods. *Gastrointest Endosc* 2000; 52: 721–724
- [16] Vila JJ, Perez-Miranda M, Basterra M et al. Endoscopic ultrasound-guided therapy of a rectal Dieulafoy lesion. *Endoscopy* 2014; 46: (Suppl. 01): E84–E85
- [17] Alshumrani G, Almuaikel M. Angiographic findings and endovascular embolization in Dieulafoy disease: a case report and literature review. *Diagn Interv Radiol* 2006; 12: 151–154