

Avoiding pitfalls of intraoperative peripheral endovascular surgery with the aid of OsiriX: expanding the use of virtual fluoroscopy

Como evitar armadilhas do intraoperatório em cirurgia endovascular periférica com o auxílio do OsiriX: ampliando o uso da fluoroscopia virtual

Giovani José Dal Poggetto Molinari¹, MD, Andréia Marques de Oliveira Dalbem¹, MD, Ana Terezinha Guillaumon¹, MD, MsC, PhD

DOI: 10.5935/1678-9741.20140094

RBCCV 44205-1575

Abstract

We have shown how the analysis of the angiotomography reconstruction through OsiriX program has assisted in endovascular perioperative programming. We presented its application in situations when an unexpected existence of metallic overlapping artifact (orthopedic osteosynthesis) compromised the adequate visualization of the arterial lesion during the procedure. Through manipulation upon OsiriX software, with assistance of preview under virtual fluoroscopy, it was possible to obtain the angles that would avoid this juxtaposition. These angles were reproduced in the C-arm, allowing visualization of the occluded segment, reducing the need for repeated image acquisitions and contrast overload, allowing the continuation of the procedure.

Descriptors: Fluoroscopy. User-Computer Interface. Multidetector Computed Tomography. Endovascular Procedures.

Resumo

Temos demonstrado como a análise da reconstrução da angiogramografia utilizando o programa OsiriX tem auxiliado na programação perioperatória endovascular. Apresentamos aqui sua aplicação em situação em que a existência de artefato metálico (osteossíntese ortopédica) comprometia a adequada visualização de lesão arterial durante o procedimento. Pela manipulação da angiogramografia no software OsiriX e com o auxílio das imagens sob fluoroscopia virtual foi possível obter-se automaticamente uma angulação que evitasse esta justaposição. Os ângulos foram reproduzidos no arcoscópio, o que permitiu expor o segmento ocluído, reduzindo a sobrecarga de contraste e de repetidas tomadas, permitindo a continuação do procedimento.

Descritores: Fluoroscopia. Interface Usuário-Computador. Tomografia Computadorizada Multidetecores. Procedimentos Endovasculares.

INTRODUCTION

Prior to computed tomography (CT) scans with multi-channel detector technology (implemented only from 1998 - when the first 4-channel equipment became available), the assessment of peripheral arterial disease by CT scan could only be performed only in a small segment of vascular system^[1,2].

The introduction of multi-slice CT scans (from 16 channels), allowed the acquisition of larger anatomic volumes^[2], making it an accurate method for the study of peripheral arteries^[1]. Although digital subtraction angiography is considered the gold standard for peripheral arterial assessment, this has been replaced by CT due to the increasing number of detectors and collimators increasingly thin^[3]. When compared to

¹Universidade Estadual de Campinas, Campinas, SP, Brazil.

This work was carried out in Hospital de Clínicas da Universidade Estadual de Campinas (Unicamp) Centro de Referência em Alta Complexidade em Cirurgia Endovascular, Campinas, SP, Brazil.

Correspondence adress:

Giovani José Dal Poggetto Molinari
Universidade Estadual de Campinas - Unicamp/Cidade Universitária Zeferino Vaz - Rua Vital Brasil, 251 - Barão Geraldo - Campinas, SP, Brazil
Zip Code: 13083-888 Mail box: 6142
E-mail: drgiovani.molinari@uol.com.br

Abbreviations, acronyms & symbols

CT Computed Tomography

the first, CT angiography is less invasive, less expensive and exposes patients to lower doses of radiation^[4].

However, the study of CT angiography generates a massive number of digital data and unwieldy, which interpretation and discrimination of changes are best evaluated when post processed in software, such as multi-planar reconstruction, volume rendering and maximum intensity projection^[4].

We have shown how the analysis of tomographic reconstruction of fine sections through the OsiriX program has aided in perioperative programming of endovascular abdominal aneurysms, in prediction of the intra-luminal placement of angiographic catheters and in correction of angular positioning of the fluoroscopy unit^[5,6].

We also reported how concepts of angulation and Virtual Fluoroscopy used on OsiriX (from multichannel CT angiography) are used to obtain the best intraoperative angle of visual exposure of peripheral artery, in situations where the existence of artifacts (like metallic orthopedic fixation) compromises its proper visualization during endovascular procedures.

CASE REPORT

Female patient, 24 years old, assisted at the Outpatient Clinic for High Complexity Endovascular Surgery at University of Campinas, with history of motorcycle trauma (fall) for 6 months, causing injury with fracture of clavicle, 3rd and 4th left ribs. She underwent on occasion to an orthopedic surgery

(with placement of implantable system for osteosynthesis - fixation with plate and pins) with no major complications. For 3 months, she developed pain, paresthesia, coldness of the limb and progressive strength loss, with recent recrudescence. Physical examination presented a preserved sensibility, decreased motor function and slowed perfusion. The values of segmentar pressures registered in the left arm through a continuous wave doppler assessment were reduced, with a brachy-brachial index of 0,55 (N.V.: 0,9-1,1), reinforcing the hypothesis of an arterial involvement of this territory.

She underwent CT angiography exam of the supra-aortic trunks and left upper limb. It was identified an image of interrupted contrast, suggestive of occlusion of left subclavian artery (near the metallic prosthesis) with refilling in its distal part. The axial sections had impairment of appropriate visualization of the artery due to streak artifacts produced by the osteosynthesis, reason why it was opted for the intraoperative arteriography, for purposes of establishing an exclusive endovascular treatment (recanalization and covered stent implantation).

During surgical procedure, there was difficulty in the correct visualization of the lesion (ie., unfilled portion of the artery by intravascular contrast) due to the overlapping of radiopaque metallic rod included in the angiographic image (Figure 1A). After some attempts to capture new images posterior to the angular repositioning of the fluoroscopy unit, it was decided to resort to auxiliary study of CT in OsiriX software. At first, the manipulation of the axial images was performed, marking the proximal and distal portions of the subclavian artery with the *point* tool (Figure 1B). A three-dimensional volume reconstruction under virtual fluoroscopy was obtained, where it was able to identify an overlap of this demarcation by the orthopedic prosthesis (Figure 1C).

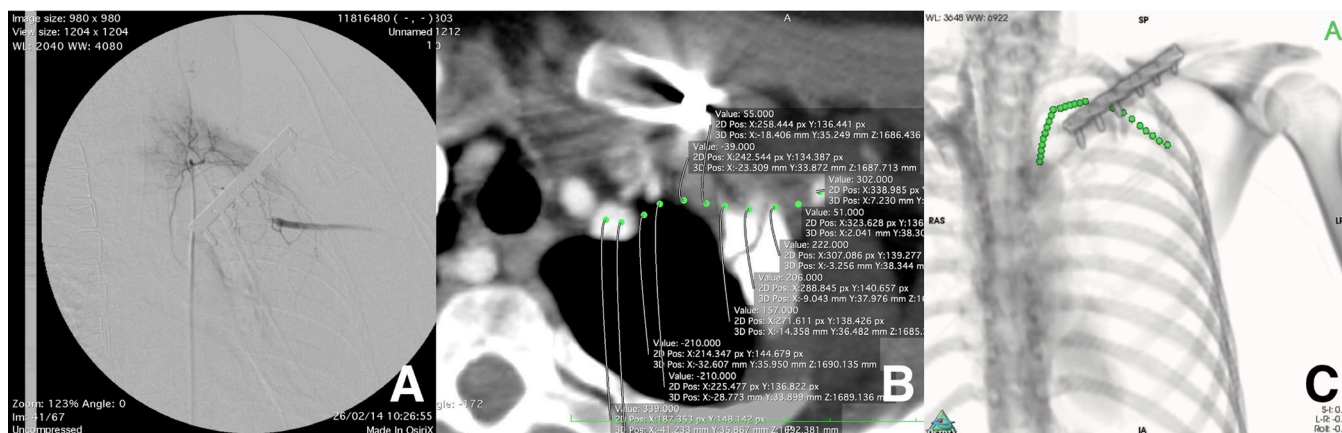


Fig. 1 - A) Intraoperative image of digital subtraction angiography, which displays an overlapping caused by the orthopedic metallic rod over the arterial thrombosed segment. B) Study of the tomographic axial view, where marks with the OsiriX's point tool were performed, over the estimated trajectory of the left subclavian artery. C) Three-dimensional-by-volume reconstruction under virtual fluoroscopy, after marking with points. It was possible to identify, in fact, the overlapping of the structures and the need of the C-arm angular repositioning intraoperatively.

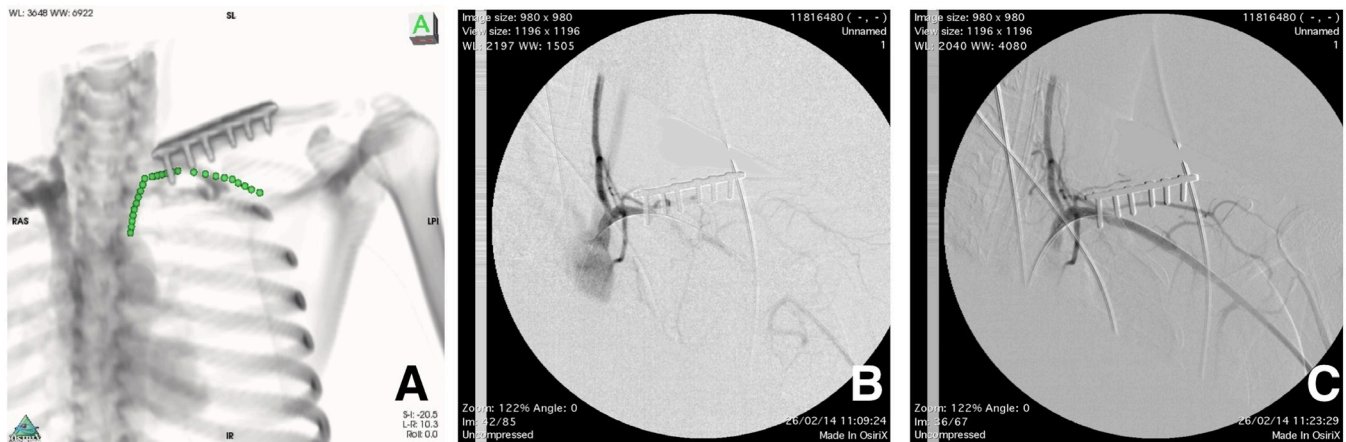


Fig. 2 - A) Three-dimensional-by-volume image rotation avoiding the overlap of the osteosynthesis upon the tomographic point marks. The angles used for C-arm repositioning were automatically yielded by the software (right inferior corner). B) Digital subtraction angiography after the angular correction of the radioscopic device, with minimum effect of image superposition, allowing the preview of the thrombosed arterial segment. C) Final outcome after arterial recanalization and the covered-stent implant.

By rotational manipulation of three-dimensional image, it was possible to obtain an angle that would avoid this juxtaposition (Figure 2A). The angles were reproduced in the C-arm, allowing visualization of the exposed occluded segment, allowing the rest of the procedure to follow (Figure 2B). Therefore, we proceeded to the artery recanalization with coated stent (Gore Viabahn 7x50) which was performed without any complications (Figure 2C).

RESULTS AND DISCUSSION

Until recently, digital subtraction arteriography was the modality of choice for evaluating patients with suspected vascular injury. However, due to the wide access of multi-channel exams, it has rapidly replaced the conventional angiography in the diagnosis of vascular trauma^[7].

In a meta-analysis by Jens et al.^[8] sensitivity and specificity for vascular injury (when compared to subtraction arteriography or surgery) was 99.2% and 96.2% respectively. This justifies why all service centers should have a trauma tomography as an accurate method for diagnosis of vascular injury in extremity trauma, by reserving the conventional angiography for interventional or when the first is inconclusive.

Vascular abnormalities in the upper limbs are found less frequently than those affecting the lower extremities. Arterial imaging studies of the upper limbs is usually performed in trauma victims with ischemic symptoms of upper extremities, prep planning of complex vascular reconstructions and dialysis access as well as follow up of endovascular or surgical procedures^[9].

Despite the many advantages, CT angiography also has its limitations. It can be ineffective in the diagnosis if the contrast reaches the studied segment too soon or too late at the period of image acquisition by the device. Another scenario in the diagnosis of arterial lesions after trauma is the presence of artifacts caused by metallic fragments on the periphery of the vessel, such as projectiles from firearms. These streaks make it impossible to analyze the correct image^[7].

Anyway, it is important to remember that in any tomographic analysis is necessary to review the images of axial views to confirm the findings presented in reconstructions and define the possible presence of these or other artifacts that simulate disease^[9].

In our case the analysis of the image in axial views showed these streaks artifacts, compromising the injury extension evaluation, even after adjusted values of windowing (brightness and contrast). Therefore it was decided to supplement with subtraction arteriography intraoperatively. Thus, it would be possible to estimate, based on the gap of intravascular contrast fill of the left subclavian artery, the extent of the lesion, the size and required length of the stent(covered stent graft).

However when facing the radiopaque image produced by the orthopedic fixation of the clavicle, it prevented the perfect view of the angiographic image due to its overlapping and radiopacity. To continue with the procedure without visualization of the arterial segment with intravascular contrast refill would increase risk of false paths, extensive dissections and the failure of the intervention.

We used the angiotomography previously performed in attempt to simulate the optimum viewing angle of the occluded segment to be reanalyzed. The OsiriX point tool marks permanently a voxel from a three-dimensional image - which is defined as the representation of a pixel (the smallest point of a digital image) in a volumetric grid originated from a series of pictures - and is reproduced in a three-dimensional-by-volume reconstruction. Doing so, it's possible to obtain any information of spatial positioning of this mark, such as the path of the occluded subclavian artery in this case. Thus, when marking with points the trajectory of the artery, it was possible to visualize it in any sort of reconstruction, axial, three-dimensional-by-volume or multiplanar. Through rotational manipulation of the three-dimensional-by-volume image, we could illustrate the studied artery avoiding overlapping the osteosynthesis plaque. The angles obtained automatically from the software were reproduced in the fluoroscopy unit, allowing the correct visualization of the angiographic image. Thereafter, it was possible to reduce the need for repeated angiographic takes in attempt to obtain the best exposure of the artery, avoiding iodinated contrast overload. Therefore we proceeded to the recanalization of the thrombosed segment with placement of a covered stent with therapeutic success (which can be observed by control angiography). The patient's clinical improvement was evident, verified with the complete resolution of the symptoms.

The use of OsiriX as a complementary tool allows doctors to assist in the preparation of surgeries (as endovascular) extending it beyond the field of diagnostic radiology. These tasks can be easily incorporated into the armamentarium of the surgeon to avoid pitfalls and unforeseen situations that are identified intraoperatively, increasing the operator risk and oftentimes leading to intervention failure.

Authors' roles & responsibilities	
GJDPM	Analysis and/or interpretation of data; statistical analysis; final manuscript approval; conception and design of the study; conduct of operations and/or experiments; manuscript drafting or critical review of its content
AMO	Analysis and/or interpretation of data; conduct of procedures and/or experiments
ATG	Analysis and/or interpretation of data; manuscript drafting and review of its content

REFERENCES

1. Brockmann C, Jochum S, Sadick M, Huck K, Ziegler P, Fink C, et al. Dual-energy CT angiography in peripheral arterial occlusive disease. *Cardiovasc Intervent Radiol.* 2009;32(4):630-7.
2. Hiatt MD, Fleischmann D, Hellinger JC, Rubin GD. Angiographic imaging of the lower extremities with multidetector CT. *Radiol Clin North Am.* 2005;43(6):1119-27.
3. Kock MC, Dijkshoorn ML, Pattynama PM, Myriam Hunink MG. Multi-detector row computed tomography angiography of peripheral arterial disease. *Eur Radiol.* 2007;17(12):3208-22.
4. Walls MC, Thavendiranathan P, Rajagopalan S. Advances in CT angiography for peripheral arterial disease. *Cardiol Clin.* 2011;29(3):331-40.
5. Molinari GJDP, Dalbem AMO, Menezes FH, Guillaumon AT. Proposal of renal artery's ostial projection under virtual geometric correction in infrarenal aneurysms: initial results of a pilot study. *Rev Bras Cir Cardiovasc.* 2014;29(1):78-82.
6. Molinari GJDP, Dalbem AMO, Guillaumon AT. The use of virtual resources for pre operative study in correction of infrarenal aneurysms: exploring the OsiriX's potential. *Rev Bras Cir Cardiovasc.* 2014;29(2):279-84.
7. Jens S, Kerstens MK, Legemate DA, Reekers JA, Bipat S, Koelemay MJ. Diagnostic performance of computed tomography angiography in peripheral arterial injury due to trauma: a systematic review and meta-analysis. *Eur J Vasc Endovasc Surg.* 2013;46(3):329-37.
8. Kock MC, Dijkshoorn ML, Pattynama PM, Myriam Hunink MG. Multi-detector row computed tomography angiography of peripheral arterial disease. *Eur Radiol.* 2007;17(12):3208-22.
9. Waliszewska M, Jakubiak A, Guzinski M, Sasiadek M. Application of the 64-slice computed tomography as a diagnostic method in acute posttraumatic ischaemia of the upper limbs - 3 case reports. *Pol J Radiol.* 2010;75(2):94-7.
10. Walls MC, Thavendiranathan P, Rajagopalan S. Advances in CT angiography for peripheral arterial disease. *Cardiol Clin.* 2011;29(3):331-40.