

Transplantation of CCR5Δ32 Homozygous Umbilical Cord Blood in a Child With Acute Lymphoblastic Leukemia and Perinatally Acquired HIV Infection

Meghan Rothenberger,¹ John E. Wagner,² Ashley Haase,³ Douglas Richman,^{4,5} Bartosz Grzywacz,⁶ Matthew Strain,⁴ Steven Lada,⁵ Jacob Estes,⁷ Courtney V. Fletcher,⁸ Anthony T. Podany,⁸ Jodi Anderson,¹ Thomas Schmidt,¹ Steve Wietgreffe,³ Timothy Schacker,^{1,b} and Michael R. Verneris^{2,a,b}

¹Department of Medicine, ²Department of Pediatrics, ³Department of Microbiology and Immunology, and ⁴Department of Pathology and Lab Medicine, University of Minnesota, Minneapolis, Minnesota; ⁵Center for AIDS Research, University of California San Diego, La Jolla, California; ⁶Veteran's Affairs (VA) San Diego Healthcare System, San Diego, California; ⁷AIDS and Cancer Virus Program and Laboratory Animal Science Program, Leidos Biomedical Research, Inc., Frederick National Laboratory for Cancer Research, Frederick, Maryland; ⁸College of Pharmacy, University of Nebraska Medical Center, Omaha, Nebraska

Background. Allogeneic hematopoietic cell transplantation (allo-HCT) in a CCR5Δ32 homozygous donor resulted in HIV cure. Understanding how allo-HCT impacts the HIV reservoir will inform cure strategies.

Methods. A 12-year-old with perinatally acquired, CCR5-tropic HIV and acute lymphoblastic leukemia underwent myeloablative conditioning and umbilical cord blood (UCB) transplantation from a CCR5Δ32 homozygous donor. Peripheral blood mononuclear cells (PBMCs) and the rectum were sampled pre- and post-transplant. The brain, lung, lymph node (LN), stomach, duodenum, ileum, and colon were sampled 73 days after transplantation (day +73), when the patient died from graft-vs-host disease. Droplet digital polymerase chain reaction (ddPCR) and in situ hybridization (ISH) were used to detect the HIV reservoir in tissues. CCR5 and CD3 expression in the LN was assessed using immunohistochemistry (IHC).

Results. HIV DNA (vDNA) was detected in PBMCs by ddPCR pretransplant but not post-transplant. vDNA was detected by ISH in the rectum at days -8 and +22, and in the LN, colon, lung, and brain day +73. vDNA was also detected in the lung by ddPCR. IHC revealed CCR5+CD3+ cells in the LN postmortem.

Conclusions. HIV was detected in multiple tissues 73 days after CCR5Δ32 homozygous UCB allo-HCT despite myeloablative conditioning and complete donor marrow engraftment. These results highlight the importance of analyzing tissue during HIV cure interventions and inform the choice of assay used to detect HIV in tissue reservoirs.

Keywords. allogeneic bone marrow transplantation; CCR5Δ32; HIV cure; HIV reservoirs.

Despite great advances in HIV treatment, cure remains elusive. The Berlin Patient, who underwent myeloablative, allogeneic hematopoietic cell transplantation (allo-HCT) from an HLA-matched, CCR5Δ32 homozygous donor, is the only individual in whom a cure has been achieved [1, 2]. Mechanistically, it is postulated that “cure” was achieved through a combination of myeloablative conditioning and eradication of HIV-infected host cells by graft-vs-host (GVH) immune responses and establishment of donor cells resistant to infection by the patient's R5 virus. Subsequent allo-HCT

transplants in HIV-infected patients using wild-type CCR5 donor cells have not resulted in lasting HIV remission [3].

We describe a case of a child with congenitally acquired HIV who developed acute lymphoblastic leukemia (ALL) with characteristics that were unlikely to be cured with traditional chemotherapy and whose odds for survival were best with an allo-HCT. We chose to use banked 3/6 HLA-matched umbilical cord blood (UCB) because of the lack of a matched sibling donor and because we previously demonstrated that 3/6 matched UCB has equivalent outcomes in children with leukemia, relative to better-matched UCB units [4]. Given the patient's HIV status and CCR5-tropic virus, we searched for a suitably HLA-matched CCR5Δ32 homozygous donor in the unrelated donor registries [5].

Published reports on CCR5Δ32 homozygous UCB allo-HCT include a 53-year-old male with HIV and myelodysplastic syndrome who died of recurrent disease 2 months after allo-HCT and a 37-year-old male with HIV and aggressive lymphoma who died 3 months after transplant from progressive disease [6, 7]. Although no virologic studies have been reported from the first patient, HIV DNA was cleared from the peripheral blood (PB) of the second patient. However, virologic studies were not performed in secondary lymphatic tissues (LTs), which harbor the

Received 18 December 2017; editorial decision 11 April 2018; accepted 9 May 2018.

^aPresent affiliation: Pediatrics-Heme/Onc and Bone Marrow Transplantation, University of Colorado, Aurora, Colorado

^bCo-senior authors

Correspondence: M. Rothenberger, MD, Department of Medicine, University of Minnesota, Medicine Education Office, MMC 284 Mayo, 8284A, 420 Delaware St SE, Minneapolis, MN 55455 (roth0134@umn.edu).

Open Forum Infectious Diseases®

© The Author(s) 2018. Published by Oxford University Press on behalf of Infectious Diseases Society of America. This is an Open Access article distributed under the terms of the Creative Commons Attribution-NonCommercial-NoDerivs licence (<http://creativecommons.org/licenses/by-nc-nd/4.0/>), which permits non-commercial reproduction and distribution of the work, in any medium, provided the original work is not altered or transformed in any way, and that the work is properly cited. For commercial re-use, please contact journals.permissions@oup.com
DOI: 10.1093/ofid/ofy090

majority of latently infected cells [8–12]. As demonstrated by the Boston Patients, both of whom developed virologic rebound after allo-HCT despite clearing HIV DNA from PB and losing detectable cellular immune responses to HIV, PB analyses cannot reliably predict cure after allo-HCT [3].

Herein, we report our experience using myeloablative conditioning followed by transplantation of a CCR5Δ32 homozygous UCB unit in a child with perinatally acquired HIV and ALL and show the impact of this procedure on the HIV reservoir in multiple tissues using both polymerase chain reaction (PCR) and in situ hybridization (ISH) 73 days after transplantation, when the patient died from complications of graft-vs-host disease (GVHD). Our results describe the timing of viral clearance after transplantation, the management of HIV-infected patients undergoing allo-HCT, and the utility of different methods of detecting HIV when evaluating cure strategies.

CASE REPORT

The patient was diagnosed with perinatally acquired HIV at age 1 and was started on antiretroviral therapy (ART). However, given difficulties tolerating multiple oral regimens and issues with clinic follow-up, the patient had detectable viremia and marked immune suppression with absolute CD4 T cell counts consistently <100 cells/mm³ throughout childhood, with several opportunistic infections including presumed *Pneumocystis jirovecii* pneumonia at age 7 years. In September 2012, at the age of 11 years, the patient underwent evaluation of pancytopenia and was found to have hypodiploid ALL. After induction using protocol COG AALL1131, the patient had persistent minimal residual disease (MRD; 0.3% using COG reference flow cytometry laboratory). Given the high-risk features of the leukemia and poor response to induction therapy, the patient was referred for consideration of allo-HCT. Because the patient's HIV was CCR5-tropic, a search for a CCR5Δ32 homozygous UCB unit commenced.

Before transfer to the University of Minnesota (UMN) Bone Marrow Transplant Center, the patient had been treated with raltegravir and tenofovir/emtricitabine but had a difficult time tolerating oral medications due to gastrointestinal (GI) issues. He developed a detectable HIV viral load (VL) and a new M184V mutation. His antiretrovirals (ARVs) were therefore changed to raltegravir, tenofovir, and abacavir several weeks before transfer to UMN. Immediately after transfer, his HIV VL was 63 800 copies/mL and absolute CD4 count was 1 cell/mm³. A gastrostomy tube was placed, tenofovir and raltegravir were continued, abacavir was stopped, and ritonavir-boosted darunavir was started in an attempt to rapidly suppress the VL before allo-HCT. Four weeks later, his VL had improved to 74 copies/mL. Transplant conditioning was initiated and consisted of cyclophosphamide (50 mg/kg × 2), fludarabine (25 mg/m² × 3), and total body irradiation (1320 cGy); GVHD prophylaxis was with cyclosporine A (CSA) and mycophenolic acid mofetil (MMF). Inhaled pentamidine, micafungin, and azithromycin were used for infectious disease

prophylaxis. During conditioning with cyclophosphamide, tenofovir and raltegravir were continued, but ritonavir and darunavir were held, and abacavir was substituted given drug/drug interactions. Abacavir was stopped and boosted darunavir was restarted after cyclophosphamide was completed. At day 0, the patient underwent UCB transplant from an HLA 3/6 matched donor. The patient's HIV PB VL was suppressed (<48 copies/mL) at the time of transplant. All ARVs were held for 3 days after transplant given concern that they might interfere with engraftment, but they were then restarted. ARV drug levels were checked weekly, and several dose adjustments were required, although HIV VL remained suppressed. The patient demonstrated neutrophil recovery in the peripheral blood on day 14, and whole-blood chimerism studies demonstrated 100% donor engraftment based on short tandem repeat analysis; the margin of error of this clinical assay is ±5%. On day 21, the bone marrow also demonstrated 100% donor engraftment and 10% cellularity, tri-lineage hematopoiesis, and no evidence of leukemia. Chimerism studies on purified CD3 and CD15 isolated from the peripheral blood on days 35 and 59 also revealed 100% donor engraftment. Thirty-six days after transplant, the patient was transitioned from intravenous to oral CSA. Concurrent with this, there was a drop in the systemic CSA levels, and the patient developed grade IV lower gastrointestinal GVHD at day 38 that was refractory to corticosteroid treatment. He was subsequently treated with antithymocyte globulin, MMF, budesonide, and infliximab. Given drug/drug interactions and concern for toxicity, all ARVs were stopped at day 62. Despite aggressive supportive care, the patient developed multi-organ failure and died 73 days after allo-HCT. The patient's clinical course is outlined in [Figure 1](#).

METHODS

Clinical and Study Laboratory Procedures

Informed consent from the patient's guardian was obtained in accordance with the Declaration of Helsinki. The work was approved by the Institutional Review Board of the University of Minnesota, and the clinical treatment protocol was registered with the US Food and Drug Administration (as an amendment to IND 14797) before study initiation. HIV tropism was determined using the Monogram Biosciences phenotypic viral RNA assay. HIV VL was measured twice weekly using the Roche COBAS Ampliprep/COBAS Taqman HIV-1 Test, version 2.0.

Plasma Antiretroviral Drug Levels

Trough plasma concentrations of ARVs were measured weekly from the time of transplant in the Antiviral Pharmacology Laboratory at the University of Nebraska Medical Center using quality-controlled, liquid chromatography/tandem mass spectrometry methods, as previously described [13–15].

Tissue Collection and Processing

Relative to the day of transplant (day 0), PBMCs were obtained at days –61, –20, and –8 and +35 and +49. Rectal biopsies

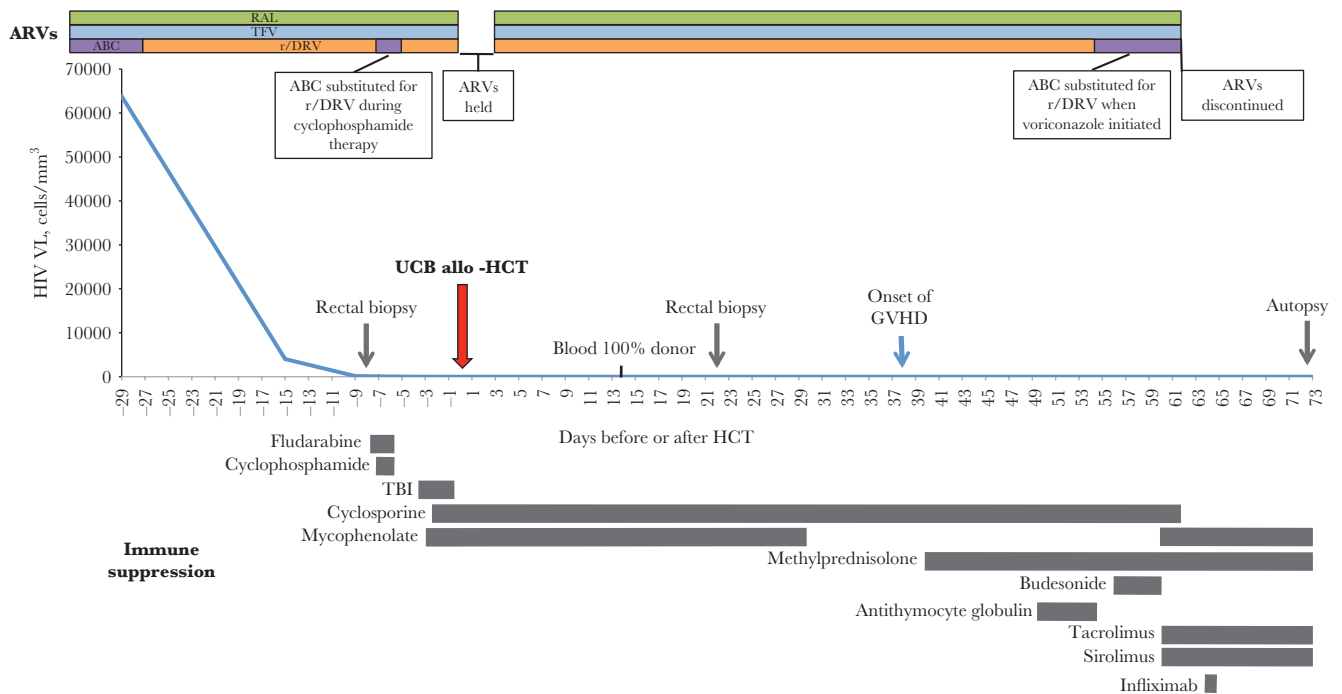


Figure 1. The patient's clinical course, including HIV viral load (VL), timing of myeloablative allogeneic umbilical cord blood hematopoietic cell transplant (UCB-allo-HCT), immune suppressant therapy, and tissue sampling time points, is shown from time of transfer to our institution to time of death 73 days after transplantation. Abbreviations: ABC, abacavir; ARVs, antiretrovirals; GVHD, graft-vs-host disease; RAL, raltegravir; r/DRV, ritonavir-boosted darunavir; TBI, total body irradiation; TDF, tenofovir.

were obtained via flexible sigmoidoscopy at days -8 and +22. Samples of the brain, lung, lymph node (LN), stomach, duodenum, ileum, and colon were obtained at autopsy. PBMCs and tissues were processed as previously described [12].

Radiolabeled RNA In Situ Hybridization

Radiolabeled RNA ISH (rISH) was performed on tissues as previously described [12]. Five-micrometer-thick sections from the paraffin-embedded tissue were cut through the entire tissue block. Twenty sections from each block were analyzed using every fourth section to measure vRNA+ cells in 20- μ m intervals. Photographic images using epifluorescence were taken with a digital camera, and the tif images were analyzed for the area of the sections and the area occupied by silver grains using Photoshop with Fovea Pro. Section weights were estimated from their 5- μ m thickness and area and density of fixed tissues. Image analyses were repeated by a blinded expert at an outside institution.

Next-Generation DNA In Situ Hybridization (DNAScope)

After processing as above, next-generation DNA in situ hybridization (DNAScope) was used to detect vDNA as previously described [16]. Image analyses were also repeated by a blinded expert at an outside institution.

Droplet Digital PCR

Droplet digital PCR (ddPCR) was performed at the University of California San Diego as previously described [17, 18]. Two primers, skGag and joPol, were used as described [19, 20].

Immunohistochemistry

Staining was completed using the Opal 4-color Fluorescent IHC Kit (PerkinElmer). Briefly, slides were dewaxed and hydrated. Antigen retrieval was performed with AR6 buffer in the microwave. After washing, slides were blocked with the PerkinElmer antibody diluent/block for 10 minutes. Slides were drained, and CD3 (clone SP7, Thermo Scientific) was added for 1 hour at room temperature. Following TBST buffer rinses, the Polymer HRP Ms+Rb was added for 10 minutes and washed again. The Opal 520 working solution was added to the slides for 10 minutes. Slides were rinsed. To strip the antibody off, the slides were microwaved again in the AR6 buffer. The staining process was repeated, this time using the CCR5 antibody (Lifespan Biosciences, Inc.) as the primary antibody and the Opal 570 for the fluorophore. Slides were washed, counterstained with DAPI, and mounted in Aqua-Poly/Mount (Polysciences, Inc.).

Role of Funding Sources

The funders of this study had no role in the design of the study, the data collection, analysis, or interpretation, the writing of the report, or the decision to submit for publication.

RESULTS

Viral load results and ART regimens used throughout the transplant course are detailed in Figure 1. At time of transplant, the trough plasma raltegravir concentration was low at 67.2 ng/mL, so the dose was increased to three 100-mg chewable tablets twice daily. The goal trough (approximately 100 ng/mL) was reached

the following week and remained stable (median, 89 ng/mL; interquartile range, 85–155 ng/mL) until discontinued. Tenofovir levels were below the limit of detection (10 ng/mL) at the time of transplant; this was felt to be due to adherence and the difficulties of use of oral tenofovir powder. Shortly after transplant, the appropriate strength (250 mg) of tenofovir tablets was obtained, and tenofovir was given as a crushed tablet via a G tube. Levels increased but did not reach the target range until day +42. Darunavir levels (median, 772 ng/mL) were in the target range from time of transplant and remained there until the onset of GI GVHD on day +38, when levels decreased; darunavir remained below target level until it was discontinued on day 57. HIV VL remained suppressed from the time of transplant until death.

HIV DNA was detectable in PBMCs using ddPCR targeting Pol and Gag genes at all time points before transplant (days –61, –20, and –8), with a frequency ranging from 140 to nearly 500 copies of HIV DNA per 10^6 cells; HIV DNA was also detected at a lower frequency in rectal tissues at day –8 (Table 1). At the time these pretransplant samples were obtained, HIV RNA was detectable in the PB as the patient did not develop a suppressed HIV VL until 5 days before transplant. Following allo-HCT, HIV DNA was not detected by ddPCR in PBMCs at +35 and +49 days, nor was it present in rectal tissues obtained at day +22. Similarly, ddPCR targeting Pol and Gag genes was negative in the brain, LN, stomach, duodenum, ileum, and colon tissues collected at autopsy on day +73. However, ddPCR using a skGag probe was positive in lung tissue at the time of autopsy, with a frequency of 22 copies/ 10^6 cells (Table 1).

No HIV RNA (vRNA) was detected by rISH in rectal tissues obtained at days –8 and +22, or in the brain, lung, LN, stomach, duodenum, ileum, and colon at autopsy. However, 2.58×10^5 copies of vDNA/gram of tissue were detected in rectal samples obtained at day –8 and 2.60×10^4 copies/gram at day +22 using DNAscope. At autopsy, 1.06×10^5 copies of vDNA/gram were detected in the LN, 1.57×10^4 copies/gram in the lung, 4.16×10^3 copies/gram in the colon, and 7.35×10^2 copies/gram in the brain (Table 1 and Figure 2). No vDNA was noted in the duodenum, ileum, or stomach.

Analysis of postmortem LN using IHC demonstrated loss of normal lymph node architecture with large areas of necrosis and depleted CD3-positive T cells. Some of the cells stained with CCR5 were consistent with persistence of rare cells of recipient origin, most of which represented CD68-positive macrophages; however, rare CD3-positive cells co-staining with CCR5 were also seen (Figure 3).

DISCUSSION

Eradication of the reservoir of vDNA+ cells had not occurred 73 days after allo-HCT, despite myeloablative conditioning, grade IV acute GVHD, and the use of CCR5Δ32 homozygous donor cells. This not only informs the clinical management of HIV-infected patients undergoing allo-HCT, but more importantly, highlights the challenges of clearing HIV from tissue reservoirs and provides insight into the utility of ddPCR and ISH in detecting the HIV reservoirs in tissues.

Although the kinetics of donor engraftment in the PB and BM are well characterized after allo-HCT, little is known about

Table 1. Results of HIV Reservoir Assessment

Time Point ^a	Tissue	Assay				
		ddPCR Pol ^b	ddPCR Gag ^c	No. of Cells Assayed by ddPCR	ISH DNA ^d	ISH RNA ^e
Pretransplant						
–60	PBMCs	211.26	146.11	74 600	-	-
–20	PBMCs	496.43	140.89	112 000	-	-
–8	PBMCs	260.10	152.33	193 000	-	-
	Rectum	71.75	35.80	53 800	2.58×10^5	0
Post-transplant						
+22	Rectum	0	0	16 100	2.60×10^4	0
+35	PBMCs	0	0	135 000	-	-
+49	PBMCs	0	0	70 000	-	-
+73 (autopsy)	Brain	0	0	22 600	7.35×10^2	0
	Lung	0	22.57	101 000	1.57×10^4	0
	Lymph node	0	0	85 900	1.06×10^5	0
	Duodenum	0	0	233 000	0	0
	Ileum	0	0	84 600	0	0
	Colon	0	0	166 000	4.16×10^3	0
	Stomach	ND	ND		0	0

Abbreviations: ddPCR, droplet digital polymerase chain reaction; ISH, in situ hybridization; ND, not done; PBMC, peripheral blood mononuclear cell.

^aDays in relationship to transplant (date of transplant = day 0).

^bDigital droplet polymerase chain reaction (PCR) using joPol primer; results reported in DNA copy per 10^6 cells.

^cDigital droplet PCR using skGag primer; results reported in DNA copy per 10^6 cells.

^dCopies of HIV DNA per gram of tissue; assay performed on tissue only.

^eCopies of HIV RNA per gram of tissue; assay performed on tissue only.

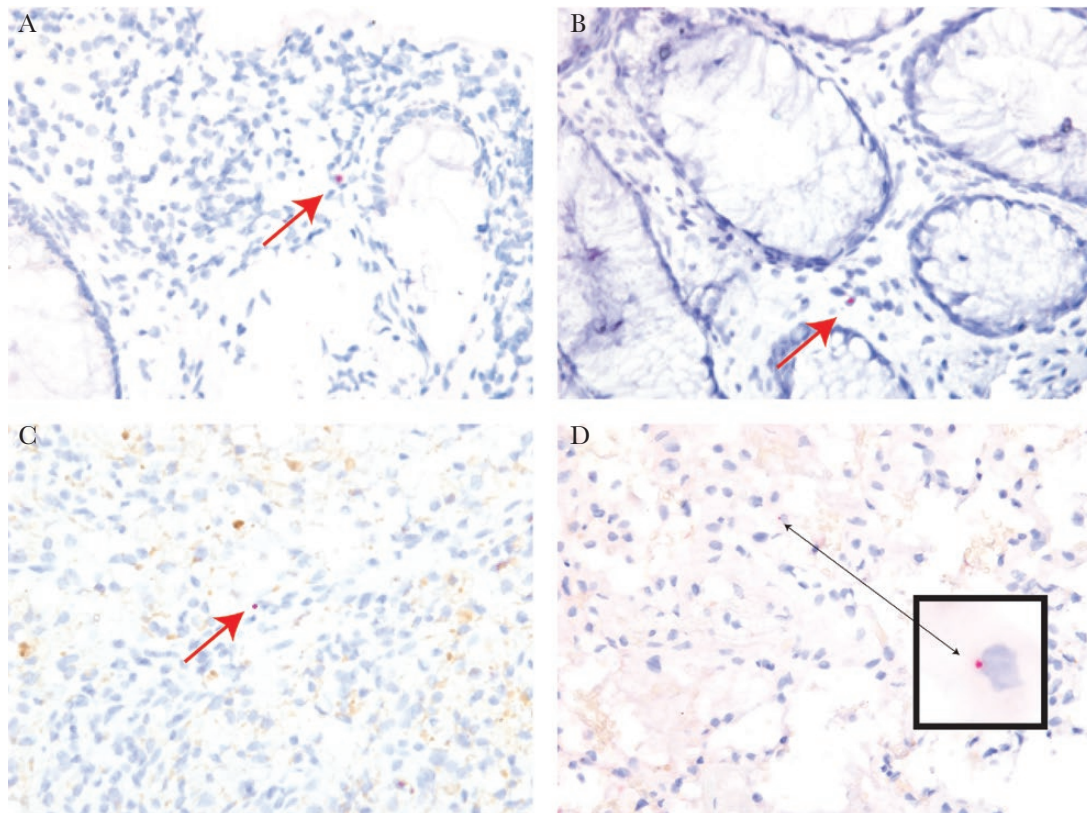


Figure 2. HIV DNA detected by next-generation in situ hybridization (DNAScope) in rectal tissue (A) obtained 22 days after transplantation and in the rectum (B), lymph node (C), and lung (D) obtained at autopsy 73 days after transplantation. HIV DNA appears red and is highlighted by arrows.

the turnover of recipient cells and the engraftment of donor cells in secondary LT, including LN and GI-associated LT (GALT). These tissues serve as the primary reservoir of HIV vDNA+ and vRNA+ cells and appear to be the source of viral recrudescence after treatment interruption [21]. In the Berlin Patient, CCR5+-expressing macrophages were detected in rectal tissue more than 5 months after transplant, although no HIV was detected [2]. In our patient, we detected presumed recipient

cells (CCR5+CD68+ macrophages and CCR5+CD3+ T cells) in the LN 73 days post-transplant despite full donor engraftment in the PB and BM; we also detected vDNA in the colon and LN at this time point. These findings suggest that (1) the turnover of recipient hematopoietic cells in secondary LT is a protracted process, (2) engraftment in PB and BM may not predict engraftment status in the secondary LTs, and (3) these long-lived, radiation- and chemotherapy-resistant recipient cells can harbor HIV for months after transplantation.

We also found vDNA in our patient's lung tissue postmortem, which is consistent with evidence that alveolar macrophages (AMs) can harbor HIV DNA [22–24]. There is also evidence that AMs repopulate slowly and remain of recipient origin for at least weeks after allo-HCT, likely explaining the detection of vDNA in this tissue [25].

Although we detected vDNA in multiple tissues, we were unable to assess replication competency. However, we readily detected vDNA despite sampling only a fraction of our patient's tissues, suggesting that the total number of vDNA+ cells was substantial at the time of death. Given evidence that up to 5% of vDNA+ cells harbor replication competent provirus, it seems likely that withdrawing ART in this individual would have resulted in recrudescence of virus replication [26, 27]. Furthermore, in the Boston Patients, viral rebound after

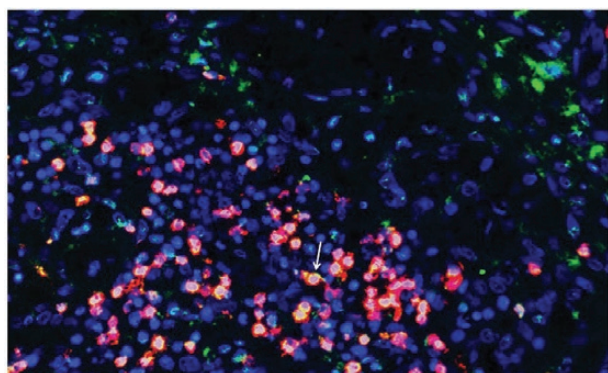


Figure 3. Lymph node obtained at autopsy 73 days after transplantation. CD3-positive T cells (green), CCR5-expressing cells (red) and double-positive cells (yellow; denoted by white arrow).

allo-HCT resulted from activation of only 1 or a few latently infected cells, demonstrating that even a very small HIV reservoir post-transplant has the potential to avert cure [3].

There were also differences between measures of HIV DNA by ddPCR and direct visualization by ISH, highlighting the challenge of reservoir measures in tissues. The results of these 2 assays varied, with vDNA being detected in only the rectum and lung post-transplant by ddPCR but in multiple tissues using DNAScope. After processing and disaggregating each tissue, only limited, unsorted cell populations could be assessed by ddPCR. The sensitivity of ddPCR was also likely further impacted by proviral sequence variation as only 2 PCR primers were used. On the other hand, DNAScope utilizes intact tissue, thereby minimizing cellular loss, and has high sensitivity through the use of a combination of ZZ probes in a cocktail probe mixture (40–85 ZZ pairs with approximately 2 to 4.2 kb of genome coverage) and an amplification cascade via sequential hybridization that allows for the visualization of individual virions or vDNA within the nuclei of infected cells [16]. HIV DNA extracted from tissues can be readily quantitated, but the number of CD4 lymphocytes or macrophages being interrogated cannot be measured at present. However, these results highlight the need for multiple measures of vRNA and vDNA to assess the impact of cure interventions, as was done with the Berlin Patient [1].

Finally, our results have implications for the clinical management of HIV+ patients undergoing allo-HCT. First, given our tissue results, we believe that post-transplant ART should be used, even though ART dosing is complex and requires careful attention to drug/drug interactions and an understanding of ARV pharmacokinetics [28]. In our patient, multiple ARV dose adjustments were required due to subtherapeutic plasma drug concentrations, presumably related to impaired GI absorption in the setting of HCT, suggesting that ARV monitoring should be routine for HIV patients undergoing allo-HCT. Furthermore, in this patient, the conversion from intravenous to oral CSA corresponded with the development of GVHD, and drug/drug interactions could have exacerbated this. We were not able to determine the optimal duration of ARVs post-transplant using treatment interruption or additional tissue sampling given our patient's untimely death, but this will need to be addressed in the future.

Second, in our patient, only the commercially available phenotypic CCR5 trophile assay was used to determine HIV tropism. However, this assay may miss minority CXCR4 variants that can be selected for by CCR5Δ32 allo-HCT, leading to virologic rebound, as has been reported [28, 29]. Although it is unknown if these variants existed in our patient or if they would have emerged post-transplant after stopping ARVs, in the future, consideration should be given to using next-generation sequencing techniques to assess for X4 variants before pursuing CCR5Δ32 allo-HCT.

Third, our case illustrates the risks of a curative approach using allogeneic transplantation in HIV-infected patients. At

present, it is unclear whether the use of a biallelic mutated CCR5 donor increases the risk of transplant-related mortality. Individuals with this genetic variation have no overt medical problems [30]. However, cure approaches using transplantation and CCR5Δ32 hematopoietic stem cell grafts in HIV+ individuals have resulted in a higher than expected mortality.

In summary, we present evidence that HIV can persist in tissues months after myeloablative UCB allo-HCT with CCR5Δ32 donor cells despite clearance of measurable HIV DNA from PBMCs. Our experience provides insight into the optimal management of HIV-infected patients with hematologic malignancies undergoing allo-HCT with CCR5Δ32 donor cells and also provides new information about the optimal tools to use when assessing new cure strategies.

Acknowledgments

Financial support. This work was supported by the following grants: National Institutes of Health grant numbers P01 CA65493 to M.R.V. and J.S.M., AI100879 to M.R.V., U19AI096109 and P01AI074340 to TWS RO1AI124965 to C.V.F. This work was also funded in part with federal funds from the National Cancer Institute, National Institutes of Health (Contract No. HHSN261200800001E to J.E.). The content of this publication does not necessarily reflect the views or policies of the Department of Health and Human Services, nor does mention of trade names, commercial products, or organizations imply endorsement by the US Government.

Potential conflicts of interest. D.R. receives personal fees from Gilead, Antiva, Merck, and Monogram. All authors have submitted the ICMJE Form for Disclosure of Potential Conflicts of Interest. Conflicts that the editors consider relevant to the content of the manuscript have been disclosed.

References

1. Yukt SA, Boritz E, Busch M, et al. Challenges in detecting HIV persistence during potentially curative interventions: a study of the Berlin Patient. *PLoS Pathog* 2013; 9:e1003347.
2. Hütter G, Nowak D, Mossner M, et al. Long-term control of HIV by CCR5 Delta32/Delta32 stem-cell transplantation. *N Engl J Med* 2009; 360:692–8.
3. Henrich TJ, Hanhauser E, Marty FM, et al. Antiretroviral-free HIV-1 remission and viral rebound after allogeneic stem cell transplantation: report of 2 cases. *Ann Intern Med* 2014; 161:319–27.
4. Kurtzberg J, Prasad VK, Carter SL, et al; COBLT Steering Committee. Results of the Cord Blood Transplantation Study (COBLT): clinical outcomes of unrelated donor umbilical cord blood transplantation in pediatric patients with hematologic malignancies. *Blood* 2008; 112:4318–27.
5. Petz LD, Redei I, Bryson Y, et al. Hematopoietic cell transplantation with cord blood for cure of HIV infections. *Biol Blood Marrow Transplant* 2013; 19:393–7.
6. Duarte RF, Salgado M, Sánchez-Ortega I, et al. CCR5 Δ32 homozygous cord blood allogeneic transplantation in a patient with HIV: a case report. *Lancet HIV* 2015; 2:e236–42.
7. Kwon M, Balsalobre P, Serrano D, et al. Single cord blood combined with HLA-mismatched third party donor cells: comparable results to matched unrelated donor transplantation in high-risk patients with hematologic disorders. *Biol Blood Marrow Transplant* 2013; 19:143–9.
8. Embretson J, Zupancic M, Ribas JL, et al. Massive covert infection of helper T lymphocytes and macrophages by HIV during the incubation period of AIDS. *Nature* 1993; 362:359–62.
9. Haase AT. Population biology of HIV-1 infection: viral and CD4+ T cell demographics and dynamics in lymphatic tissues. *Annu Rev Immunol* 1999; 17:625–56.
10. Haase AT, Henry K, Zupancic M, et al. Quantitative image analysis of HIV-1 infection in lymphoid tissue. *Science* 1996; 274:985–9.
11. Reinhart TA, Rogan MJ, Huddleston D, et al. Simian immunodeficiency virus burden in tissues and cellular compartments during clinical latency and AIDS. *J Infect Dis* 1997; 176:1198–208.
12. Schacker T, Little S, Connick E, et al. Productive infection of T cells in lymphoid tissues during primary and early human immunodeficiency virus infection. *J Infect Dis* 2001; 183:555–62.

13. Delahunty T, Bushman L, Robbins B, Fletcher CV. The simultaneous assay of tenofovir and emtricitabine in plasma using LC/MS/MS and isotopically labeled internal standards. *J Chromatogr B Analyt Technol Biomed Life Sci* **2009**; 877:1907–14.
14. Sandkovsky U, Swindells S, Robbins BL, et al. Measurement of plasma and intracellular concentrations of raltegravir in patients with HIV infection. *AIDS* **2012**; 26:2257–9.
15. Podany AT, Winchester LC, Robbins BL, Fletcher CV. Quantification of cell-associated atazanavir, darunavir, lopinavir, ritonavir, and efavirenz concentrations in human mononuclear cell extracts. *Antimicrob Agents Chemother* **2014**; 58:2866–70.
16. Deleage C, Wietgreffe SW, Del Prete G, et al. Defining HIV and SIV reservoirs in lymphoid tissues. *Pathog Immun* **2016**; 1:68–106.
17. Strain MC, Lada SM, Luong T, et al. Highly precise measurement of HIV DNA by droplet digital PCR. *PLoS One* **2013**; 8:e55943.
18. Massanella M, Gianella S, Lada SM, et al. Quantification of total and 2-LTR (long terminal repeat) HIV DNA, HIV RNA and herpesvirus DNA in PBMCs. *Bio Protoc* **2015**; 5:pii: e1492.
19. Rousseau CM, Nduati RW, Richardson BA, et al. Association of levels of HIV-1-infected breast milk cells and risk of mother-to-child transmission. *J Infect Dis* **2004**; 190:1880–8.
20. Mulder J, McKinney N, Christopherson C, et al. Rapid and simple PCR assay for quantitation of human immunodeficiency virus type 1 RNA in plasma: application to acute retroviral infection. *J Clin Microbiol* **1994**; 32:292–300.
21. Rothenberger MK, Keele BF, Wietgreffe SW, et al. Large number of rebounding/founder HIV variants emerge from multifocal infection in lymphatic tissues after treatment interruption. *Proc Natl Acad Sci U S A* **2015**; 112:E1126–34.
22. Yearsley MM, Diaz PT, Knoell D, Nuovo GJ. Correlation of HIV-1 detection and histology in AIDS-associated emphysema. *Diagn Mol Pathol* **2005**; 14:48–52.
23. Cribbs SK, Lennox J, Caliendo AM, et al. Healthy HIV-1-infected individuals on highly active antiretroviral therapy harbor HIV-1 in their alveolar macrophages. *AIDS Res Hum Retroviruses* **2015**; 31:64–70.
24. Jambo KC, Banda DH, Kankwatira AM, et al. Small alveolar macrophages are infected preferentially by HIV and exhibit impaired phagocytic function. *Mucosal Immunol* **2014**; 7:1116–26.
25. Nakata K, Gotoh H, Watanabe J, et al. Augmented proliferation of human alveolar macrophages after allogeneic bone marrow transplantation. *Blood* **1999**; 93:667–73.
26. Ho YC, Shan L, Hosmane NN, et al. Replication-competent noninduced proviruses in the latent reservoir increase barrier to HIV-1 cure. *Cell* **2013**; 155:540–51.
27. Bruner KM, Murray AJ, Pollack RA, et al. Defective proviruses rapidly accumulate during acute HIV-1 infection. *Nat Med* **2016**; 22:1043–9.
28. Kordelas L, Verheyen J, Beelen DW, et al; Essen HIV AlloSCT Group. Shift of HIV tropism in stem-cell transplantation with CCR5 Delta32 mutation. *N Engl J Med* **2014**; 371:880–2.
29. Hütter G. More on shift of HIV tropism in stem-cell transplantation with CCR5 delta32/delta32 mutation. *N Engl J Med* **2014**; 371:2437–8.
30. Galvani AP, Novembre J. The evolutionary history of the CCR5-Delta32 HIV-resistance mutation. *Microbes Infect* **2005**; 7:302–9.