

[ CASE REPORT ]

## Clinical Characteristics and Predictors Related to the Progression of Multinodular Goiter Causing Tracheal Compression and Deviation: A Report of Two Cases and Review of the Literature

Toshihiro Takamori<sup>1</sup>, Shoichiro Izawa<sup>2</sup>, Takahiro Fukuhara<sup>3</sup>, Akemi Sato<sup>1</sup>, Hitomi Ichikawa<sup>1</sup>, Toru Motokura<sup>4</sup>, Kazuhiro Yamamoto<sup>2</sup> and Tetsuya Fukuda<sup>1</sup>

### Abstract:

We describe the clinical course of two patients who developed tracheal compression and deviation by multinodular goiter (MNG). Case 1: A 66-year-old woman presented with thyroid swelling. Five years after the initial admission, she was diagnosed with hyperthyroidism by Graves' disease and increased bilateral thyroid lobes compressing the trachea. Thyroglobulin was elevated from 210 to 472 ng/mL. Case 2: A 52-year-old woman presented with thyroid swelling. Five years after the initial admission, the increased right lobe deviated the trachea and compressed the right recurrent laryngeal nerve. Thyroglobulin was elevated from 122 to 392 ng/mL. Two cases and literature review indicated that MNG with >50 mm, solid components, and extension to the mediastinum or paralarynx were risk factors of tracheal compression and deviation. Monitoring thyroglobulin elevation can help predict the clinical course.

**Key words:** multinodular goiter, tracheal compression, tracheal deviation, thyroglobulin, hyperthyroidism

(Intern Med 61: 1375-1381, 2022)

(DOI: 10.2169/internalmedicine.7989-21)

### Introduction

Benign thyroid nodules are detected quite frequently in general clinical practice. Despite unremarkable thyroid physical examination findings, thyroid nodules are identified by an ultrasound evaluation in up to 50% of the general population (1). It is generally accepted that iodine deficiency is the most common environmental factor associated with benign thyroid nodules.

Multinodular goiter (MNG) constitutes nodular hyperplasia of thyroid follicular cells and causes approximately 30% of thyroid nodules (2). When a thyroid nodule >10 mm in size is documented by ultrasound, fine-needle aspiration cytology (FNAC) is indicated on the basis of features associated with malignancy (3). When malignancy is denied following ultrasound and FNAC examinations, observation by

ultrasound is indicated (3).

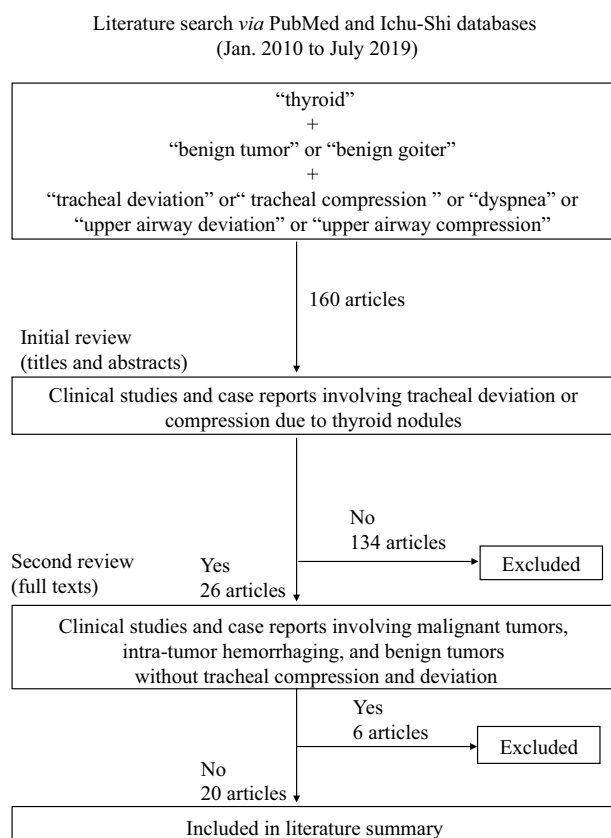
Treatment for MNG includes surgery, <sup>131</sup>I radioiodine, and thyroid-stimulating hormone (TSH) suppression by levothyroxine (4). However, few patients with MNG require surgery. Mediastinum MNG is an established surgical indication based on evidence that the lower thyroid pole tends to increase in size due to negative pressure and gravity in the thoracic cavity (5, 6). Because most nodules do not substantially grow during five years of follow-up (7), there have been few case reports regarding other clinical features associated with MNG progression.

We herein report two patients admitted to our clinic because of MNG who required surgery for tracheal compression and deviation after progression. We also describe the current literature involving patients who required surgery for relief of tracheal compression and deviation.

<sup>1</sup>Division of Clinical Laboratory, Tottori University Hospital, Japan, <sup>2</sup>Division of Endocrinology and Metabolism, Tottori University Faculty of Medicine, Japan, <sup>3</sup>Department of Otolaryngology, Head and Neck Surgery, Tottori University Faculty of Medicine, Japan and <sup>4</sup>Division of Clinical Laboratory Medicine, Tottori University Faculty of Medicine, Japan

Received: May 18, 2021; Accepted: September 1, 2021; Advance Publication by J-STAGE: October 19, 2021

Correspondence to Dr. Shoichiro Izawa, s-izawa@tottori-u.ac.jp



**Figure 1.** Flow chart of literature review selection process.

### Biochemical parameters

In our case presentation, the concentrations of TSH, free thyroxine (T4), thyroglobulin (Tg), Tg autoantibody (TgAb), TSH receptor autoantibody (TRAb), and thyroid peroxidase autoantibody were evaluated using an electrochemiluminescence immunoassay (ECLusys; Roche Diagnostics, Rotkreuz, Switzerland); the reference ranges of these parameters are 0.27-4.2  $\mu$ U/mL, 1.0-1.8 ng/dL, <33.7 ng/mL, <28 IU/mL, <2.0 IU/mL, and <16 IU/mL, respectively.

### Literature review

We conducted a literature search to identify publications regarding progression of MNG causing tracheal compression and deviation. Original articles and case reports published from January 2010 to July 2019 were surveyed on July 31, 2019, using the following keywords: “thyroid”; “benign tumor” or “benign goiter”; and “tracheal deviation” or “tracheal compression” or “dyspnea” or “upper airway deviation” or “upper airway compression.” The search was performed in both PubMed and a Japanese database, Ichu-Shi web. The titles and abstracts were reviewed by two authors (T.T. and S.I.). Publications in languages other than English, as well as articles/reports involving malignant tumors, intra-tumor hemorrhaging, and benign tumors without tracheal compression and deviation, were excluded from this review (Fig. 1).

## Case Reports

### Case 1

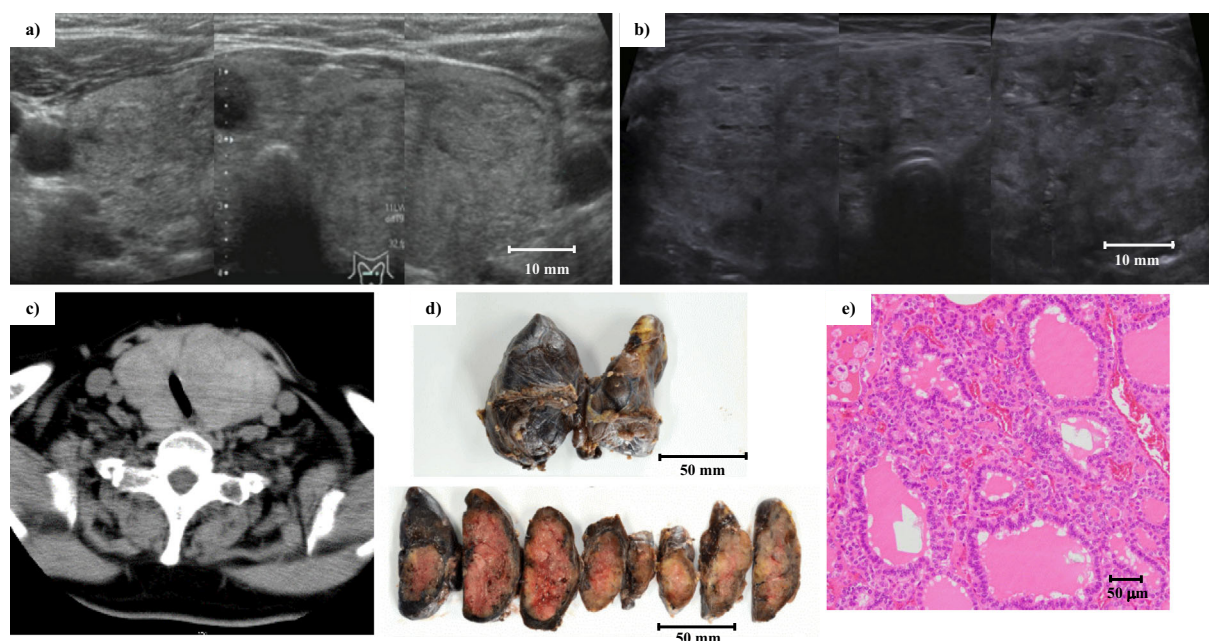
A 66-year-old woman was admitted to our clinic because of diffuse goiter. Her thyroid function test (TFT) results revealed euthyroid status, with TSH level of 0.387  $\mu$ U/mL and free T4 level of 1.53 ng/dL. Her Tg level was elevated to 210 ng/mL, although her TgAb findings were negative. Transverse thyroid ultrasound revealed diffuse swelling of the bilateral thyroid lobes (right lobe width: 31.6 mm, right lobe depth: 21.9 mm, left lobe width: 36.2 mm, left lobe depth: 31.5 mm, isthmus depth: 12.4 mm) and a solid nodule with indistinct boundaries (largest diameter: 40 mm) in the left lobe (Fig. 2a). FNAC did not reveal any cytologically significant findings associated with malignancy. The patient was diagnosed with MNG and recommended to undergo annual ultrasound observation.

Five years after initial admission, the patient was diagnosed with Graves' disease and began thiamazole therapy with TSH level of 0.04  $\mu$ U/mL and free T4 level of 1.82 ng/dL. Her TRAb level was elevated to 4.8 IU/mL. She had wheezing and mild dyspnea on exertion, but her symptoms improved following the normalization of TFT by thiamazole. A general clinical workup to rule out cardiovascular and respiratory disease did not show any significant findings.

Two years after she had been diagnosed with Graves' disease, the patient was referred to our clinic due to chest pain during exertion. On admission, she had shortness of breath. However, a general clinical workup to rule out cardiovascular and respiratory disease did not show any significant findings, except for stridor in the upper airway. Her TFT results revealed euthyroid status, with TSH level of 1.40  $\mu$ U/mL and free T4 level of 1.11 ng/dL. No history of hypothyroidism was observed before the admission. Her TRAb level was elevated to 5.0 IU/mL, and her Tg level was elevated to 472 ng/mL. Her TgAb finding was negative.

Transverse thyroid ultrasound demonstrated considerable enhancement of the left lobe volume compared with the initial admission (right lobe width: 32.9 mm, right lobe depth: 27.2 mm, left lobe width: 48.8 mm, left lobe depth: 34.2 mm, isthmus depth: 17.9 mm; Fig. 2b). Nodules documented during the initial admission were difficult to detect. Computed tomography (CT) revealed nodular swelling of bilateral thyroid lobes and tracheal compression (Fig. 2c). Her estimated thyroid volume was 196 mL. Her chest pain and shortness of breathing were suggested to correlate with tracheal compression. Thus, total thyroidectomy was performed to prevent suffocation.

A histopathological evaluation demonstrated multiple nodular lesions with thyroid follicles. The nodules exhibited partial capsular formation. The patient's histopathological diagnosis was consistent with MNG (Fig. 2d, e).



**Figure 2.** Imaging findings and histopathological evaluation results of the patient in case 1. Transverse thyroid ultrasound on initial admission (a) revealed diffuse swelling of bilateral thyroid lobes. Thyroid ultrasound (b) and cervical computed tomography (c) on subsequent admission (due to shortness of breath) showed enlargement of the bilateral thyroid lobes and tracheal compression. A macroscopic analysis of the nodules demonstrated partial capsular formation (d). A microscopic analysis (Hematoxylin and Eosin staining,  $\times 200$ ) showed features consistent with multinodular goiter (e).

## Case 2

A 52-year-old woman was admitted to our clinic because of diffuse goiter that had begun 5 years prior. Her TFT results revealed euthyroid status, with TSH level of  $0.477 \mu\text{U/mL}$  and free T4 level of  $1.00 \text{ ng/dL}$ . Her Tg level was elevated to  $122 \text{ ng/mL}$ , although her TgAb and thyroid peroxidase autoantibody findings were negative. Transverse thyroid ultrasound demonstrated diffuse swelling of the thyroid gland with right lobe predominance (right lobe width:  $27.8 \text{ mm}$ , right lobe depth:  $23.8 \text{ mm}$ , left lobe width:  $11.1 \text{ mm}$ , left lobe depth:  $10.2 \text{ mm}$ , isthmus depth:  $1.7 \text{ mm}$ ; Fig. 3a). A heterogeneous solid nodule (largest diameter:  $43 \text{ mm}$ ) was observed in the right lobe. FNAC results were suggestive of follicular neoplasm. The patient was therefore recommended to undergo an annual examination. One year after initial admission, ultrasound revealed that the nodule had grown to  $50 \text{ mm}$ , while the FNAC findings were unchanged from the prior admission. However, the patient was then lost to follow-up.

Five years after the initial admission, the patient was re-admitted to our clinic because of hoarseness and dysphagia. General clinical workup to rule out cardiovascular and respiratory disease did not show any significant findings. Stridor was not auscultated. However, right vocal cord incomplete paralysis was noted on an endoscopic examination. Her TFT results revealed euthyroid status with TSH level of  $0.400 \mu\text{U/mL}$  and free T4 level of  $1.13 \text{ ng/dL}$ . Her Tg level was elevated to  $392 \text{ ng/mL}$ , although her thyroid autoanti-

body findings were all negative (TRAb  $<0.3 \text{ IU/mL}$ , TgAb  $<10 \text{ IU/mL}$ , and thyroid peroxidase autoantibody  $<9 \text{ IU/mL}$ ). Transverse thyroid ultrasound revealed that the right lobe volume (width:  $58.4 \text{ mm}$ , depth:  $39.3 \text{ mm}$ ; Fig. 3b) had increased compared with the initial admission. The nodule in the right lobe had grown to  $62 \text{ mm}$  in diameter. CT revealed a heterogeneous nodule with indistinct boundaries in the right lobe as well as tracheal deviation (Fig. 3c). Her estimated thyroid volume was  $169 \text{ mL}$ .

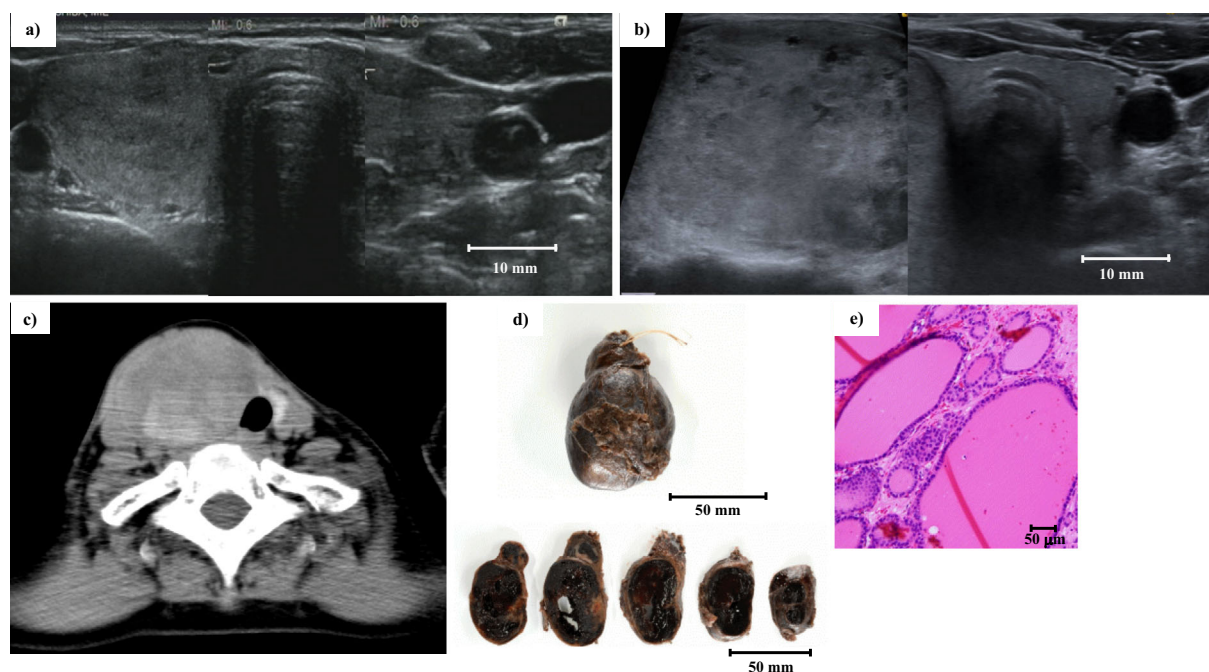
Hemi-thyroidectomy of the right lobe was performed to relieve tracheal deviation and right recurrent laryngeal nerve compression. Her hoarseness and dysphagia completely recovered after the surgery. A histopathological evaluation revealed a nodular lesion with follicles of various sizes. The nodules exhibited unclear capsular formation. Hemorrhaging and fibrosis were observed in the interstitial tissue. The patient's histopathological diagnosis was consistent with MNG (Fig. 3d, e).

## Discussion

MNG is one of the most common benign findings on an ultrasound evaluation of thyroid nodules (2). Most instances of MNG do not exhibit growth during five years of follow-up (7). Accordingly, there are limited indications for surgical treatment of MNG.

We conducted a literature search to identify publications regarding progression of MNG causing tracheal compression and deviation. Publications involving malignant tumors,





**Figure 3.** Imaging findings and histopathological evaluation results of the patient in case 2. Transverse thyroid ultrasound on initial admission (a) revealed diffuse swelling of the thyroid gland with right lobe predominance. On subsequent admission (due to hoarseness and dysphagia), the trachea was deviated to the left by a large heterogeneous nodule in right lobe, detected by ultrasound (b) and cervical computed tomography (c). A macroscopic analysis of the right lobe showed hemorrhaging and fibrosis in the interstitial tissue (d). A microscopic analysis (Hematoxylin and Eosin staining,  $\times 200$ ) revealed features consistent with multinodular goiter (e).

intra-tumor hemorrhaging, and benign cases without tracheal compression and deviation were excluded from this review (Fig. 1).

Twenty publications (8-27) including 42 patients were reviewed based on the evaluation method summarized in Fig. 1. Table presents the clinical characteristics, thyroid sizes, nodule sizes and characteristics, and TFT results of all included publications and our two patients. Nineteen of the publications (8-26) were case reports, while one was an original article (27). The mean patient age was 64 years old. Women were most frequently affected (man-to-woman ratio of 9:33). The most common symptoms were dyspnea and dysphagia. Increased edema, secretion, bleeding due to respiratory disease, and a smoking habit were identified as risk factors (24).

The total median transverse length of the bilateral thyroid lobes in 5 patients (1 evaluated by histopathology and 4 evaluated by CT) (9, 17, 26) was 82 (62-98) mm. The median thyroid volume was 275 (range, 156-800) mL in 8 patients (6 evaluated by histopathology and 2 evaluated by CT) (10, 22). A case series involving 65 asymptomatic patients with upper way obstruction reported by Sorensen et al. (28) revealed a median thyroid volume of 58 (14-642) mL, as determined by magnetic resonance imaging. Our literature review suggested that the symptoms of the patients were associated with increasing thyroid volume.

The median diameter of the main thyroid nodule in 10

patients (4 evaluated by histopathology and 6 evaluated by CT) (8, 15, 16, 20, 21, 24, 25) was 91 (50-150) mm. The minimum thyroid nodule diameter was 50 mm in our patients with tracheal compression and deviation. An indication of surgery for benign nodules  $>40$  mm in size is thus reasonable in accordance with the current guidelines (3). Bilateral nodules were documented on preoperative CT in 15 of the 29 cases. Consistent with an established surgical indication of MNG (5, 6), 26 of 29 cases had MNG that extended to the mediastinum. In contrast, 7 of 29 cases had MNG that extended to the paralarynx. The main nodule consisted of solely solid components in 15 of 29 cases. Cystic nodules were observed in only 2 of 29 cases.

TFT results were reported for 42 patients. Notably, 13 of the 42 patients showed hyperthyroidism (10-12, 18, 22, 27), despite the TFT data not being severe. Thyroglobulin levels were not present in the reviewed literature. However, obvious Tg elevation was observed in both of our patients.

According to the guidelines of the American Thyroid Association (3), nodules  $>40$  mm in size that tend to grow despite benign cytology findings and those with the potential to compress adjacent organs are recommended for surgery. Our two patients had a natural history of MNG requiring surgical treatment, although the reviewed literature did not describe the time course of MNG progression.

A surgical indication for MNG causing tracheal compression and deviation is rare in the clinical setting. However,

**Table. Clinical Characteristics of Previously Reported Patients with Multinodular Goiter Requiring Surgery for Tracheal Compression and Deviation.**

	Total	Case 1	Case 2	Summary of reviewed case reports [8-26]	[27]	
Age (years)	64	66	52	60±16*	72±9*	
Patients number	42	1	1	27	13	
Sex (M/F)	9/33	0/1	0/1	7/20	2/11	
Chief complaint**						
	Dyspnea	0	0	18	2	
	Dysphagia	0	1	2	6	
	Shortness of breath	1	0	4	0	
	Dysphonia	0	0	1	2	
	Chest pain	1	0	2	0	
	Hoarseness	0	1	0	0	
	Facial edema	0	0	1	0	
	Unconsciousness	0	0	1	0	
	Wheezing	0	0	1	0	
	Coldness	0	0	1	0	
	Discoloration	0	0	1	0	
	Paresthesia	0	0	1	0	
	Cough	0	0	0	1	
Thyroid size	Total transverse length of the bilateral lobes (mm)	82 (62-98)***, n=5	82	69	90 (62-98)***, n=3	ND
	Volume (mL)	275 (156-800)***, n=8	196	169	340 (156-800)***, n=6	ND
Nodule size	Diameter (mm)	91 (50-150)***, n=10	ND	62	93 (50-150)***, n=9	ND
Localization of nodule	Bilateral lobe	15	0	0	15	ND
	Right lobe	7	0	1	6	ND
	Left lobe	7	1	0	6	ND
Direction of nodular extension**	Mediastinum	26	1	1	24	ND
	Paralarynx	7	0	1	6	ND
Components of nodule	solid	15	1	1	13	ND
	mixed	8	0	0	8	ND
	cystic	2	0	0	2	ND
Thyroid function	Hyperthyroid	13	0	1	6	6
	Euthyroid	28	1	0	20	7
	Hypothyroid	1	0	0	1	0
	TSH (μU/mL)	0.40 (0.003-2.1)***, n=7	1.40	0.40	0.345 (0.0003-2.1)***, n=5	ND
	Free T4 (ng/dL)	1.11 (0.9-1.25)***, n=7	1.11	1.13	1.1 (0.9-1.25)***, n=5	ND
Thyroglobulin level on initial admission /at surgery (ng/mL)		166 (122-210)*** /432 (392-472)***, n=2	210/472	122/392	ND/ND	ND/ND

Data are shown as number unless otherwise indicated.

ND: not determined, \*: mean±standard deviation, \*\*: multiple complaints or phenotypes were acceptable, \*\*\*: median (range)

the time course of MNG progression may be predicted based on the clinical features. Alfonso et al. reported a case series involving 273 benign thyroid nodules that underwent surgical treatment. Approximately 22% of the affected patients experienced dyspnea or dysphagia. However, only 2.3% experienced acute progression requiring emergent surgery. In addition, they reported that tracheal deviation and thyroiditis were risk factors for MNG progression (29). Rios et al. also reported that patients with a high risk of progression to tracheal compression were those who had nodules with intrathoracic components and those >55 years old with observational periods of >10 years (30). There is a possibility that other factors (except nodule size) may contribute to tracheal compression associated with MNG progression. Our literature review suggests that MNG with solid components that extend to the mediastinum or paralarynx are frequently

observed in cases with tracheal compression and deviation.

Kadhim et al. (31) reported that excess iodine intake increased the possibility of tracheal compression on thyrotoxicosis in five patients with MNG. The patient in case 1 was diagnosed with Graves' disease during follow-up. Graves' disease is a common cause of hyperthyroidism, due to diffuse swelling and enhanced blood flow to the thyroid gland, involving TRAb (32); notably, the production of TRAb can stimulate the enlargement of the thyroid volume. In our literature review, no etiology was stated for 9 of the 12 patients with hyperthyroidism, and 3 were diagnosed with toxic MNG (10-12, 18, 22, 28). Ten of the 12 patients were reported from Europe. The prevalence of toxic MNG in Europe is known to be extremely high compared to that in Japan (33). The development of hyperthyroidism may thus be regarded as a potential cause of MNG progression. How-

ever, further studies will be necessary to consider the etiology of hyperthyroidism.

Tg is a secretory protein synthesized by the endoplasmic reticulum of the thyroid gland; its primary functions include the storage of iodide and production of thyroid hormone (34). Under normal conditions, a small amount of Tg is detected in serum. However, the production of Tg can be enhanced by the presence of tumors originating from thyroid follicular cells and by stimulation with TRAb. The destruction of thyroid follicular cells by inflammation can also contribute to elevated serum Tg levels. Elevated Tg is common in various thyroid diseases, including differentiated thyroid carcinomas and benign nodules, Graves' disease, destructive thyroiditis, and elevation of TSH induced by primary hypothyroidism (35). Therefore, it is difficult to distinguish whether a thyroid nodule is benign or malignant based on a spot Tg analysis alone. A serum Tg analysis of TgAb-positive samples should be presumed to carry high risks of both false negative and false positive results (36). However, our two patients exhibited Tg elevation from their initial admission until surgical treatment of tracheal compression. Tg monitoring over time in a single patient may help predict the progression of the thyroid volume.

The main limitation of our literature review was that it included a small number of patients with sufficient laboratory data and imaging. Most patients did not undergo extensive preoperative clinical examinations because of the requirement for emergent surgery. A large multicenter study is therefore necessary to confirm our findings.

In conclusion, our report of two cases and review of the literature indicated that observation of nodules with solid components that extended to the mediastinum or paralarynx by imaging modalities and a time-course assessment of serum Tg level could predict tracheal compression and deviation, especially in MNG with a diameter >50 mm.

**The authors state that they have no Conflict of Interest (COI).**

#### Acknowledgement

We thank Dr. Kazuhiko Matsuzawa, Dr. Kazuhisa Matsumoto, and Dr. Kenji Fukaya from the Division of Endocrinology and Metabolism and all members of the Division of Clinical Laboratory for the evaluation and management of the patients described in this report. We also thank Dr. Naritomo Miyake, Dr. Tetsushi Koyama, Dr. Ryohei Donishi, and Dr. Kazunori Fujiwara from the Department of Otolaryngology, Head and Neck Surgery, for conducting surgical treatment and performing the histopathological evaluations. Finally, we thank Ryan Chastain-Gross, Ph.D., for editing a draft of this manuscript.

#### References

- Hegedus L, Bonnema SJ, Bencedbaek FN. Management of simple nodular goiter: current status and future perspectives. *Endocr Rev* **24**: 102-132, 2002.
- Morris LF, Ragavendra N, Yeh MW. Evidence-based assessment of the role of ultrasonography in the management of benign thyroid nodules. *World J Surg* **32**: 1253-1263, 2008.
- Haugen BR, Alexander EK, Bible KC, et al. 2015 American Thyroid Association management guidelines for adult patients with thyroid nodules and differentiated thyroid cancer: the American Thyroid Association Guidelines Task Force on Thyroid Nodules and Differentiated Thyroid Cancer. *Thyroid* **26**: 1-133, 2016.
- Hermus AR, Huysmans DA. Treatment of benign nodular thyroid disease. *N Engl J Med* **338**: 1438-1447, 1998.
- Shin JJ, Grillo HC, Mathisen D, et al. The surgical management of goiter: part I. Preoperative evaluation. *Laryngoscope* **121**: 60-67, 2011.
- Rios A, Rodriguez JM, Canteras M, Galindo PJ, Balsalobre MD, Parrilla P. Risk factors for malignancy in multinodular goitres. *Eur J Surg Oncol* **30**: 58-62, 2004.
- Durante C, Costante G, Lucisano G, et al. The natural history of benign thyroid nodules. *JAMA* **313**: 925-935, 2015.
- Machado NO, Grant CS, Sharma AK, al Sabti HA, Kolidyan SV. Large posterior mediastinal retrosternal goiter managed by a transcervical and lateral thoracotomy approach. *Gen Thorac Cardiovasc Surg* **59**: 507-511, 2011.
- Wexler S, Yamane K, Fisher KW, Diehl JT, Hirose H. Single-stage operation for giant substernal goiter with severe coronary artery disease. *Ann Thorac Cardiovasc Surg* **17**: 524-527, 2011.
- Azuma K, Oda J, Oda K, et al. A 71-year-old female with giant goiter associated with tracheomalacia. *Acute Med Surg* **1**: 242-244, 2014.
- Sato H, Masuda R, Iwazaki M, Inomoto C, Shoji S, Osamura YR. Airway obstruction caused by substernal thyrotoxic multinodular goiter. *Tokai J Exp Clin Med* **41**: 181-184, 2016.
- Giulea C, Enciu O, Nadragea M, Badiu C, Miron A. Pemberton's sign and intense facial edema in superior vena cava syndrome due to retrosternal goiter. *Acta Endocrinol (Buchar)* **12**: 227-229, 2016.
- Nistor C, Ciuche A, Constantinescu I. Emergency surgical tracheal decompression in a huge retrosternal goiter. *Acta Endocrinol (Buchar)* **13**: 370-374, 2017.
- Chafik A, Benjelloun A, Bouchentouf R, Mikou I, Ehirchiou A. Left laterotracheal retrosternal goiter with left upper limb ischemia. *Asian Cardiovasc Thorac Ann* **18**: 579-580, 2010.
- El Jaouhari SD, Doghmi N, Najout H, et al. Acute respiratory failure secondary to a cervical goitre in a pregnant woman: a case report. *BMC Emerg Med* **19**: 18, 2019.
- Chaudhry IU, Cheema AI, AlShamasi Z, Mutairi H. Hoarseness of voice, respiratory distress and dysphagia due to giant primary posterior mediastinal ectopic goitre: a rare clinical entity. *BMJ Case Rep* **2016**: bcr2016215132, 2016.
- Sohail AA, Shahabuddin S, Siddiqui MI. Ectopic thyroid mass separately present in mediastinum and not a retrosternal extension: a report of two cases. *Case Rep Surg* **2019**: 3821767, 2019.
- Bula G, Paliga M, Koziolok H, Mucha R, Gawrychowski J. Acute respiratory failure in goitre patients qualified for operative treatment. *Endokrynol Pol* **64**: 215-219, 2013.
- Mali S, Sarebanhassanabadi M. Combined open-heart coronary artery bypass surgery and subtotal thyroidectomy in a 54-year-old patient: a case report. *Ethiop J Health Sci* **26**: 285-288, 2016.
- Piao M, Yuan Y, Wang Y, Feng C. Successful management of trachea stenosis with massive substernal goiter via thacheobronchial stent. *J Cardiothorac Surg* **8**: 212, 2013.
- Chen X, Xu H, Ni Y, Sun K, Li W. Complete excision of a giant thyroid goiter in posterior mediastinum. *J Cardiothorac Surg* **8**: 207, 2013.
- Gutierrez T, Leong AC, Pang L, Chevretton E, Jeannon JP, Simo R. Multinodular thyroid goitre causing obstructive sleep apnoea syndrome. *J Laryngol Otol* **126**: 190-195, 2012.
- Shin JH, Baek JH, Oh YM, Ha EJ, Lee JH. Combination therapy of temporary tracheal stenting and radiofrequency ablation for multinodular thyroid goiter with airway compression. *Korean J*

- Radiol **14**: 805-809, 2013.
24. Ito T, Shingu K, Maeda C, et al. Acute airway obstruction due to benign asymptomatic nodular goiter in the cervical region: a case report. *Oncol Lett* **10**: 1453-1455, 2015.
  25. Garingarao CJ, Añonuevo-Cruz C, Gasacao R. Acute respiratory failure in a rapidly enlarging benign cervical goitre. *BMJ Case Rep* **2013**: bcr2013200027, 2013.
  26. McNeill CJ, Sinnott JD, Howlett D. Bilateral brachiocephalic vein compression: an unusual and rare presentation of multinodular goitre. *BMJ Case Rep* **2016**: bcr2016217074, 2016.
  27. Albareda M, Viguera J, Santiveri C, et al. Upper airway obstruction in patients with endotracheal goiter enlargement: no relationship between flow-volume loops and radiological tests. *Eur J Endocrinol* **163**: 665-669, 2010.
  28. Sorensen JR, Lauridsen JF, Dossing H, et al. Thyroidectomy improves tracheal anatomy and airflow in patients with nodular goiter: a prospective cohort study. *Eur Thyroid J* **6**: 307-314, 2017.
  29. Alfonso A, Christoudias G, Amaruddin Q, Herbsman H, Gardner B. Tracheal or esophageal compression due to benign thyroid disease. *Am J Surg* **142**: 350-354, 1981.
  30. Ríos A, Rodríguez JM, Canteras M, Galindo PJ, Tebar FJ, Parrilla P. Surgical management of multinodular goiter with compression symptoms. *Arch Surg* **140**: 49-53, 2005.
  31. Kadhim AL, Sheahan P, Timon C. Management of life-threatening airway obstruction caused by benign thyroid disease. *J Laryngol Otol* **120**: 1038-1041, 2006.
  32. Bahn RS, Burch HB, Cooper DS, et al. Hyperthyroidism and other causes of thyrotoxicosis: management guidelines of the American Thyroid Association and American Association of Clinical Endocrinologists. *Endocrine Practice* **17**: 456-520, 2011.
  33. Wiener JD. Plummer's disease: localized thyroid autonomy. *J Endocrinol Invest* **10**: 207-224, 1987.
  34. Di Jeso B, Arvan P. Thyroglobulin from molecular and cellular biology to clinical endocrinology. *Endocr Rev* **37**: 2-36, 2016.
  35. Pacini F, Pinchera A, Giani C, Grasso L, Doveri F, Baschieri L. Serum thyroglobulin in thyroid carcinoma and other thyroid disorders. *J Endocrinol Invest* **3**: 283-292, 1980.
  36. Spencer C, Petrovic I, Fatemi S, LoPresti J. Serum thyroglobulin (Tg) monitoring of patients with differentiated thyroid cancer using sensitive (second-generation) immunometric assays can be disrupted by false-negative and false-positive serum thyroglobulin autoantibody misclassifications. *J Clin Endocrinol Metab* **99**: 4589-4599, 2014.

The Internal Medicine is an Open Access journal distributed under the Creative Commons Attribution-NonCommercial-NoDerivatives 4.0 International License. To view the details of this license, please visit (<https://creativecommons.org/licenses/by-nc-nd/4.0/>).