



CASE REPORT

## Chronic hepatitis E – an emerging disease in an immunocompromised host

Amitabh Singh<sup>1</sup>, Rachna Seth<sup>1</sup>, Anand Gupta<sup>1</sup>, Shalimar<sup>2,\*</sup>,  
Baibaswata Nayak<sup>2</sup>, Subrat kumar Acharya<sup>2</sup>, Prasenjit Das<sup>3</sup>

<sup>1</sup>Department of Paediatrics, All India Institute of Medical Sciences, New Delhi, India, <sup>2</sup>Department of Gastroenterology, All India Institute of Medical Sciences, New Delhi, India and <sup>3</sup>Department of Pathology, All India Institute of Medical Sciences, New Delhi, India

\*Corresponding author. Assistant Professor, Department of Gastroenterology, All India Institute of Medical Sciences, New Delhi 110029, India. Tel: +91-11-2658866; Email: drshalimar@yahoo.com

### Abstract

Chronic hepatitis E virus (HEV) infection is increasingly being reported in immunosuppressed individuals with HIV, patients with haematological malignancy and transplant recipients. The diagnosis of cirrhosis and liver failure post chronic HEV is controversial due to lack of standard diagnostic criteria. The treatment benefits of ribavirin in chronic HEV of genotype 1 are not well reported. We report a case of chronic HEV infection of genotype 1 leading to chronic liver disease in a child cured of acute leukaemia. Our report also highlights the successful use of ribavirin for eradicating chronic HEV infection and its subsequent survival benefits. Chronic hepatitis E may be an emerging disease of immunosuppressed patients and should be suspected in the presence of cryptogenic transaminitis. Ribavirin is an effective therapy for controlling HEV.

**Key words:** chronic hepatitis E; immunosuppression; chronic liver disease; ribavirin.

### Introduction

Hepatitis E virus (HEV) infection is a public health problem in developing countries and occurs both as sporadic cases and as epidemics. A study by WHO reported that approximately 3.7 million people worldwide are affected by HEV and associated mortality is 70 000 per year [1]. The disease usually presents as a self-limiting acute illness. Chronic HEV infection has been reported in immunosuppressed individuals with HIV, haematological malignancy and transplant recipients [2]. Most of the HEV infections in immunocompromised hosts, especially those after solid organ transplantation, become chronic. The diagnosis of cirrhosis and liver failure post chronic HEV is controversial due to lack of standard diagnostic criteria. There is lack of data on treatment benefits of ribavirin in chronic HEV of genotype

1. We report a case of chronic hepatitis E infection of genotype 1 leading to chronic liver disease in a child cured of acute leukaemia. We also highlight the successful use of ribavirin in eradicating chronic HEV infection in our patient and its subsequent survival benefits.

### Case Presentation

A 13-year-old boy, treated for acute lymphoblastic leukaemia (ALL), presented two years after completion of maintenance chemotherapy with complaints of fever, vomiting, abdominal pain and loss of appetite for 5 days. There was no associated gastrointestinal bleeding or altered sensorium. The patient had a history of acute HEV infection 1 year previously and had

Submitted: 28 April 2016; Revised: 17 May 2016; Accepted: 6 June 2016

© The Author(s) 2016. Published by Oxford University Press and Sixth Affiliated Hospital of Sun Yat-Sen University.

This is an Open Access article distributed under the terms of the Creative Commons Attribution Non-Commercial License (<http://creativecommons.org/licenses/by-nc/4.0/>), which permits non-commercial re-use, distribution, and reproduction in any medium, provided the original work is properly cited. For commercial re-use, please contact [journals.permissions@oup.com](mailto:journals.permissions@oup.com)

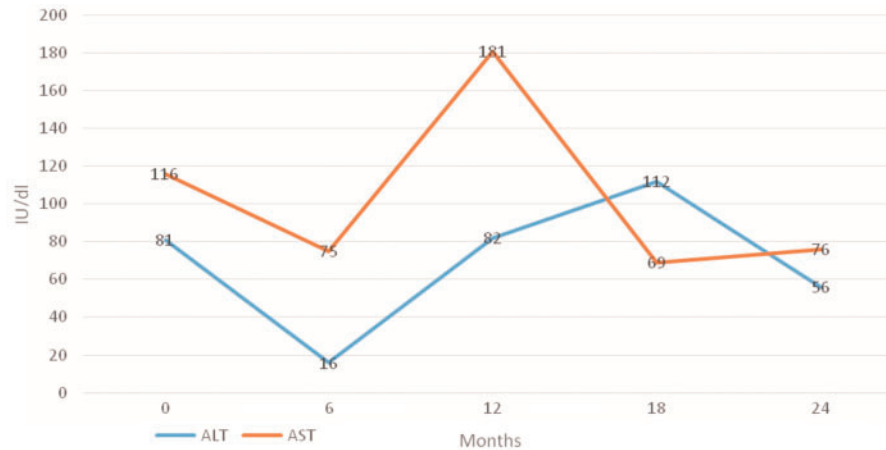


Figure 1. Trend of liver enzymes post completion of chemotherapy and HEV infection in the patient with post-HEV chronic liver disease

recovered clinically. The possibility of acute hepatitis was considered because of his current symptoms.

His liver function tests (LFT) were: total bilirubin 5.6 mg/dL (normal <1.0 mg/dL), aspartate aminotransferase 112 IU/L (normal <40 IU/L), alanine aminotransferase 69 IU/L (normal <40 IU/L). The patient had deranged prothrombin time (test 16.5, international normalized ratio (INR) 1.4 and hypoalbuminemia (2.2 g/dL)). His serology for IgM HEV (ELISA, Dia.Pro, Italy) was positive. Work-up for other viral infections including hepatitis A (IgM HAV), hepatitis B (HBsAg, IgM HbcAb) and hepatitis C (anti-HCV Ab) and ELISA for human immunodeficiency virus (HIV) were negative. Ultrasound of the abdomen revealed a coarse echotexture of liver and dilated portal vein. There were high-grade oesophageal varices on upper gastrointestinal endoscopy.

The patient was evaluated for underlying aetiology of cirrhosis, including total anti-HbcAb, HCV RNA, autoimmune markers, IgA tissue transglutaminase (tTG), copper studies and Kayser Fleischer ring, which were all negative. In view of anti-HEV IgM positivity 1 year previously and other parameters suggesting chronic liver disease, the possibility of chronic HEV infection was considered. RNA was detectable in patient sera by both nested polymerase chain reaction (PCR) and Taqman-real time PCR. Retrospective evaluation of the past treatment records showed that there had been a transient increase in aspartate transaminase (AST) / alanine transaminase (ALT) level during chemotherapy, but subsequent reports had normalised, and these results were attributed to chemotherapy drugs. The patient's laboratory parameters following the completion of chemotherapy and his first episode of HEV infection (1 year ago) are shown in Figure 1.

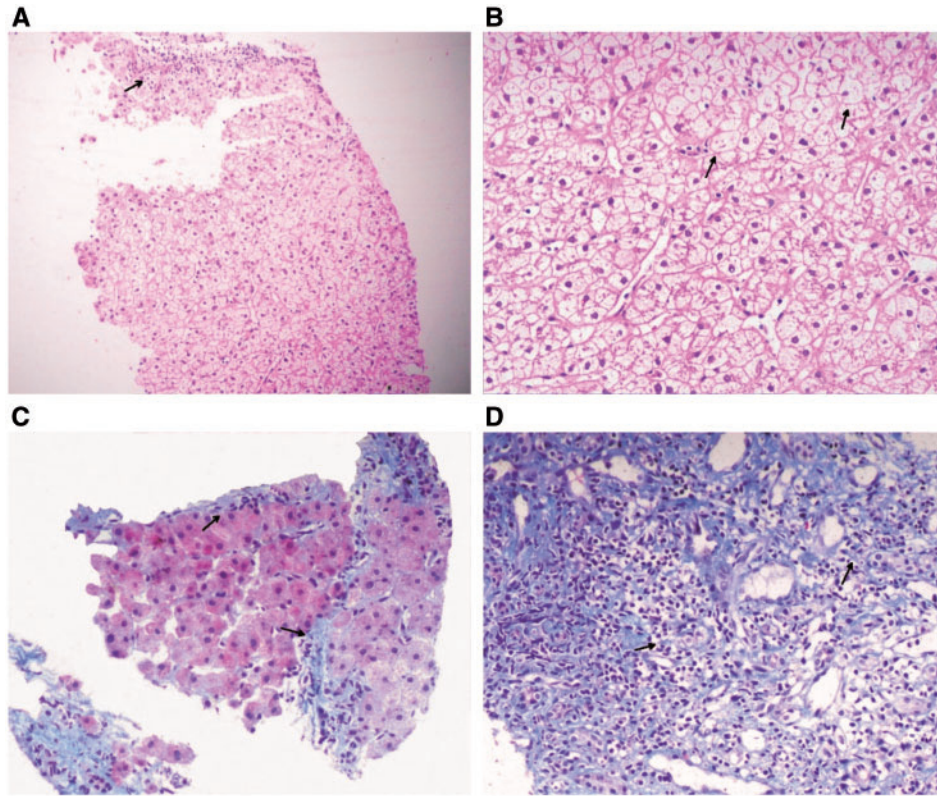
Transjugular liver biopsy showed distortion of lobular architecture, nodule formation with septae showing dense chronic inflammatory infiltrate, hepatocytes with areas of ballooning degeneration and foci of spotty necrosis (Figure 2). Orcein stain and periodic acid Schiff stains did not reveal any copper-associated proteins or cytoplasmic inclusion bodies. The patient continued to have episodes of intermittent fever and strong HEV RNA positivity for the next 3 months (Figure 3C). To determine HEV RNA genotype, sequencing of amplicon was carried out. Phylogenetic analysis of this amplicon sequence with other HEV genotype reference sequences indicated this to be HEV genotype 1 (Figure 3A). Based on these findings, a diagnosis of

chronic HEV genotype 1 infection with cirrhosis was made. The child was started on ribavirin therapy (dose 15mg/kg/d). The patient's RNA load started declining from 1 month post therapy and was significantly reduced by 3 months post therapy (Figure 3B). HEV RNA was found undetectable 9 and 12 months post therapy, consecutively (Figure 3C). After 6 months of ribavirin therapy, the patient was asymptomatic, which was corroborated with HEV RNA load in patient sera.

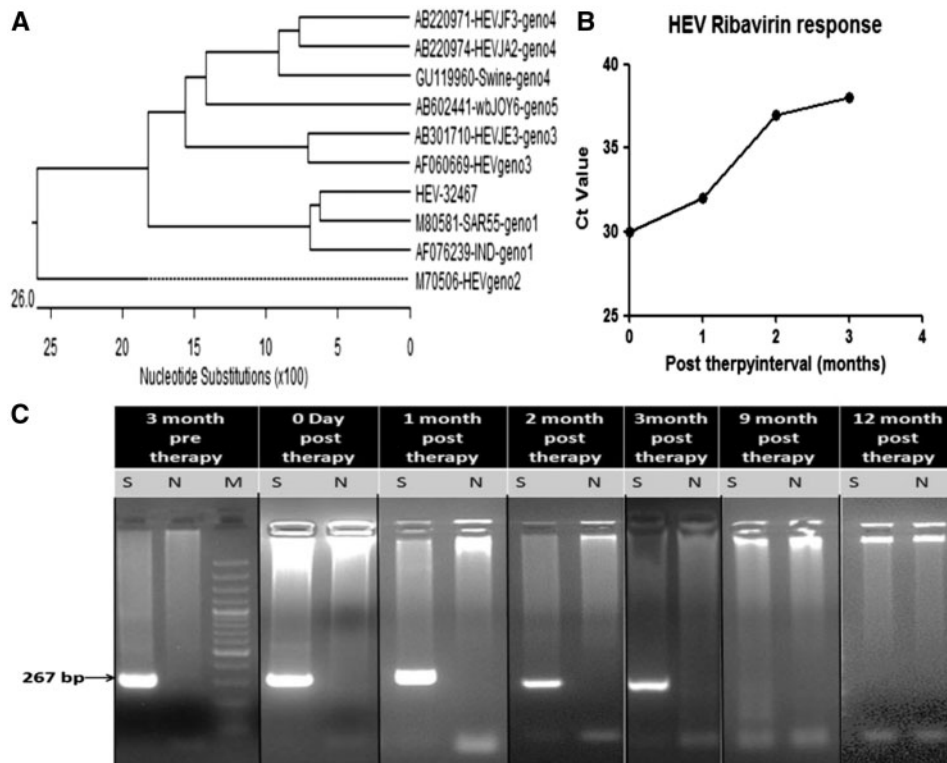
## Discussion

Our patient had persistent transaminitis, positive anti-HEV IgM antibodies and HEV RNA, possibly for a long time, with a background of acute leukaemia. He was subsequently diagnosed as having underlying cirrhosis; aetiological work-up for all other known aetiologies of cirrhosis was found to be negative. The persistence of anti-HEV IgM antibodies made us clinically suspicious of underlying chronic HEV infection. The patient may have acquired HEV infection during treatment of ALL, which was not recognized as HEV is self-limiting in the majority of cases [1]. The patient also received multiple blood product transfusions during ALL treatment, which may have also increased the risk of HEV infection in an endemic country such as India.

HEV epidemics in tropical countries are generally caused by genotype 1 due to fecal-oral transmission. Sporadic cases in developed countries are mostly due to HEV genotype 3 infection, possibly of zoonotic origin. In this case, the patient was infected with HEV genotype 1. Most cases of chronic HEV infection have been reported to occur in patients on immunosuppressive therapy. Concerns have been raised about persistent HEV infection, primarily due to blood transfusion, which can lead to chronic liver disease in patients receiving multiple blood transfusions. Matubayashi *et al.* in 2004 reported the first case of transfusion-transmitted HEV infection [3]. Persistent immune suppression in patients may interfere with host immune response to HEV, further leading to chronic infection. The period of immunosuppression is prolonged after chemotherapy, which may help in establishing chronicity of HEV. Our patient was also positive for anti-HEV IgM for 1 year prior to detection of HEV RNA, indicating chronic HEV infection [4]. HEV RNA is normally detectable by PCR in patient sera for 14–28 days post infection. Prolonged excretion of HEV and prolonged clinical course have been



**Figure 2.** A) Low power photomicrograph of the transjugular liver biopsy shows distorted lobular architecture with fibrous septae and interface hepatitis (arrow) (haematoxylin-eosin staining, x 40). B) The hepatocytes on high power examination show diffuse ballooning (arrows). No cholestasis or cytoplasmic inclusion bodies are seen (haematoxylin-eosin staining, 200). C) Masson's trichrome stain shows regenerative hepatic nodules surrounded by fibrous septae (arrows) (Masson's trichrome stain, x 40). D) Dense lymphocytic cell infiltrate is identified within the fibrous septae (arrows) (Masson's trichrome stain, x 100).



**Figure 3.** A) Phylogenetic analysis of PCR amplicon (HEV-32467) sequence with HEV reference sequence (genotype 1, 2, 3, 4 and 5) showed clustering genotype 1 sequence, indicating it as HEV genotype 1. B) Real-time PCR of HEV RNA isolated at months 0, 1, 2 and 3 post-ribavirin therapy indicates decline in HEV RNA titre (HEV RNA titre is inversely proportional to Ct value). C) Qualitative detection of HEV RNA by nested PCR. M-100 bp ladder, N-Negative control and S- patient sample. HEV RNA was detectable 3 months pre-therapy to 3 months post therapy, and HEV RNA became undetectable at 9 and 12 months post therapy.

reported in haematological malignancies, but chronicity leading to cirrhosis has been seen in transplant recipients [5]. Immunity acquired from natural infection protects against subsequent HEV infections [6]. Most of the causes of non-A, non-B hepatitis remain undiagnosed.

Management of hepatitis E is mainly symptomatic in immunocompetent patients who are able to clear virus effectively. In immunosuppressed patients, virus clearance may be affected, and it is desirable to reduce immunosuppressive drugs. Reduction in immune suppression in patients is reported to reduce viral load by 30% [7]. In scenarios in which reduction in immunosuppression doesn't work, ribavirin monotherapy (600–1000 mg/d) for 3 months has been considered as the first-line drug for chronic hepatitis E [8]. Recombinant vaccine is available for hepatitis E but is not available globally. Studies have shown vaccine efficacy of 95% against HEV genotype 1 [9]. Ribavirin is considered effective in eradicating chronic HEV genotype 3 infections. There are reports of efficacy of ribavirin in acute on chronic liver failure caused by HEV genotype 1 [7,10]. Preventive measures against hepatitis E cannot be overemphasized, and improvement in sanitation and availability of clean drinking water will go a long way in reducing the prevalence of hepatitis E in hyperendemic areas.

In conclusion, HEV infection has far different implications in immunocompromised hosts. Ribavirin is an effective therapy, not only for controlling HEV but also for improving HEV-induced cirrhosis.

### Author contributions

AS, RS, AG, S, BN, SKA were involved in the patient's care, implementation and interpretation of data and writing of the manuscript. PD was involved in study design, implementation and writing of the manuscript. S will act as guarantor for this paper.

Conflicts of interest statement: none declared.

### REFERENCES

1. Rein DB, Stevens GA, Theaker J, et al. The global burden of hepatitis E virus genotypes 1 and 2 in 2005. *Hepatology* 2012;**55**:988–97.
2. Hoerning A, Hegen B, Wingen AM, et al. Prevalence of hepatitis E virus infection in pediatric solid organ transplant recipients—a single-center experience. *Pediatr Transplant* 2012;**16**:742–7.
3. Matubayashi K, Nagaoka Y, Sakata H, et al. Transfusion-transmitted hepatitis E caused by apparently indigenous hepatitis E virus strain in Hokkaido, Japan. *Transfusion* 2004;**44**:934–40.
4. Fujiwara S, Yokokawa Y, Morino K, et al. Chronic hepatitis E: a review of the literature. *J Viral Hepat* 2014;**21**:78–89.
5. Péron JM, Mansuy JM, Récher C, et al. Prolonged hepatitis E in an immunocompromised patient. *J Gastroenterol Hepatol* 2006;**21**:1223–4.
6. Zhang J, Zhang XF, Zhou C, et al. Protection against hepatitis E virus infection by naturally acquired and vaccine-induced immunity. *Clin Microbiol Infect* 2014;**20**:O397–405.
7. Kamar N, Rostaing L, Abravanel F, et al. Ribavirin therapy inhibits viral replication on patients with chronic hepatitis e virus infection. *Gastroenterology* 2010;**139**:1612–8.
8. Wedemeyer H, Pischke S, Manns MP. Pathogenesis and treatment of hepatitis E virus Infection. *Gastroenterology* 2012;**142**:1388–97.e1.
9. Shrestha MP, Scott RM, Joshi DM, et al. Safety and efficacy of a recombinant hepatitis E vaccine. *N Engl J Med* 2007;**356**:895–903.
10. Goyal R, Kumar A, Panda SK, et al. Ribavirin therapy for hepatitis E virus-induced acute on chronic liver failure: a preliminary report. *Antivir Ther* 2012;**17**:1091–6.