

## CASE REPORT

### Familial florid Cemento-osseous dysplasia – case report and review of literature

Amit Thorawat<sup>1</sup>, Chaitra Kalkur<sup>2</sup>, Venkatesh G. Naikmasur<sup>3</sup> & Bassel Tarakji<sup>1</sup>

<sup>1</sup>Department of Oral and Maxillofacial Sciences, Al-Farabi Colleges, Riyadh 11691, Saudi Arabia

<sup>2</sup>Department of Oral Medicine and Radiology, Century International Institute of Dental Sciences and Research Centre, Kasaragod, Kerala, India

<sup>3</sup>Department of Oral Medicine and Radiology, Shri Dharmasthala Manjunatheshwara Dental College, Dharwad 580009, Karnataka, India

#### Correspondence

Amit Thorawat, Department of Oral and Maxillofacial Sciences, Al-Farabi Colleges, Riyadh 11691, Saudi Arabia.  
Tel: +966 591004469;  
E-mail: amitnaisa@gmail.com

#### Funding Information

No sources of funding were declared for this study.

Received: 9 May 2015; Revised: 20 August 2015; Accepted: 18 September 2015

*Clinical Case Reports* 2015; 3(12): 1034–1037

doi: 10.1002/ccr3.426

## Introduction

Familial florid cemento-osseous dysplasia is a very uncommon condition. The term florid osseous dysplasia was coined in 1976 by Melrose et al. [1]. Till today, nearly 2% cases have been reported in the Indians according to current literature [2]. Focal cemento-osseous dysplasia was coined by Summerlin and Tomich in 1994 based on site of occurrence of the cemento-osseous dysplasia in the oral cavity [3].

Wood and Goaz prefer to use the term “diffuse cementosis” [4]. Bhaskar and Cutright (1968) summarized the characteristics of this disorder as follows: (1) The lesions are restricted to the jaw bones, (2) The vast majority of the individuals are above 30 years of age, (3) Predominantly seen in black women, (4) Mandibular involvement is much more common than maxillary involvement [4].

This article enlightens a family in which mother and daughter showed clinical characteristics, imaging findings, and histopathological sections of florid cemento-osseous dysplasia.

## Key Clinical Message

Familial Florid cemento-osseous dysplasia is a very uncommon condition. Cemento-osseous dysplasia is totally asymptomatic in many cases, in those conditions, lesions are detected in a radiograph taken for other purposes. In this report, we describe a family in which mother and daughter exhibited clinical, radiographic, and histologic features of florid cemento-osseous dysplasia.

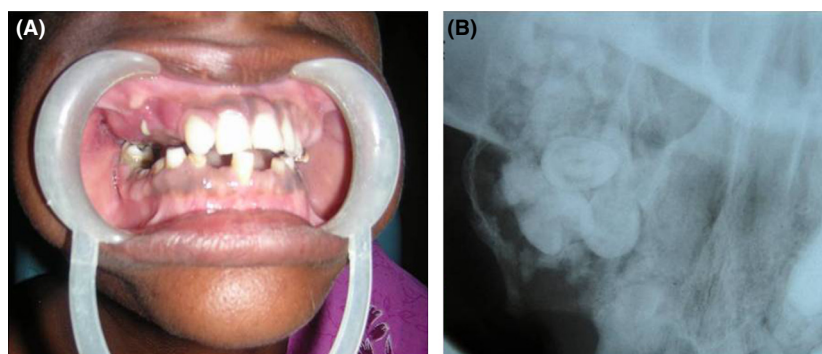
## Keywords

Cemento-osseous dysplasia, familial, fibro-osseous lesion, sclerosing osteitis.

## Case Report

### Case 1

A female patient aged 24 years reported to our department with a complaint of pain and swelling in the right maxillary posterior region of the jaw, since a year. One year back, she noticed a swelling associated with pain, which was intermittent, throbbing in character, and with no aggravating factors. On clinical examination, bilateral submandibular lymphnodes were palpable and non-tender. Diffused extraoral swelling was present on the right middle-third of the face extending superiorly from the infraorbital region to inferiorly up to the line joining the angle of the mouth to the tragus of the ear, and anteriorly from the ala of the nose to posteriorly till 3 cm in front of the right tragus of the ear has been edited for sense. Please check and approve.. Intraorally, bilateral maxillary arch expansion along with pus discharge in relation to 15, 16 regions was found and noticeable expansion of mandibular arch was seen (Fig. 1A and B).



**Figure 1.** (A) Clinical appearance of Maxillary arch with bony expansion and pus discharge i.r.t. 15, 16 region. (B) Cropped Maxillary Occlusal radiograph of the patient showing the large, numerous, irregularly shaped, sclerotic radiopacities admixed with diffuse ill-defined, radiolucent-radiopaque areas along with multiple impacted teeth. Corticle expansion can be seen.

## Case 2

A woman aged 45 years reported to our department with a complaint of decayed teeth in the left mandibular posterior region of the jaw. No associated symptoms were noticed. On examination, extraorally, no abnormality was detected. On inspection, intraorally, adequate mouth opening was seen, bilateral expansion of the maxillary arch and noticeable expansion of mandibular arch was present.

Orthopantomograph revealed multiple radiopaque masses with radiolucent borders found in both quadrants of the lower jaw. Thin radiolucent lesions were seen with most of the sclerotic areas confined within the alveolus and epicenter of the lesions are above the inferior alveolar nerve canal (Fig. 2A and B).

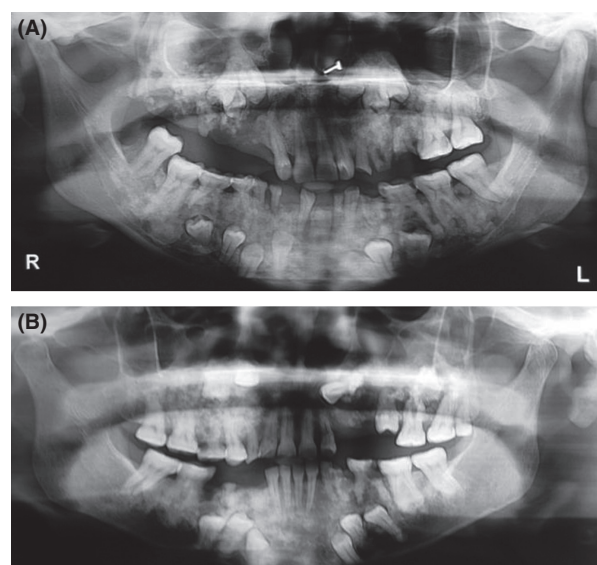
Bone and soft biopsy were performed in first case as the patient was symptomatic. Histopathological sections revealed large mass of sclerotic bone, which was hypocellular with resting and reversal lines were evident. Marrow space areas of variable sizes were seen. Sections from soft tissue showed fibrous to fibrocellular stroma with dilated blood vessel and chronic inflammatory cell infiltration. Overlying epithelium was parakeratinized stratified squamous epithelium suggestive of cemento-osseous dysplasia (Fig. 3).

Blood chemistry of calcium, phosphorus, and alkaline phosphatase was carried out for both the individuals, and was within normal limits.

In our case, broad spectrum antibiotics along with periodic recall was advised. Only periodic follow-up and good oral care were advised in asymptomatic case (Case 2).

## Discussion

Even though the familial form of florid osseous dysplasia is rare, it was reported in several literatures. In 1982,



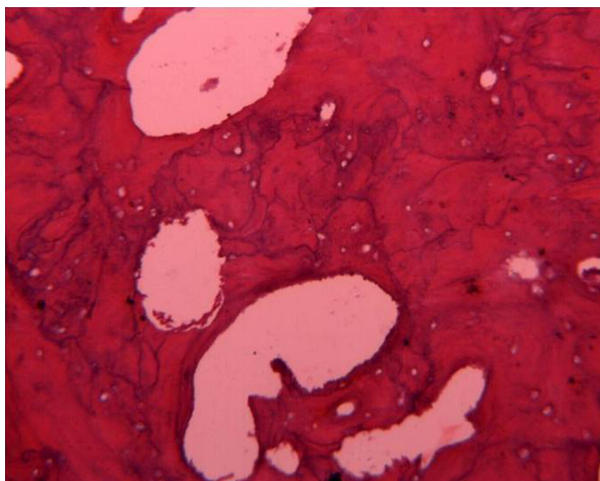
**Figure 2.** Panoramic Radiographs showing multiple radio opaque lesions seen in the periapical regions of the mandible. In both the cases, epicenter of the lesion is above the inferior alveolar canal [Case 1 (above) and 2 (below)].

Sedano et al. described cemental dysplasia occurring in 10 members of the same family under the term of “autosomal dominant cemental dysplasia.”

Among Caribbean individuals, in 1989, Thakkar et al. described a case of familial periapical cemental dysplasia. In 1991, among a white family, Oikarinen et al. diagnosed as gigantiform cementoma in three members (father, son, and daughter) [1].

In 2008, Moshref and his co-authors specified florid cemento-osseous dysplasia as the dysplastic lesion associated with osteogenesis imperfecta in one family pedigree literature [2].

Our both cases (daughter and mother) had similar clinical and radiographic features. Biopsy was done in



**Figure 3.** Photomicrograph showing large sclerotic mass of bone and cementum-like material in the fibrous connective tissue.

first case because of symptomatic condition. Other members of the same family were normal.

In a systematic review of the literature, it was found that 59% of cemento-osseous dysplasia cases arise in African patients, 37% in Asians, and 3% in Caucasians [5]. Black and Asian women are most commonly affected than men. Most common in the fourth decade of life, but the age range is broad [6]. Loh and Yeo in oriental individuals, diagnosed nine cases over a 34-year period. Among them, eight were middle-aged Chinese-based women and the other was an Indian woman [7].

In our case, we diagnosed based on the patient's age, gender, clinical findings, localization of lesions, and radiological features as well as ethnicity. Clinically, in most cases, affected patients are asymptomatic, and the disease is detected only on routine dental radiographs. However, occasional patients may have dull, intermittent, poorly localized pain, especially in lesions that are infected secondarily [1, 8]. This condition is not affected with abnormalities elsewhere in the skeleton and there are no disturbances in the blood chemistry.

Radiologic findings of florid cemento-osseous dysplasia (FCOD) depends on the degree of maturation of the lesion. Radiographs often demonstrate numerous, irregularly shaped, sclerotic radiopacities admixed with diffuse ill-defined, radiolucent–radiopaque areas. In mature cases, lesions appear as completely radiopaque with radiolucent periphery and surrounded by sclerotic borders same as PCD (Periapical cemental dysplasia). FCOD affects both jaws bilaterally, mainly mandibular posterior region and occurs above the inferior alveolar nerve canal [2, 9, 10]. Few reports commented on the presence or absence of jaw expansion. Yonestu and Nakamura reported mild

bony expansion based on occlusal radiographs or axial Computed Tomography images [11].

Osseous dysplasia (OD) considered to be originated from the periodontal ligament space and plays an important role in the formation of cementum by regulating the differentiation of PDL stem cells [12, 13].

All types of OD consist of fibrous cellular tissue, both woven as well as lamellar bone and masses of cementum-like material and no capsule. Hard tissue component in most cases does not fuse with the root surface of the involved teeth, but may merge with the surrounding bone [14].

Florid cemento-osseous dysplasia may also be confused with fibrous dysplasia. However, the variation in appearances of mineralized material distinguishes both lesions. Fibrous dysplasia almost exclusively consisting of woven bone [14].

The histopathologic features that help to distinguish FCOD and cemento-ossifying fibroma are that FCOD demonstrates multiple fragments without a fibrous capsule, thick curvilinear bony trabeculae, irregular cementoid masses, loose collagen fibers, and free hemorrhage throughout the lesion. In contrast, cemento-ossifying fibroma showed a single large, intact specimen with a fibrous capsule, ovoid cementoid deposits, dense collagen fibers, and free hemorrhage at its border [15].

Paget's disease affects the whole mandibular region and shows loss of lamina dura, whereas epicenter of florid cemento-osseous dysplasia is above mandibular canal. Paget's disease involves multiple bones such as spine, femur, skull, pelvis, and sternum with abnormal biochemical serum changes, such as increased alkaline phosphatase levels, but FCOD shows no other bony changes, or dermatological neoplasms or tooth malformations [16].

Therapeutic interventions are not entitled for cemento-osseous dysplasias unless complications such as bone infections or deformity of face are seen [14]. In case of secondary infection, antibiotics are ineffective in dysplastic bone. Sequestrectomy of the infected cemental/osseous structures combined with antibiotics are given in complicated cases [7, 17].

In our case, broad-spectrum antibiotics along with periodic recall was advised. Only periodic follow-up and good oral care were advised in asymptomatic case.

## Conclusion

Florid cemento-osseous dysplasia is a benign, nonneoplastic, self-limiting disease. Minimal number of cases have been reported in the current literature. FCOD presents with no symptoms and found incidentally on radiographs. Conservative approaches such as broad-spectrum antibiotics in case of infections along with periodic follow-up

are required. In asymptomatic individuals, only periodic follow-up and good oral care are advised. Surgical intervention of involved bone is required only for cosmetic concerned individuals.

## Conflict of Interest

None declared.

## References

1. Toffanin, A., R. Benetti, and R. Manconi. 2000. Familial florid osseous dysplasia. *J. Oral Maxillofac. Surg.* 58:1440–1446.
2. Mangala, M., D. N. Ramesh, P. S. Surekha, and P. Santosh. 2006. Florid cemento-osseous dysplasia: review and report of two cases. *Indian J. Dent. Res.* 17:131.
3. Summerlin, D. J., and C. E. Tomich. 1994. Focal Cemento-osseous dysplasia. A clinicopathologic study of 221 cases. *Oral Surg. Oral Med. Oral Pathol.* 78:611–620.
4. Wood, N. K., and P. W. Goaz. 1989. Differential diagnosis of oral lesions, 3rd edn. St. Louis, CV Mosby. pp. 620–622.
5. MacDonald-Jankowski, D. S. 2003. Florid cemento-osseous dysplasia: a systematic review. *Dentomaxillofac. Radiol.* 32:141–149.
6. Melrose, R. J., A. M. Abrams, and B. G. Mills. 1976. Florid osseous dysplasia: a clinical-pathological study of thirty-four cases. *Oral Surg.* 41:62–82.
7. Loh, F., and J. Yeo. 1989. Florid osseous dysplasia in Orientals. *Oral Surg. Oral Med. Oral Pathol.* 68:748–753.
8. Alawi, F. 2001. Benign fibroosseous diseases of the maxillaofacial bones. A review and differential diagnosis. *Am. J. Clin. Pathol.* 118:S50–S70.
9. Kawai, T., H. Hiranuma, M. Kishino, A. Jikko, and M. Sakuda. 1999. Cemento-osseous dysplasia of the jaws in 54 Japanese patients: a radiographic study. *Oral Surg. Oral Med. Oral Pathol. Oral Endod.* 87:107–114.
10. Baden, E., and S. A. Saroff. 1987. Periapical cemental dysplasia and periodontal disease. A case report with review of the literature. *J. Periodontol.* 58:187–191.
11. Yonestu, K., and T. Nakamura. 2001. CT of calcifying jaw bone diseases. *AJR Am. J. Roentgenol.* 177:937–943.
12. Sonayama, W., B. M. Seo, T. Yamaza, and S. Shi. 2007. Human hertwig's epithelial root sheath cells play crucial roles in cementum formation. *J. Dent. Res.* 86:594–599.
13. Hammarstrom, L., I. Alatli, and C. D. Fong. 1996. Origins of cementum. *Oral Dis.* 2:63–69.
14. Barnes, L., J. W. Eveson, P. Reichart, and D. Sidransky (eds.). 2005. World Health Organization classification of tumors. Pathology and genetics of head and neck tumors. IARC Press, Lyon. p. 323.
15. Su, L., D. R. Weathers, and C. A. Waldron. 1997. Distinguishing features of focal cemento-osseous dysplasia and cemento-ossifying fibromas: I. A pathologic spectrum of 316 cases. *Oral Surg. Oral Med. Oral Pathol. Oral Radiol. Endod.* 84:301–309.
16. Saadettin, T., G. Ümmühan, C. Mustafa, and Çakur. Binali. 2007. Florid cemento-osseous dysplasia: a case report. *Med. Oral Pathol. Oral Cir. Bucal.* 12:E348–E350.
17. Beyouni, I., P. Farge, J. F. Mazoyer, and J. L. Coudert. 1998. Florid cemento-osseous dysplasia: report of a case documented with computed tomography and 3D imaging. *Oral Surg. Oral Med. Oral Pathol. Oral Radiol. Endod.* 85:707–711.