

Case report

Extensive cerebral venous sinus thrombosis: a potential complication in a patient with COVID-19 disease

Paul Bolaji, Babatunde Kukoyi, Nasar Ahmad, Chris Wharton

Stroke Medicine, New Cross Hospital, Wolverhampton, UK

Correspondence to
Dr Paul Bolaji;
paul.bolaji@nhs.net

Accepted 16 July 2020

SUMMARY

A 63-year-old man was admitted with left-sided weakness and subsequent focal seizures following a recent diagnosis of Severe acute respiratory syndrome coronavirus 2 (SARS-CoV-2) pneumonia in a nearby hospital. He developed status epilepticus and became comatose, requiring intensive care unit admission for invasive ventilation. Imaging done at admission confirmed extensive cerebral venous sinus thrombosis (CVST) with bilateral venous cortical infarcts and acute cortical haemorrhage. No known risk factor for CVST could be identified. He improved with anticoagulation and antiepileptic therapy. He was subsequently transferred to an inpatient rehabilitation facility. Although Coronavirus disease 19 (COVID-19) infection has been previously associated with thrombotic complications, these mostly relate to the pulmonary vasculature. We present this case as a potential association between CVST and COVID-19 infection.

improved clinically and was discharged home after a 2 day admission, to self-isolate for 14 days.

He had a medical history of well-controlled diabetes and asthma. He was a non-smoker and never drank alcohol. There was no previous history of venous thromboembolism, stroke or heart disease. He had no history suggestive of malignancy and no significant family history of venous thromboembolism or stroke.

On arrival at the ED, the patient was clinically euvolaemic. There were no signs of deep venous thrombosis. Glasgow Coma Scale was 15/15 and he was observed to have a brief period of left-sided facial twitching. He had expressive and receptive dysphasia but normal ocular movements, visual fields and facial symmetry. He had dense left-sided hemiplegia, left-sided sensory inattention and extensor plantar response on the left. Despite a diagnosis of COVID-19 pneumonia, there were no signs of respiratory distress and peripheral oxygen saturations were normal in room air.

BACKGROUND

COVID-19 disease is a worldwide pandemic that has affected over 8 million people globally as of 18 June 2020. Severe disease is associated mainly with pneumonia, but several non-respiratory complications have been observed in case series and reports.

COVID-19 disease has been associated with ischaemic stroke, seizures and encephalopathy.¹ However there are very few reports of COVID-19 associated cerebral venous sinus thrombosis (CVST) in the published literature.

CVST is a rare disease. There are several known genetic and acquired risk factors for CVST. CVST has a good prognosis when treated promptly but can be fatal when not treated.²

CASE PRESENTATION

A 63-year-old previously fit and well man presented to the emergency department (ED) at our institution after waking up with left-sided weakness and inability to stand. There was no preceding history of headache or visual disturbances.

He had initially presented to a nearby hospital 2 days prior with a week history of fever, shortness of breath and dry cough. He was subsequently diagnosed with mild COVID-19 pneumonia based on chest x-ray findings and a positive SARS-CoV-2 nasopharyngeal swab. He was treated empirically with clarithromycin for possible superimposed bacterial pneumonia. He

INVESTIGATIONS

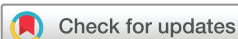The patient had brain imaging with plain CT and CT venogram (figures 1 and 2, respectively) at admission that revealed extensive venous sinus thrombosis with bilateral venous cortical infarcts and acute cortical haemorrhage.

D-dimers were significantly elevated. Protein C, S and antithrombin III levels were reported as normal. Factor V Leiden mutation was negative. Lupus anticoagulant was moderately positive, however, anticardiolipin IgG antibodies were within the normal range. The antinuclear antibody was negative (table 1). Alanine transaminase was initially elevated at admission (table 1). However, it normalised before discharge. Other components of the liver function tests, electrolytes, urea and creatinine were within normal limits.

He was rescreened for COVID-19 infection in our hospital and the SARS-CoV-2 virus was detected from nasopharyngeal swab sampling. Repeat chest X-ray at admission showed patchy bilateral ground-glass consolidation consistent with COVID-19 pneumonia. Chest X-ray, routine blood tests and other clinical findings were not suggestive of malignancy.

TREATMENT

Therapeutic doses of low-molecular-weight heparin and levetiracetam were commenced at admission.



© BMJ Publishing Group Limited 2020. No commercial re-use. See rights and permissions. Published by BMJ.

To cite: Bolaji P, Kukoyi B, Ahmad N, et al. *BMJ Case Rep* 2020;**13**:e236820. doi:10.1136/bcr-2020-236820

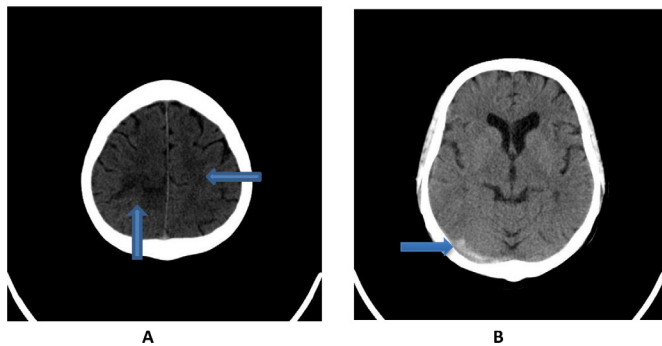


Figure 1 Plain CT brain images. (A) Low density seen within the right parietal lobe with further patchy low density within the posterior aspect of the left parietal lobe suspicious for recent infarct. (B) Hyperdensity of right transverse sinus suspicious of thrombus (this non-contrasted CT finding may be misinterpreted as haemorrhage).

A few hours later, he developed convulsive status epilepticus which was treated with intravenous lorazepam and intravenous phenytoin. He required intubation and was managed in the intensive care unit. He did not have any further seizure episodes and we were able to extubate him after 4 days. He was then transferred to the stroke unit for further management.

In the stroke unit, he was managed by a multidisciplinary stroke team with inpatient rehabilitation including speech and language therapy, physiotherapy and occupational therapy. He made steady improvement and low-molecular-weight heparin was continued for therapeutic anticoagulation. This was subsequently changed to edoxaban as advised by the haematologist while he was at the rehabilitation facility.

OUTCOME AND FOLLOW-UP

He was transferred to continue further inpatient treatment in a rehabilitation centre closer to his primary residence with a plan to continue anticoagulation for 6 months. His mobility and ability to perform activities of daily living improved and he was able to walk with a cane in the rehabilitation centre. He was discharged home from the rehabilitation centre about 3 weeks after his initial presentation in our hospital.

DISCUSSION

CVST is an uncommon condition.³ The annual incidence in studies ranges between 1.32 and 1.57 per 100 000.^{4,5} It is more common in the younger population and more prevalent in women than men.³ CVST can present broadly as three clinical syndromes: isolated intracranial hypertension (headache,

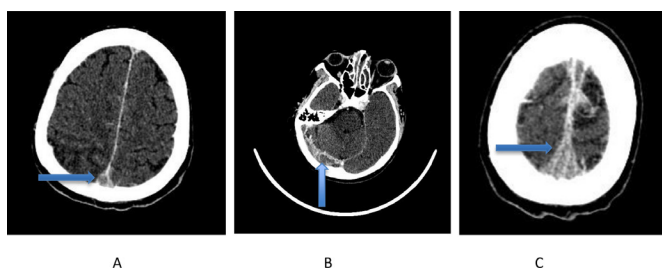


Figure 2 CT venogram images. (A) Empty delta sign suggestive of filling defect in the posterior part of the superior sagittal sinus post contrast administration. (B) Filling defect in the right transverse sinus and the right sigmoid sinus. (C) Filling defect involving the middle part of the superior sagittal sinus.

Table 1 Summary of blood tests requested during admission

Blood tests	Value	Reference range
Haemoglobin (g/L)	130	130–180
White cell count (x10 ⁹ /L)	8.0	4.0–11.0
Lymphocyte count (x10 ⁹ /L)	1.1	1.5–4.5
C-reactive protein (mg/dL)	60	0–5
ALT (IU/L)	91	<56
International normalised ratio	1.1	
Fibrinogen (g/L)	5.68	1.50–4.50
D-dimers (mg/L FEU)	4.77	0.15–0.45
Ferritin (ng/mL)	610.0	22–275
Protein S (IU/mL)	134	60–140
Protein C (IU/mL)	84	70–130
Antithrombin III (IU/mL)	116	80–120
Factor V Leiden mutation	Absent	
Prothrombin gene mutation (G20210A)	Absent	
Antinuclear antibody	Negative	
Lupus anticoagulant	Moderately present	
Anticardiolipin IgG (GPL)	4.1	0–10

ALT, alanine transaminase; IgG, immunoglobulin G.

papilloedema and visual problems), encephalopathy (mental status change, widespread neurological signs and coma) and focal syndrome (with seizures reported in 39.3%, paresis in 37.2% and aphasia in 19.1%).^{5–7} CVST can cause stroke due to focal cerebral infarction and haemorrhage that is seen on brain imaging in 46.5% and 39.3% of presentations, respectively.⁷ Urgent neuroimaging with cranial CT and CT venography or magnetic resonance venography are recommended for diagnosis, and initial treatment with heparin anticoagulation favoured (even in the presence of intracerebral haemorrhage), resulting in a good outcome for 80% and mortality of <5% in the Western world.⁸

The risk factors that predispose individuals to CVST are also seen in other forms of venous thromboembolism. Risk factors like oral contraceptive use, pregnancy and puerperium might explain the increased prevalence of CVST in women in comparison with men.² Genetic predisposition to thrombophilia might also be detected in people with CVST like protein C, S and antithrombin III deficiency, factor V Leiden and prothrombin G20210A gene mutations.⁹ Other risk factors are connective tissue disease, local infections of the head, neck and sinuses and malignancy especially in the older population.¹⁰ However, a study showed that in up to 12.5% of cases, no risk factor is identified.⁷ The absence of an established risk factor makes COVID-19 disease a strong potential aetiological factor for developing CVST in our patient presented in this case.

COVID-19 disease has multi-systemic manifestations, one of which includes a high prevalence of venous thromboembolism. In some case series, the incidence of venous thromboembolism ranged between 25% and 27% of patients with severe COVID-19 infection.^{11,12} This prothrombotic state is not only limited to severe COVID-19 disease. In a recent retrospective study conducted by Han *et al*,¹³ coagulation parameters like raised D-dimers, fibrin degradation products and high fibrinogen were found to be correlated with the severity of the COVID-19 infection. These coagulation parameters were also noted to be raised in milder infection compared with healthy controls.

The mechanism of this thrombophilic state in SARS-CoV-2 infection has not been fully elucidated. However, several putative mechanisms have been proposed. The cytokine storm in

severe inflammatory response syndrome seen in COVID-19 disease can induce a procoagulable state.^{14 15} It is also considered that SARS-CoV-2 could have some specific procoagulant effects independent of the cytokine storm, especially with its tropism for angiotensin converting enzyme 2 (ACE2) receptor that is present in the endothelium of blood vessels.¹⁵ A case series has also reported the association of COVID-19 disease with cerebral infarction and raised antiphospholipid antibodies, which was similarly noticed in the blood profile of our patient.¹⁶ Such a link between antiphospholipid antibodies and thrombotic complications of SARS-CoV-2 could also explain the prothrombotic state in COVID-19 disease, but transient rises in antiphospholipid antibodies in acute illness are known to cause false positives.¹⁷

There have been a few specifically reported cases of CVST and COVID-19 disease in literature apart from the more published associations with pulmonary embolism and deep venous thrombosis.^{1 18–22} Hughes *et al*¹⁸ initially reported CVST in a 59-year-old man who was COVID-19 positive. In a more recent case series of three patients, Calvacanti *et al*²² reported CVST in patients younger than 41 years of age with COVID-19 disease. However, these patients were not reported to have been screened for genetic thrombophilia, and one of them was on oestrogen replacement therapy. The extensive thrombophilia screening for conditions associated with CVST and their absence in our patient goes further to validate the association between COVID-19 and CVST in our patient.

It is plausible that cases could have been under-reported as clinicians may not have considered CVST as a cause of neurological symptoms in patients with COVID-19 disease. The neurological presentations of CVST are not specific to the condition. It is the presence of a known risk factor with either the insidious

presentation of significant headache or encephalopathy or with sudden onset seizure or stroke symptoms that often prompt more focused investigation for CVST. For primary care and ED professionals, these neurological symptoms may serve as a 'red flag' for requesting advanced neuroimaging beyond plain CT scans for patients with COVID-19 disease.

In conclusion, we suggest that clinicians consider the possibility of CVST in patients with neurological symptoms who test positive for SARS-CoV-2 to expedite prompt recognition and management of this condition.

Contributors PB: managed the patient, conceived the idea of the case report, was involved in planning, literature search and referencing for the case report, wrote the initial draft of the case report, revised the case report and approved the final draft of the case report; is the guarantor. BK: managed the patient, conceived the idea of the case report, was involved in planning the case report, wrote the initial draft of case report, took consent from the patient, revised the case report and approved the final draft of the case report. NA: managed the patient, was involved in planning the case report, revised, critically analysed the initial draft, did literature search and approved the final draft of the case report. CW managed the patient, was involved in planning the case report, revised, critically analysed the initial draft and approved the final draft of the case report.

Funding The authors have not declared a specific grant for this research from any funding agency in the public, commercial or not-for-profit sectors.

Competing interests None declared.

Patient consent for publication Obtained.

Provenance and peer review Not commissioned; externally peer reviewed.

This article is made freely available for use in accordance with BMJ's website terms and conditions for the duration of the covid-19 pandemic or until otherwise determined by BMJ. You may use, download and print the article for any lawful, non-commercial purpose (including text and data mining) provided that all copyright notices and trade marks are retained.

Patient perspective

Honestly, it all seemed like a blur to me. I do not remember being in ICU.

It was only 5 or 6 days later I realised where I was. It just started coming back to me a little bit at a time.

I think I have done quite well from where I was, my left side is a bit weak but it is all working, so I am glad about that.

The nurses said I have done well because I beat COVID-19 and more or less beat the stroke as well.

Learning points

- ▶ COVID-19 disease can present with thrombotic complications including cerebral venous sinus thrombosis (CVST).
- ▶ SARS-CoV-2 infection may cause CVST and other venous thromboembolism either through increased cytokine and clotting factors production or direct endothelial injury through binding to the ACE2 receptor.
- ▶ Neurological symptoms like headaches, seizures and focal neurological deficits in patients with COVID-19 disease should be considered as red flags for CVST.
- ▶ Clinicians should have a low threshold for requesting advanced neuroimaging beyond a plain CT scan to aid prompt diagnosis of CVST.
- ▶ CVST is associated with the good functional outcome despite the severity of neurological deficit if patient are treated early with anticoagulation and complications like status epilepticus are addressed.

REFERENCES

- 1 Mao L, Jin H, Wang M, *et al*. Neurologic manifestations of hospitalized patients with coronavirus disease 2019 in Wuhan, China. *JAMA Neurol* 2020;1127. doi:10.1001/jamaneurol.2020.1127. [Epub ahead of print: 10 Apr 2020].
- 2 Saposnik G, Barinagarrementeria F, Brown RD, *et al*. Diagnosis and management of cerebral venous thrombosis. *Stroke* 2011;42:1158–92.
- 3 Allroggen H, Abbott RJ. Cerebral venous sinus thrombosis. *Postgrad Med J* 2000;76:12–15.
- 4 Bousser M-G, Ferro JM. Cerebral venous thrombosis: an update. *Lancet Neurol* 2007;6:162–70.
- 5 Devasagayam S, Wyatt B, Leyden J, *et al*. Cerebral venous sinus thrombosis incidence is higher than previously thought. *Stroke* 2016;47:2180–2.
- 6 Biousse V, Ameri A, Bousser MG. Isolated intracranial hypertension as the only sign of cerebral venous thrombosis. *Neurology* 1999;53:1537.
- 7 Ferro José M., Canhão Patrícia, Stam J, Ferro J, Canhão P, *et al*. Prognosis of cerebral vein and dural sinus thrombosis. *Stroke* 2004;35:664–70.
- 8 Ferro J, Bousser M, Canhão P, *et al*. European stroke organization guideline for the diagnosis and treatment of cerebral venous thrombosis – endorsed by the European Academy of Neurology. *Eur J Neurol* 2017;2:195–221.
- 9 Deschens MA, Conard J, Horellou MH, *et al*. Coagulation studies, factor V Leiden, and anticardiolipin antibodies in 40 cases of cerebral venous thrombosis. *Stroke* 1996;27:1724–30.
- 10 Ameri A, Bousser MG. Cerebral venous thrombosis. *Neurol Clin* 1992;10:87–111.
- 11 Cui S, Chen S, Li X, *et al*. Prevalence of venous thromboembolism in patients with severe novel coronavirus pneumonia. *J Thromb Haemost* 2020;18:1421–4.
- 12 Klok FA, Kruij MJHA, van der Meer NJM, *et al*. Confirmation of the high cumulative incidence of thrombotic complications in critically ill ICU patients with COVID-19: an updated analysis. *Thromb Res* 2020;191:148–50.
- 13 Han H, Yang L, Liu R, *et al*. Prominent changes in blood coagulation of patients with SARS-CoV-2 infection. *Clin Chem Lab Med* 2020;58:1116–20.
- 14 Mehta P, McAuley DF, Brown M, *et al*. COVID-19: consider cytokine storm syndromes and immunosuppression. *Lancet* 2020;395:1033–4.
- 15 Connors JM, Levy JH. COVID-19 and its implications for thrombosis and anticoagulation. *Blood* 2020;135:2033–40.
- 16 Zhang Y, Xiao M, Zhang S, *et al*. Coagulopathy and antiphospholipid antibodies in patients with Covid-19. *N Engl J Med* 2020;382:e38.
- 17 Moore GW. Recent guidelines and recommendations for laboratory detection of lupus anticoagulants. *Semin Thromb Hemost* 2014;40:163–71.

- 18 Hughes C, Nichols T, Pike M, *et al.* Cerebral venous sinus thrombosis as a presentation of COVID-19. *Eur J Case Rep Intern Med* 2020;7:001691.
- 19 Garaci F, Di Giuliano F, Picchi E, Francesco G, Francesca D, Eliseo P, *et al.* Venous cerebral thrombosis in COVID-19 patient. *J Neurol Sci* 2020;414:116871.
- 20 Hemasian H, Ansari B. First case of Covid-19 presented with cerebral venous thrombosis: a rare and dreaded case. *Rev Neurol* 2020;176:521–3.
- 21 Poillon G, Obadia M, Perrin M, *et al.* Cerebral venous thrombosis associated with COVID-19 infection: causality or coincidence? *J Neuroradiol.* 2020. doi:10.1016/j.neurad.2020.05.003. [Epub ahead of print: 11 May 2020].
- 22 Cavalcanti DD, Raz E, Shapiro M, *et al.* Cerebral venous thrombosis associated with COVID-19. *AJNR Am J Neuroradiol* 2020. doi:10.3174/ajnr.A6644. [Epub ahead of print: 18 Jun 2020].

Copyright 2020 BMJ Publishing Group. All rights reserved. For permission to reuse any of this content visit <https://www.bmj.com/company/products-services/rights-and-licensing/permissions/>
BMJ Case Report Fellows may re-use this article for personal use and teaching without any further permission.

Become a Fellow of BMJ Case Reports today and you can:

- ▶ Submit as many cases as you like
- ▶ Enjoy fast sympathetic peer review and rapid publication of accepted articles
- ▶ Access all the published articles
- ▶ Re-use any of the published material for personal use and teaching without further permission

Customer Service

If you have any further queries about your subscription, please contact our customer services team on +44 (0) 207111 1105 or via email at support@bmj.com.

Visit casereports.bmj.com for more articles like this and to become a Fellow