

## Case Report

# Hyponatraemia caused by LGI1-associated limbic encephalitis

Rory F. McQuillan and Joanne M. Bargman

Division of Nephrology, University Health Network, Toronto, Canada

Correspondence and offprint requests to: Rory F. McQuillan; E-mail: Rory.mcquillan@uhn.on.ca

### Abstract

Limbic encephalitis (LE), once thought to be a rare paraneoplastic phenomenon, is increasingly diagnosed in patients without malignancy. Autoimmune LE has emerged as a distinct clinical entity. Autoantibodies to neuronal cell surface proteins have been described and may now be tested for. This has led to an exponential increase in the number of cases being reported. The most recently implicated autoantibody is to the leucine-rich anti-glioma 1 protein (LGI1). This protein is involved in synaptic transmission and inherited loss-of-function mutations cause autosomal dominant lateral temporal epilepsy. LGI1 is also expressed in specific tubules in the kidney. Anti-leucine-rich anti-glioma 1 protein (anti-LGI1) LE presents with sub acute onset of progressive neurological, cognitive and psychiatric disturbance. The condition is complicated in up to 60% of cases with severe and life threatening hyponatraemia. As well as causing significant morbidity, the co-existence of hyponatraemia may confuse the initial diagnosis. We present a case of anti-LGI1 which was complicated by hyponatraemia with a comprehensive review of the literature.

**Keywords:** hyponatraemia; limbic encephalitis; IVIG

### Case report

A 74-year-old woman first presented to another hospital 18 months previously with generalized tonic–clonic seizures in the setting of severe hyponatraemia. She had no significant medical history save for mild hypertension. She was not taking anti-hypertensive medication, following instead a low salt diet on the advice of her family doctor. Serum sodium on presentation was 117 mmol/L, and her seizures were attributed to hyponatraemia, which was in turn thought to be secondary to reduced salt intake. The patient was treated successfully with water restriction and increased salt intake. Her serum sodium concentration on discharge was 132 mmol/L. She had no further seizure activity during the admission. Magnetic resonance imaging (MRI) of the brain was normal. She was commenced on phenytoin in hospital which was continued after discharge.

Over the following weeks, she developed an unusual neurological syndrome characterized by involuntary jerking

of the upper limbs, lip smacking and falls. A clinical diagnosis of complex partial seizures was made. Initially, the dose of phenytoin was increased and subsequently levetiracetam and primidone were added. Despite this, the episodes became more frequent, occurring >20 times/day. They evolved to include involuntary shouting, periods of garbled speech and aphasia. She was re-admitted for further evaluation. Repeat cranial imaging was again unremarkable. Lumbar puncture was normal. During electroencephalography monitoring, she had numerous clinical episodes, though no electrical correlate was noted. This finding prompted a diagnosis of psychogenic ‘pseudoseizure’ and referral to a psychiatrist was made.

The patient continued to deteriorate. The involuntary movements continued, her affect became withdrawn and her cognitive ability rapidly declined. Her falls became more frequent and more severe necessitating numerous hospital visits. During this time, her serum sodium again decreased to 123–126 mmol/L.

She was referred to our centre for neurological opinion. Repeat MRI showed subtle increased signal intensity in the mesial temporal lobes bilaterally, raising the possibility of limbic encephalitis (LE). A thorough workup for latent malignancy was performed, including computed tomography imaging of the thorax, abdomen and pelvis, tumour markers and repeat lumbar puncture.

While routine analysis of the cerebrospinal fluid was again normal, fluid sent for autoantibody screening demonstrated the presence of anti-leucine-rich anti-glioma 1 protein (anti-LGI1) antibodies. In the absence of any evidence of malignancy, the patient was diagnosed with autoimmune encephalitis and started on intravenous immunoglobulin (IVIG) 1 g/kg.

Following the first IVIG infusion, serum sodium fell from 127 to 120 mmol/L. This was accompanied by an acute worsening of her neurological syndrome. Nephrology opinion was sought. The patient was clinically euvolaemic with pulse and blood pressure in the normal range. Serum osmolality was low at 260 mOsm/L and urine osmolality was inappropriately high at 554 mOsm/L. The picture was felt to be in keeping with chronic inappropriate anti-diuretic hormone (ADH) release due to LE exacerbated acutely by administration of the IVIG solution. As vasopressin inhibitors were not available, the patient was managed with fluid restriction and oral salt tablets and administration of the

remaining IVIG was deferred until sodium normalized. Serum sodium increased to 136 mmol/L, allowing for the remainder of the planned IVIG to be given in a more gradual fashion. The patient's neurological symptoms and hyponatraemia resolved with monthly IVIG for an initial 6 months followed by maintenance oral azathioprine.

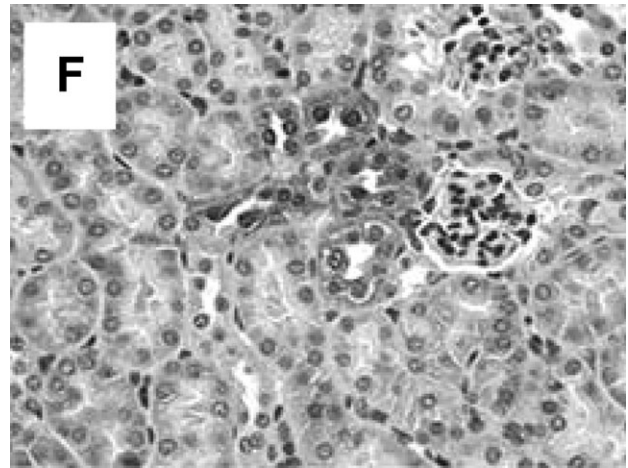
## Discussion

The limbic system comprises the amygdala, thalamus, hypothalamus and medial temporal lobes and is primarily responsible for modulating behaviour, governing emotions and control of neuro-endocrine functions. LE is a form of encephalitis involving this area of the brain. LE typically presents with behavioural disturbance, changes in personality and cognitive impairment and may often be misdiagnosed as a psychiatric disorder [1].

Classically, LE has been considered a paraneoplastic phenomenon, most frequently as a complication of small-cell lung cancers [2]. More recently, it has become apparent that LE may occur in the absence of malignancy. Autoimmune LE has emerged as a distinct clinical entity, and novel autoantibodies to neuronal cell surface proteins have now been described [3–5]. This has led to an exponential increase in the number of cases being reported. Antibodies against the *N*-methyl *D*-aspartate (NMDA) receptor [3], the glutamate 1 (GluR1) and GluR2 subunits of the  $\alpha$ -amino-3-hydroxy-5-methyl-4-isoxazolepropionic acid receptor [4] and against the B1 subunit of the gamma-aminobutyric acid B receptor [5] have all been described. The most recently implicated autoantibody is to the leucine-rich anti-glioma 1 protein (LGI1) [6]. This protein is involved in synaptic transmission and inherited loss-of-function mutations cause autosomal dominant lateral temporal epilepsy [7] and autosomal dominant partial epilepsy with auditory features [8]. Anti-LGI1 LE typically presents with movement disorder, personality change and seizure and is complicated by hyponatraemia, which may be severe in up to 60% of cases [6].

The exact cause of hyponatraemia is unclear. Certainly in the case described here, the patient behaved clinically and biochemically as if an excess of anti-diuretic hormone was present with low serum osmolality and inappropriately high urine osmolality, responding to fluid restriction and increased solute intake. Animal models have demonstrated that LGI1 is strongly expressed in the hypothalamus [9], which might support the theory that hyponatraemia is secondary to excess ADH release. However, LGI1 is also expressed in specific tubules of the kidney, which raises the possibility of a direct antibody effect on the renal tubules (Figure 1 [9]).

The term autoimmune LE may be misleading as a subsection of patients with these antibodies will go on to develop malignancies and must be screened regularly. This is especially important in young women with NMDA receptor-associated encephalitis where 50% of those aged  $\geq 18$  years will develop ovarian teratoma [10]. In males with the same condition, the discovery of a tumour is extremely rare. In those patients in whom malignancy cannot be demonstrated, the majority of cases are responsive to immunosuppression.



**Fig. 1.** Immunohistochemical analysis of the expression pattern of LGI1 in individual specific tubules in the kidney from the bacterial artificial chromosome transgenic mouse. Head et al. [9] reproduced with permission.

The most frequently used agent reported in the literature is IVIG [11].

In treating LGI1-associated LE, it is important to bear in mind that IVIG may itself cause hyponatraemia, which can lead to transient worsening of neurological symptoms, as observed in this case. IVIG is essentially an iso-osmolar fluid, which, when administered to a patient with a fixed high urine osmolality due to inappropriate ADH release, cannot readily be excreted. This effect leads to dilution of the serum osmolality and hyponatraemia. Pseudohyponatraemia due to expansion of the solid phase of the plasma by the high protein content of IVIG must be ruled out but will be associated with normal serum osmolality. In patients with renal failure receiving maltose-based IVIG suspensions, maltose may accumulate in the extra cellular fluid raising the serum osmolality and drawing water out of cells, leading to hyponatraemia. In patients with normal renal function, this does not occur because maltose is rapidly broken down to glucose in the proximal renal tubules and crosses freely into the peritubular capillaries. Glucose may then be taken up by cells and metabolized, such that the net effect of giving IV maltose is delivery of a hypotonic fluid.

## Conclusion

LE, once thought to be a rare paraneoplastic phenomenon is being diagnosed with increased frequency in patients without malignancy. Autoimmune LE should now be considered as part of the differential diagnosis in adults and children presenting with new onset of behavioural disturbance, personality change and cognitive decline, particularly if accompanied by seizure or movement disorder. The recently described anti-LGI1-associated LE is often associated with severe hyponatraemia. It should always be kept in mind that in a patient presenting with confusion and hyponatraemia, the confusion may not be secondary to hyponatraemia and that a unifying diagnosis may be present. LE should be considered in any patient with neurological disturbance and unexplained hyponatraemia. It is an important clinical point that IVIG while highly effective in treating

autoimmune LE may, at least transiently, worsen hyponatraemia and the neurological symptoms.

*Conflict of interest statement.* None declared.

## References

1. McCoy B, Akiyama T, Widjaja E *et al.* Autoimmune limbic encephalitis as an emerging pediatric condition: case report and review of the literature. *J Child Neurol* 2011; 26: 218–222
2. Gultekin SH, Rosenfeld MR, Voltz R *et al.* Paraneoplastic limbic encephalitis: neurological symptoms, immunological findings and tumor association in 50 patients. *Brain* 2000; 123: 1481–1494
3. Dalmau J, Gleichman AJ, Hughes EG *et al.* Anti-NMDA-receptor encephalitis: case series and analysis of the effects of antibodies. *Lancet Neurol* 2008; 7: 1091–1098
4. Lai M, Hughes EG, Peng X *et al.* AMPA receptor antibodies in limbic encephalitis alter synaptic receptor location. *Ann Neurol* 2009; 65: 424–434
5. Lancaster E, Lai M, Peng X *et al.* Antibodies to the GABA (B) receptor in limbic encephalitis with seizures: case series and characterization of the antigen. *Lancet Neurol* 2010; 9: 67–76
6. Lai M, Huijbers MG, Lancaster E *et al.* Investigation of LGI1 as the antigen in limbic encephalitis previously attributed to potassium channels: a case series. *Lancet Neurol* 2010; 9: 776–785
7. Morante-Redolat JM, Gorostidi-Pagola A, Piquer-Sirerol S *et al.* Mutations in the LGI1/Epitempin gene on 10q24 cause autosomal dominant lateral temporal epilepsy. *Hum Mol Genet* 2002; 11: 1119–1128
8. Kalachikov S, Evgrafov O, Ross B *et al.* Mutations in LGI1 cause autosomal-dominant partial epilepsy with auditory features. *Nat Genet* 2002; 30: 335–341
9. Head K, Gong S, Joseph S *et al.* Defining the expression pattern of the LGI1 gene in BAC transgenic mice. *Mamm Genome* 2007; 18: 328–337
10. Florance NR, Davis RL, Lam C *et al.* Anti-N-methyl-D-aspartate receptor (NMDAR) encephalitis in children and adolescents. *Ann Neurol* 2009; 66: 11
11. Vincent A, Buckley C, Schott JM *et al.* Potassium channel antibody-associated encephalopathy: a potentially immunotherapy-responsive form of limbic encephalitis. *Brain* 2004; 127 (Pt 3): 701

*Received for publication: 25.7.11; Accepted in revised form: 26.7.11*