

# Quadruple-negative RT-PCR assay for COVID-19, but clinically and radiologically COVID pneumonia with POTS: Case report and case-based review

SAGE Open Medical Case Reports  
Volume 9: 1–6  
© The Author(s) 2021  
Article reuse guidelines:  
sagepub.com/journals-permissions  
DOI: 10.1177/2050313X211066647  
journals.sagepub.com/home/sco



Nithya Rajendran<sup>1</sup> , Puteri Maisarah Rameli and Grace Collins

## Abstract

A 25-year-old woman with a background history of bronchial asthma and intellectual disability presented to hospital with progressively worsening dyspnoea. Despite testing negative four times for coronavirus disease infection by nasopharyngeal swab reverse-transcriptase polymerase chain reaction, her clinical symptoms of hypoxaemic respiratory failure and radiological findings on computed tomography pulmonary angiogram were consistent with coronavirus disease pneumonia. Although she made a quick recovery in the intensive care unit with a combination of empirical antibiotics, corticosteroids, high flow nasal oxygen, therapeutic anticoagulation and awake semi proning, her protracted hospital course due to persistent sinus tachycardia remained challenging. A diagnosis of potential postural orthostatic tachycardia syndrome was explored during the acute phase of illness following an active stand test and exclusion of other causes. She was treated with beta blockers as she failed to improve with non-pharmacological measures. We searched for similar cases by analysing the literature databases. Our case aims to stress the importance of recognising and treating patients with negative nasal reverse-transcriptase polymerase chain reaction swabs as coronavirus disease infection, especially if there is strong evidence of clinical and radiological findings where diagnosis is often under recognised in asthmatics with intellectual disability.

## Keywords

SARS-CoV-2, COVID-19, tachycardia, RT-PCR, negative nasal swab, POTS, bronchial asthma, steroids, pulmonary embolism, intellectual disability

Date received: 25 September 2021; accepted: 28 November 2021

## Introduction

Severe acute respiratory syndrome coronavirus 2 (SARS-CoV-2) affects all members of society. However, certain risk factors such as asthma and intellectual disability can enhance one's susceptibility to the condition, thereby increasing the risk of mortality.<sup>1,2</sup> A negative swab does not preclude a diagnosis, with one systematic review reporting false-negative rates between 2% and 29% on reverse-transcriptase polymerase chain reaction (RT-PCR) which became positive on consecutive testing.<sup>3</sup> There is limited data describing incidence of postural orthostatic tachycardia syndrome (POTS) in coronavirus disease (COVID-19) patients. Although it is not uncommon to have negative RT-PCR and still have the disease, we report a case on a patient with asthma and intellectual disability whose clinical, radiological and post

infection sequelae were consistent with COVID-19 infection despite four negative nasopharyngeal swabs.

## Case report

A 25-year-old woman with a background of bronchial asthma and intellectual disability presented with progressively worsening dyspnoea, preceded by a week of generally feeling unwell. Her general practitioner had initially treated her with

Department of General Internal Medicine, St. James's Hospital, Dublin, Ireland

### Corresponding Author:

Nithya Rajendran, Department of General Internal Medicine, St. James's Hospital, Dublin 8, Ireland.  
Email: NRajendran@stjames.ie



oral antibiotics for a presumed urinary tract infection; however, her symptoms worsened prompting a visit to the emergency department (ED). On assessment in ED, she was afebrile with low oxygen saturation 82% on room air, tachypnoeic at 38–40 cycles per minute and tachycardic at 130 beats per minute (bpm) with regular rhythm. Her saturations improved to 93% with 40% venturi 10 L/min of oxygen via face mask.

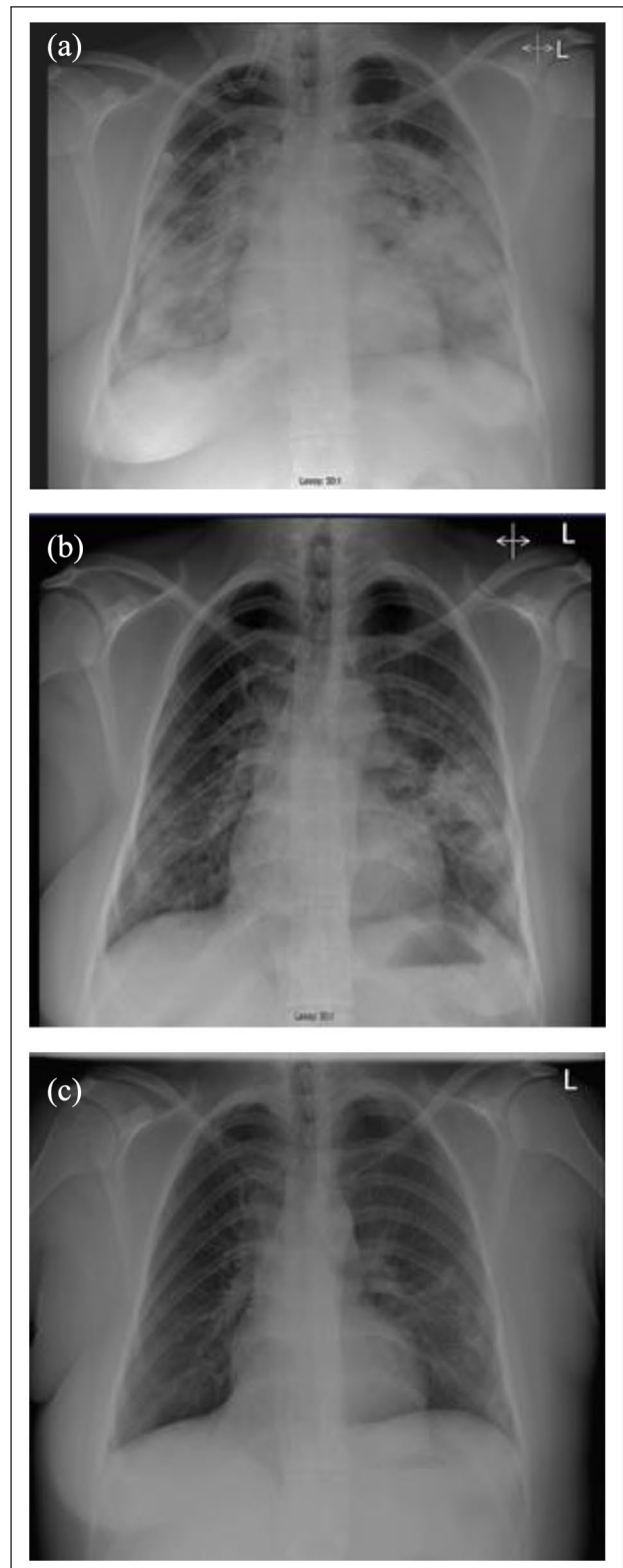
On auscultation, there was reduced air entry in the right lower zone with basal coarse crepitations in the left zone and expiratory wheeze. Arterial blood gas on 40% oxygen revealed mild alkalosis and an urgent chest X-ray (CXR) (Figure 1(a)) was performed. She was hospitalised with direct admission to intensive care unit (ICU), treated with intravenous hydrocortisone, empirical antibiotics including amoxicillin/clavulanic acid 1.2 g three times daily, clarithromycin 500 mg twice daily and salbutamol bronchodilators. Her saturations continued to drop to 83% despite 10 L of oxygen. Therefore, a decision was made to switch her to high flow nasal oxygen, where she maintained saturations of 93% at 40 L/min on fraction of inspired oxygen 65%–70% in ICU.

Laboratory results on admission showed haemoglobin, 12.8 g/dL; raised white cell count,  $16.8 \times 10^9/L$ ; neutrophilia,  $14.9 \times 10^9/L$ ; lymphocyte count,  $1.1 \times 10^9/L$ ; platelet count,  $391 \times 10^3/L$ ; and C-reactive protein, 128.29 mg/L. Interestingly, her RT-PCR nasal swab was negative on four consecutive occasions. D-Dimer was elevated to 6427 ng/mL (0–500 ng/mL) and interleukin-6 level raised at 20.17 pg/mL (0.09–7.26 pg/mL) (Table 1).

Her elevated D-Dimer, tachycardia and persistent oxygen requirements prompted a computed tomography pulmonary angiogram (CTPA) (Figure 2(a) and (b)) which confirmed pulmonary embolism (PE). Despite an ICU stay of 8 days, she never required intubation. Her treatment from admission was maintained until discharge to ward. A cardiologist's opinion was sought for her persistent sinus tachycardia, initially thought to be secondary to infection, PE and regular use of salbutamol bronchodilators. Transthoracic echocardiogram was unremarkable and revealed an overall normal left ventricular systolic function with ejection of 55%. Her telemetry over 72 h recorded sinus tachycardia with no evidence of ectopics or arrhythmias. Eventually, her oxygen requirements continued on a downward trajectory and a bronchoalveolar lavage was no longer deemed necessary given clinical improvements.

A possible diagnosis of POTS was explored in light of her persistent tachycardia, orthostatic intolerance (OI) and fatigue following exclusion of other causes (Table 1). An active stand test demonstrated increased heart rate by 38 bpm from supine after 10 min of standing on Day 4 (Figure 3). Initial non-pharmacological measures such as hydration and dietary modifications failed to control heart rate and a decision was made to trial her on bisoprolol 2.5 mg once daily.

At ward level, she was rehabilitated and gradually weaned off oxygen therapy. She was discharged on Day 30 of her



**Figure 1.** (a) CXR image shows diffuse bilateral airspace consolidation with sparing of the lung apices. (b) CXR image shows marked interval improvement in appearances of the left and right hemithorax with some residual infiltrates. (c) CXR image showing almost complete resolution of previous infiltrates.

**Table 1.** Laboratory investigations to rule out other causes for sinus tachycardia and atypical infection screen.

Laboratory test	Values	Normal range
TSH	0.75 mU/L	0.27–4.20 mU/L
Free T4	14.64 pmol/L	12.0–22.0 pmol/L
Ferritin	234 µg/L	23–393 µg/L
HBA1C	35	20–42
NT Pro BNP	423 ng/mL	<300 ng/mL normal; 300–450 unlikely acute heart failure; >450 ng/mL acute heart failure likely
25 OH Vitamin D	46 nmol/L	>50 nmol/L Normal; 30–50 nmol/L Insufficiency; <30 nmol/L Deficiency
CD 25	1606.38 pg/mL	101.8–2509.4 pg/mL
Connective tissue disease screen	0.10 ratio	0.0–0.69
Galactomannan index	0.2	>0.5
Beta D glucan	<8.0 pg/mL	>80 pg/mL
Legionella urinary antigen	Negative	
Pneumococcal urinary antigen	Negative	
Viral screen (cytomegalovirus, Epstein–Barr virus)	Negative	
Carbapenemase-producing Enterobacteriaceae (CPE)	Negative	
Methicillin-resistant <i>Staphylococcus aureus</i> (MRSA)	Negative	
Vancomycin-resistant Enterococcus (VRE)	Negative	

TSH: thyroid-stimulating hormone; NT: N terminal; BNP: B-type natriuretic peptide.

hospital stay on apixaban for 3 months duration and bisoprolol 3.75 mg once daily with follow-up organised for the COVID clinic. In the interim, she had one presentation to ED with complaints of right lower limb swelling, which was investigated and found to be negative for deep vein thrombosis in the lower extremity. Repeat CXR was performed at 8 weeks (Figure 1(b)) and 3 months (Figure 1(c)).

Repeat echocardiogram was booked and a decision was made to continue her beta blocker therapy and re-assess if symptoms changed. Virtual phone clinic 9 months post COVID-19 infection confirmed ongoing symptoms. The patient maintains on beta-blockers and her heart rate remains variable on exertion with complaints of fatigue as confirmed with her general practitioner. SARS-CoV-2 antibody testing following COVID-19 infection was not pursued as the patient's mother declined further appointments and investigations due to concerns of distress to the patient.

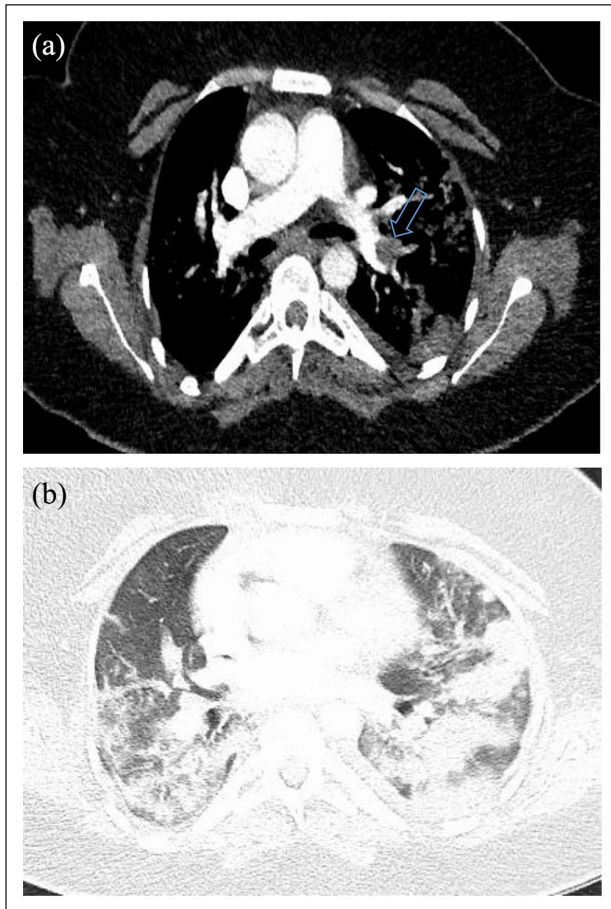
## Discussion

A special report on COVID-19 and older people with intellectual disability, launched in December 2020, provided great insight on the impact of the pandemic on this vulnerable population in Ireland. Among 62.4% adults tested for COVID-19, only 11 tested positive, confirming an overall infection rate of 2.5%. A total of 61 (8.6%) participants had a history of lung disease/asthma. The most common COVID-19-like symptoms reported by participants were fever (57.7%), cough (43.7%), fatigue (12.7%) and shortness of breath (9.9%). The report highlighted high rates of comorbid

health conditions which can lead to poorer outcomes for COVID-19, although no deaths were reported at the time.<sup>4</sup>

Failure to recognise symptoms in individuals with asthma and intellectual disability is not uncommon as evident from our case. There is a trivial overlap of non-specific symptoms and limited case references detailing asthma exacerbations as a result of COVID-19 infection. Different hypotheses including altered T1-type immunity, mucus hypersecretion reducing exposure to SARS-CoV-2 in the distal lung, different asthma phenotypes and adherence to asthma therapies such as inhaled corticosteroids allude to reduced COVID-19 symptoms and lower mortality risk.<sup>5</sup> In addition, there is paucity of literature exploring implications and outcomes of COVID-19 in patients with intellectual disabilities.

Multiple studies have reported negative nasal RT-PCR swabs due to sampling errors or as a result of collection of specimens from the upper respiratory tract.<sup>6–8</sup> The false-negative rate in our medical facility is between 1% and 2% and PCR results are interpreted with caution especially if clinical and radiological findings were suspicious for COVID-19 pneumonia. It is now not unusual to diagnose COVID-19 pneumonia on individuals testing negative on RT-PCR for the virus. As per Hase et al.,<sup>9</sup> a diagnosis of COVID-19 could be considered if the clinical and radiological evidence strongly point towards the infection, and bronchoalveolar lavage samples could be analysed for SARS-CoV-2 RNA virus, as lower respiratory tract specimens harbour the virus for a longer duration when compared to the upper respiratory tract. As per Lu et al.,<sup>10</sup> it is vital to understand that RT-PCR only detects samples with high RNA reactivity (viral load).



**Figure 2.** Axial view of CTPA: (a) pulmonary embolism in the left upper lobar pulmonary artery extending towards segmental and subsegmental branches. Further pulmonary embolism identified in the middle lobar pulmonary artery. (b) Widespread bilateral consolidation with sparing of the lung apices bilaterally likely representing COVID-19-related pneumonia.

Patients go on to have hypoxaemic respiratory failure secondary to inflammatory cytokines released by the virus, that is, cytokine storm.<sup>11</sup>

Diagnosis of dysautonomia syndrome such as POTS requires extensive clinical and diagnostic evaluation. POTS is a clinical syndrome defined by the presence of chronic symptoms. These include (1) OI, (2) heart rate of 120 bpm or an increase in heart rate by  $\geq 30$  bpm within 10 min of assuming an upright posture and (3) absence of orthostatic hypotension (a decrease in blood pressure  $> 20/10$  mmHg).<sup>12,13</sup> Some authors suggest POTS can be experienced weeks to months following triggers such as viral illness, that is, SARS-CoV as noted in our case.<sup>14,15</sup>

There are various pathophysiological mechanisms for developing OI in POTS. One mechanism broadly described is cardiovascular deconditioning following prolonged bed rest, resulting in cardiac atrophy, and subsequent physical

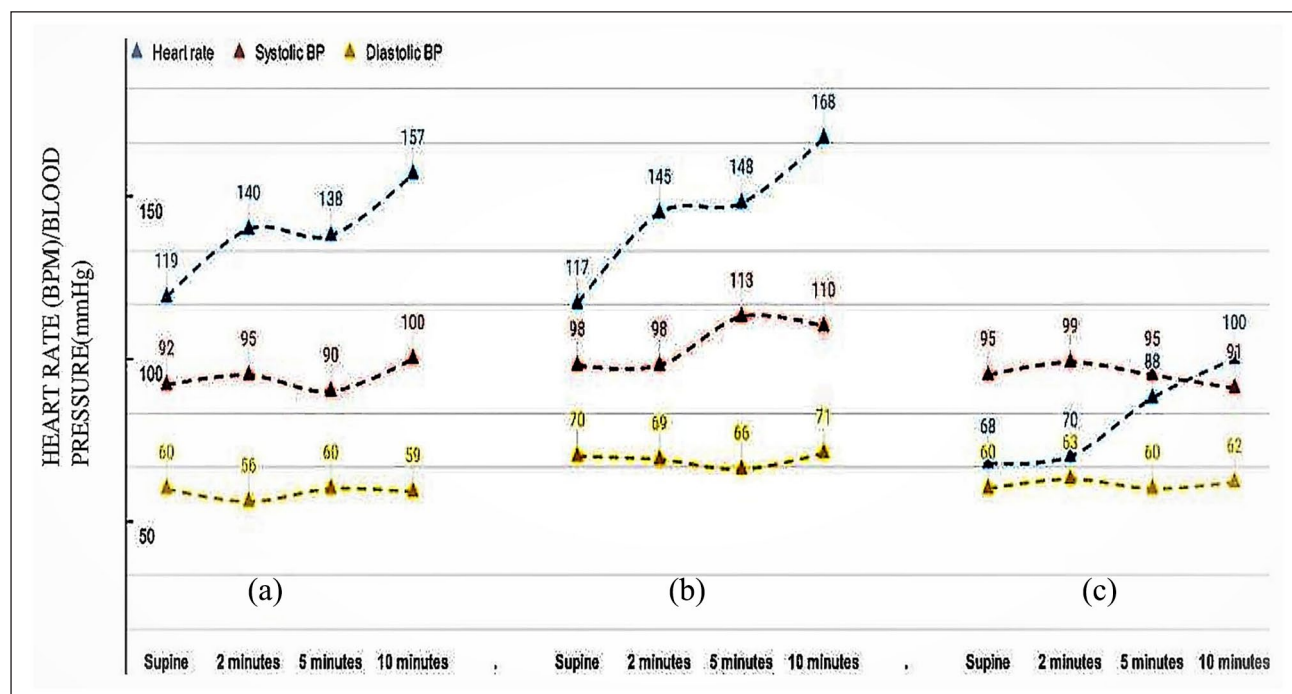
deconditioning. Reversibility is attainable with graduated physical activity which increases myocardial mass and cardiac output. Other mechanisms described include hyperadrenergic stimulation, autoimmunity, autonomic dysfunction, anxiety and hypovolaemia. The most morbid consequence of POTS universally is physical deconditioning secondary to OI. Engagement with structured exercise regimens, in which patients are encouraged to incorporate and continue indefinitely throughout their lifestyle, plays a vital role in the road to recovery.<sup>13,16</sup>

In our patient's case, merely sitting up from a supine position provoked a rise in heart rate by at least 26 bpm, which further increased to heart rate  $> 30$  bpm at 2, 5 and 10 min intervals of standing (Figure 3) with no significant orthostatic hypotension. It is highly plausible that she may have experienced an overlap between sinus tachycardia caused by provoked PE and POTS during the course of her illness. However, her post-viral recovery stand test necessitated further evaluation to exclude POTS. Following the absence of abnormal echocardiogram findings, thyroid dysfunction, vasculitis and rhythm disturbances, a possible diagnosis of POTS was established with a positive active stand test and 10-min walk test. In our case, the patient reconditioned by engaging with the physiotherapist on most days of her inpatient rehabilitation. We were unable to pursue the gold standard head-up tilt-table test due to the patient's noncompliance to proceed with further investigations or physiotherapy sessions in the outpatient setting.

Our case report describes a dilemma wherein the patient had four negative nasal RT-PCR but her clinical presentation and CTPA were consistent with COVID-19 pneumonia following exclusion of other differentials. Bronchoalveolar lavage samples were not required as she had shown improvement with treatment for COVID-19 infection. Furthermore, she also had PE triggered by SARS-CoV-2 infection as noted on CTPA and the postural constancy of tachycardia coupled with fatigue pointed towards POTS in the setting of post-viral infection.

## Conclusion

To our knowledge, we report the first case of a quadruple RT-PCR negative patient, with clinical and radiological positive findings consistent with COVID-19 pneumonia, who also suffered from post-viral dysautonomia, most likely POTS. Clinicians should always maintain a high level of suspicion in those with an intellectual disability or an underlying chronic respiratory condition like asthma. It is worth noting that POTS and sinus tachycardia are prevalent conditions post COVID-19 infection. This case report acknowledges the complexities in diagnosis and management of such overlapping cases in individuals with intellectual disability.



**Figure 3.** A line graph depicting HR increments and BP response on active stand testing: (a) Day 4 – during acute phase of illness; (b) Day 7 – trialed on Bisoprolol 2.5 mg post exclusion of other causes; and (c) 12-week follow-up – HR remained > 30 bpm on 10 min of standing despite up titration to Bisoprolol 3.75 mg. No postural drop in blood pressure was noted on all three occasions.

### Acknowledgements

We would like to thank the Physiotherapy Department of St. James's Hospital, Dublin.

### Author contributions

N.R. contributed to conceptualisation, data collection, data analysis, drafting, revising and final approval of manuscript. P.M.R. contributed to data collection, data analysis, drafting, revising and final approval of manuscript. G.C. contributed to data collection, data analysis, drafting, revising and final approval of manuscript.

### Data availability

All data are provided within this review and data within original published papers noted in this review.

### Declaration of conflicting interests

The author(s) declared no potential conflicts of interest with respect to the research, authorship and/or publication of this article.

### Ethical approval

No ethical approval was required due to sufficient anonymity of data.


### Funding

The author(s) received no financial support for the research, authorship and/or publication of this article.

### Informed consent

Patient has the decisional capacity to provide consent and a written informed consent was obtained from the patient and permission was sought from the patient's mother for the publication of this manuscript.

### ORCID iD

Nithya Rajendran  <https://orcid.org/0000-0002-0690-0005>

### References

- Landes SD, Turk MA, Formica MK, et al. COVID-19 outcomes among people with intellectual and developmental disability living in residential group homes in New York State. *Disabil Health J* 2020; 13(4): 100969.
- Liu S, Zhi Y and Ying S. COVID-19 and asthma: reflection during the pandemic. *Clin Rev Allergy Immunol* 2020; 59(1): 78–88.
- Warson J, Whiting PF and Brush JE. Interpreting a COVID-19 test result. *BMJ* 2020; 369: m1808.
- McCarron M. The impact of COVID-19 on people ageing with an intellectual disability in Ireland report launch 2020-IDS-TILDA: Trinity College Dublin, <https://idstilda.tcd.ie/wave4/launch.php>
- Lombardi C, Gani F, Berti A, et al. Asthma and COVID-19: a dangerous liaison? *Asthma Res Pract* 2021; 7(1): 9.
- Feng H, Liu Y, Lv M, et al. A case report of COVID-19 with false negative RT-PCR test: necessity of chest CT. *Jpn J Radiol* 2020; 38(5): 409–410.

7. Wiseman J, D'Amico TA, Zawadzka S, et al. False negative SARS-CoV-2 PCR: a case report and literature review. *Respir Med Case Rep* 2020; 31: 101140.
8. Chen LD, Li H, Ye Y-M, et al. A COVID-19 patient with multiple negative results for PCR assays outside Wuhan, China: a case report. *BMC Infect Dis* 2020; 20(1): 517.
9. Hase R, Kurita T, Muranaka E, et al. A case of imported COVID-19 diagnosed by PCR-positive lower respiratory specimen but with PCR-negative throat swabs. *Infect Dis* 2020; 52(6): 423–426.
10. Lu CY, Bai HL, Yuan Y, et al. The value of CT imaging for COVID-19 pneumonia: report of a false-negative nucleic acid test case. *J Thorac Dis* 2020; 12(5): 2827–2829.
11. Wang J, Jiang M, Chen X, et al. Cytokine storm and leukocyte changes in mild versus severe SARS-CoV-2 infection: review of 3939 COVID-19 patients in China and emerging pathogenesis and therapy concepts. *J Leukoc Biol* 2020; 108(1): 17–41.
12. Raj SR. The postural tachycardia syndrome (POTS): pathophysiology, diagnosis, and management. *Indian Pacing Electrophysiol J* 2006; 6: 84–99.
13. Johansson M, Ståhlberg M, Runold M, et al. Long-haul post-COVID-19 symptoms presenting as a variant of postural orthostatic tachycardia syndrome: the Swedish experience. *JACC Case Rep* 2021; 3(4): 573–580.
14. Kanjwal K, Jamal S, Kichloo A, et al. New-onset postural orthostatic tachycardia syndrome following coronavirus disease 2019 infection. *J Innov Card Rhythm Manag* 2020; 11(11): 4302–4304.
15. Grubb BP, Kanjwal Y and Kosinski DJ. The postural tachycardia syndrome: a concise guide to diagnosis and management. *J Cardiovasc Electrophysiol* 2006; 17(1): 108–112.
16. Bryarly M, Phillips LT, Fu Q, et al. Postural orthostatic tachycardia syndrome: JACC focus seminar. *J Am Coll Cardiol* 2019; 73(10): 1207–1228.