

Hungry bone disease in a pregnant woman with parathyroid adenoma

Sir,

Primary hyperparathyroidism (pHPT) is the third widespread endocrine disorder after diabetes and thyroid disease. The pathology signs are mostly atypical and therefore the diagnosis is done tardy, and the surgery is performed in symptomatic patients. The postoperative hypocalcemia might occur after full surgical removal of parathyroid tissue, long-term hypercalcemic, and suppression of nonadenomatous parathyroid glands. Alternatively, hypocalcemia is due to “hungry bone syndrome” (HBS) caused by massive calcium deposition in the bone after surgical treatment of pHPT. Our goal is to determine the optimal management of hyperparathyroidism in pregnancy and the obstetric and neonatologic outcomes.

A 42-year-old multiparous patient was admitted by the 32 week of gestation. The patient reported lower abdominal pain and weight loss associated with nausea

and vomiting. On admission, the pulse rate was 90 pulses/min and the blood pressure was 110/70 mmHg. The lung, heart, abdomen, and neurological examinations were normal. The serology assessment found an elevated serum calcium level at 150 mg/l (88 < normal value < 106 mg/l), hypophosphatemia, hypercalciuria, and increased parathyroid hormone (PTH) level at 207 pg/ml (12 < normal < 88). These all confirmed the pHPT diagnosis. The ultrasound demonstrated a large nodule adjacent to the inferior left lobe pole of the thyroid gland. The abdominal ultrasound demonstrated nephrolithiasis and renal pelvic dilatation. The electrocardiography showed sinus rhythm, and the QT tract was normal. The hydration treatment consisted of intravenous saline solution in order to control continuous hypercalcemia. However, the hypercalcemia persisted and a parathyroidectomy was achieved in the 33 week of gestation; a left inferior parathyroid adenoma was removed per surgery. The histology did not evidence any malignancy. Two days later, a cesarean section was performed for fetal suffering, and a female newborn was delivered weighing 2500 g with an APGAR score of 7/10 and a normal phosphocalcic level. By the second postoperative day, the serum calcium level suddenly came down to 70 mg/l. The hypophosphoremia was at 18 mg/l (25 < normal value < 45), and the hyperparathormonemia and the alkaline-phosphate were 3 times and 10 times the normal value, respectively, that evoked the HBS diagnosis. The calcium continued to decrease to less than 45 mg/l despite the continuous intravenous calcium supplementation that was supplied for 2 days. Then, calcium associating 1- α -hydroxyl-vitamin D3 was administrated orally (2 μ g/day). Several months later, the serum calcium and phosphorus levels become normal [Figure 1]. Bone mineral density was achieved on diagnosis and 1 year later, lumbar spine BMD increased from 0.833 g/cm² on diagnosis to 1.032 g/cm² [Table 1]. pHPT is caused by long-term increase of parathormone (PTH) secretion by pathological parathyroid gland.^[1] The incidence of pHPT in reproductive females is estimated to be 8 new cases per 100,000 per year.^[1] Untreated hypercalcemia would demonstrate an increased risk of maternal complications of 67%.^[2] They are reported to be hyperemesis, nephrolithiasis, and pancreatitis after delivery.^[3] In addition, the fetus would suffer of delayed growth and neonatal hypocalcemia.^[4] The maternal pHPT symptoms are not specific and include muscle weakness, vomiting, psychiatric symptoms, visceral calcification, nephrocalcinosis, or kidney stone.^[5] The early diagnosis is always difficult during pregnancy since symptoms are generally trivial and easy to confuse with minor complications of pregnancy. Therefore, the diagnosis is done tardy, and our case was diagnosed by the 32 week of

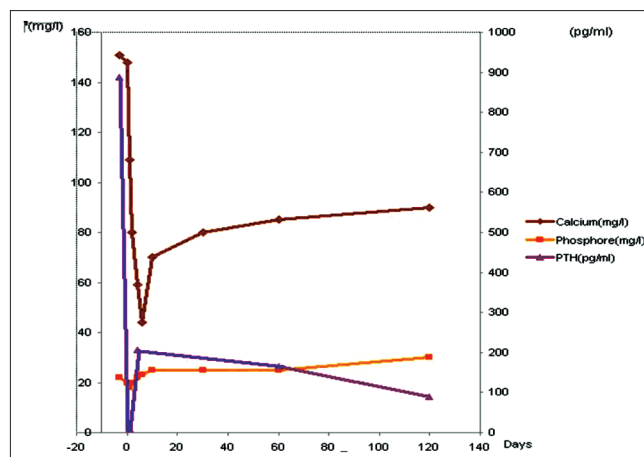


Figure 1: Evolution of biological parameters before and after treatment

Table 1: Evolution of DMO parameters at the diagnosis time and 1 year after treatment

| Lumbar spine | At baseline | 6 months | 12 months |
|--------------------------|-------------|----------|-----------|
| BMD (g/cm ²) | 0.833 | 0.859 | 1.032 |
| Z score | -1.8 | -1.5 | +0.1 |
| T score | -2.0 | +1.8 | -0.2 |

pregnancy. The maternal neck exploration optimal time of HPT symptomatic woman is in the second trimester of pregnancy; this allows avoiding the organogenesis in the first trimester, and consequently the risk of preterm labor in the third trimester.^[6] This could be achieved safely yet in the third trimester by a parathyroid surgeon.^[7] The surgical treatment should be postponed to postdelivery stage in symptom-free patients. Maternal hypercalcemia was found in our case in the third trimester, and symptomatic treatment was not efficient to control hypercalcemia, and thus surgery was performed. The delivered baby often demonstrates neonatal hypocalcemia resulting from intrauterine suppression of fetal parathyroid function by maternal hypercalcemia. Our neonate case demonstrated hypotrophy; however, the phosphocalcic assessment was normal. In contrast, the mother developed severe hypocalcemia and hypophosphatemia with moderate HPT explained by an extensive remineralization of the skeleton called HBS which is different from postoperative HPT. The HBS was described by Albright *et al.* in 1948 as a result of severe retention of calcium by previously demineralized bones consequent of PTH excess effects.^[8] HBS occurs in 13%–30% of primary HPT cases after parathyroidectomy.^[9] Hypocalcemia in HBS evolves within 24 hours and usually resolves within 4 weeks. Rare cases showed persistent HBS lasting several years.^[10] Brasier *et al.* followed 198 patients after surgery for pHPT and studied the risk factors for developing HBS. They found a positive correlation with aging, larger adenoma size, increased serum alkaline phosphatase levels, and elevated

blood urea nitrogen level.^[11,12] Intravenous calcium in symptomatic patients should be administered in low rate of 93–186 mg of calcium gluconate. A continuous intravenous calcium gluconate is administered in severe or prolonged hypocalcemia cases according to the feedback of the calcemia assessment. Our case showed an improvement of BMD in postoperative stage. Authors demonstrated severe bone loss recovering after successful surgery treatment.

This article reported a pHPT diagnosed in pregnant woman which was complicated by severe HBS after parathyroid surgery. Early diagnosis and appropriate treatment of hyperparathyroidism is essential. Appropriate monitoring of serum calcium levels by calcium compensation in the early postoperative period is necessary to prevent complications.

**Hanan El Ouahabi, Houda Salhi, Saïd Boujraf¹,
Farida Ajdi**

Department of Endocrinology, University Hospital of Fez, Fez, Morocco, ¹Department of Biophysics and Clinical MRI Methods, University of Fez, Fez, Morocco

Corresponding author: Dr. Saïd Boujraf

Department of Biophysics and Clinical MRI Methods,
Faculty of Medicine and Pharmacy, University of Fez, BP. 1893; Km 2.200,
Sidi Hrazem Road, Fez 30000, Morocco.
E-mail: sboujraf@gmail.com

parathyroid adenoma associated with primary hyperparathyroidism and marked post operative hungry bone syndrome. *Intern Med* 1996;35:545-9.

| Access this article online | |
|--|--|
| Quick Response Code: | Website: www.ijem.in |
|  | DOI: 10.4103/2230-8210.98045 |

REFERENCES

1. Milas M, Wagner K, Easley K, Siperstein A, Weber CJ. Double adenomas revisited: Non uniform distribution favors enlarged superior parathyroids. *Surgery* 2003;134:995-1003.
2. Schnatz PF, Curry SL. Primary hyperparathyroidism in pregnancy: Evidence-based management. *Obstet Gynecol Surv* 2002;57:365-6.
3. Amaya García M, Acosta Ferial M, Soto Moreno A, Dios Fuentes E, Navarro González E, Quijada Thong D, *et al.* Primary hyperparathyroidism in pregnancy. *Gynecol Endocrinol* 2004;19:111-4.
4. Graham EM, Freedman LJ, Forouzan I. Intrauterine growth retardation in a woman with primary hyperparathyroidism. *J Reprod Med* 1998;43:451-4.
5. Wilsomd T, Martin T, Christensen R, Yee AH, Reynolds C. Hyperparathyroidism in pregnancy. *Can Med Assoc J* 1983;129:986-9.
6. Kelly TR. Primary hyperparathyroidism and pregnancy. *Surgery* 1991;110:1028-34.
7. Schnatz PF, Taxton S. Parathyroidectomy in the third trimester of pregnancy. *Obstet Gynecol Surv* 2005;60:272-82.
8. Albright F, Reifenstein EC. *The Parathyroid Glands and Metabolic Bone Disease.* Baltimore: Williams and Wilkins; 1948.
9. Headley CM. Hungry bone syndrome following parathyroidectomy. *ANNA J* 1998;25:283-9; quiz 290-1.
10. Brasier AR, Nussbaum SR. Hungry bone syndrome: Clinical and biochemical predictors of its occurrence after parathyroid surgery. *Am J Med* 1988;84:654-60.
11. Chehaiber MM, Jensen JE. Hungry bone syndrome due to vitamin-D deficiency. *Ugeskr Laeger* 2009;171:2925-6.
12. Natsui K, Tanaka K, Suda M, Yasoda A, Shigeno C. Oxyphil