

RESEARCH ARTICLE

An in vivo ^{11}C -PK PET study of microglia activation in Fatal Familial Insomnia

Leonardo Iaccarino^{1,2}, Luca Presotto³, Valentino Bettinardi³, Luigi Gianolli³, Ignazio Roiter⁴, Sabina Capellari^{5,6}, Piero Parchi^{5,6}, Pietro Cortelli^{5,6} & Daniela Perani^{1,2,3}

¹Vita-Salute San Raffaele University, Milan, Italy

²In vivo Human Molecular and Structural Neuroimaging Unit, Division of Neuroscience, IRCCS San Raffaele Scientific Institute, Milan, Italy

³Nuclear Medicine Unit, IRCCS San Raffaele Hospital, Milan, Italy

⁴ASL9 Ca' Foncello, Treviso, Italy

⁵Department of Biomedical and Neuromotor Sciences (DIBINEM), Alma Mater Studiorum University of Bologna, Bologna, Italy

⁶IRCCS Institute of Neurological Sciences of Bologna, AUSL Bologna, Bologna, Italy

Correspondence

Daniela Perani, Division of Neuroscience, Vita-Salute San Raffaele University, IRCCS San Raffaele Scientific Institute, Nuclear Medicine Unit, IRCCS San Raffaele Hospital, Via Olgettina 60, Milan, Italy.
Tel: +39 02.2643.2224;
Fax: +39 02.2643.2717;
E-mail: perani.daniela@hsr.it

Funding Information

The research received funding from the EU FP7 INMIND Project (FP7-HEALTH-2011-two-stage "Imaging of Neuroinflammation in Neurodegenerative Diseases", grant agreement no. 278850).

Received: 3 October 2017; Accepted: 14 October 2017

Annals of Clinical and Translational Neurology 2018; 5(1): 11–18

doi: 10.1002/acn3.498

Abstract

Objective: Postmortem studies reported significant microglia activation in association with neuronal apoptosis in Fatal Familial Insomnia (FFI), indicating a specific glial response, but negative evidence also exists. An in vivo study of local immune responses over FFI natural course may contribute to the understanding of the underlying pathogenesis. **Methods:** We included eight presymptomatic subjects (mean \pm SD age: 44.13 \pm 3.83 years) carrying the pathogenic D178N-129^{met} FFI mutation, one symptomatic patient (male, 45 yrs. old), and nine healthy controls (HC) (mean \pm SD age: 44.00 \pm 11.10 years.) for comparisons. ^{11}C -(R)-PK11195 PET allowed the measurement of Translocator Protein (TSPO) overexpression, indexing microglia activation. A clustering algorithm was adopted to define subject-specific reference regions. Voxel-wise statistical analyses were performed on ^{11}C -(R)-PK11195 binding potential (BP) images both at the group and individual level. **Results:** The D178N-129^{met/val} FFI patient showed significant ^{11}C -(R)-PK11195 BP increases in the midbrain, cerebellum, anterior thalamus, anterior cingulate cortex, orbitofrontal cortex, and anterior insula, bilaterally. Similar TSPO increases, but limited to limbic structures, were observed in four out of eight presymptomatic carriers. The only carrier with the codon 129^{met/val} polymorphism was the only one showing an additional TSPO increase in the anterior thalamus. **Interpretation:** In comparison to nonprion neurodegenerative diseases, the observed lack of a diffuse brain TSPO overexpression in preclinical and the clinical FFI cases suggests the presence of a different microglia response. The involvement of limbic structures might indicate a role for microglia activation in these key pathologic regions, known to show the most significant neuronal loss and functional deafferentation in FFI.

Introduction

Prion Diseases (PrDs) or transmissible spongiform encephalopathies (TSEs) are a group of rapidly progressive conditions characterized by the accumulation of misfolded prion protein (scrapie PrP - PrP^{Sc}).¹ Human prion diseases include conditions such as Creutzfeldt–Jakob Disease (CJD) and Fatal Familial Insomnia (FFI) and include sporadic, genetic, and acquired forms.^{2,3}

The net majority of the fatal insomnia cases are familial, with FFI qualifying as one of the most common inherited prion disease worldwide.³ FFI is a rare disease⁴ linked to a missense mutation in the prion protein gene (*PRNP*) at codon-178, with aspartate-asparagine replacement (Asp→Asn) (D178N mutation),^{5,6} which has a high, almost complete, penetrance.^{5–7} The D178N mutation can trigger different clinico-pathological syndromes, either thalamic-dominant FFI or CJD, depending on a

methionine-valine polymorphism at *PRNP* codon-129.^{8–10} FFI syndrome is almost exclusively associated with methionine in the mutated allele (D178N-129M),⁹ but not all the carriers of the D178N-129M mutation develop an FFI phenotype.^{11,12} Additionally, methionine/valine polymorphism in the normal allele appears relevant for disease progression and severity, with FFI D178N-129^{M/M} patients presenting with a more rapid decline compared to D178N-129^{M/V} cases.⁹ FFI presents with disrupted sleep (loss of sleep spindles and slow-wave sleep and enacted dreams), autonomic hyperactivation and motor abnormalities (myoclonus, ataxia, dysarthria, dysphagia, and pyramidal signs).^{13,14}

Postmortem tissue evaluation consistently reveals neuronal death due to apoptosis and gliosis, largely confined to the ventral anterior and dorso-medial thalamic nuclei and inferior olivary nuclei, not correlating with the amount of PrP^{Sc} deposition.^{10,13,15–17} Previous studies have reported only mild PrP^{Sc} accumulation in FFI, particularly in patients with the shortest disease duration.^{16,18} Significant microglia activation has been described in association with neuronal apoptosis in FFI, both in terms of topography and magnitude,¹⁷ but negative evidence also exists.^{19,20}

Structural Magnetic Resonance Imaging (MRI) studies have provided negative/heterogeneous evidence for volume loss,²¹ whereas novel approaches with diffusion tensor imaging (DTI) revealed significant alterations in the thalamus, cerebellum, and medulla oblongata.^{22,23}

With regard to molecular Positron Emission Tomography (PET) imaging, several ¹⁸F-FDG-PET studies revealed focal thalamic hypometabolism in FFI, variably reaching limbic and frontotemporal cortical regions possibly due to thalamic functional deafferentation.^{18,21,24,25} Limbic and cortical involvement is also supported by pathology studies showing a spread of PrP^{Sc} deposition, neurodegeneration, and gliosis in these areas, depending on disease duration.^{8,18}

To date, the relationships between PrP^{Sc}, neuronal apoptosis, spongiform change, and brain immune activation are not yet fully understood.¹⁷ In contrast to some in vivo²⁶ and postmortem evidence in CJD,²⁷ the in vivo dynamics of microglia responses in FFI are currently unknown.^{17,20}

PET with specific radioligands, such as the carbon-11 labeled (R)-PK11195, allows the in vivo investigation of microglia activation in humans.²⁸ These techniques detect overexpression of the 18 kDa Translocator Protein (TSPO), an outer mitochondrial membrane protein whose levels rise during microglia activation²⁹ but also, to a lesser extent, during astrocytes and macrophage activation.^{29,30} This technique has been previously adopted in several neurodegenerative conditions,^{28,31} including prion diseases.²⁶

Here, we employed ¹¹C-(R)-PK11195-PET to evaluate presence and temporal course of microglia activation, in vivo, in both presymptomatic carriers of the FFI D178N-129M mutation and in a single symptomatic patient.

Methods

Participants

We enrolled eight presymptomatic carriers of the D178N *PRNP* mutation (age mean \pm SD 44.13 \pm 3.83 years), belonging to three Italian families. Seven of them (FFI Carriers 1-7) were homozygous, 129^{M/M}, whereas only one (FFI Carrier 8) was heterozygous, 129^{M/V}, at *PRNP* codon 129. All the ¹¹C-(R)-PK11195 scans were performed at the Nuclear Medicine Unit of the San Raffaele Hospital (Milan, Italy) between 2006 and 2008. Of note, all the carriers are currently still asymptomatic (June 2017). The only FFI patient was a male, 45 years old, who carried a 129^{met/val} polymorphism. He was evaluated 6 months after symptom onset and was still autonomous at the time of PET. He died 8 months after PET, thus presenting with a total 14 months of disease duration (see Table 1, sensitive data, such as sex and age, is not revealed for confidentiality reasons).

¹¹C-(R)-PK11195 PET scans of nine healthy volunteers were included for comparison (mean age \pm SD: 44.00 \pm 11.10). The controls were external volunteers ($N = 6$) or relatives of the presymptomatic carriers without the mutation ($N = 3$).

All the procedures involving human participants performed in this study were in accordance with the ethical standards of the institutional and/or national research committee and with the 1964 Helsinki declaration and its later amendments or comparable ethical standards. All

Table 1. Summary of the FFI cohort.

ID	<i>PRNP</i> codon 129	Follow-up (years) PET–Study time
FFI Patient	met/val	–
FFI Carrier 1	met/met	11
FFI Carrier 2	met/met	10
FFI Carrier 3	met/met	11
FFI Carrier 4	met/met	10
FFI Carrier 5	met/met	10
FFI Carrier 6	met/met	11
FFI Carrier 7	met/met	11
FFI Carrier 8	met/val	9

FFI, Fatal Familial Insomnia; *PRNP*, Prion Protein Gene; met, methionine; val, valine.

Sensitive data, such as sex and age, is not revealed for confidentiality reasons.

the subjects involved personally gave their informed consent.

¹¹C-(R)-PK11195 PET acquisition

¹¹C-(R)-PK11195 PET scans were performed at the Nuclear Medicine Unit of San Raffaele Hospital (Milan, Italy), with multi-ring PET tomographs, either PET-CT system “Discovery LS” or “Discovery 690” General Electric Medical Systems. ¹¹C-(R)-PK11195 injected dose was of approximately 370 ± 37 MBq, with optimal radiochemical and chemical purity >95%.³²

The acquisition protocol consisted of a dynamic scan of 15 frames with a total duration of 58 min, that is, $6 \times 30 \text{ sec} / 2 \times 1 \text{ m} / 1 \times 3 \text{ m} / 3 \times 5 \text{ m} / 2 \times 10 \text{ m} / 1 \times 15 \text{ m}$. PET data were corrected for attenuation artifacts, radioactive decay, and scatter. Transaxial images were reconstructed using a Shepp-Logan filter (cut-off 5 mm filter width) in the transaxial plane, and a Shepp-Logan filter (cut-off 8.5 mm) in the axial direction. For each scan, the individual frames were realigned over time with statistical parametric mapping (SPM5) software to account for movement during acquisition.

¹¹C-(R)-PK11195 PET data processing

¹¹C-(R)-PK11195 nondisplaceable binding potential (BP_{ND}) images were estimated with a Receptor Parametric Mapping (RPM) (0.04 min⁻¹ lower bound, 1.0 min⁻¹ upper bound, 30 basis functions)³³ procedure, a basis function implementation of the Simplified Reference Tissue Modeling (SRTM) method.³⁴ The SRTM analysis generates BPs by modeling the time activity curve (TAC) of a preset reference region and comparing it voxel-wise in the whole scan.³⁴ The identification of a reference region with ¹¹C-(R)-PK11195-PET can be particularly challenging, since the delivery of the tracer is homogeneous across the whole-brain, hindering the delineation of an anatomically defined region.^{35,36} This methodological caveat led to the development of automated clustering algorithms able to select pseudo-reference regions, that is, clusters of voxels sharing a specific TAC.^{35,37} Here, we employed the Curve Distance Clustering Algorithm (CDCA),³⁸ which is an adaptation of the well-validated SuperVised Clustering Algorithm.³⁵

The CDCA algorithm estimates the similarity of the TACs of each voxel with four predefined TACs, representing reference tracer delivery in four compartments, that is, blood, white matter, gray matter with nonspecific binding and high-specific binding.³⁸ The voxels with a TAC most resembling of the gray matter with nonspecific binding compartment were then used as reference region for the parametric BP analysis.

The clustering maps obtained with the CDCA procedure were also used to spatially normalize ¹¹C-(R)-PK11195 BP images to the standard Montreal Neurological Institute (MNI) space. The probability maps of the gray and white matter were entered into the unified segmentation module of SPM12. The resulting spatial transformations were used for the warping to MNI space and to subsequently deform a standardized MNI mask to native space in order to mask extracranial uptake. This pipeline resulted in masked and warped ¹¹C-(R)-PK11195 BP images.

¹¹C-(R)-PK11195 PET analysis

Voxel-wise statistical comparisons in the FFI carriers were performed at group and single-subject levels. Analyses were run with SPM12 software, covarying for age as a nuisance factor. Statistical significance was set at $P < 0.001$ (uncorrected for multiple comparisons), with minimum cluster extent $k:100$ voxels. Single-subject analysis was performed by estimating individual voxel-wise z-score maps for the symptomatic patient and FFI mutation carriers using the mean and standard deviation of ¹¹C-(R)-PK11195 values in the healthy controls. Consistent with the group comparison, statistical significance was set at $z > 3.29$ (two-sided, $P < 0.001$).

Results

FFI presymptomatic carriers

The group analysis showed no statistically significant differences with the healthy controls. At single-subject evaluation, clusters of significant activation were present in limbic regions in four FFI presymptomatic carriers (carriers 1,3,6,8), namely the insula and the cingulate cortex in all the subjects; other than in the putamen and pallidum in carriers 1 and 3, respectively (see Fig. 1). Of note, carrier 8 was the only D178N-129^{M/V} and also the only showing significant focal ¹¹C-(R)-PK11195 BP increases in the left anterior thalamus, comparable to the FFI D178N-129^{M/V} patient pattern (see below and Fig. 1). The lack of thalamic involvement was confirmed in all the other carriers also adopting more liberal statistical thresholds, that is, $z > 2.58$ (two-sided, $P < 0.01$).

FFI symptomatic patient

The single-subject analysis revealed significant cortical TSPO overexpression, peaking in the anterior cingulate cortex, in the medial orbitofrontal cortex and in the anterior insula. At the subcortical level, the FFI patient showed confined and significant BP increases in the anterior thalamus (MNI $\pm 14, -4, 8$), with a remarkable

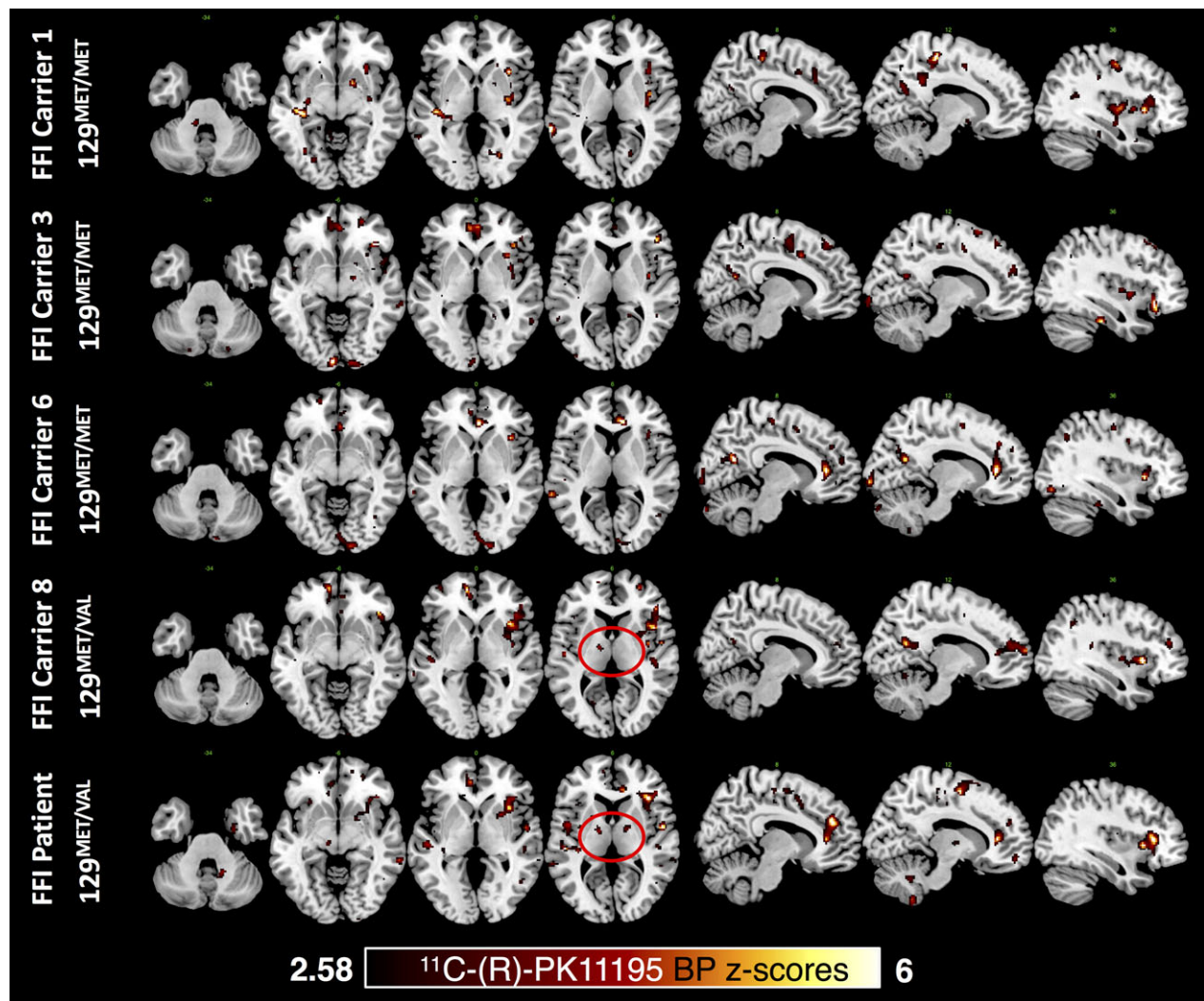


Figure 1. ^{11}C -(R)-PK11195 BP increases in single subjects. Figure shows significant ($z > 2.58$, $P < 0.01$ two-tailed) ^{11}C -(R)-PK11195 BP elevation in four carriers, three D178N-129^{met/met} and one D178N-129^{met/val}, together with the symptomatic patient (D178N-129^{met/val}). Red circles highlight BP increases in the anterior thalamic nuclei in Carrier 8 and the patient. Voxels with significant increases are overlaid on a standard anatomical template with MRICron software on multiple axial and sagittal slices (<http://www.mccauslandcenter.sc.edu/crn1/tools>). BP, binding potential.

colocalization observed in FFI carrier 8. The closest fit to atlas-based subnuclei was with the ventral thalamic anterior nuclei. Of note, the FFI patient additionally showed significant focal ^{11}C -(R)-PK11195 increases in the left midbrain (MNI -10, -20, -5) and cerebellum (MNI 14, -52, -32; -38, -66, -48; 12, -51, -56) (see Fig. 1).

Discussion

FFI is a fatal monogenic disease characterized by a specific combination of a missense mutation and an in cis single-nucleotide polymorphism in the *PRNP* gene.³⁹ The D178N-129M combination predominantly yields a unique

clinical and neuropathological signature, with selective thalamic and brainstem nuclei degeneration leading to a fatal disease characterized by severe sleep alterations with autonomic hyperactivity and myoclonus.^{15,39} Here, we present the first in vivo ^{11}C -(R)-PK11195 PET study of microglia activation in presymptomatic carriers of the Fatal Familial Insomnia *PRNP* D178N-129M pathogenic mutation, and an evaluation in a single symptomatic patient.

Ever since its characterization,^{5,6,13} FFI has consistently shown remarkably distinct clinical and pathological features, defining a unique entity within prionopathies.⁸ One cardinal difference with other prionopathies relates to the

generally low accumulation of PrP^{Sc} aggregates, reaching significant levels only in the cerebral cortex of the cases with the longest disease duration.^{3,8}

The association between microglial activation and the neuropathological changes in FFI remains elusive, highlighted by the discordant results provided by autopsy studies.^{17,19,20} Postmortem evidence indeed showed significant microglia activation in FFI, with a remarkable concordance with neuronal apoptosis, both in terms of topography and magnitude.^{17,20} It was then suggested that in FFI, microglia cells could reactively migrate to apoptotic sites to digest debris or, conversely, could somehow fuel neuronal apoptosis through the activation of pro-inflammatory signaling cascades.^{17,40} Still, there is evidence for a lack of association between microglia activation in FFI and interleukin-1 β levels, thus not supporting the latter hypothesis.¹⁷

The present unique in vivo PET findings in D178N-129^{M/M} pre-symptomatic mutation carriers crucially show a lack of significant in vivo TSPO overexpression (i.e., microglia activation) in key FFI pathology regions, that is, ventral anterior and medial dorsal thalamic nuclei and inferior olivary nuclei. The here included presymptomatic carriers were on average about 44 years old and were still asymptomatic (June 2017), after an average 10 years of follow-up after PET scan. Considering that FFI has been shown to harbor almost complete penetrance,⁷ with risk of clinical onset peaking around 50–55 years of age,⁴¹ our cohort was studied about 6–11 years before the expected clinical onset. These negative ¹¹C-(R)-PK11195-PET findings are in accordance with a previous ¹⁸F-FDG-PET study in FFI presymptomatic mutation carriers, showing the only dysfunctional marker being significant thalamic hypometabolism.⁴² More specifically, the latter was evident only shortly before the clinical onset (about 13–21 months)⁴² and was considered related to underlying fast and abrupt pathology processes. Four out of eight presymptomatic carriers showed spatially consistent and significant ¹¹C-(R)-PK11195 BP increases in the limbic structures, such as anterior/middle/posterior cingulate cortices and insula; with two of them showing an additional involvement of basal ganglia. Unraveling the biological meaning of these brain ¹¹C-(R)-PK11195 BP increases in presymptomatic carriers is challenging. All the carriers were neurologically normal and did not have any clinical complaint. Considering the asymptomatic phase and the previous in vivo evidence, both the presence of PrP^{Sc} pathology and neurodegeneration are unlikely. This is confirmed by the lack of significant increases in regions where the pathogenic process is expected to begin, that is, medulla oblongata and anterior ventral/dorso-medial thalamic nuclei, in all carriers but one (see below). The observed pattern of microglia activation could be due to molecular mechanisms that are in need of further studies. Therefore, while the present data

provide some evidence for limbic microglial activation in presymptomatic FFI, these results should be interpreted with caution.

Notably, the symptomatic FFI patient showed significant ¹¹C-(R)-PK11195 BP increases in key FFI pathology regions, such as the ventral anterior thalamic nuclei, the midbrain and the cerebellum. It is of particular interest that the only presymptomatic carrier with a codon 129^{M/V} polymorphism showed a rather limited but significant TSPO overexpression in anterior thalamus, orbitofrontal cortex, and right anterior insula, all topographically consistent with the pattern seen in the affected patient. While it is tempting to speculate that the codon 129 polymorphism could be associated with differential dynamics of microglia responses in FFI, the present findings cannot unequivocally confirm this claim and further studies are needed.

These findings suggest that, although confined, FFI in the symptomatic phase may be associated with a selective and focal microglia activation in key pathologic subcortical regions, extending to limbic cortical regions perhaps bearing functional deafferentation effects. At the cortical levels, previously reported FFI patients with longer disease durations (i.e., D178N-129^{M/V}) showed both marked in vivo ¹⁸F-FDG-PET hypometabolism and significant postmortem spongiosis and gliosis, with a milder neuronal loss especially evident in frontal and cingulate regions.^{18,24,39}

We have recently described significant ¹¹C-(R)-PK11195 BP increases in CJD, with magnitude and topography varying according to the clinical subtype.²⁶ In particular, more significant increases were observed at the subcortical levels in variant CJD and cortical levels in typical sporadic CJD, whereas the only genetic CJD patient (PRNP V210I mutation) showed the most confined and least significant increases.²⁶ Both the genetic V210I CJD and the D178N-129^{M/V} FFI showed an overall lower magnitude of in vivo ¹¹C-(R)-PK11195 BP increases, in comparison to the sporadic and the variant CJD cases.²⁶ It is tempting to speculate that these genetic prion disease cases could have been characterized by a slowly progressive incubation period, reflecting in a distinctive temporal dynamic of microglia activation. This would imply that, in preclinical and earliest clinical phases of genetic prion diseases, microglia cells could be not activated or, alternatively, activated in a neuroprotective phenotype. With disease progression and chronicity of pathology accumulation, microglia cells could progressively activate and switch to a more aggressive functional phenotype, possibly detected by ¹¹C-(R)-PK11195-PET (see below). Genetic prion diseases have been classified as “fast” or “slow” based on the usual clinical course, ranging from very rapid (<3 years of disease duration) to slower

courses (>3 years), witnessing a pronounced variability concerning survival time.⁴ Therefore, this hypothesis is more likely to hold true in slower, less fulminant, genetic cases.

Very few previous studies have evaluated in vivo TSPO overexpression in presymptomatic mutation carriers of neurodegenerative proteinopathies, and crucially none of them in prion diseases. Significant striatal and cortical ¹¹C-(R)-PK11195 binding increases have been described in premanifest Huntington Disease (HD) mutation carriers, also correlating with the short-time probability of disease onset.⁴³ Another study employing ¹¹C-DAA1006-PET found significant TSPO overexpression in presymptomatic genetic carriers of microtubule-associated protein tau (MAPT) mutation.⁴⁴

Neuroinflammation has been evaluated also by means of ¹¹C-deuterium-L-deprenyl, indexing brain astrocytosis, in a study addressing presymptomatic carriers of inherited autosomal dominant AD (ADAD).⁴⁵ Of note, brain astrocytosis in ADAD is higher in the presymptomatic phases of disease, and steadily declines approaching clinical onset.⁴⁵ It is reasonable to consider that neurodegenerative conditions with long-lasting pathology accumulation, progressive insidious clinical onset, and longer survival time, such as genetic AD, are characterized by different microglial characteristics and temporal dynamics when compared to conditions with an abrupt clinical onset and short survival times, for example, in prion disease.

The present findings should also be considered in light of the lacking consensus on whether TSPO-based PET radioligands preferentially detect specific microglia functional states. Microglia are extremely versatile cells, which can acquire diverse phenotypes in response to specific trigger insults.⁴⁶ In postmortem evidence in prionopathies, microglia cells seem to be able to clear apoptotic material but not PrP^{Sc}, even after priming with lipopolysaccharide stimulation.⁴⁷ Apoptosis is the leading neuronal death mechanism in FFI¹⁷ and is known to trigger a specific neuroprotective microglial response, oriented toward phagocytosis of debris and restoration of tissue homeostasis through anti-inflammatory signaling.^{47,48} It is conceivable that at some point, the unremitting accumulation of PrP^{Sc} pathology, together with increased neuronal loss, ultimately triggers a microglial functional switch, that is, from neuroprotective to neurotoxic, which has already been suggested in prion diseases.²⁷ In FFI, thalamus, midbrain, brainstem, and cerebellum bear the brunt of pathology^{8,15} and here we showed focal and significant in vivo TSPO overexpression in the symptomatic patient. FFI patients with longest disease course have shown cortical pathology and dysfunction^{18,24} and we here consistently detected TSPO overexpression in cortical regions in vivo.

Thus, microglia activation seems to be part of the FFI pathology, in a peculiar and/or limited amount. Whether specific microglia functional states are present early in the FFI course, switching to the harmful aggressive phenotype in later phases, is a crucial issue in need of further studies, also considering the development of possible immunomodulatory interventions.

Acknowledgments

The authors wish to thank the families for their outstanding commitment to this study. The authors thank Mr. Gautam Tammewar for the final English revision. The research received funding from the EU FP7 INMIND Project (FP7-HEALTH-2011-two-stage “Imaging of Neuroinflammation in Neurodegenerative Diseases”, grant agreement no. 278850).

Author Contributions

Conception and design of the study: D.P., P.P., P.C.; Acquisition and analysis of data: L.I., L.P., V.B., L.G., S.C., I.R., D.P.; drafting a significant portion of the manuscript or figures: L.I., D.P., P.C.

Conflicts of Interest

The authors declare no competing interests.

References

1. Prusiner SB. Novel proteinaceous infectious particles cause scrapie. *Science* 1982;216:136–144.
2. Puoti G, Bizzi A, Forloni G, et al. Sporadic human prion diseases: molecular insights and diagnosis. *Lancet Neurology* 2012;11:618–628.
3. Schmitz M, Dittmar K, Llorens F, et al. Hereditary human prion diseases: an update. *Mol Neurobiol* 2016;8:559–12.
4. Kim M-O, Takada LT, Wong K, et al. Genetic PrP prion diseases. *Cold Spring Harb Perspect Biol* 2017; <http://cshperspectives.cshlp.org/citmgr?gca=cshperspect%3Bcshperspect.a033134v1>.
5. Medori R, Tritschler HJ, LeBlanc A, et al. Fatal familial insomnia, a prion disease with a mutation at codon 178 of the prion protein gene. *N Engl J Med* 1992;326:444–449.
6. Medori R, Montagna P, Tritschler HJ, et al. Fatal familial insomnia: a second kindred with mutation of prion protein gene at codon 178. *Neurology* 1992;42(3 Pt 1):669–670.
7. Minikel EV, Vallabh SM, Lek M, et al. Quantifying prion disease penetrance using large population control cohorts. *Sci Transl Med* 2016;8:322ra9.

8. Parchi P, Petersen RB, Chen SG, et al. Molecular pathology of fatal familial insomnia. *Brain Pathol* 1998;8:539–548.
9. Goldfarb LG, Petersen RB, Tabaton M, et al. Fatal familial insomnia and familial creutzfeldt-jakob disease: disease phenotype determined by a DNA polymorphism. *Science* 1992;258:806–808.
10. Montagna P, Gambetti P, Cortelli P, Lugaresi E. Familial and sporadic fatal insomnia. *Lancet Neurol* 2003;2:167–176.
11. Zerr I, Giese A, Windl O, et al. Phenotypic variability in fatal familial insomnia (D178N-129M) genotype. *Neurology* 1998;51:1398–1405.
12. Zarranz JJ, Digon A, Atarés B, et al. Phenotypic variability in familial prion diseases due to the D178N mutation. *J Neurol Neurosurg Psychiatry* 2005;76:1491–1496.
13. Lugaresi E, Medori R, Montagna P, et al. Fatal familial insomnia and dysautonomia with selective degeneration of thalamic nuclei. *N Engl J Med* 1986;315:997–1003.
14. Krasnianski A, Sanchez Juan P, Ponto C, et al. A proposal of new diagnostic pathway for fatal familial insomnia. *J Neurol Neurosurg Psychiatry* 2014;85:654–659.
15. Lugaresi E, Tobler I, Gambetti P, Montagna P. The pathophysiology of fatal familial insomnia. *Brain Pathol* 1998;8:521–526.
16. Parchi P, Castellani R, Cortelli P, et al. Regional distribution of protease-resistant prion protein in fatal familial insomnia. *Ann Neurol* 1995;38:21–29.
17. Dorandeu A, Wingertsman L, Chrétien F, et al. Neuronal apoptosis in fatal familial insomnia. *Brain Pathol* 1998;8:531–537.
18. Cortelli P, Perani D, Parchi P, et al. Cerebral metabolism in fatal familial insomnia: relation to duration, neuropathology, and distribution of protease-resistant prion protein. *Neurology* 1997;49:126–133.
19. Shi Q, Xie W-L, Zhang B, et al. Brain microglia were activated in sporadic CJD but almost unchanged in fatal familial insomnia and G114V genetic CJD. *Virology* 2013;10:1.
20. Llorens F, Thüne K, Schmitz M, et al. Identification of new molecular alterations in fatal familial insomnia. *Hum Mol Genet* 2016;25:2417–2436.
21. Krasnianski A, Bartl M, Sanchez Juan PJ, et al. Fatal familial insomnia: clinical features and early identification. *Ann Neurol* 2008;63:658–661.
22. Gemignani A, Laurino M, Provini F, et al. Thalamic contribution to sleep slow oscillation features in humans: a single case cross sectional EEG study in fatal familial insomnia. *Sleep Med* 2012;13:946–952.
23. Grau-Rivera O, Calvo A, Bargalló N, et al. Quantitative magnetic resonance abnormalities in creutzfeldt-jakob disease and fatal insomnia. *J Alzheimers Dis* 2017;55:431–443.
24. Perani D, Cortelli P, Lucignani G, et al. [18F]FDG PET in fatal familial insomnia: the functional effects of thalamic lesions. *Neurology* 1993;43:2565–2569.
25. Prieto E, Domínguez-Prado I, Riverol M, et al. Metabolic patterns in prion diseases: an FDG PET voxel-based analysis. *Eur J Nucl Med Mol Imaging* 2015;42:1522–1529.
26. Iaccarino L, Moresco RM, Presotto L, et al. An In Vivo (11)C-(R)-PK11195 PET and in vitro pathology study of microglia activation in creutzfeldt-jakob disease. *Mol Neurobiol* 2017;62:545.
27. Aguzzi A, Nuvolone M, Zhu C. The immunobiology of prion diseases. *Nat Rev Immunol* 2013;13:888–902.
28. Jacobs AH, Tavitian B, INMiND consortium. Noninvasive molecular imaging of neuroinflammation. *J Cereb Blood Flow Metab* 2012;32:1393–1415.
29. Liu G-J, Middleton RJ, Hatty CR, et al. The 18 kDa translocator protein microglia and neuroinflammation. *Brain Pathol* 2014;24:631–653.
30. Lavisse S, Guillermier M, Hérard A-S, et al. Reactive astrocytes overexpress TSPO and are detected by TSPO positron emission tomography imaging. *J Neurosci* 2012;32:10809–10818.
31. Stefaniak J, O'Brien J. Imaging of neuroinflammation in dementia: a review. *J Neurol Neurosurg Psychiatry* 2016;87:21–28.
32. Matarrese M, Moresco RM, Cappelli A, et al. Labeling and evaluation of N-[11C] methylated quinoline-2-carboxamides as potential radioligands for visualization of peripheral benzodiazepine receptors. *J Med Chem* 2001;44:579–585.
33. Gunn RN, Lammertsma AA, Hume SP, Cunningham VJ. Parametric imaging of ligand-receptor binding in PET using a simplified reference region model. *NeuroImage* 1997;6:279–287.
34. Lammertsma AA, Hume SP. Simplified reference tissue model for PET receptor studies. *NeuroImage* 1996;4(3 Pt 1):153–158.
35. Turkheimer FE, Edison P, Pavese N, et al. Reference and target region modeling of [11C]-(R)-PK11195 brain studies. *J Nucl Med* 2007;48:158–167.
36. Turkheimer FE, Rizzo G, Bloomfield PS, et al. The methodology of TSPO imaging with positron emission tomography. *Biochem Soc Trans* 2015;43:586–592.
37. Yaqub M, vanBerckel BNM, Schuitemaker A, et al. Optimization of supervised cluster analysis for extracting reference tissue input curves in (R)-[(11)C]PK11195 brain PET studies. *J Cereb Blood Flow Metab* 2012;32:1600–1608.
38. Presotto L, Iaccarino L, Bettinardi V, et al. An automated clustering algorithm for reference region extraction of brain 11 C-PK11195 studies. Nuclear Science Symposium and Medical Imaging Conference (NSS/MIC), 2015 IEEE 2015:1–3.

39. Montagna P. Fatal familial insomnia and the role of the thalamus in sleep regulation. *Handb Clin Neurol* 2011;99:981–996.
40. Unterberger U, Voigtlander T, Budka H. Pathogenesis of prion diseases. *Acta Neuropathol* 2005;109:32–48.
41. Forloni G, Tettamanti M, Lucca U, et al. Preventive study in subjects at risk of fatal familial insomnia: innovative approach to rare diseases. *Prion* 2015;9:75–79.
42. Cortelli P, Perani D, Montagna P, et al. Pre-symptomatic diagnosis in fatal familial insomnia: serial neurophysiological and 18FDG-PET studies. *Brain* 2006;129(Pt 3):668–675.
43. Tai YF, Pavese N, Gerhard A, et al. Microglial activation in presymptomatic Huntington's disease gene carriers. *Brain* 2007;130(Pt 7):1759–1766.
44. Miyoshi M, Shinotoh H, Wszolek ZK, et al. In vivo detection of neuropathologic changes in presymptomatic MAPT mutation carriers: a PET and MRI study. *Parkinsonism Relat Disord* 2010;16:404–408.
45. Rodriguez-Vieitez E, Saint-Aubert L, Carter SF, et al. Diverging longitudinal changes in astrocytosis and amyloid PET in autosomal dominant Alzheimer's disease. *Brain* 2016;139(Pt 3):922–936.
46. Perry VH, Nicoll JAR, Holmes C. Microglia in neurodegenerative disease. *Nat Rev Neurol* 2010;6:193–201.
47. Hughes MM, Field RH, Perry VH, et al. Microglia in the degenerating brain are capable of phagocytosis of beads and of apoptotic cells, but do not efficiently remove PrPSc, even upon LPS stimulation. *Glia* 2010;58:2017–2030.
48. De Simone R, Ajmone-Cat MA, Minghetti L. Atypical antiinflammatory activation of microglia induced by apoptotic neurons: possible role of phosphatidylserine-phosphatidylserine receptor interaction. *Mol Neurobiol* 2004;29:197–212.