

Surgical Reconstruction of Complex Distal Foot Defects With Vascularized Fascia Lata

Mengdong Liu, MD,* Yunshu Yang, MS,* Yong Zhang, BCh,† Xuekang Yang, MD,* and Dahai Hu, PhD*

Background: Reconstruction of distal foot defect remains a challenge in plastic surgery. The purpose of this report is to present a new procedure that repairs these defects in severe burn patients. Results of application and follow-up in 7 patients were presented.

Methods: From January 2016 to March 2018, a total of 7 patients (age ranging from 21 to 57 years) with distal foot defects were treated in our department. All the wounds were caused by severe burns and repaired by the free vascularized fascia lata combined with thin split-skin graft. After the operation, the status of the fascia flaps and grafted skin was observed, and follow-up information and complications were documented.

Results: Among the 7 patients, the flaps and grafted skins completely survived in 5 patients. One patient was found to have grafted skin necrosis in the perioperative period, and 1 patient was found to have partial flap necrosis in the follow-up period. After conventional dressing treatment and skin grafting, the wounds healed in both patients. The mean follow-up was 6 months.

Conclusions: The method of combining the free vascularized fascia lata with thin split-skin graft represents a satisfactory approach for the repairing of distal foot defects.

Key Words: distal foot, tissue defects, reconstruction, free flap

(*Ann Plast Surg* 2020;84: 525–528)

Reconstruction of distal foot defect has always been challenging because the graft and transfer options are exceedingly limited.¹ Distal foot defects are usually accompanied by tendon or bone exposure. Skin graft is not suitable for bone exposure wound, because its long-term durability is unsatisfactory. Local flaps often have limited reach and size. Free flaps are associated with technical challenges and may cause bulky appearance, which results in postoperative esthetic and functional problems.² Optimal reconstruction of the distal foot defect should ensure not only stable cover able to resist friction while walking but also smooth foot contour to allow for the use of normal footwear, as well as the appropriate strength, durability and tension to achieve satisfactory foot

function. Among autologous flaps, the free tensor fascia lata flap is one of the most common muscle flaps for reconstructing tissue defect, but to our knowledge, it has not been previously described for the reconstruction of distal foot defects.^{3–6} The purpose of this report was to present a new procedure for reconstruction of the distal foot defects through combining the free vascularized fascia lata (FVFL) with thin split-skin graft. Herein, we showed that this method could achieve satisfactory repair effects.

PATIENTS AND METHODS

Patients

From January 2016 to March 2018, a total of 7 patients (5 males and 2 females, age ranging from 21 to 57 years) with distal foot defects caused by severe burns were treated in our department. The inclusion criteria for this study were as follows: (1) age ranged from 18 to 60 years, (2) with soft tissue defects in distal foot area caused by severe burns, and (3) without any severe uncontrollable systemic disease. All the defects were repaired by the FVFL combined with thin split-skin graft. Each patient provided informed consent, and the study was permitted by the Research Ethics Committee of Xijing Hospital (permit number, fmmu-16-0122).

Patient and Wound Characteristics

Among the 7 burned patients, 2 patients were burned by hot metal, 2 patients were burned by alcohol, and 3 patients were burned by electric. All the 7 patients were unilateral deep tissue defects of distal foot, 4 cases involved tendon exposure, and 3 cases had bone exposure. The size of the recipient area defects ranged from 3.2 cm × 5.5 cm to 5.2 cm × 8.6 cm. The detailed characteristics of the patients and wounds were listed in Table 1.

Preoperative Preparation

Before the operation, careful and comprehensive examinations were carried out, and all the patients had no operation contraindication diseases. The blood flows of anterior tibial artery, posterior tibial artery, dorsalis pedis artery, and the descending branch of lateral circumflex femoral artery were assessed by preoperative color Doppler arteriography. Considering the factors such as the location and size of the wound, the length of the vascular pedicle, and the diameter of vessels, the dorsalis pedis artery and vein were chosen as recipient vessels. If the vascular conditions were unsatisfactory, the ipsilateral great saphenous vein and the medial plantar artery were selected as alternative recipient vessels.^{7–9}

SURGICAL TECHNIQUE

Surgical Procedure

The surgical procedure was composed of 4 steps. First of all, the wound debridement treatment was conducted. For infected wound, 1 week negative pressure treatment and antibiotic therapy were conducted after debridement. The second step was to harvest the flap. The procedures of designing and harvesting the fascia flap were similar

Received April 16, 2019, and accepted for publication, after revision August 2, 2019. From the *Department of Burns and Cutaneous Surgery, Xijing Hospital, Air Force Military Medical University, Xi'an; and †Department of Burns Surgery, The Second People's Hospital of Xinxiang, Henan, China.

M.L. and Y.Y. contributed equally to this work.

Conflicts of interest and sources of funding: This study was partly supported by National Natural Science Foundation of China (81701902) and Natural Science Foundation of Shaanxi Province (2018JQ8049). The funders had no role in study design, data collection and analysis, decision to publish, or preparation of the article. The authors declared no conflicts of interest in this study.

Reprints: Dahai Hu, PhD, Department of Burns and Cutaneous Surgery, Xijing Hospital, Air Force Military Medical University, 15 Changle Xi Rd, Xi'an 710032, China. E-mail: hudahai@fmmu@126.com; or Xuekang Yang, MD, Department of Burns and Cutaneous Surgery, Xijing Hospital, Air Force Military Medical University, 15 Changle Xi Rd, Xi'an 710032, P.R. China. E-mail: 575871573@qq.com.

Copyright © 2019 The Author(s). Published by Wolters Kluwer Health, Inc. This is an open-access article distributed under the terms of the Creative Commons Attribution-Non Commercial-No Derivatives License 4.0 (CCBY-NC-ND), where it is permissible to download and share the work provided it is properly cited. The work cannot be changed in any way or used commercially without permission from the journal.

ISSN: 0148-7043/20/8405–0525

DOI: 10.1097/SAP.0000000000002115

TABLE 1. Characteristics of Patients

Patient	Age, y	Sex	Causes of Injuries	Characteristics of Wound	Defect Size, cm ²	Survival Condition of Flap	Complications
1	21	Female	Burned by alcohol	Right 3rd and 4th toes	4.0 × 6.5	Survival	None
2	29	Male	Electric burn	Right 3rd, 4th, and 5th toes, exposure of 4th and 5th phalanges and tendons, and exposure of 5th metatarsal	5.2 × 8.6	Survival	None
3	33	Male	Electric burn	Right 1st and 2nd toes	4.2 × 5.2	Survival	None
4	42	Male	Burned by alcohol	Left foot, exposure of 4th and 5th metatarsals	4.5 × 6.0	Survival	None
5	48	Female	Burned by the hot metal	Left 2nd and 3rd toes and the exposure of tendons	4.8 × 5.0	Survival	Partial flap necrosis caused by diabetes
6	53	Male	Burned by the hot metal	Left 4th toe and the exposure of 4th phalanx	3.2 × 5.5	Survival	None
7	57	Male	Electric burn	Right 1st and 2nd toes, exposure of 1st phalanx and tendon, and exposure of 1st metatarsal	3.8 × 7.5	Survival	Grafted skin necrosis caused by subcutaneous hemorrhage

as those of anterolateral thigh flap.^{10,11} The differences were that we only harvested the deep fascia and vascular pedicle, and the skin and the subcutaneous tissue were kept in the donor site. Third, the vascular anastomosis was performed. The anastomosis of the descending branch of lateral circumflex femoral artery and the dorsalis pedis artery (or the medial plantar artery), and the anastomosis of the descending branch of lateral circumflex femoral vein and the dorsalis pedis vein (or the great saphenous vein) were performed under the microscope. The end-to-end manner or end-to-side manner was chosen depending on the location of wound and status of vessels. After anastomosis, the patency of each vessel and blood circulation of flap were meticulously checked. After careful hemostasis, we sutured and fixed the flap to the recipient area and inserted the indwelling rubber drainage strip around the flap. Finally, we did the skin graft. After harvesting the thin split-skin and preparing the drainage holes, the skin was transplanted and fixed onto the surface of the fascia lata. Then, pressure dressings were set on the graft skin, and the affected limbs were kept in functional position with braces.

Postoperative Management

After the operation, all patients received intravenous anticoagulant, antispasmodic, and vasodilator drugs (dextran and papaverine hydrochloride).^{12,13} The ultrasound Doppler was performed every 2 hours to determine if the vascular anastomosis remained unobstructed within 1 week after surgery. The bandage was removed at 1 week after surgery, and the dressing was changed every 2 days. Patients were instructed to walking and systemic rehabilitation exercises from 2 weeks after

operation. All the patients were advised to use anticicatrical drugs from 3 weeks to 6 months after surgery.

RESULTS

Case Report

A 53-year-old male steelworker was admitted to our department with deep third degree burns in the fourth toe of his left foot. The wound caused by the hot metal in an industrial accident 3 weeks ago. After the injury, the patient was treated with conventional dressing at the local hospital. The wound not only did not heal but also got infected. Debridement of the burns was performed in the first surgical attempt at 24 days after the accident. Partial phalanx exposure, infected necrotic tissue, purulent exudates, and hypodermal infected lacuna were observed (Fig. 1A). After surgical debridement, we found the fourth phalanx exposure. The wound size was about 3.2 cm × 5.5 cm (Fig. 1B). The Kirschner wire was used to keep the stability of the joint, and the negative pressure treatment of wound was conducted. Antibiotic treatment was initiated according to results of the wound cultures. The reconstruction of the defect was performed in the second surgical attempt at 7 days after the debridement (Fig. 2A). We designed and obtained an FVFL according to the wound size (Figs. 2B–D). After harvesting the flap, surgical incision was repaired by suture in situ. Then, the vascular anastomosis was performed as end-to-site to the dorsalis pedis artery and end-to-end to the accompanying veins (Figs. 2E–G). After that, we performed the thin split-skin grafting at the recipient site

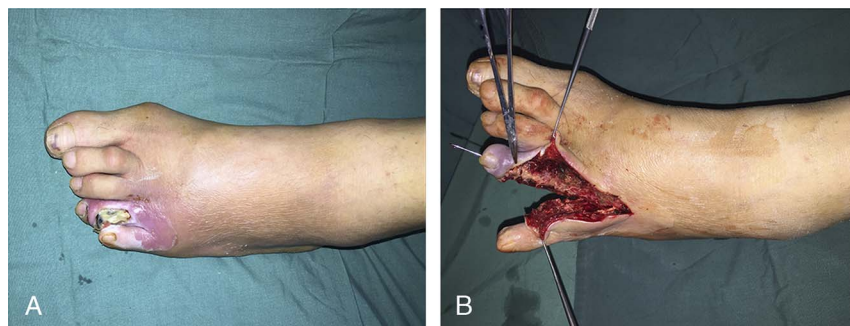


FIGURE 1. Characteristics of wound. A, Before debridement, infected necrotic tissue and purulent exudates remained on the wound. B, After debridement, the fourth phalanx exposed. The total wound size was approximately 3.2 × 5.5 cm. [full color online](#)

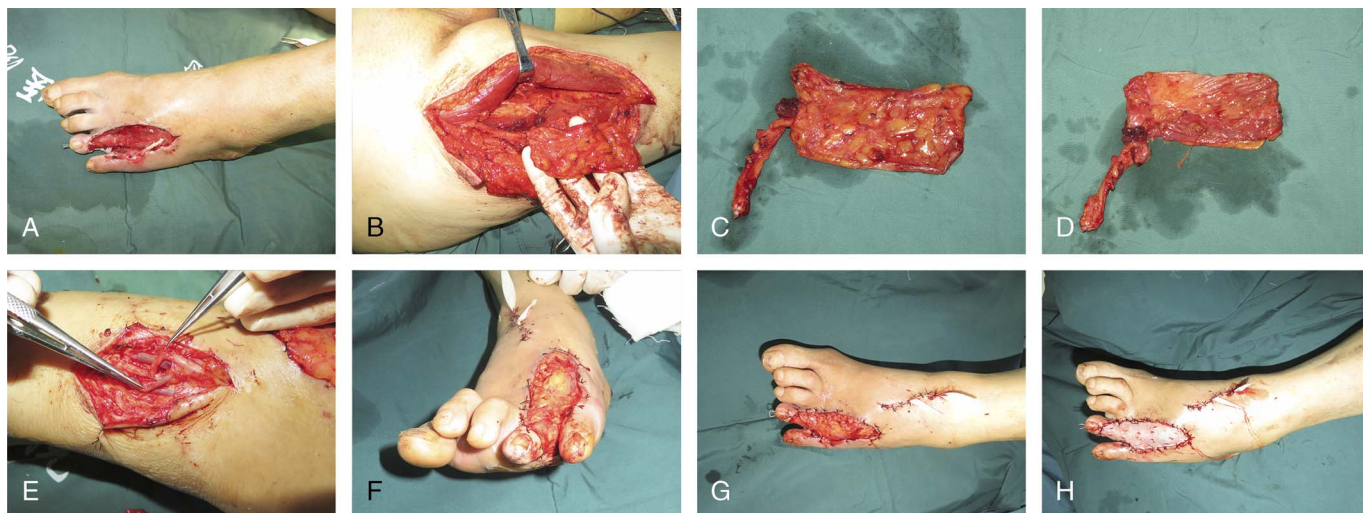


FIGURE 2. The process of reconstruction. A, After debridement and negative pressure treatment, the wound became clean. B, Harvesting the free vascularized anterolateral thigh fascia lata flap according to the wound size. C and D, The outer surface and inner surface of the flap. E, The vascular anastomosis was performed as end-to-site to the dorsalis pedis artery and end-to-end to the accompanying veins. F and G, Fixing the flap to the recipient site. H, Grafting of thin split-skin. [full color online](#)

(Fig. 2F). After surgery, the grafted flap and skin completely survived, and no postoperative complications were found. At the 3- and 6-month follow-ups, the functional recovery and appearance were satisfactory (Fig. 3).

Treatment Outcomes

In the perioperative period, the FVFLs and grafted skins survived completely in 5 patients. Grafted skin necrosis gradually happened in 1 patient (57-year-old, male), which was caused by subcutaneous hemorrhage; after conventional dressing therapy and skin re-grafting, the wound healed. The mean follow-up was 6 months. During the follow-up period, partial flap necrosis was found in 1 patient (48-year-old, female) at 4 months after operation. After a detailed inquiry of the patient's medical history, we found that the patient had a history of diabetes. From 3 months after operation, blood glucose control had been unsatisfactory. After insulin therapy, strict blood glucose control, conventional dressing therapy,

and skin re-grafting, the wound healed. All the patients accepted antiscar drug treatment. Six months after the operation, the foot functions of these patients were normal, and all the patients were satisfied with the treatment effects and appearance.

DISCUSSION

Distal foot problems vary in severity and complexity, and several local and distant reconstructive strategies have been proposed for resolving these problems. Obviously, skin graft is not suitable for severing as coverage in distal foot, because the durability could not meet functional requirements and may lead to recurrent ulceration of the area.¹⁴ Therefore, local flaps are commonly used. The filleted and partial filleted toe flaps are useful for reconstruction of minor defects, but their use would jeopardize the toes themselves.^{15,16} The reverse dorsal metatarsal artery flap, webspace neurovascular island flap, and distally based dorsalis pedis flap could be chosen for repairing distal foot defects, but

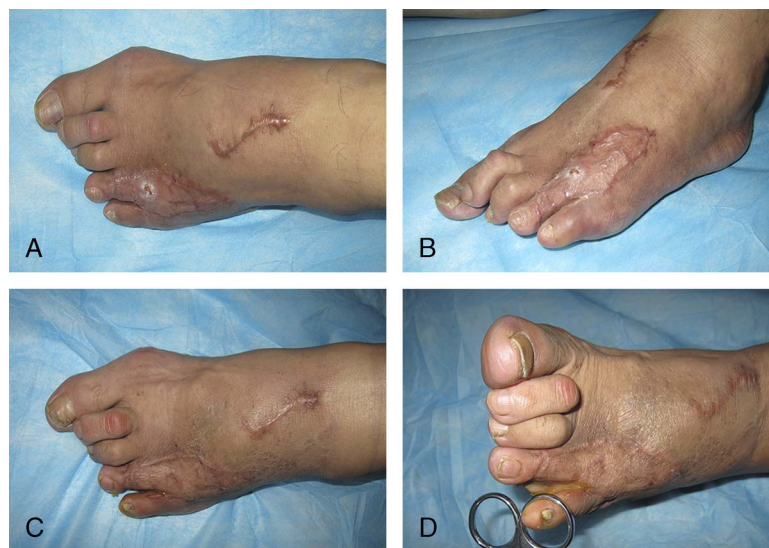

FIGURE 3. Follow-up showed that the flap and grafted skin survived well. A and B, 3 months; (C) and (D), 6 months. [full color online](#)

they are also restricted by their limited arc of rotation and skin quality.^{17,18} The option of distant pedicled flaps, cross-foot, and cross-leg flaps is also limited by inherited drawbacks, namely, the transfer of nonglabrous skin and the prolonged immobilization and hospitalization period.^{19,20} Free flaps have the potential of solving any coverage problem anywhere on the foot, but they tend to be bulky and cannot meet the esthetic requirements of patients.^{14,21} Considering these characteristics and limitation of the flaps mentioned previously, we chose the method of combining the FVFL with thin split-skin graft.

On the basis of our experiences, this method offers the following advantages. First, the flexibility and plasticity of the FVFL are satisfactory. By folding or stuffing method, the FVFL is capable to repair various wound of foot, including lacunar wound, fissure wounds, and so on. Second, the damage to the donor site is little. In the presented method, the skin and the subcutaneous tissue are kept in the donor site, and after harvesting the flap, surgical incision could be repaired by suture in situ. In addition, the thigh function is not affected by scar contracture of the incision. Third, the appearance of the recipient area is satisfactory. The conventional flap often causes a bulky appearance and need for further fat removing surgery, but the FVFL is thin enough. Fourth, based on its rich blood supply, the FVFL has good anti-infective properties, which can promote wound healing when the wound is complicated by bacterial infection or osteomyelitis.

However, our method has some limitations. First, the area of the FVFL that could be harvested is limited, and excessive injury to the deep fascia and perforator vessel may cause poor healing in the donor area and affect the thigh function. Second, the surgical method is complicated and required microsurgical techniques. Third, it is difficult to observe the blood circulation of flap and the survival condition of grafted skin after surgery, because the operated area was wrapped with pressure dressing. According to our experience, regular ultrasonic Doppler examination is necessary. Fourth, for patients with systemic disease such as diabetes, atherosclerosis, and so on, actively and strictly treating basic diseases is significant to reduce the incidence of postoperative complications. Fifth, the sensory reconstruction of the distal foot was important for patient's functional recovery and avoiding excessive wear of surgical area. Unfortunately, the surgical procedures of sensory reconstruction were not explored in the present study.

CONCLUSIONS

The method of combining the FVFL with thin split-skin graft represents a satisfactory approach for the repair of distal foot defects. This method has advantages such as the good appearance of the recipient site, strong resistance to infection, and little damage at the donor site. In addition, to avoid the failure of the transplantation, noninvasive instruments such as ultrasonic Doppler, laser Doppler, and infrared thermal detectors are necessary for postoperative observation of the blood circulation in this method.

REFERENCES

1. Akita S, Mitsukawa N, Rikihisa N, et al. Reconstruction of the great toe using a pedicled medial plantar flap with anterograde venous drainage. *Microsurgery*. 2014;34:398–403.
2. Limthongthang R, Eamsobhana P. First dorsal metatarsal artery perforator flap to cover great toe defect. *J Orthop Surg (Hong Kong)*. 2017;25:2309499017739497.
3. O'Hare PM, Leonard AG, Brennen MD. Experience with the tensor fasciae latae free flap. *Br J Plast Surg*. 1983;36:98–104.
4. Mathes SJ, Buchanan RT. Tensor fascia lata: neurosensory musculo-cutaneous free flap. *Br J Plast Surg*. 1979;32:184–187.
5. Agarwal AK, Gupta S, Bhattacharya N, et al. Tensor fascia lata flap reconstruction in groin malignancy. *Singapore Med J*. 2009;50:781–784.
6. Akhtar MS, Khurram MF, Khan AH. Versatility of pedicled tensor fascia lata flap: a useful and reliable technique for reconstruction of different anatomical districts. *Plast Surg Int*. 2014;2014:846082.
7. Wu Z, Song D, Lin J, et al. Anatomic basis of the distally based venocutaneous flap on the medial plantar artery of the hallux with medial plantar vein and nutrient vessels: a cadaveric dissection. *Surg Radiol Anat*. 2015;37:975–981.
8. Bonte A, Bertheuil N, Menez T, et al. Distally based medial plantar flap: a classification of the surgical techniques. *J Foot Ankle Surg*. 2018;57:1230–1237.
9. Ozkan O, Ozkan O, Cinpolat A, et al. Reconstruction of distal lower extremities defect using the free peroneal artery perforator vessel based flap. *Microsurgery*. 2014;34:629–632.
10. Agostini T, Lazzeri D, Spinelli G. Anterolateral thigh flap thinning: techniques and complications. *Ann Plast Surg*. 2014;72:246–252.
11. Graboyes EM, Hornig JD. Evolution of the anterolateral thigh free flap. *Curr Opin Otolaryngol Head Neck Surg*. 2017;25:416–421.
12. Vargas CR, Iorio ML, Lee BT. A systematic review of topical vasodilators for the treatment of intraoperative vasospasm in reconstructive microsurgery. *Plast Reconstr Surg*. 2015;136:411–422.
13. Pršić A, Kiwanuka E, Catterson SA, et al. Anticoagulants and statins as pharmacological agents in free flap surgery: current rationale. *Eplasty*. 2015;15:e51.
14. Lykoudis EG, Seretis K, Lykissas MG. Free sensate medial plantar flap for contralateral plantar forefoot reconstruction with flap reinnervation using end-to-side neurotaphy: a case report and literature review. *Microsurgery*. 2013;33:227–231.
15. Hayashi A, Maruyama Y. Reverse first dorsal metatarsal artery flap for reconstruction of the distal foot. *Ann Plast Surg*. 1993;31:117–122.
16. Butler CE, Chevray P. Retrograde-flow medial plantar island flap reconstruction of distal forefoot, toe, and webspace defects. *Ann Plast Surg*. 2002;49:196–201.
17. Ishikawa K, Isshiki N, Suzuki S, et al. Distally based dorsalis pedis island flap for coverage of the distal portion of the foot. *Br J Plast Surg*. 1987;40:521–525.
18. Sakai S. A distally based island first dorsal metatarsal artery flap for the coverage of a distal plantar defect. *Br J Plast Surg*. 1993;46:480–482.
19. Taylor GA, Hopson WL. The cross-foot flap. *Plast Reconstr Surg*. 1975;55:677–681.
20. Morris AM, Buchan AC. The place of the cross-leg flap in reconstructive surgery of the lower leg and foot: a review of 165 cases. *Br J Plast Surg*. 1978;31:138–142.
21. Harris BN, Bewley AF. Minimizing free flap donor-site morbidity. *Curr Opin Otolaryngol Head Neck Surg*. 2016;24:447–452.