

Congenital scoliosis: a narrative review and proposal of a treatment algorithm

Amer Sebaaly^{1,2}, Mohammad Daher², Bendy Salameh², Ali Ghoul¹, Samuel George¹ and Sami Roukoz^{1,2}

¹Department of Orthopedic Surgery, Hotel Dieu de France Hospital, Beirut, Lebanon

²Faculty of Medicine, Saint Joseph University, Beirut, Lebanon

Correspondence should be addressed to A Sebaaly
Email
amersebaaly@hotmail.com

- Congenital scoliosis (CS) is a spinal deformity resulting from underlying spinal malformations with an incidence of 0.5–1/1000 births.
- CS makes up 10% of scoliotic deformities, of which 25% do not progress, 25% progress mildly and 50% need treatment depending on the age, curve characteristics and magnitude and type of anomaly.
- CS is associated with non-vertebral anomalies (genitourinary, musculoskeletal, cardiac, ribs anomalies, etc.) and intraspinal anomalies (syrinx and tethered cord).
- Imaging should include whole spine X-rays, CT scanner with reconstruction to better delineate the vertebral anomalies and MRI to visualize the neural elements.
- Treatment of CS in the majority of cases is non-surgical and relies on fusion techniques (*in situ* fusion and hemiepiphysiodesis), resection techniques (hemiverterba resection), and growth-friendly techniques (distraction and instrumentation without fusion).

Keywords

- ▶ scoliosis
- ▶ congenital
- ▶ treatment algorithm

EFORT Open Reviews
(2022) 7, 318–327

Introduction

Congenital scoliosis (CS) is a spinal deformity resulting from underlying spinal malformations (1). Its progressions and treatment vary depending on the patient's and the curve's characteristics (1). The causes of these congenital spinal abnormalities are still unclear, but it has been reported that there is a risk of 5–10% of CS for siblings of a patient presenting multiple vertebral anomalies; hence, the speculation about genetic factors (2). This narrative review will shed the light on available evidence regarding this pathology and propose a management algorithm for this rare disease.

Prevalence and etiologies

CS has an incidence of 0.5–1/1000 births worldwide (3, 4, 5, 6, 7). However, many asymptomatic cases do not get diagnosed until a radiograph is taken which incidentally shows a congenital vertebral malformation (CVM) (7). CS makes up 10% of scoliotic deformities (8), of which 25% do not progress, 25% progress mildly and 50% need treatment (9).

On the embryologic level, somites originate from the paraxial mesenchyma in the trilaminar germ disk. They contain precursor cells for structures such as the spine and the striated musculature of the trunk. Somitogenesis

occurs between day 20 and day 35 after conception and disruptions of this mechanism contribute to CVM leading to CS (5). The process involves signaling pathways such as Notch1, FGF, HOX and Wnt (3, 10, 11).

Due to the association of CS with a great number of congenital syndromes such as CHARGE, Klippel–Feil and VACTERL (6, 11, 12, 13, 14), multiple genetic factors are thought to contribute to CS. Cases where one of two monozygotic twins presents CVM while the other is asymptomatic have been seen and have proven the additional influence of environmental factors (9, 10, 15).

The genetic causes are poorly understood but exome sequencing proposed potentially associated genes. It has been shown that a compound inheritance of a null mutation and a hypomorphic allele of the T-box 6 (*TBX6*) gene is responsible of 10% sporadic CS (16). Further studies expanded the mutational spectrum and improved the molecular diagnostic rate (17). In addition, *LFNG* mutations have been linked to CVM, potentially causing a spectrum of presentations which include CS and SCD (spondylocostal dysostosis) (5). An autosomal dominant trait pattern has also been identified for CS in the *FBN1* gene which is also known to cause Marfan syndrome and a series of other syndromes with skeletal dysplasia. *FBN1* could potentially be responsible for monogenic CS (18).

Many other genes are listed in the literature as related to CVM and should be further studied. Other congenital factors associated with CS are connective tissue disorders such as Beals or Marfan syndrome, congenital muscular dystrophies, hypotonia, spinal cord malformations and leg length discrepancy (7).

Environmental causes may play an important role in the pathogenesis of CS. Many expositions were found to contribute to CS including gestational diabetes (6, 19), hypoxia (6) and carbon monoxide exposition during somite formation from cigarette smoke, inducing hypoxia and reactive oxygen species (6, 19). Moreover, prolonged febrile states and hyperthermia exposing the fetus to high temperatures (6, 8, 19) are also responsible for CVM. Same goes for the treatment with antiepileptics, (19) such as valproic acid (6), and with alcohol intake which is related to Klippel–Feil syndrome (7). Environmental toxins such as boric acid (10) and teratogenic factors, cancer and tumors of the spine (11, 20) have also been correlated to CVM. As opposed to idiopathic scoliosis, endocrine factors have not been shown to cause CS (15). CS is also related to rickets and malnutrition as well as vitamin deficiency (10, 21).

There are many non-vertebral anomalies associated with CS, such as genitourinary (22), musculoskeletal (1), cardiac (23) and rib anomalies (24). Thus, it is important to perform renal and cardiac ultrasound/MRI (23, 25), musculoskeletal evaluation (26) and vital capacity screening (because the lung function may be compromised by an association between the rib and vertebral anomalies) (25) in these patients. The presence of these defects will not influence the progression of the vertebral abnormalities, but they might affect the surgical intervention (27).

Diagnosis and classification

The diagnosis should begin by a careful family history review (20). Obstetrical history must also be reviewed along with existing fetal imaging in order to explore any pre-birth vertebral defect (20). Maternal health problems and use of substances and medications should also be noted (20).

Physical examination consists of cognitive assessment (20), height and weight examination, skin evaluation, a neurological exam, and an assessment of pelvic and truncal balance, along with a search for anatomical deformities in the spine and asymmetry in upper and lower limbs (28). A very important part of the evaluation of the CS patient is the assessment of thoracic insufficiency syndrome which is evaluated by the thumb excursion test.

Imaging studies starts with anteroposterior (AP) and lateral plain X-rays to measure the curve's Cobb angle in order to evaluate the CS and study its progression

(Fig. 1) (19). CT scans and 3D CTs are used to evaluate the anatomy in order to find bony abnormalities and study if thoracic insufficiency syndrome (19) is present. Intraspinal anomalies are frequently associated with CS with the most common abnormality being syrinx, diastematomyelia and tethered cord (Fig. 2) (23). They are more frequent in patients with failures of segmentations with a preponderance in women (29) and also in patients with rib anomalies (24). Due to this high incidence rate, MRIs must be performed on CS patients prior to any surgical intervention (23). Tethered cord should be addressed before scoliosis surgical correction (Fig. 2) (1). Indicators of these abnormalities can be neurocutaneous markers or reflex anomalies (1).

The vertebral anomalies may be isolated or in association with other syndromes like the VACTERL syndrome (30). In order to classify all of the different vertebral abnormalities, they are first sorted into scoliosis caused by longitudinal imbalance and scoliosis caused by rotational imbalance (31). The latter is divided into spinal traction anomalies, spinal pushing anomalies and mixed anomalies (31). The longitudinal imbalance group is divided into four groups which are scoliosis caused by: failure of segmentation, failure of formation, mixed defects and complex unclassifiable defects (27, 32, 33). Failure of formation

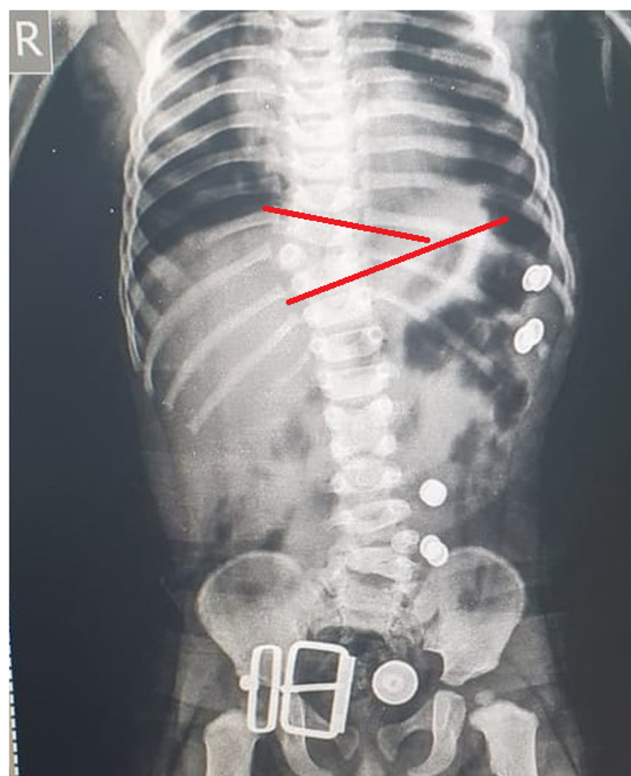


Figure 1 Full spine X-ray of a patient with hemivertebra and a 35° scoliosis measured by the Cobb technique.

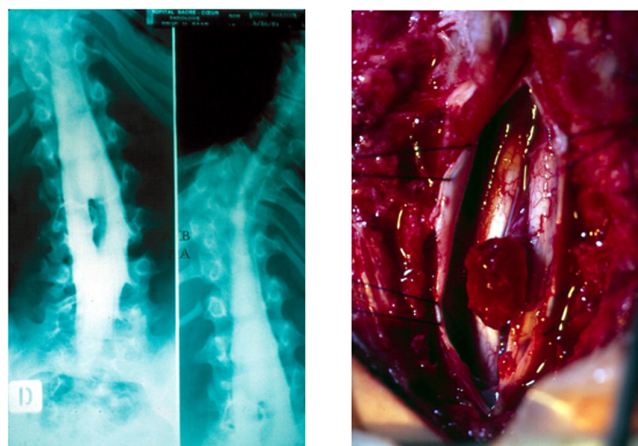


Figure 2

Myelogram of a patient with CS showing doubled dural sac. Intraoperative finding of diastatomyelia with a bony spur.

consists of wedged vertebra, hemivertebra with different levels of segmentation and hemivertebra body (Fig. 3) (31). Failures of segmentation consists of vertebral block or unilateral longitudinal bar (31) which may act as a growth tether (25). Hemimetameric shift is the resulting balance due to the presence of two contralateral hemivertebras set apart by one normal vertebra (Fig. 4) (1). These different anomalies usually are on the apex of the curve with the hemivertebra being the most frequent (29).

Natural history

Progression is related to the asymmetry of growth comparing the convex and concave sides of the curve and this development occurs more frequently on the convex side (34). As a matter of fact, 50% of the curves progress quickly, whereas 25% progress slowly and the remaining 25% do not progress at all (33). Progression occurs in the ‘normal’ disc spaces, whereas the fused segments do not progress. This progression speed depends on the age of the patient, the location of the apex, the type of the anomaly and the curves' characteristics (1, 33).

1. Age: The progression is fastest before the age of 5 and in the growth spurt during adolescence (age

between 11 and 14) (19). Curves that are clinically present before the age of 10 have a poor prognosis due to their growth potential (27) and if deformities are evident during the first year of life, then the worst prognosis must be predicted (25).

2. Location of the apex: Curves in the upper thoracic area have the slowest progression, whereas in the midthoracic area it is more rapid and the fastest progression is in the thoracolumbar region (35) and this may be a consequence of the presence of the thoracic cage and/or the difference of pressure in these two locations.
3. Type of the anomaly: The worst prognosis is the association of unilateral bar with contralateral hemivertebra, whereas the complete block vertebra/incarcerated hemivertebra is the most benign for progression (1). A completely segmented hemivertebra surrounded by healthy disc spaces predict a higher progression (1), and if there is more than one hemivertebra present, progression rate may be faster (34). In hemimetameric shifts, progression is also possible (36), mostly in the thoracolumbar region (37). Finally, a bar or a fused rib can simulate a tether and accelerate the curve progression (25).
4. Curves' characteristics: the presence of two unilateral curves causes a deep malformation, whereas contralateral curves may contribute to balance the spine (27). If the curve's Cobb angle is less or equal to 25°, then progression is unlikely (20). Regarding the unilateral unsegmented bar, the progression is also influenced by the bar's extent (35).

Imaging and follow-up

AP and lateral plain X-rays are the gold standard modality for confirming the diagnosis, classifying the anomaly and following up on the curve progression (22). Radiographs can be taken supine if patient is diagnosed before walking age. The Cobb–Lipmann technique used for measuring the curve severity in idiopathic scoliosis is the gold standard in CS for angle evaluation (22). It consists of measuring the angle between the lines drawn from

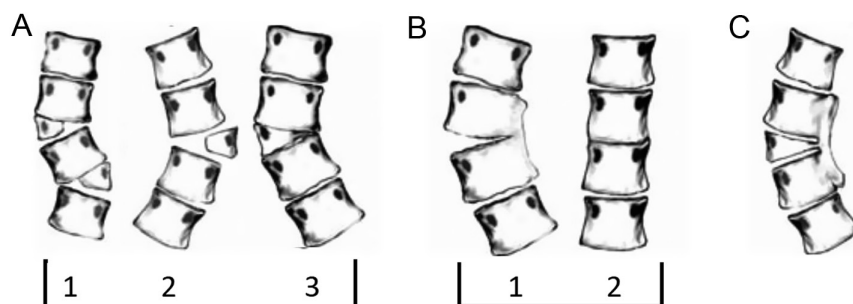


Figure 3

Drawing showing the types of vertebral anomalies: (A) Failure of formation (A1: semisegmented; A2: fully segmented; A3: wedge vertebra), (B) failure of segmentation (B1: Bar; B2: Vertebral block) and (C) mixed deformities.

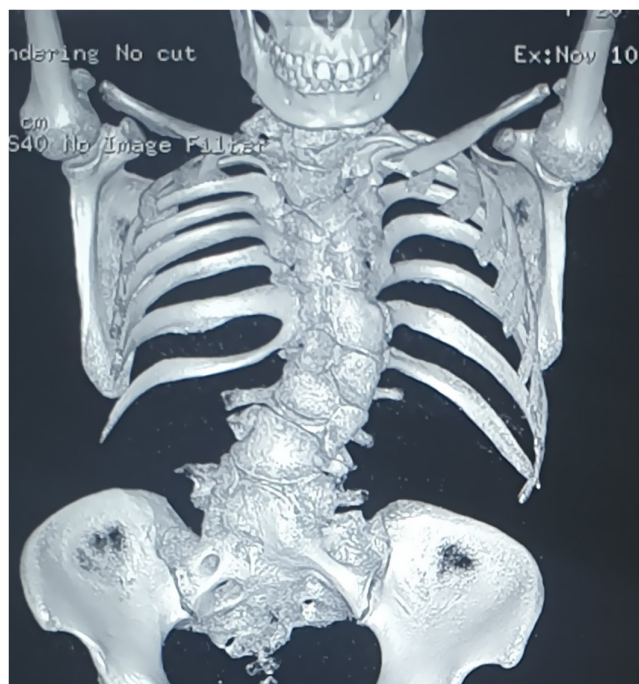


Figure 4

3D reconstruction of a CT scanner of a 21-year-old female showing a congenital scoliosis with several hemivertebrae and vertebral blocs and bars. Nonetheless, the patient has a good coronal balance thanks to hemimetameric shift.

the upper endplate of the upper vertebrae and lower endplate of the lower vertebrae (Fig. 1) (22). The pedicle method proposed in skeletally immature patients was not found to be more accurate (26). Since maximum spinal growth occurs in the first 3 years and during puberty, sequential weight bearing radiographs every 6 months are recommended during these two phases to monitor curve progression (33).

Plain radiographs can be difficult to interpret with superimposed structures and the patients' small size. CT scan's clinical use is limited by cost, radiation exposure and postural changes on curve (38). However, a 3D reconstruction is essential in preoperative planning to assess posterior anatomy of the spine and uncover up to 50% of additional abnormalities unexplored on plain radiographs (Fig. 4) (39). Several studies showed that the use of a 3D CT can change the classification of the defect, specifically in hemivertebra defects; thus altering the clinician's course of action. Therefore, we recommend the use of 3D CT scan to evaluate failure of formation anomalies prior to instrumentation or osteotomies of the spine. Thus, CT is best used in complex deformities in which X-rays are difficult to interpret and for preoperative planning and not for follow-up. Finally, lung volume calculations can be obtained and correlated to lung function in patients presenting with CS (40).

Spinal dysraphism is associated with CS with a varying prevalence of 17–37% regardless of neurological symptoms on physical examination (41). When a corrective surgery is planned or in the presence of anomalies on neurological examinations, MRI is recommended to screen for common forms of dysraphism: diastematomyelia, syringomyelia, tethered cord, dural bands, cysts and tight filum terminale (42).

CS can be associated with up to 20% of urinary tract malformations (43). This warrants a renal ultrasound to every patient diagnosed with CS regardless of symptoms at presentation. If patient is undergoing a spine MRI, the renal ultrasound may be replaced with abdominal MRI for urinary tract evaluation (44). Also, a systematic cardiac assessment should be performed to all patients diagnosed with CS, with echocardiography if any anomaly is suspected or routinely before a programmed procedure (30).

Non-surgical management

CS englobes an array of abnormalities with varying patterns of presentations and progression. The complexity of the disease makes its management difficult and variable. The ultimate goal of treatment whether its observation or surgery should be preventing curve progression while achieving spinal balance. In order to achieve these goals, and as mentioned above, the age at presentation, deformity location and nature are taken into consideration.

The term 'congenital' can be misleading as deformities may be present at birth but abnormal curvature may or may not be evident on physical examination (20). The time of presentation is important since curve progression is linked to spinal growth (33). Therefore, an abnormal curvature presenting at a young age is more likely to progress and should be managed until after skeletal maturity.

As previously said, over 70% of CS progresses aggressively with a need for surgery. However, it is known that certain deformities such as bloc vertebra and wedged hemivertebra can be managed conservatively. Patient should be followed up frequently in his first 5 years of life (every 6 months till age of 4 then once a year before puberty) and during pubertal growth (every 6 months). Congenital curves are usually rigid and inflexible which makes primary bracing concealed. Bracing could be advised for compensatory curves.

After balancing the above factors, the ideal indications for corrective or prophylactic surgery are: unilateral bar with or without contralateral hemivertebra, a curve magnitude more than 40° and deformities showing aggressive progression presenting before 5 years of age.

Surgical management

Four surgical principles are applied in CS: fusion with or without instrumentation, convex hemiepiphysiodesis, vertebrectomy in case of hemivertebra and rib distraction (45).

In situ fusion

In situ fusion is generally done by a posterior approach. Exposure must be performed with caution because failure to recognize posterior laminar subtle defect can lead to neurological injuries. After exposure, imaging radiograph confirms the abnormal vertebra because the hemivertebra or bar seen anteriorly on X-rays may not have corresponding or easily recognizable posterior elements with the fusion extending one level above and below the deformity with postoperative bracing (46). Correction with fusion is limited to 10° extending to 15° with instrumentation (47). Instrumentation can decrease bracing time and increase correction pre operatively with the same neurological complication rate postoperatively (48). Ruf *et al.* showed the possible use of pedicle screws in a pediatric population with 1 year of age (49). However, correction is lost over time due to fusion mass bending phenomenon and pseudarthrosis (50). An isolated posterior approach conserves anterior growth potential leading to vertebral rotation progression and crankshaft phenomenon (50, 51). Kesling *et al.* showed that 15% of 54 patients under the age of 10 years, who underwent posterior *in situ* spinal fusion had crankshaft phenomenon. They reported that it was also positively correlated with earlier surgery and curves greater than 50° (52). An anterior release with discectomies can provide a more solid arthrodesis and avoid crankshaft phenomenon (51). Multi-level arthrodesis at a young age is known to limit lung development and decrease vital capacity (48). *In situ* fusion is recommended as a prophylactic procedure at a younger age for progressive non-deforming curves with less than 40° angles, extending along a short segment.

Convex hemiepiphysiodesis

The rationale behind the procedure is arresting the growth potential of the convex side of the curve. The same principle commonly employed for deformity of growing long bones is applied: convex hemiepiphysiodesis slows convex side growth, while concave curve still grows, allowing for safe progressive deformity. The surgeon should remove the lateral halves of the disks and fuse the vertebrae together anteriorly and posteriorly (53). The condition for this method is the convex side having a growth potential (a patient young enough for significant correction to occur (age <6 years)). This means the procedure is pointless with a unilateral block vertebra deformity and perfect

for a fully segmented hemivertebra anomaly (53). The discrepancy of growth potential created between the concave and convex side should reestablish the balance in the deformed segment. Ideally, this technique extends one level above and below the deformity without exposing the concave side of the curve. Some studies showed this technique to provide 15° of correction, while other studies showed no correction (53, 54). Uzumcugil *et al.* showed the unpredictable character of the procedure with correction rates varying from 20% to 70% of the cases (55). Rizkallah *et al.* showed promising results using this method with an overall mean correction of the Cobb angle by 35.47% with a better correction rate in patients less than 3 years of age having an isolated hemivertebra with curves less than 35° (56) (Fig. 5). Walhout *et al.* reviewed the ideal indications for an hemiepiphysiodesis: fully segmented hemivertebra, age less than 5 years, a short segment of a maximum of five vertebrae and a less than 70° curve without a major kyphotic component (57).

Hemivertebra excision

The method consists of removing the hemivertebra and adjacent disks with its respective lamina and pedicles in the event of severe truncal imbalance (58). An excision through a posterior approach or sequential posterior and anterior approach is indicated (58). Studies showed a superior curve correction of this method compared to *in situ* fusion and hemiepiphysiodesis (58). Both approaches have similar neurologic complications with varying rate of 10–20% (58). The posterior approach requires more expertise but presents with shorter surgery time and hospital stay (59). The spinal cord in the lumbar region is less susceptible to manipulation which makes this procedure more convenient in the thoracolumbar and lumbar region (60). Several studies showed correction rates of up to 40° (61). Hemivertebra excision is recommended in the case of a hemivertebra preferably in the lumbar region with a curve more than 40° (Fig. 6).

Rib distraction

When vertebral anomalies are associated with multiple rib fusion or absence, thoracic insufficiency syndrome can develop (62). Halting of the lung growth due to loss of thorax compliance can lead to respiratory complications and eventually death (62). To overcome these complications even before the appearance of thorax insufficiency syndrome, rib distraction can be used (62).

The procedure mainly consists of multiple open wedge thoracotomies followed by insertion of vertical expendable prosthetic titanium rib devices (63). The devices are hooked around the second and third rib and caudally around the last ribs, in the lumbar spine, sacral spine or pelvis. Distraction is then performed

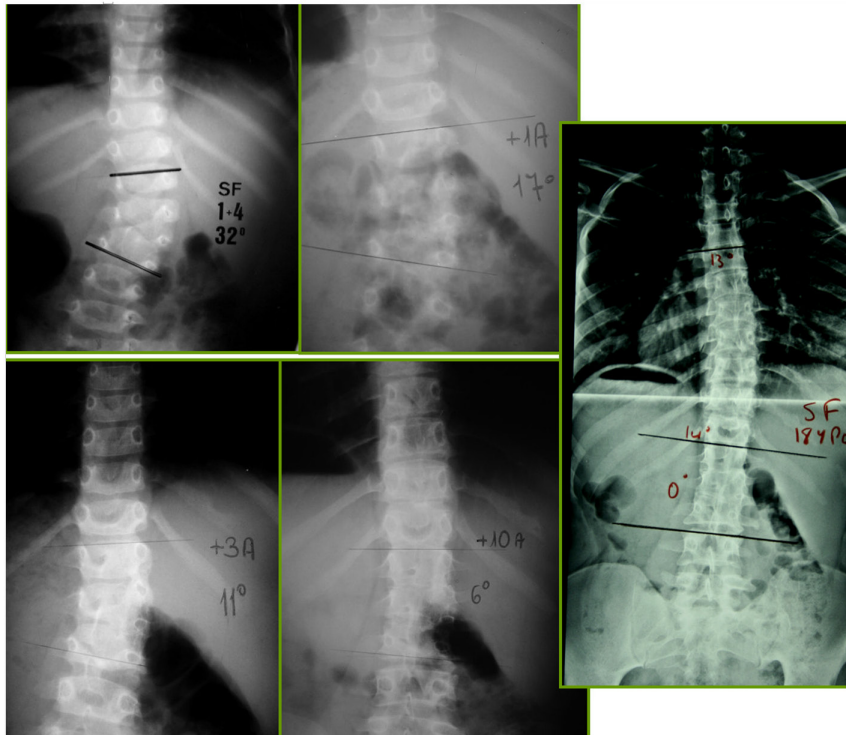


Figure 5

A/P dorso-lumbar X-rays of a patient with L3 hemivertebra operated of anterior and posterior convex hemiepiphysiodesis in the preoperative setting and at 1 year, 3 years, 10 years and 18 years postoperatively.

along the concave side of the curve at an interval of 5–6 months preventing curvature progression (63). Several studies showed the improvement of truncal balance, Cobb angle and tilting of the spine with the use of vertical expandable prosthetic titanium rib (VEPTR) (64, 65, 66). However, the pulmonary results are controversial with chest wall compliance declining

postoperatively in contrast to vital capacity and lung volumes improving (67).

The procedure presents with high rate of neurological complications of 7% with brachial plexus palsy being the most common (68). Rib and lamina fractures, infection and lesions are also common events (68). Device ossification can be seen postoperatively which leads to severe loss

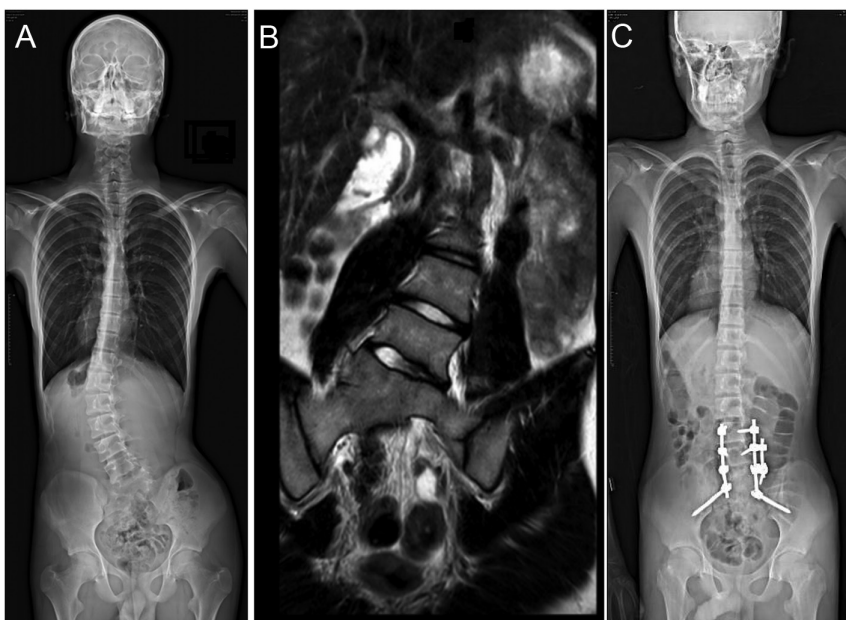


Figure 6

(A) Full Spine X-ray showing a lumbar scoliosis with a Cobb angle of 45°. (B) Coronal T2-weighted MRI showing a right hemivertebra (fully segmented with the disc above and non-segmented below). (C) Full spine X-ray showing 90% correction of the scoliosis with the hemivertebra resection and L4 to iliac fusion.

of chest compliance (68). The use of this procedure may remain as a last resort to thoracic complications in CS not manageable by more conventional methods.

Instrumentation without fusion

The rationale behind this technique is to preserve the growth potential of the spine while limiting the curve progression (69). The ultimate aim is gaining spinal length in order to have normal pulmonary function. This technique is used for long segments deformities. Rods are attached by interconnectors and fixed above and below the curve by hooks and local fusion (69). Lengthening occurs every 4–6 months until definitive fusion is decided (69).

Dual rod technique is recommended in place of single-rod technique for being a more solid construct and superior at correction (70). Studies showed that growing rods can improve Cobb angle with a varying rate of 20–50% (71, 72). In terms of growth potential, it is established that repeated lengthening can halt growth due to auto fusion phenomenon (73, 74). In addition to growth inhibition, this technique inhibits several implant-related complications with rates up to 50% in some studies (73, 74). Another problem with growing rods are frequent procedures and radiation exposure due to repeated X-rays (75, 76). Noninvasive alternatives have been proposed, such as magnetic lengthening with not enough studies concerning long-term results (75, 76). Ultrasound surveillance have also been proposed to monitor lengthening.

Corrective osteotomies

Vertebral column resection involves removing segments of the spine including the body of the vertebra and the posterior elements, which include the lamina, transverse process and ribs with instrumentation (77). This can all be done from a posterior or combined anterior and

posterior approach (77). This salvage procedure is indicated in case of rigid residual curve, neurological deficits and failure of other conventional methods (78). The reconstructive osteotomy aims to restore truncal balance by shortening the spine and removing previous fusion masses. A case series showed an average operation time of 546 min, average blood loss of 1650 mL and a correction rate in congenital deformities of 46% of the Cobb angle (79). Other studies showed a correction rate of 62 and 8% neurological complications and 2% spinal cord injury (80).

Treatment algorithm

Based on this review, we propose the following algorithm for the treatment of CS (Fig. 7). The main criteria for the selection of optimal treatment are the patient’s age, the Cobb angle magnitude and the type of malformation. Although VEPTR procedures may be used in patients as early as 6 months and up to skeletal maturity, it is better to wait until age >3 years old for stronger fixation points on the ribs. The only exception to use VEPTR thoracic expansion technique in children below 2 years of age are: CS with absence or fused ribs (type II) and especially if the deformity combines with thoracic insufficient syndrome (TIS).

In summary of this algorithm, closer follow-up should be done at younger age, growing techniques should be preferred until skeletal maturity and definitive fusion techniques should be done after the age of 10 years.

Conclusion

In conclusion, CS is a wide spectrum disease. It could range from a balanced disease with a very low risk of progression to an aggressive and rapidly progressive one. One should keep in mind the high rate of intracanal anomalies associated with CS. Non operative treatment

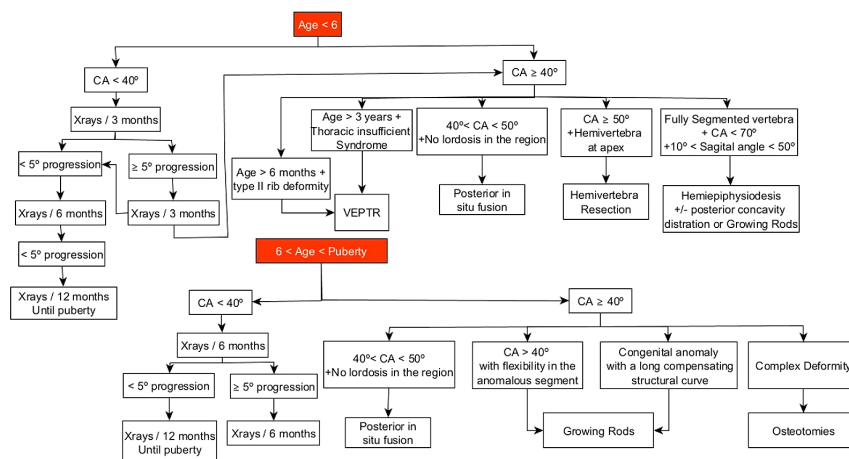


Figure 7 Proposed treatment algorithm for the treatment of congenital scoliosis. CA, Cobb angle. VEPTR, vertical expandable prosthetic titanium rib.

usually fails in this group of patient and surgical treatment should be tailored according to the age, curve magnitude and malformation type.

ICMJE Conflict of Interest Statement

A S reports receiving payment for lectures from Medtronic Spine. All other authors declare that there is no conflict of interest that could be perceived as prejudicing the impartiality of this review.

Funding Statement

This work did not receive any specific grant from any funding agency in the public, commercial, or not-for-profit sector.

References

- Pahys JM & Guille JT. What's new in congenital scoliosis? *Journal of Pediatric Orthopedics* 2018 **38** e172–e179. (<https://doi.org/10.1097/BPO.0000000000000922>)
- Wynne-Davies R. Congenital vertebral anomalies: aetiology and relationship to spina bifida cystica. *Journal of Medical Genetics* 1975 **12** 280–288. (<https://doi.org/10.1136/jmg.12.3.280>)
- Giampietro PF, Pourquie O, Raggio C, Ikegawa S, Turnpenny PD, Gray R, Dunwoodie SL, Gurnett CA, Alman B, Cheung K, et al. Summary of the first inaugural joint meeting of the International Consortium for scoliosis genetics and the International Consortium for vertebral anomalies and scoliosis, March 16–18, 2017, Dallas, Texas. *American Journal of Medical Genetics Part A* 2018 **176** 253–256.
- Debnath UK, Goel V, Harshavardhana N & Webb JK. Congenital scoliosis – quo vadis. *Indian Journal of Orthopaedics* 2010 **44** 137–147. (<https://doi.org/10.4103/0019-5413.61997>)
- Takeda K, Kou I, Mizumoto S, Yamada S, Kawakami N, Nakajima M, Otomo N, Ogura Y, Miyake N, Matsumoto N, et al. Screening of known disease genes in congenital scoliosis. *Molecular Genetics and Genomic Medicine* 2018 **6** 966–974. (<https://doi.org/10.1002/mgg3.466>)
- Giampietro PF, Raggio CL, Blank RD, McCarty C, Broeckel U & Pickart MA. Clinical, genetic and environmental factors associated with congenital vertebral malformations. *Molecular Syndromology* 2013 **4** 94–105. (<https://doi.org/10.1159/000345329>)
- Brand MC Examination of the Newborn With Congenital Scoliosis *Advances in neonatal care* 2008 **8** 265–273. (<https://doi.org/10.1097/01.ANC.0000338016.03040.6b>)
- Mackel CE, Jada A, Samdani AF, Stephen JH, Bennett JT, Baaj AA & Hwang SW. A comprehensive review of the diagnosis and management of congenital scoliosis. *Child's Nervous System* 2018 **34** 2155–2171. (<https://doi.org/10.1007/s00381-018-3915-6>)
- Cho W, Shepard N & Arlet V. The etiology of congenital scoliosis: genetic vs. environmental – a report of three monozygotic twin cases. *European Spine Journal* 2018 **27** 533–537. (<https://doi.org/10.1007/s00586-018-5604-2>)
- Hensinger RN. Congenital scoliosis: etiology and associations. *Spine* 2009 **34** 1745–1750. (<https://doi.org/10.1097/BRS.0b013e3181abf69e>)
- Giampietro PF, Dunwoodie SL, Kusumi K, Pourquie O, Tassy O, Offiah AC, Cornier AS, Alman BA, Blank RD, Raggio CL, et al. Progress in the understanding of the genetic etiology of vertebral segmentation disorders in humans. *Annals of the New York Academy of Sciences* 2009 **1151** 38–67. (<https://doi.org/10.1111/j.1749-6632.2008.03452.x>)
- Samartzis D, Kalluri P, Herman J, Lubicky JP & Shen FH. Cervical scoliosis in the klippel-feil patient. *Spine* 2011 **36** E1501–E1508. (<https://doi.org/10.1097/BRS.0b013e31823145e4>)
- Passias PG, Poorman GW, Jalai CM, Diebo BG, Vira S, Horn SR, Baker JF, Shenoy K, Hasan S, Buza J, et al. Incidence of congenital spinal abnormalities among pediatric patients and their association with scoliosis and systemic anomalies. *Journal of Pediatric Orthopedics* 2019 **39** e608–e613. (<https://doi.org/10.1097/BPO.0000000000001066>)
- Giampietro PF, Dunwoodie SL, Kusumi K, Pourquie O, Tassy O, Offi AC, Cornier AS, Alman BA, Blank RD, Raggio CL, et al. Molecular diagnosis of vertebral segmentation disorders in humans. *Expert Opinion on Medical Diagnostics* 2008 **2** 1107–1121. (<https://doi.org/10.1517/17530059.2.10.1107>)
- Farley FA. Etiology of congenital scoliosis. *Seminars in Spine Surgery* 2010 **22** 110–112. (<https://doi.org/10.1053/j.semss.2010.03.001>)
- Xie Y, Li Z, Tang H, Li M & Guan Z. Posterior C1 lateral mass and C2 pedicle screw internal fixation for atlantoaxial instability. *Journal of Clinical Neuroscience* 2009 **16** 1592–1594. (<https://doi.org/10.1016/j.jocn.2009.03.026>)
- Chen W, Lin J, Wang L, Li X, Zhao S, Liu J, Akdemir ZC, Zhao Y, Du R, Ye Y, et al. TBX6 missense variants expand the mutational spectrum in a non-Mendelian inheritance disease. *Human Mutation* 2019 **41** 182–195.
- Lin M, Zhao S, Liu G, Huang Y, Yu C, Zhao Y, Wang L, Zhang Y, Yan Z, Wang S, et al. Identification of novel FBN1 variations implicated in congenital scoliosis. *Journal of Human Genetics* 2020 **65** 221–230.
- Burnei G, Gavrilu S, Vlad C, Georgescu I, Ghita RA, Dughilă C, Japie EM & Onilă A. Congenital scoliosis: an up-to-date. *Journal of Medicine and Life* 2015 **8** 388–397.
- Brand MC. Examination of the newborn with congenital scoliosis: focus on the physical. *Advances in Neonatal Care* 2008 **8** 265–273; quiz 274. (<https://doi.org/10.1097/01.ANC.0000338016.03040.6b>)
- Chen C, Tan H, Bi J, Li Z, Rong T, Lin Y, Sun L, Li X & Shen J. Identification of competing endogenous RNA regulatory networks in vitamin A deficiency-induced congenital scoliosis by transcriptome sequencing analysis. *Cellular Physiology and Biochemistry* 2018 **48** 2134–2146.
- Van Goethem J, Van Campenhout A, van den Hauwe L & Parizel PM. Scoliosis. *Neuroimaging Clinics of North America* 2007 **17** 105–115. (<https://doi.org/10.1016/j.nic.2006.12.001>)
- Furdock R, Brouillet K & Luhmann SJ. Organ system anomalies associated with congenital scoliosis: a retrospective study of 305 patients. *Journal of Pediatric Orthopedics* 2019 **39** e190–e194. (<https://doi.org/10.1097/BPO.0000000000001279>)
- Xue X, Shen J, Zhang J, Zhao H, Li S, Zhao Y, Liang J, Qiu G & Weng X. Rib deformities in congenital scoliosis. *Spine* 2013 **38** E1656–E1661. (<https://doi.org/10.1097/BRS.0000000000000008>)
- Batra S & Ahuja S. Congenital scoliosis: management and future directions. *Acta Orthopaedica Belgica* 2008 **74** 147–160.
- Mehta SS, Modi HN, Srinivasalu S, Chen T, Suh SW, Yang JH & Song HR. Interobserver and intraobserver reliability of Cobb angle measurement: endplate versus pedicle as bony landmarks for measurement: a statistical analysis. *Journal of Pediatric Orthopedics* 2009 **29** 749–754. (<https://doi.org/10.1097/BPO.0b013e3181b72550>)

- 27. Marks DS, Qaimkhani SA, Qaimkhani SA & Orth F.** The natural history of congenital scoliosis and kyphosis. *Spine* 2009 **34** 1751–1755. (<https://doi.org/10.1097/BRS.0b013e3181af1caf>)
- 28. Batra PS, Seiden AM & Smith TL.** Surgical management of adult inferior turbinate hypertrophy: a systematic review of the evidence. *Laryngoscope* 2009 **119** 1819–1827. (<https://doi.org/10.1002/lary.20544>)
- 29. Gupta N, S R, G B & Shetty A.** Vertebral and intraspinal anomalies in Indian population with congenital scoliosis: a study of 119 consecutive patients. *Asian Spine Journal* 2016 **10** 276–281. (<https://doi.org/10.4184/asj.2016.10.2.276>)
- 30. Basu PS, Elsebaie H & Noordeen MHH.** Congenital spinal deformity: a comprehensive assessment at presentation. *Spine* 2002 **27** 2255–2259. (<https://doi.org/10.1097/00007632-200210150-00014>)
- 31. Ghiță RA, Georgescu I, Muntean ML, Hamei Ş, Japie EM, Dughilă C & Țiripa I.** Burnei-Gavriliu classification of congenital scoliosis. *Journal of Medicine and Life* 2015 **8** 239–244.
- 32. Kaspiris A, Grivas TB, Weiss HR & Turnbull D.** Surgical and conservative treatment of patients with congenital scoliosis: α search for long-term results. *Scoliosis* 2011 **6** 12. (<https://doi.org/10.1186/1748-7161-6-12>)
- 33. McMaster MJ & Singh H.** Natural history of congenital kyphosis and kyphoscoliosis: a study of one hundred and twelve patients. *Journal of Bone and Joint Surgery A* 1999 **81** 1367–1383.
- 34. Arlet V, Odent T & Aebi M.** Congenital scoliosis. *European Spine Journal* 2003 **12** 456–463. (<https://doi.org/10.1007/s00586-003-0555-6>)
- 35. McMaster MJ & McMaster ME.** Prognosis for congenital scoliosis due to a unilateral failure of vertebral segmentation. *Journal of Bone and Joint Surgery A* 2013 **95** 972–979.
- 36. Shawen SB, Belmont PJ, Kuklo TR, Owens BD, Taylor KF, Kruse R & Polly DW.** Hemimetameric segmental shift: a case series and review. *Spine* 2002 **27** E539–E544. (<https://doi.org/10.1097/00007632-200212150-00025>)
- 37. Kuhns JG & Hormell RS.** Management of congenital scoliosis; review of one hundred seventy cases. *AMA Archives of Surgery* 1952 **65** 250–263. (<https://doi.org/10.1001/archsurg.1952.01260020263007>)
- 38. Newton PO, Hahn GW, Fricka KB & Wenger DR.** Utility of three-dimensional and multiplanar reformatted computed tomography for evaluation of pediatric congenital spine abnormalities. *Spine* 2002 **27** 844–850. (<https://doi.org/10.1097/00007632-200204150-00012>)
- 39. Bush CH & Kalen V.** Three-dimensional computed tomography in the assessment of congenital scoliosis. *Skeletal Radiology* 1999 **28** 632–637. (<https://doi.org/10.1007/s002560050565>)
- 40. Gollogly S, Smith JT, White SK, Firth S & White K.** The volume of lung parenchyma as a function of age: a review of 1050 normal CT scans of the chest with three-dimensional volumetric reconstruction of the pulmonary system. *Spine* 2004 **29** 2061–2066. (<https://doi.org/10.1097/01.brs.0000140779.22741.33>)
- 41. Prahinski JR, Polly DW, McHale KA & Ellenbogen RG.** Occult intraspinal anomalies in congenital scoliosis. *Journal of Pediatric Orthopedics* 2000 **20** 59–63. (<https://doi.org/10.1097/01241398-200001000-00013>)
- 42. Suh SW, Sarwark JF, Vora A & Huang BK.** Evaluating congenital spine deformities for intraspinal anomalies with magnetic resonance imaging. *Journal of Pediatric Orthopedics* 2001 **21** 525–531. (<https://doi.org/10.1097/01241398-200107000-00021>)
- 43. MacEwen GD, Winter RB, Hardy JH & Sherk HH.** Evaluation of kidney anomalies in congenital scoliosis. 1972. *Clinical Orthopaedics and Related Research* 2005 **434** 4–7. (<https://doi.org/10.1097/00003086-200505000-00002>)
- 44. Drvaric DM, Ruderman RJ, Conrad RW, Grossman H, Webster GD & Schmitt EW.** Congenital scoliosis and urinary tract abnormalities: are intravenous pyelograms necessary? *Journal of Pediatric Orthopedics* 1987 **7** 441–443. (<https://doi.org/10.1097/01241398-198707000-00012>)
- 45. Dubouset J, Zeller R, Miladi L, Wicart P & Mascard E.** Orthopedic treatment of spinal deformities in infancy and early childhood. *Revue de Chirurgie Orthopedique et Reparatrice de l'Appareil Moteur* 2006 **92** 73–82. ([https://doi.org/10.1016/s0035-1040\(06\)75679-3](https://doi.org/10.1016/s0035-1040(06)75679-3))
- 46. Hall JE, Herndon WA & Levine CR.** Surgical treatment of congenital scoliosis with or without Harrington instrumentation. *Journal of Bone and Joint Surgery* 1981 **63** 608–619. (<https://doi.org/10.2106/00004623-198163040-00011>)
- 47. Winter RB & Lonstein JE.** Congenital scoliosis with posterior spinal arthrodesis T2–L3 at age 3 years with 41-year follow-up: a case report. *Spine* 1999 **24** 194–197. (<https://doi.org/10.1097/00007632-199901150-00023>)
- 48. Winter RB, Moe JH & Lonstein JE.** Posterior spinal arthrodesis for congenital scoliosis. An analysis of the cases of two hundred and ninety patients, five to nineteen years old. *Journal of Bone and Joint Surgery: American Volume* 1984 **66** 1188–1197. (<https://doi.org/10.2106/00004623-198466080-00006>)
- 49. Ruf M & Harms J.** Pedicle screws in 1- and 2-year-old children: technique, complications, and effect on further growth. *Spine* 2002 **27** E460–E466. (<https://doi.org/10.1097/00007632-200211010-00019>)
- 50. Winter RB & Moe JH.** The results of spinal arthrodesis for congenital spinal deformity in patients younger than five years old. *Journal of Bone and Joint Surgery: American Volume* 1982 **64** 419–432. (<https://doi.org/10.2106/00004623-198264030-00013>)
- 51. Terek RM, Wehner J & Lubicky JP.** Crankshaft phenomenon in congenital scoliosis: a preliminary report. *Journal of Pediatric Orthopedics* 1991 **11** 527–532. (<https://doi.org/10.1097/01241398-199107000-00021>)
- 52. Kesling KL, Lonstein JE, Denis F, Perra JH, Schwender JD, Transfeldt EE & Winter RB.** The crankshaft phenomenon after posterior spinal arthrodesis for congenital scoliosis: a review of 54 patients. *Spine* 2003 **28** 267–271. (<https://doi.org/10.1097/01.BRS.0000042252.25531.A4>)
- 53. Andrew T & Piggott H.** Growth arrest for progressive scoliosis. Combined anterior and posterior fusion of the convexity. *Journal of Bone and Joint Surgery: British Volume* 1985 **67** 193–197. (<https://doi.org/10.1302/0301-620X.67B2.3980524>)
- 54. Marks DS, Sayampanathan SR, Thompson AG & Piggott H.** Long-term results of convex epiphysiodesis for congenital scoliosis. *European Spine Journal* 1995 **4** 296–301. (<https://doi.org/10.1007/BF00301039>)
- 55. Uzumcugil A, Cil A, Yazici M, Acaroglu E, Alanay A, Aksoy C & Surat A.** Convex growth arrest in the treatment of congenital spinal deformities, revisited. *Journal of Pediatric Orthopedics* 2004 **24** 658–666. (<https://doi.org/10.1097/00004694-200411000-00013>)
- 56. Rizkallah M, Sebaaly A, Kharrat K & Kreichati G.** Is there still a place for convex hemiepiphysiodesis in congenital scoliosis in young children? A long-term follow-up. *Global Spine Journal* 2020 **10** 406–411. (<https://doi.org/10.1177/2192568219858305>)
- 57. Walhout RJ, van Rhijn LW & Pruijs JEH.** Hemi-epiphysiodesis for unclassified congenital scoliosis: immediate results and mid-term follow-up. *European Spine Journal* 2002 **11** 543–549. (<https://doi.org/10.1007/s00586-002-0395-9>)

- 58. Holte DC, Winter RB, Lonstein JE & Denis F.** Excision of hemivertebrae and wedge resection in the treatment of congenital scoliosis. *Journal of Bone and Joint Surgery A* 1995 **77** 159–171.
- 59. Li Y, Wang G, Jiang Z, Cui X, Li T, Liu X, Zhang W & Sun J.** One-stage posterior excision of lumbosacral hemivertebrae: retrospective study of case series and literature review. *Medicine* 2017 **96** e8393. (<https://doi.org/10.1097/MD.0000000000008393>)
- 60. Bollini G, Docquier PL, Launay F, Viehweger E & Jouve JL.** Résultats à maturité osseuse après résection d'hémivertèbres par double abord. *Revue de Chirurgie Orthopédique et Réparatrice de l'Appareil Moteur* 2005 **91** 709–718. ([https://doi.org/10.1016/s0035-1040\(05\)84481-2](https://doi.org/10.1016/s0035-1040(05)84481-2))
- 61. Bollini G, Jouve JL, Cottalorda J, Petit P, Paniel M & Jacquemier M.** Aneurysmal bone cyst in children: analysis of twenty-seven patients. *Journal of Pediatric Orthopedics: Part B* 1998 **7** 274–285. (<https://doi.org/10.1097/01202412-199810000-00005>)
- 62. Campbell RM, Smith MD, Mayes TC, Mangos JA, Willey-Courand DB, Kose N, Pinero RF, Alder ME, Duong HL & Surber JL.** The characteristics of thoracic insufficiency syndrome associated with fused ribs and congenital scoliosis. *Journal of Bone and Joint Surgery: American Volume* 2003 **85** 399–408. (<https://doi.org/10.2106/00004623-200303000-00001>)
- 63. Motoyama EK, Yang CI & Deeney VF.** Thoracic malformation with early-onset scoliosis: effect of serial VEPTR expansion thoracoplasty on lung growth and function in children. *Paediatric Respiratory Reviews* 2009 **10** 12–17. (<https://doi.org/10.1016/j.prrv.2008.10.004>)
- 64. Samdani AF, Ranade A, Dolch HJ, Williams R, St. Hilaire T, Cahill P & Betz RR.** Bilateral use of the vertical expandable prosthetic titanium rib attached to the pelvis: a novel treatment for scoliosis in the growing spine. *Journal of Neurosurgery: Spine* 2009 **10** 287–292. (<https://doi.org/10.3171/2008.12.SPINE08427>)
- 65. El-Hawary R, Kadhim M, Vitale M, Smith J, Samdani A, Flynn JM & Children's Spine Study Group.** VEPTR implantation to treat children with early-onset scoliosis without rib abnormalities: early results from a prospective multicenter study. *Journal of Pediatric Orthopedics* 2017 **37** e599–e605. (<https://doi.org/10.1097/BPO.0000000000000943>)
- 66. Murphy RF, Moisan A, Kelly DM, Warner WC, Jones TL & Sawyer JR.** Use of vertical expandable prosthetic titanium rib (VEPTR) in the treatment of congenital scoliosis without fused ribs. *Journal of Pediatric Orthopedics* 2016 **36** 329–335. (<https://doi.org/10.1097/BPO.0000000000000460>)
- 67. Emans JB, Caubet JF, Ordonez CL, Lee EY & Ciarlo M.** The treatment of spine and chest wall deformities with fused ribs by expansion thoracostomy and insertion of vertical expandable prosthetic titanium rib: growth of thoracic spine and improvement of lung volumes. *Spine* 2005 **30** (17 Supplement) S58–S68. (<https://doi.org/10.1097/01.brs.0000175194.31986.2f>)
- 68. Parnell SE, Effmann EL, Song K, Swanson JO, Bompadre V & Phillips GS.** Vertical expandable prosthetic titanium rib (VEPTR): a review of indications, normal radiographic appearance and complications. *Pediatric Radiology* 2015 **45** 606–616. (<https://doi.org/10.1007/s00247-014-3128-4>)
- 69. Odent T, Ilharreborde B, Miladi L, Khouri N, Violas P, Ouellet J, Cunin V, Kieffer J, Kharrat K, Accadbled F, et al.** Fusionless surgery in early-onset scoliosis. *Orthopaedics and Traumatology, Surgery and Research* 2015 **101** (6 Supplement) S281–S288. (doi:10.1016/j.otsr.2015.07.004.)
- 70. Mundis GM, Kabirian N & Akbarnia BA.** Dual growing rods for the treatment of early-onset scoliosis. *JBJS Essential Surgical Techniques* 2014 **3** e6. (<https://doi.org/10.2106/JBJS.ST.K.00050>)
- 71. Wang S, Zhang J, Qiu G, Wang Y, Li S, Zhao Y, Shen J & Weng X.** Dual growing rods technique for congenital scoliosis: more than 2 years outcomes: preliminary results of a single center. *Spine* 2012 **37** E1639–E1644. (<https://doi.org/10.1097/BRS.0b013e318273d6bf>)
- 72. Akbarnia BA, Marks DS, Boachie-Adjei O, Thompson AG & Asher MA.** Dual growing rod technique for the treatment of progressive early-onset scoliosis: a multicenter study. *Spine* 2005 **30** (Supplement) S46–S57. (<https://doi.org/10.1097/01.brs.0000175190.08134.73>)
- 73. Watanabe K, Uno K, Suzuki T, Kawakami N, Tsuji T, Yanagida H, Ito M, Hirano T, Yamazaki K, Minami S, et al.** Risk factors for complications associated with growing-rod surgery for early-onset scoliosis. *Spine* 2013 **38** E464–E468. (<https://doi.org/10.1097/BRS.0b013e318288671a>)
- 74. Liang J, Li S, Xu D, Zhuang Q, Ren Z, Chen X & Gao N.** Risk factors for predicting complications associated with growing rod surgery for early-onset scoliosis. *Clinical Neurology and Neurosurgery* 2015 **136** 15–19. (<https://doi.org/10.1016/j.clineuro.2015.05.026>)
- 75. Tsurikou AI & Roberts SB.** Magnetic controlled growth rods in the treatment of scoliosis: safety, efficacy and patient selection. *Medical Devices* 2020 **13** 75–85. (<https://doi.org/10.2147/MDER.S198176>)
- 76. Akbarnia BA & Mundis GM.** Magnetically controlled growing rods in early onset scoliosis: indications, timing and treatment. *Der Orthopade* 2019 **48** 477–485. (<https://doi.org/10.1007/s00132-019-03755-0>)
- 77. Tauchi R, Tsuji T, Ohara T, Suzuki Y, Saito T, Nohara A, Sugawara R, Imagama S & Kawakami N.** Reconstructive surgery for the post-hemiepiphysiodesis residual deformity in congenital scoliosis. *European Journal of Orthopaedic Surgery and Traumatology* 2013 **23** (Supplement 1) S111–S113. (<https://doi.org/10.1007/s00590-013-1183-4>)
- 78. Hedequist D & Emans J.** Congenital scoliosis. *Journal of the American Academy of Orthopaedic Surgeons* 2004 **12** 266–275. (<https://doi.org/10.5435/00124635-200407000-00007>)
- 79. Lenke LG, Newton PO, Sucato DJ, Shufflebarger HL, Emans JB, Sponseller PD, Shah SA, Sides BA & Blanke KM.** Complications after 147 consecutive vertebral column resections for severe pediatric spinal deformity: a multicenter analysis. *Spine* 2013 **38** 119–132. (<https://doi.org/10.1097/BRS.0b013e318269fab1>)
- 80. Yang C, Zheng Z, Liu H, Wang J, Kim YJ & Cho S.** Posterior vertebral column resection in spinal deformity: a systematic review. *European Spine Journal* 2016 **25** 2368–2375. (<https://doi.org/10.1007/s00586-015-3767-7>)