

Hemothorax induced by severe cough: An unusual presentation

SAGE Open Medical Case Reports
Volume 7: 1–3
© The Author(s) 2019
Article reuse guidelines:
sagepub.com/journals-permissions
DOI: 10.1177/2050313X19846043
journals.sagepub.com/home/sco



Luis Arturo Camarillo-Reyes^{1,2}, Roberto Ivan Marquez-Córdova^{2,3},
Salim Surani⁴  and Joseph Varon^{5,6,7,8}

Abstract

Massive hemothorax resulting from cough-induced rib fracture is a condition in which blood accumulates in the chest, compromising the lungs and mediastinal structures. The most common cause of massive hemothorax is acute pro-traumatic injury. We present a case of a 47-year-old gentleman with morbid obesity and psoriasis, who was admitted to the emergency department due to shortness of breath that has been increased progressively after coughing for a period of 2 weeks. Chest radiograph demonstrated a large density in the left hemithorax, collapsing the left lung. Chest computerized tomography showed a left seventh rib fracture and massive pleural effusion. A closed chest tube thoracostomy was performed draining 3 L of hemorrhagic effusion, likely due to bleeding from the intercostal artery tear due to severe and prolonged cough. Cough-induced hemothorax due to spontaneous rib fractures are rare and clinicians should be well aware of this entity to prevent hemorrhagic shock and organ damage.

Keywords

Cough, hemothorax, tube thoracostomy, pleural effusion

Date received: 15 December 2018; accepted: 3 April 2019

Introduction

Approximately 150,000 Americans die every year due to trauma; 25% of those deaths are related to thoracic cage trauma. Hemothorax, however, is one of the most common complications of thoracic trauma. In addition to trauma, the non-traumatic hemothorax can be encountered in several diseases processes such as thoracic malignancies and metastasis, infections, tuberculosis, pulmonary arteriovenous malformation (AVM), pulmonary embolism, iatrogenic during thoracentesis or central venous access, and abnormal anatomy.^{1,2} The hemothorax may be seen due to injury to the chest wall compromising the intercostal arteries or can be due to pulmonary, diaphragmatic, vascular, and mediastinal injuries compromising bronchial arteries or major vascular structures. Cough-induced hemothorax presenting to the emergency department (ED) is rare. We hereby present such an unusual case.

Case presentation

A 47-year-old man presented to the ED with progressive shortness of breath of 2 weeks of duration. His dyspnea followed a “coughing spell.” His past medical history was

significant for chronic stable asthma, rheumatoid arthritis, psoriatic arthritis, metabolic syndrome, obstructive sleep apnea, and morbid obesity.

On arrival to the ED, patient was in severe respiratory distress, with a heart rate 130 min⁻¹, respiratory rate 34 min⁻¹, blood pressure 100/60 mmHg, and 89% oxygen saturation while breathing room air. He had diminished breath sounds in his left hemithorax and a large hematoma involving the left anterolateral aspect thorax. His hemoglobin level was 11.6 g/dL. Chest radiograph revealed near complete opacification of the left hemithorax (see Figure 1). Contrast-enhanced

¹Universidad Veracruzana, Xalapa, Mexico

²Dorrington Medical Associates, Houston, TX, USA

³Universidad Autonoma de Baja California, Mexicali, Mexico

⁴Texas A&M University-Corpus Christi, Corpus Christi, TX, USA

⁵Acute and Continuing Care, Houston, TX, USA

⁶The University of Texas Health Science Center, Houston, TX, USA

⁷The University of Texas Medical Branch at Galveston, Houston, TX, USA

⁸United Memorial Medical Center/United General Hospital, Houston, TX, USA

Corresponding Author:

Salim Surani, Texas A&M University-Corpus Christi, 701 Ayers St, Corpus Christi, TX 78413, USA.

Email: srsurani@hotmail.com



computed tomography (CT) of the chest revealed a large homogeneous opacification area occupying the left thoracic space consistent with pleural effusion that prevented the localization of the exact bleeder source vessel, with compressive atelectasis, and fracture of the seventh rib on the left side (see Figure 2). No lung mass, pleural mass, vascular bundle injury, or pulmonary embolism was seen.

Due to significant effusion and possibility of recurrent bleeding once the tamponade is relieved, an emergency tube thoracostomy was performed in the left fifth intercostal space rather than using pigtail catheter, and a 36F tube was placed, draining 3 L of hemorrhagic pleural effusion. His symptoms resolved rapidly. His repeat chest X-ray showed resolution of the hemothorax. No significant drainage or any air leak was seen from the chest tube, which was removed

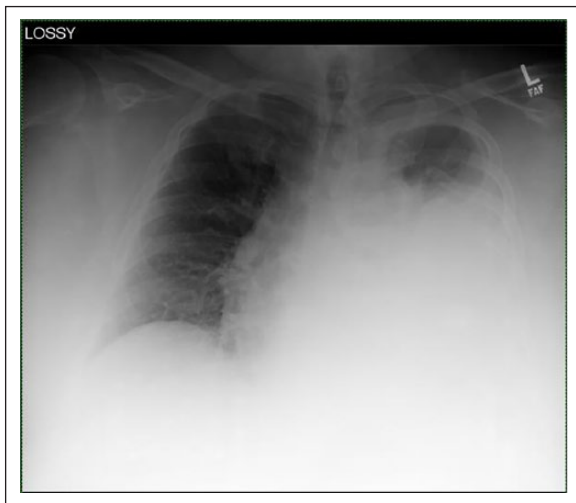


Figure 1. Anteroposterior chest radiograph on arrival to the emergency department shows a large opacity in left hemithorax.

after 48 h. His hemoglobin and hematocrit remained stable throughout the course of the stay. Patient was discharged home. On 3-month follow-up, the patient was completely asymptomatic.

Discussion

Spontaneous fractures of the ribs due to cough are rare but cough-induced hemothorax have rarely been reported.³⁻⁵ Most cases occur due to severe coughing. These fractures are thought to occur due to one of the two mechanisms. The first one is related to the force applied, and then, stress causes deformation which, when it exceeds the elastic limit, results in inelastic deformation of the rib. Cough, by itself, may produce an elastic deformation in the most vulnerable parts of the ribs, either at the costochondral junctions or in osteoporotic bone, usually the middle 3rd between the 5th and 10th ribs.³ The second mechanism may be related to contrary muscle forces acting on the ribs.⁶ Opposing action of intercostal muscles and other respiratory muscles on the same rib may result in fracture. For example, the simultaneous contraction of the shoulder girdle muscles, especially the serratus anterior, pulls the ribs upward and laterally, and the abdominal muscles pull the ribs downward and medially, possibly contributing to the development of rib fractures.⁶

The hemothorax may not be present in the initial X-ray done very earlier in the course of injury. The disruption of the chest wall tissue and pleural membrane with compromising of the intercostal or intermammary artery can cause the hemothorax as well as hematoma, as seen in this case. Massive hemothorax with acute blood loss and shock can be seen with the injury to the major arterial or venous structures or heart. Several of the congenital, intralobar, or extralobar sequestrations; AVM; and injuries to the parenchymal structure can cause the hemothorax.⁷ The pulmonary parenchyma

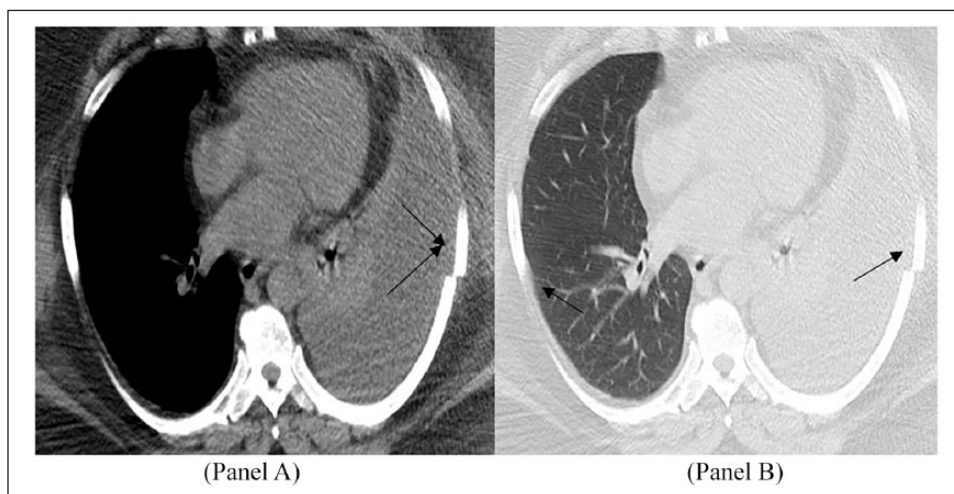


Figure 2. Contrast-enhanced computed tomography of the chest reveals a fracture of the seventh left rib in both the mediastinal (Panel A) and the lung window (Panel B) views (see arrows). In addition, a large pleural effusion is depicted in the left hemithorax.

can also be injured by fractured rib causing penetrating injury, but those are usually associated with prolonged pneumothorax and air leak seen in the Pleur-evac chamber beside the hemothorax. No air leakage was seen in our patient.

Management is based on preventing complications with the use of imaging and clinical evaluation of the hemodynamic stability of the patient.³ The CT scan has become the mainstay in the evaluation of a patient with hemothorax, and fluid in the pleural space is assumed to be blood. In case of doubt, the use of the Hounsfield units may prove useful. Also, an arterial blush indicates persisting bleeding and is an indication for an urgent procedure.⁸ In our case, the patient had a left seventh rib fracture followed by left-sided hemothorax, likely due to injury of intercostal artery tear, which resolved spontaneously without any surgical intervention or thoracotomy. Video-assisted thoracoscopy (VATS) has been suggested if >1500 mL of blood has been accumulated and/or a continuous production of >200 mL of blood per hour is found in developing cardiac tamponade, great vessel injury, injury to esophagus, massive air leak, diaphragmatic rupture, or cardiac injury to name a few. In addition, open thoracotomy can be performed in the patient who is not a candidate for the VATS.² Among the endovascular treatment of an arterial rupture, the techniques include coil embolization and stent graft placement and are preferred for hemodynamically stable patients; these procedures require more time for planning and preparation.⁹ The spasmodic cough in this patient was likely due to status asthmaticus. Cough-induced hemothorax has rarely been described before due to severe bronchospasm secondary to *status asthmaticus*.^{10,11}

Conclusion

Cough-induced hemothorax due to rib fractures can be life-threatening, and a delayed suspicion and diagnosis can lead to poor outcomes. Pleural effusion in a patient presenting with cough and a rib fracture should make clinicians to suspect hemothorax in their differential diagnosis.

Declaration of conflicting interests

The author(s) declared no potential conflicts of interest with respect to the research, authorship, and/or publication of this article.

Ethical approval

Our institution does not require ethical approval for reporting individual cases or case series.

Funding

The author(s) received no financial support for the research, authorship, and/or publication of this article.

Informed consent

Written informed consent was obtained from the patient(s) for their anonymized information to be published in this article.

Patient consent

Written permission has been obtained from the patient on 30 January 2019 for this submission.

ORCID iD

Salim Surani  <https://orcid.org/0000-0001-7105-4266>

References

- Ota K, Fumimoto S, Iida R, et al. Massive hemothorax due to two bleeding sources with minor injury mechanism: a case report. *J Med Case Rep* 2018; 12(1): 291.
- Mahoozi H, Volmerig J and Hecker E. Modern management of traumatic hemothorax. *J Trauma Treat* 2016; 5(3): 326.
- Roberge RJ, Morgenstern MJ and Osborn H. Cough fracture of the ribs. *Am J Emerg Med* 1984; 2: 513–517.
- Hillenbrand A, Henne-Bruns D and Wurl P. Cough induced rib fracture, rupture of the diaphragm and abdominal herniation. *World J Emerg Surg* 2006; 1: 34–33.
- Henriques AC, Malena CR, Freitas AC, et al. Transdiaphragmatic intercostal hernia after spontaneous rib fractures secondary to coughing fit. *Rev Col Bras Cir* 2010; 37(1): 78–80.
- Daniel R, Naidu B and Khalil-Marzouk J. Cough-induced rib fracture and diaphragmatic rupture resulting in simultaneous abdominal visceral herniation into the left hemithorax and subcutaneously. *Eur J Cardiothorac Surg* 2008; 34(4): 914–915.
- DiCrescenzo V, Laperuta P, Napolitano F, et al. Pulmonary sequestration presented as massive left hemothorax and associated with primary lung sarcoma. *BMC Surg* 2013; 13(Suppl. 2): S34.
- Broderick S. Hemothorax etiology, diagnosis, and management. *Thorac Surg Clin* 2013; 23(1): 89–96, vi–vii.
- Mydin M, Sharma A, Zia Z, et al. A novel approach in managing right-sided haemothorax in neurofibromatosis type I. *Asian Cardiovasc Thorac Ann* 2015; 23(5): 573–575.
- Ricketti PA, Unkle DW, Lockey R, et al. Idiopathic hemothorax in a patient with status asthmaticus. *J Asthma* 2016; 53(7): 770–773.
- Jang JY, Lim YS, Woo JH, et al. Spontaneous rupture of intercostal artery after severe cough. *Am J Emerg Med* 2015; 33(1): 131.e1–131.e3.