

# COVID-19 Reinfection in a Patient with Hodgkin Lymphoma: a Case Report

Atefeh Fakharian<sup>1</sup>, Hamed Ebrahimibagha<sup>2</sup>,  
Maryam Sadaat Mirenayat<sup>1</sup>, Fargol  
Farahmandi<sup>2</sup>

<sup>1</sup> Chronic Respiratory Diseases Research Center (CRDRC), National Research Institute of Tuberculosis and Lung Diseases (NRITLD), Shahid Beheshti University of Medical Sciences, Tehran, Iran, <sup>2</sup> Medical Student Research Committee, School of Medicine, Shahid Beheshti University of Medical Sciences, Tehran, Iran.

Received: 9 September 2020

Accepted: 8 November 2020

Correspondence to: Mirenayat MS

Address: Chronic Respiratory Diseases Research Center (CRDRC), NRITLD, Shahid Beheshti University of Medical Sciences, Tehran, Iran

Email address: maryam.mirenayat@gmail.com

COVID-19 pneumonia has invaded the world and continues to expand. The current evidence of the immune system reaction to this viral pneumonia shows that the post-infectious immunity against the virus may be temporary, and the virus may reinfect the patients after healing from the previous one. Here is presented a 55-year-old female patient, as a known case of Hodgkin lymphoma, diagnosed with COVID-19 reinfection during 40 days. Such evidence may be helpful in further understanding the immunology of the disease.

**Key words:** COVID-19; Hodgkin Lymphoma; Reinfection

## INTRODUCTION

Severe acute respiratory syndrome coronavirus-2 (SARS-CoV-2) that can cause coronavirus disease 2019 (COVID-19) was first found in Wuhan, China, and rapidly spread throughout the world. COVID-19 is a viral pneumonia with different manifestations that may be mild, severe, or even lethal. Each patient with an underlying disease is affected in some way by COVID-19 (1).

Although the durability of neutralizing antibodies against SARS-CoV-2 is not defined yet, the resistance period is estimated up to 40 days since the onset of symptoms (2). Evidence of antibody response to SARS-CoV-2 and similar coronaviruses is limited; however, an animal model study shows at least a temporary immunity after recovery from COVID-19 against reinfection (3). Some

other evidence shows that the result of RT-PCR becomes positive again in some patients within 10-28 days after recovery, which even reaches 37 days in some cases (4-6).

The study by Ye et al., showed that about 9.1% of patients with COVID-19 manifested signs and symptoms of reinfection (4). Also, two other studies estimated the rate of reinfection and positive RT-PCR result after recovery as 14.5% and 21.4%, respectively (7, 8). Yuan et al., in another study, enrolled 25 patients with a positive result in RT-PCR for an average of six days after being discharged (9). Given the evidence of COVID-19 reinfection, the time course between discharge with a negative RT-PCR result and resolved symptoms to a positive RT-PCR result varies from 4 to 17 days (4, 7, 10-12).

It is known that cancers and therapies of patients' blood affect the immune system. Hence, patients, especially the ones with such cancer, are at a higher risk for SARS-CoV-2 infection or reinfection (13,14).

Normally, a patient is not expected to develop reinfection when a short interval elapsed since resolution from the disease. The current report presents a patient, as a known case of Hodgkin lymphoma (HL), who experienced two confirmed SARS-Cov-2 infections in a short period.

### CASE SUMMARIES

The patient was a 55-year-old female, as a known case of Hodgkin lymphoma, from 1.5 years ago and her last chemotherapy was 55 days before attending the center. Two weeks after chemotherapy, she had a dry cough, dyspnea, chills, and myalgia. The chest spiral computed tomography (spiral CT) scan revealed bilateral multifocal patchy ground-glass opacity (GGO) and consolidations, especially in sub-pleural space and peribronchovascular, which was suggestive of COVID-19 (Figure 1). After six days of hospitalization in the COVID-19 ward and receiving a conservative therapy, the signs and symptoms improved, and the result of her real-time polymerase chain reaction (RT-PCR) for SARS-CoV-2 was negative. Therefore, she was discharged with good general health.

After 40 days, she was brought to the hospital while she felt severe dyspnea and had chills, dry cough, and myalgia. Her oxygen saturation in the room air was 85%, and she described her symptoms the same as the previous visit. This time instead of CT-scan, an RT-PCR was practiced, which the result was positive for SARS-CoV-2 (Figure-2A). Again the patient received conservative therapy, and her RT-PCR result became negative after one week, and she had no signs and symptoms. Her last CT-scan showed an apparent improvement in the previously affected sections (Figure-2B).

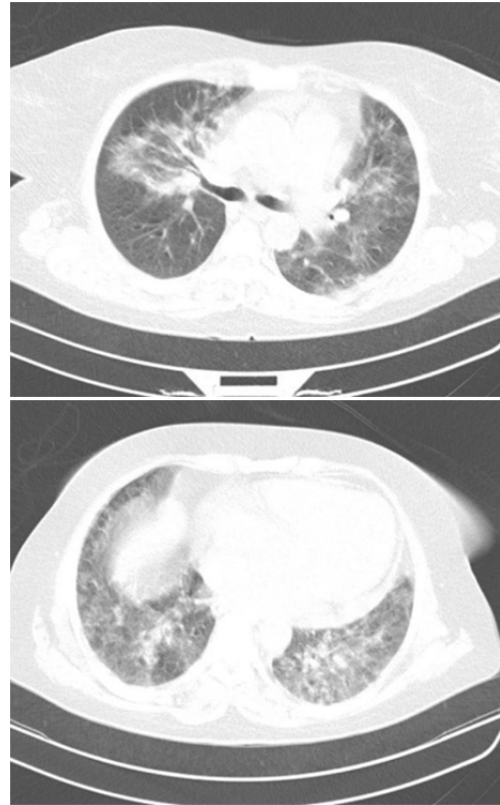


Figure 1. Patient's CT-scan at her first admission. Severe lung involvement is seen in both lungs.

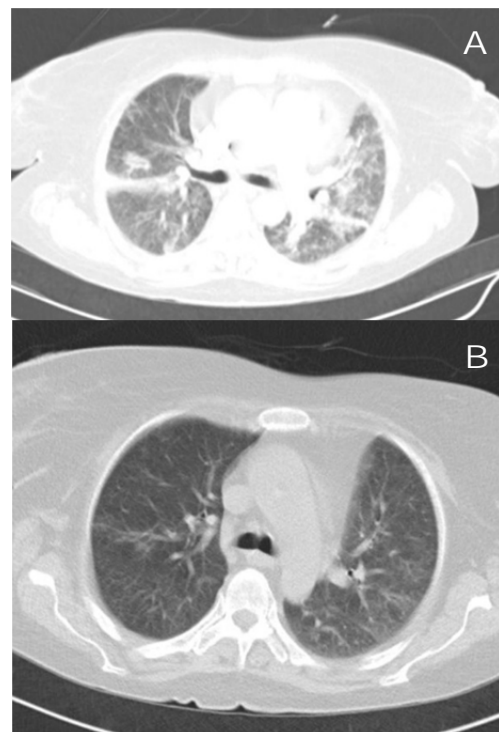


Figure 2. Patient's CT-scan at her second admission. A) at the day of admission B) one week after hospitalization

## DISCUSSION

As most of the evidence of the management of COVID-19 shows, in-patients can be discharged after resolving the symptoms and when there are two negative RT-PCR results within two consecutive days. Some evidence shows that positive RT-PCR results are reported in some patients sometimes after discharge. It may be due to incomplete SARS-CoV-2 clearance, incorrect sampling, or a false-negative result of RT-PCR. Also, it may be due to reinfection or even reactivation as well (3). Some patients may also be discharged with a false-negative PCR result while having a persistent infection (15).

Regarding the current case, according to the first RT-PCR and CT-scan results and resolving the symptoms, it was made sure that the patient was completely cured during her first admission.

Three mechanisms are reported based on the immune response to reinfection, which are the insufficiency of the immune response, short-lived immune response, and strain explicit in addition to mutations of SARS-CoV-2 (16). For proving reinfection with SARS-CoV-2, culture-based evidence of the new infection and elimination of the previous one is needed. There is no case of human reinfections with SARS-CoV-2 thus far (3). There is a report of two patients diagnosed with COVID-19 and discharged after two negative results of RT-PCR, indicating that after 10 days, the viral RNA was detected in both of them (12). It is noteworthy that the SARS-CoV-2 RNA may be recognized in nasopharyngeal or throat swabs over 20 days after negative results (8).

In two reports, patients who had a positive throat swab after discharge had stable or improved symptoms on radiographic examination (12, 17). There is no evidence that patients with a history of the disease and resolved signs and symptoms may transmit it; however, transmission from immunosuppressed patients with a history of the disease is not impossible (3).

For a better understanding of the pathophysiology of COVID-19 reinfection, studies should be focused on viral

strain genetics, evaluation of immune system response to infection, and inflammatory targets (18). As discussed earlier, the duration of the immune response plays a significant role in reinfection. Barthold and Smith, in a study on mice, showed that despite similar antibody responses, there are mechanisms affecting the immune system resistance against murine coronavirus species (19). From the evidence and observations concerning the immune response to COVID-19 and SARS, it can be concluded that the humoral immunologic response is not enough to make the long-term immunity, and the cellular immunity and related cytokines play pivotal roles in a long-standing immunity (20,21).

It is recommended that reducing the dose of chemotherapy should be considered in patients receiving immunochemotherapy in COVID-19 epidemic areas. In addition, the effect of immunotherapy with monoclonal antibodies-e g, rituximab, on COVID-19 should also be considered (22).

Based on the mentioned evidence, it is strongly believed that the presented patient was reinfected with SARS-CoV-2 just 40 days after recovery from the previous one. Since the patient had Hodgkin lymphoma, it can be assumed that the effect of chemoradiotherapy on her immune system may affect the active immunity expected to be acquired after the first infection; therefore, after another exposure, she was reinfected with the virus.

## CONCLUSION

The experience of this case and similar reported cases show that unlike most viral infections, COVID-19 can cause reinfection even as short as 40 days after recovery from the previous one.

## Conflicts of Interest

The authors declare that the research was conducted in the absence of any commercial or financial relationships that could be construed as a potential conflict of interest.

## REFERENCES

1. Lai CC, Shih TP, Ko WC, Tang HJ, Hsueh PR. Severe acute respiratory syndrome coronavirus 2 (SARS-CoV-2) and coronavirus disease-2019 (COVID-19): The epidemic and the challenges. *Int J Antimicrob Agents* 2020;55(3):105924.
2. Zhao J, Yuan Q, Wang H, Liu W, Liao X, Su Y, et al. Antibody Responses to SARS-CoV-2 in Patients With Novel Coronavirus Disease 2019. *Clin Infect Dis* 2020;71(16):2027-34.
3. Kirkcaldy RD, King BA, Brooks JT. COVID-19 and Postinfection Immunity: Limited Evidence, Many Remaining Questions. *JAMA* 2020;323(22):2245-6.
4. Ye G, Pan Z, Pan Y, Deng Q, Chen L, Li J, et al. Clinical characteristics of severe acute respiratory syndrome coronavirus 2 reactivation. *J Infect* 2020;80(5):e14-7.
5. Zhou F, Yu T, Du R, Fan G, Liu Y, Liu Z, et al. Clinical course and risk factors for mortality of adult inpatients with COVID-19 in Wuhan, China: a retrospective cohort study. *Lancet* 2020;395(10229):1054-62.
6. Chang D, Zhao P, Zhang D, Dong JH, Xu Z, Yang G, et al. Persistent Viral Presence Determines the Clinical Course of the Disease in COVID-19. *J Allergy Clin Immunol Pract* 2020;8(8):2585-2591.e1.
7. Yuan J, Kou S, Liang Y, Zeng J, Pan Y, Liu L. Polymerase Chain Reaction Assays Reverted to Positive in 25 Discharged Patients With COVID-19. *Clin Infect Dis* 2020;71(16):2230-2.
8. Xiao AT, Tong YX, Zhang S. False negative of RT-PCR and prolonged nucleic acid conversion in COVID-19: Rather than recurrence. *J Med Virol* 2020:10.
9. Yuan J, Kou S, Liang Y, Zeng J, Pan Y, Liu L. Clinical Characteristics on 25 Discharged Patients with COVID-19 Virus Returning. *medRxiv* 2020.
10. Dong X, Cao YY, Lu XX, Zhang JJ, Du H, Yan YQ, et al. Eleven faces of coronavirus disease 2019. *Allergy* 2020;75(7):1699-709.
11. Shi Y, Wang Y, Shao C, Huang J, Gan J, Huang X, et al. COVID-19 infection: the perspectives on immune responses. *Cell Death Differ* 2020;27(5):1451-4.
12. Xing Y, Mo P, Xiao Y, Zhao O, Zhang Y, Wang F. Post-discharge surveillance and positive virus detection in two medical staff recovered from coronavirus disease 2019 (COVID-19), China, January to February 2020. *Euro Surveill* 2020;25(10):2000191.
13. Wang H, Zhang L. Risk of COVID-19 for patients with cancer. *Lancet Oncol* 2020;21(4):e181.
14. He W, Chen L, Chen L, Yuan G, Fang Y, Chen W, et al. COVID-19 in persons with haematological cancers. *Leukemia* 2020;34(6):1637-45.
15. Hoang VT, Dao TL, Gautret P. Recurrence of positive SARS-CoV-2 in patients recovered from COVID-19. *J Med Virol* 2020:10.
16. Chaturvedi R, Naidu R, Sheth S, Chakravarthy K. Efficacy of Serology Testing in Predicting Reinfection in Patients With SARS-CoV-2. *Disaster Med Public Health Prep* 2020:1-3.
17. Young BE, Ong SWX, Kalimuddin S, Low JG, Tan SY, Loh J, et al. Epidemiologic Features and Clinical Course of Patients Infected With SARS-CoV-2 in Singapore. *JAMA* 2020;323(15):1488-94.
18. Gousseff M, Penot P, Gallay L, Batisse D, Benech N, Bouillier K, et al. Clinical recurrences of COVID-19 symptoms after recovery: Viral relapse, reinfection or inflammatory rebound? *J Infect* 2020;81(5):816-46.
19. Barthold SW, Smith AL. Duration of challenge immunity to coronavirus JHM in mice. *Arch Virol* 1989;107(3-4):171-7.
20. Channappanavar R, Fett C, Zhao J, Meyerholz DK, Perlman S. Virus-specific memory CD8 T cells provide substantial protection from lethal severe acute respiratory syndrome coronavirus infection. *J Virol* 2014;88(19):11034-44.
21. Enjuanes L, Zuñiga S, Castaño-Rodríguez C, Gutierrez-Alvarez J, Canton J, Sola I. Molecular Basis of Coronavirus Virulence and Vaccine Development. *Adv Virus Res* 2016;96:245-86.
22. Li Q, Zhu F, Xiao Y, Liu T, Liu X, Wu G, et al. A Primary Mediastinal Large B-Cell Lymphoma Patient with COVID-19 Infection after Intensive Immunochemotherapy: A Case Report. *Front Oncol* 2020;10:924.