


# Thoraco-abdominal duplication cyst of the jejunum presenting as respiratory distress in a young infant—a case report

Nilgün Harputluoğlu <sup>1,\*</sup>, Tanju Çelik<sup>1</sup>, Günyüz Temir<sup>2</sup> and Münevver Hoşgör<sup>2</sup>

<sup>1</sup>Izmir Dr Behçet Uz Children's Hospital, Pediatric Palliative Care Center-Izmir, Turkey

<sup>2</sup>Izmir Dr Behçet Uz Children's Hospital, Department of Pediatric Surgery-Izmir, Turkey

\*Correspondence address. Pediatric Palliative Care Center; Dr Behçet Uz Children's Hospital, İsmet Kaptan Region, Sezer Doğan St., No. 11, Alsancak, Konak, 35210, İzmir, Turkey. Tel: +905306418055; E-mail: nilgunharputluoglu@yahoo.com.tr

## Abstract

Thoraco-abdominal duplication cysts are rare congenital anomalies that can accompany vertebral and spinal cord pathologies and occur most frequently in the small intestines. Symptoms such as respiratory distress, dyspnea, tachypnea, cough, hemoptysis, cyanosis, vomiting and dysphagia may develop depending on the location. The cyst has several clinical and radiological dilemmas. We present a rare case of thoraco-abdominal duplication cyst in a 3-month-old male patient presenting with respiratory distress in the neonatal period. Thoraco-abdominal duplications require a high index of suspicion and meticulous clinical management. Thus, patients can be successfully managed without any unnecessary interventions, complications and loss of time.

## INTRODUCTION

Gastrointestinal duplication (GID) cysts are rare congenital anomalies and most frequently occur in the small intestines (mostly in the ileum, as 33%). Jejunal duplication cysts have been reported previously and account for 10% in a review of 280 patients [1, 2]. Thoraco-abdominal GIDs constitute <2–5% of all GID [3]. They arise in the abdomen and, after passing through the right crus of the diaphragm, surpass behind the esophagus and aorta, through their own cavities, through the diaphragm. They tend to be long, large, tubular lesions, usually located in the posterior mediastinum to the right of the midline [1] and are usually closed cranially and connect caudally to the small intestine [1]. The prevalence of accompanying thoracic vertebral anomalies is high (88%) [3–5]. Diagnosis can be achieved with prenatal diagnosis methods. We presented a rare case with difficulties in diagnosis and treatment management, which has not been reported as such to the best of our knowledge. This report aimed to raise awareness regarding GID cysts and provide the consideration of these cysts in the differential diagnoses.

## CASE PRESENTATION

A 3-month-old baby boy born with cesarean section and 3710 g from a 34-year-old G1P0 (gravida:1, parity:0) mother was followed up in another center due to

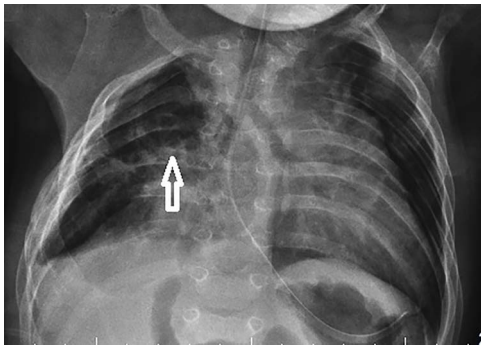
respiratory distress and transferred to the neonatal intensive care unit on the 17th postnatal day. As a result of the examinations performed in the neonatal intensive care unit due to flexion contracture in the right hand, kyphoscoliosis and respiratory distress, a hiatal hernia was diagnosed, and an operation was performed. The patient, whose respiratory distress did not regress and who had congenital anomalies, was transferred to our pediatric palliative care center.

On physical examination, the baby's weight was 3160 g (10–50p), height was 52 cm (90p) and head circumference was 36 cm (90p). The patient had a pulse of 156 apex beats/min, respiratory rate of 68/min, blood pressure of 80/62 mmHg, preductal SpO<sub>2</sub> of 92% and postductal SpO<sub>2</sub> of 93% (at room air). He was determined to have respiratory distress, tachypnea, intercostal and subcostal retractions, abdominal distention, restlessness and crying spells. No palpable mass in the abdomen and no rebound or defense signs were observed. The parents stated that there was an abnormality detected in the baby's intestines in the second trimester of pregnancy in the prenatal period, and amniocentesis was performed, but the result was not pathological. The chest X-ray of the patient revealed a cystic appearance in the right lung (Fig. 1). Laboratory parameters of the case are presented in Table 1. There was no hernia or cystic mass determined with ultrasound in postnatal radiological

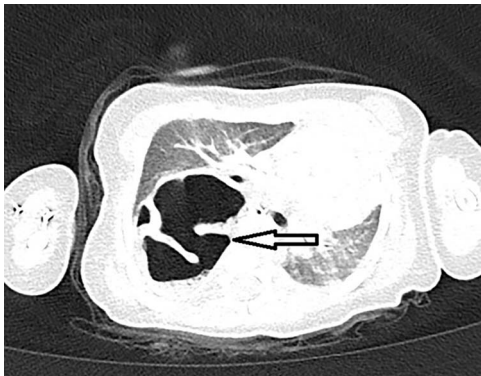
Received: January 20, 2022. Revised: May 22, 2022. Accepted: May 29, 2022

© The Author(s) 2022. Published by Oxford University Press. All rights reserved. For permissions, please e-mail: journals.permissions@oup.com

This is an Open Access article distributed under the terms of the Creative Commons Attribution-NonCommercial License (<http://creativecommons.org/licenses/by-nc/4.0/>), which permits non-commercial re-use, distribution, and reproduction in any medium, provided the original work is properly cited. For commercial re-use, please contact journals.permissions@oup.com



**Figure 1.** The cystic lesion in the right lung, at the apex, deviating the heart slightly to the left, chest X-ray.

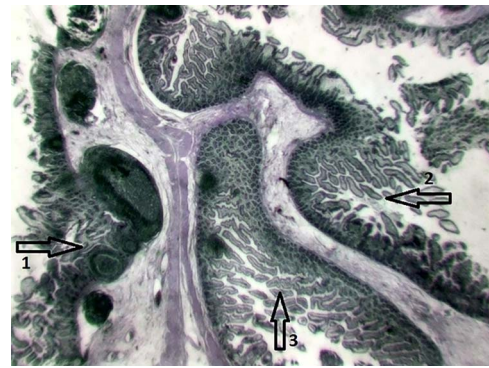


**Figure 2.** Chest CT, cystic lesion appearance medial to the right hemidiaphragm, posteriorly and at the apex, in which the intestinal wall appears as septa.

examinations. On chest computed tomography (CT), mediastinal compartments were deviated to the left, a suspicious appearance of 2 cm in the diaphragm behind the medial of the right hemidiaphragm and herniation of the intestinal loops into the right hemidiaphragm were revealed (Fig. 2). Since this region was considered to be associated with the spinal cord, spinal magnetic resonance imaging (MRI) revealed an unidentified C5 vertebral corpus—an enteric duplication cyst extending transdiaphragmally from the hiatus level to the right hemithorax—accompanying meningocele tissue. Fluoroscopy showed malrotation and gastroesophageal reflux, which caused herniation in the jejunal anses from the medial center of the right hemidiaphragm to the hiatus level to the right hemithorax.

### Surgical method

The patient was operated on with the preliminary diagnosis of right thoracic mass and diaphragmatic hernia, detected in postnatal chest X-ray and cervicothoracic tomography. No diaphragmatic defect or weakness was determined at laparotomy. Following this operation, a right thoracotomy was performed. In the posterior of the right hemithorax, a tortuous and conglomerate thoracic mass covered by the pleura and extending to the apex was observed. The mass, considered to be a duplication of the gastrointestinal tract, was incised with the



**Figure 3.** Histopathological appearance with Jejunum Hematoxylin-Eosin stain. The duplicated segment (1) is seen on the far left, the normal small intestine segment (2) on the right, and the muscular layers of both segments in between (3).

appearance of an intestinal loop. There was no defect in the diaphragm.

### Pathological outcome

Pathological examination revealed mucosal irregular lumen tissue with a length of 6.5 cm and a diameter of 2–4 cm. When examined from the serosal surface, a second luminal structure with a blunt ending, 5 cm in length and 1.5 cm in diameter, with open ends on both sides, was determined. The mucosa was flattened in places when it was opened along the lumen, and the wall thickness was thinned up to 1 mm (Fig. 3).

### DISCUSSION

Although GID cysts in children are usually symptomatic in the first year of life, clinical diagnosis may be challenging since they are rare and the symptoms are non-specific. In the literature, GID cysts are generally in the form of case reports, and there are few case series. In our case, there was a duplication cyst located in the right hemithorax, as it was closed cranially, and the caudal end was associated with the jejunum. Holcomb 3rd et al. [4] reported thoraco-abdominal GID cysts in only 3 of 96 patients in their 37-year series. These three thoraco-abdominal GID cysts were revealed to be associated with the stomach, ileum and jejunum, respectively, all were accompanied by vertebral anomalies, and one of them was associated with the spinal cord [4]. Erginel et al. [6] reported respiratory distress in only 2 of 40 patients in their 26-year enteric duplication cyst series. Small intestine duplications develop as a result of incomplete recanalization at the eighth week of gestation. They are observed as round or tubular cystic lesions surrounded by the intestinal mucosa. There is a connection with the true lumen very rarely. These present as palpable masses in the first year of life in one-third of the cases. There may be bleeding or intussusception in 15% of cases. Vomiting due to obstruction can also occur [7]. Duplication cysts usually create a dilemma in diagnosis and treatment with their clinical and radiological findings. GID cysts can be mistaken for diaphragmatic hernia and

**Table 1.** Laboratory parameters of the case (complete blood count, biochemical parameters and blood gas analysis)

	Case value	Measurement unit	Normal value
Hemoglobin	10.6	g/dl	10.6–13.2
Hematocrit	30.9	%	32.4–39.5
Red blood cell			3.90–4.96
Mean corpuscular volume	79.8	fL	75.9–87.6
Mean corpuscular hemoglobin		pg	24.8–29.5
Mean erythrocyte hemoglobin concentration		g/dl	31.5–35.5
Red cell distribution width		%	12.2–14.9
White blood cell	9.860	10 <sup>3</sup> /ul	4.27–11.40
Neutrophil		%	29.8–71.4
Lymphocyte		%	16.7–57.8
Monocytes		%	4.2–11.3
Basophil		%	0–0.6
Eosinophil		%	0–4.0
Thrombocyte	333.000	10 <sup>3</sup> /ul	199–367
Glucose	87	mg/dl	60–100
Blood urine nitrogen	10	mg/dl	7–16.8
Creatinine	0.4	mg/dl	0.3–0.7
Uric acid		mg/dl	2.02–4.96
Sodium	135	mmol/l	136–145
Potassium	4.6	mmol/l	3.5–5.1
Chlorine	104	mmol/l	98–107
Calcium	9.4	mmol/l	8.8–10.8
Phosphorus		mg/dl	3–5.5
Alkaline phosphatase		IU/l	156–369
Alanine amino transferase	12	IU/l	5–40
Aspartate amino transferase	28	IU/l	7–40
Total bilirubin		mg/dl	0.2–1.2
Direct bilirubin		mg/dl	0–0.5
Gamma glutamyl transferase		IU/l	9–36
Total protein	6.3	g/dl	6–8
Albumin	4.2	g/dl	3.8–5.4
Creatine kinase		IU/l	29–168
C-reactive protein	0.2	mg/dl	<0.5
Ph	7.437		7.35–7.45
PCo2	34.4	mmHg	35–45
PO2	94.1	mmHg	83–108
HCO3–	22.7	mmol/l	21–28
sO2	97.3	%	95–99

bronchopulmonary cysts due to their origin and developmental pathogenesis [8]. Diaphragmatic hernia is defined as the presence of abdominal viscera in the chest due to a defect in the diaphragm and shows similar clinical symptoms, although the pathogenesis is different [9]. Differential diagnosis is critical since it affects the method of treatment. In our case, respiratory distress was the most prominent symptom. The patient had abdominal bloating, restlessness and crying spells. The abdominal symptoms of our case were mostly similar to the features of infant colic and were at a level that could be ignored. Interestingly, despite its association with the jejunum, there were no symptoms of bowel obstruction. Pain and discomfort due to distension in the cyst, air swallowing due to crying and abdominal distension may have been observed.

The most commonly used imaging methods in diagnosis are X-ray and ultrasonography. Conventional contrast-enhanced radiographic examinations may be valuable in diagnosing tubular GID cysts. CT is extremely useful in identifying surrounding structures, and MRI,

particularly FIESTA (rapid imaging using steady-state acquisition), has also been greatly beneficial in diagnosing skeletal abnormalities [10]. In our case, a right thoracic cystic lesion was detected on X-ray, but it could not be differentiated by ultrasound even though it was examined three times. However, the persistence of the symptoms revealed the need for further investigations. The diagnosis was achieved by fluoroscopy, and the patient was operated on. The diagnosis was confirmed histopathologically. Some cases of misdiagnosis and associated problems leading to patient mismanagement have been reported [10]. Even in a pediatric hospital, the most critical reason the case was missed initially is that GID cysts, especially thoraco-abdominal duplications, are rare and not considered in the clinical differential diagnosis.

GID cysts, occurring with various gastrointestinal symptoms, may present with respiratory distress and a cystic mass in the thorax. It is important to consider the thoraco-abdominal duplication cysts with a high index of suspicion. Thus, patients can be successfully managed

without unnecessary interventions, complications and loss of time.

## AUTHORS' CONTRIBUTIONS

Each author has participated in the concept and design; analysis and interpretation of data; drafting or revising of the manuscript and that each author has approved the manuscript as submitted and agree to be accountable for all aspects of the work.

## ACKNOWLEDGMENT

We would like to thank Pathologist MD Malik Ergin for contributing to the pathological examinations and images.

## FUNDING

All authors have declared that they have no financial relationships at present or within the previous 3 years with any organizations that might have an interest in the submitted work.

## ETHICAL APPROVAL

All procedures performed in studies involving human participants were done in accordance with the ethical standards of the institutional and/or national research committee and with the 1964 Helsinki Declaration and its later amendments or comparable ethical standards.

## INFORMED CONSENT

Written informed consent for publication was obtained from the patient for submission of this manuscript for publication.

## GUARANTOR

Dr Nilgün Harputluoğlu is acting as a guarantor of this manuscript.

## REFERENCES

1. Macpherson RI. Gastrointestinal tract duplications: clinical, pathologic, etiologic, and radiologic considerations. *Radiographics* 1993;**13**:1063–80. <https://pubs.rsna.org/doi/pdf/10.1148/radiographics.13.5.8210590>.
2. Sangüesa Nebot C, Llorens Salvador R, Carazo PE. Enteric duplication cysts in children: varied presentations, varied imaging findings. *Insights Imaging* 2018;**9**:1097–106. [https://www.ncbi.nlm.nih.gov/pmc/articles/PMC6269332/pdf/13244\\_2018\\_Article\\_660.pdf](https://www.ncbi.nlm.nih.gov/pmc/articles/PMC6269332/pdf/13244_2018_Article_660.pdf).
3. Sharma S, Yadav AK, Mandal AK, Zaheer S, Yadav D, Samie A. Enteric duplication cysts in children: a clinicopathological dilemma. *J Clin Diagn Res* 2015;**9**:8–11. <https://www.ncbi.nlm.nih.gov/pmc/articles/PMC4576543/pdf/jcdr-9-EC08.pdf>.
4. Holcomb GW 3rd, Gheissari A, O'Neill JA Jr, Shorter NA, Bishop HC. Surgical management of alimentary tract duplications. *Ann Surg* 1989;**209**:167–74. <https://www.ncbi.nlm.nih.gov/pmc/articles/PMC1493914/pdf/annsurg00180-0045.pdf>.
5. Karnak B, Ocal T, Şenocak ME, Tanyel FC, Büyükpamukçu N. Alimentary tract duplications in children: report of 26 years' experience. *Turk J Pediatr* 2000;**42**:118–25. <https://pubmed.ncbi.nlm.nih.gov/10936977/>.
6. Erginel B, Soysal FG, Ozbey H, Keskin E, Celik A, Karadağ A et al. Enteric duplication cysts in children: a single-institution series with forty patients in twenty-six years. *World J Surg* 2017;**41**: 620–4. <https://doi.org/10.1007/s00268-016-3742-4>.
7. Khong PL, Cheung SCW, Leong LLY, Ooi CGC. Ultrasonography of intra-abdominal cystic lesions in the newborn. *Clin Radiol* 2003;**58**:449–54. [https://doi.org/10.1016/S0009-9260\(03\)&break;ss00125-9](https://doi.org/10.1016/S0009-9260(03)&break;ss00125-9).
8. Katz R, Pitt R, Kim D, Wingrove B. Thoracoscopic pneumonectomy for communicating bronchopulmonary foregut malformation in a 4-month-old child. *J Pediatr Surg* 2010;**45**:427–9. <https://doi.org/10.1016/j.jpedsurg.2009.11.045>.
9. Poddihe D, Boggini T, Savasta S, Marsegli GL. Unrecognised diaphragmatic hernia in a refugee child: an incidental diagnosis. *BMJ Case Rep* 2017;**2017**:bcr2017220748. <https://doi.org/10.1136/bcr-2017-220748>.
10. Olajide A, Yisau AA, Abdulraseed NA, Kashim IOO, Olaniyi AJ, Morohunfade AOA. Gastrointestinal duplications: experience in seven children and a review of the literature. *Saudi J Gastroenterol* 2010;**16**:105–9. <https://www.ncbi.nlm.nih.gov/pmc/articles/PMC3016497/pdf/SJG-16-105.pdf>.