

Rituximab Improves Subclinical Temporal Dispersion of Distal Compound Muscle Action Potential in Anti-MAG/SGPG Neuropathy Associated with Waldenström Macroglobulinemia: A Case Report

Minori Kodaira Kanji Yamamoto

Department of Neurology, Nagano Municipal Hospital, Nagano, Japan

Key Words

Anti-MAG/SGPG neuropathy · Waldenström macroglobulinemia · Subclinical temporal dispersion · Distal compound muscle action potential · Rituximab

Abstract

Patients with anti-myelin-associated glycoprotein (MAG)/sulfated glucuronyl paragloboside (SGPG) neuropathy associated with Waldenström macroglobulinemia show demyelinating neuropathy, but the temporal dispersion of distal compound muscle action potential (CMAP) in motor nerve conduction studies (NCS), which represents heterogeneous demyelination at the motor nerve terminal, is rare. We report on a 70-year-old man with anti-MAG/SGPG neuropathy associated with Waldenström macroglobulinemia; he had a 2-year history of mild dysesthesia of the foot sole without any motor symptoms. He showed marked temporal dispersion of distal CMAP in the tibial nerve with other demyelinating findings in the NCS. The temporal dispersion of distal CMAP in the tibial nerve improved significantly, and motor function was again normal 1 year after rituximab monotherapy. The temporal dispersion of distal CMAP in anti-MAG/SGPG neuropathy is rare, but it could occur from an early stage when the patients show mild or no motor symptoms. Rituximab therapy before secondary axonal degeneration has great potential to reverse the effects of the demyelination including the temporal dispersion of distal CMAP, and to prevent the deterioration of neuropathy in anti-MAG/SGPG neuropathy.

Minori Kodaira
Department of Neurology
Nagano Municipal Hospital
1333-1 Tomitake, Nagano 381-8551 (Japan)
E-Mail kodaira@nips.ac.jp

Kodaira et al.: Rituximab Improves Subclinical Temporal Dispersion of Distal Compound Muscle Action Potential in Anti-MAG/SGPG Neuropathy Associated with Waldenström Macroglobulinemia: A Case Report

Introduction

Neuropathy in Waldenström macroglobulinemia is very heterogeneous; electrophysiological studies show not only demyelinating neuropathy, but also axonal neuropathy [1]. Demyelinating neuropathies in Waldenström macroglobulinemia are classified into anti-myelin-associated glycoprotein (MAG)/sulfated glucuronyl paragloboside (SGPG) neuropathy and chronic inflammatory demyelinating polyradiculoneuropathy (CIDP), depending on whether an anti-MAG antibody is present [1]. The temporal dispersion of distal compound muscle action potential (CMAP) in motor nerve conduction studies (NCS), which represents heterogeneous demyelination at the motor nerve terminal, is often observed in CIDP [2, 3], but it has been rarely observed in anti-MAG/SGPG neuropathy [2]. Rituximab has recently been administered to patients with anti-MAG/SGPG neuropathy. However, the course of electrophysiological findings has been controversial [4–9]. Here, we report the case of a patient with anti-MAG/SGPG neuropathy associated with Waldenström macroglobulinemia who showed subclinical temporal dispersion of distal CMAP and electrophysiological improvement after rituximab monotherapy.

Case Presentation

A 70-year-old man had a 2-year history of mild dysesthesia of the foot sole. He had no family history of neuropathy. Neurological examination showed disturbed vibration sense in the feet, a positive Romberg sign, and diminished deep tendon reflexes of the extremities. Superficial sensation was preserved. Muscle atrophy, weakness, dysautonomia, cranial neuropathies and cerebellar ataxia were absent. Laboratory examinations showed no abnormal findings, except for an elevated serum immunoglobulin M (IgM) level (673 mg/dl) and the detection of IgM kappa monoclonal protein on serum immunofixation electrophoresis. Anti-MAG antibody was detected by Western blot analysis, and the anti-SGPG antibody titer determined using an enzyme-linked immunoassay was 819,200 (normal value, $\leq 3,200$). Although the protein concentration was slightly elevated (67 mg/dl), no pleocytosis was observed in the cerebrospinal fluid. Bone marrow analysis showed an increase in abnormal small lymphocytes (13%). Imaging studies showed no malignancies. Motor NCS showed demyelinating neuropathy. The temporal dispersion of distal CMAP was apparent in the tibial nerve (fig. 1a), and the duration of CMAP was slightly prolonged in the median nerve (fig. 1b). No conduction block was detected in either nerve. Sensory NCS showed demyelinating and axonal neuropathy. We diagnosed the patient with anti-MAG/SGPG neuropathy associated with Waldenström macroglobulinemia and initiated rituximab monotherapy, i.e., intravenous rituximab at a standard dosage of 375 mg/m² weekly for 4 weeks. Dysesthesia and vibration-sense disturbance in the feet were unchanged, but Romberg sign disappeared 3 months after the initiation of therapy. On reexamination 1 year after therapy, motor function was normal and the serum IgM concentration and anti-SGPG antibody titer had diminished (289 mg/dl and 25,600, respectively). Serum anti-MAG antibody and abnormal lymphocytes in the bone marrow had disappeared, but serum IgM-kappa monoclonal protein was present. The parameters of the NCS before and 1 year after therapy are shown in table 1. Distal latency (DL) and F-wave latency in the median and tibial nerves shortened, and motor nerve conduction velocity in the median nerve improved. The temporal dispersion of distal CMAP in the tibial nerve improved significantly (fig. 1c), but the CMAP waveform in the median nerve was unchanged (fig. 1d). The parameters of the sensory NCS

Kodaira et al.: Rituximab Improves Subclinical Temporal Dispersion of Distal Compound Muscle Action Potential in Anti-MAG/SGPG Neuropathy Associated with Waldenström Macroglobulinemia: A Case Report

were not remarkably altered. The patient has been carefully followed up without additional treatment in the outpatient department.

Discussion

The clinical picture of our patient was consistent with anti-MAG/SGPG neuropathy; slowly progressive, symmetric, predominantly distal, and sensory neuropathy with relatively mild or negligible weakness [10]. The results of motor NCS also fulfilled the criteria for demyelination neuropathy [11]. Hence, we diagnosed the patient with anti-MAG/SGPG neuropathy associated with Waldenström macroglobulinemia.

Several electrophysiological studies have shown that anti-MAG/SGPG neuropathy presents with disproportionate distal slowing of the motor nerve conduction, prolongation of DL, and a low terminal latency index without conduction block [12–15]. These findings were consistent with those in the median nerve of our patient. However, the temporal dispersion of distal CMAP in the tibial nerve was apparent before therapy. The temporal dispersion of distal CMAP in anti-MAG/SGPG neuropathy, defined as an interval of >9 ms between the onset of the first negative peak and return to base line of the last negative peak of the CMAP, has been detected in only 15 and 10.7% of the tibial and median nerves, respectively [2]. It is known that the temporal dispersion of distal CMAP is rarely seen in anti-MAG/SGPG neuropathy because it typically presents with a uniform involvement of fibers [2]. However, the lower limit of the temporal dispersion of distal CMAP has recently been shortened to less than 9 ms (median ≥ 6.6 ms and tibial ≥ 8.8 ms) [3, 11]. According to these criteria, distal CMAP in the median nerve of our patient was also slightly dispersed. The temporal dispersion of distal CMAP in anti-MAG/SGPG neuropathy may occur more frequently than has been reported in the past.

Responses to treatments with corticosteroids, intravenous immunoglobulin, plasma exchange and immunosuppressive agents are usually poor in anti-MAG/SGPG neuropathy [9]. Rituximab, a chimeric anti-CD20 monoclonal antibody, has recently been administered to patients with anti-MAG/SGPG neuropathy and improved the laboratory findings [4–9]. However, longitudinal investigations of electrophysiological studies of the patients treated with rituximab have been limited and controversial [4–8]. While some studies have shown the shortening of DL and the improvement of nerve conduction velocities [4, 5], others have shown a lack of electrophysiological improvement [6–8], and no studies have shown that rituximab improves the temporal dispersion of distal CMAP. Moreover, the relationship between the temporal dispersion of distal CMAP and motor symptoms, including the degree and duration of weakness, has not yet been investigated. In the lower extremities of most reported patients treated with rituximab, distal CMAP was already very small or had disappeared [4, 8], suggesting considerable progression of secondary axonal degeneration in the motor nerve. In contrast, our patient presented with only mild sensory symptoms before rituximab monotherapy based on Mayo Clinic consensus for management of newly diagnosed Waldenström macroglobulinemia [16]. We considered that active and heterogeneous demyelination at the motor nerve terminal in the tibial nerve, which has not yet induced prominent secondary axonal degeneration, would be seen during the first NCS. The temporal dispersion of distal CMAP in anti-MAG/SGPG neuropathy could occur at an early stage when the patients do not show significant motor symptoms. Administration of rituximab before the progression of secondary axonal degeneration has a great potential to reverse the effects of demyelination including the temporal dispersion of distal CMAP and to prevent the deterioration of neuropathy in anti-MAG/SGPG neuropathy associated with

Waldenström macroglobulinemia. Early treatment with rituximab may also be effective in patients with anti-MAG/SGPG neuropathy associated with monoclonal gammopathy of undetermined significance. As for the sensory nerves, we suspected that secondary axonal degeneration had already taken place, based on sensory nerve action potential measurements before therapy and the observation that parameters of the sensory NCS had not substantially improved after therapy.

Disclosure Statement

The authors have no conflict of interest.

References

- Viala K, Stojkovic T, Doncker AV, Maisonobe T, Lenglet T, Bruneteau G, Musset L, Neil J, Léger JM, Leblond V: Heterogeneous spectrum of neuropathies in Waldenström's macroglobulinemia: a diagnostic strategy to optimize their management. *J Peripher Nerv Syst* 2012;17:90–101.
- Gondim FA, De Sousa EA, Latov N, Sander HW, Chin RL, Brannagan TH: Anti-MAG/SGPG associated neuropathy does not commonly cause distal nerve temporal dispersion. *J Neurol Neurosurg Psychiatry* 2007;78:902–904.
- Isose S, Kuwabara S, Kokubun N, Sato Y, Mori M, Shibuya K, Sekiguchi Y, Nasu S, Fujimaki Y, Noto Y, Sawai S, Kanai K, Hirata K, Misawa S; Tokyo Metropolitan Neuromuscular Electrodiagnosis Study Group: Utility of the distal compound muscle action potential duration for diagnosis of demyelinating neuropathies. *J Peripher Nerv Syst* 2009;14:151–158.
- Renaud S, Fuhr P, Gregor M, Schweikert K, Lorenz D, Daniels C, Deuschl G, Gratwohl A, Steck AJ: High-dose rituximab and anti-MAG-associated polyneuropathy. *Neurology* 2006;66:742–744.
- Gruson B, Ghomari K, Beaumont M, Garidi R, Just A, Merle P, Merlusca L, Marolleau JP, Royer B: Long-term response to rituximab and fludarabine combination in IgM anti-myelin-associated glycoprotein neuropathy. *J Peripher Nerv Syst* 2011;16:180–185.
- Benedetti L, Briani C, Franciotta D, Carpo M, Padua L, Zara G, Zambello R, Sormani MP, Mancardi GL, Nobile-Orazio E, Schenone A: Long-term effect of rituximab in anti-mag polyneuropathy. *Neurology* 2008;71:1742–1744.
- Dalakas MC, Rakocevic G, Salajegheh M, Dambrosia JM, Hahn AF, Raju R, McElroy B: Placebo-controlled trial of rituximab in IgM anti-myelin-associated glycoprotein antibody demyelinating neuropathy. *Ann Neurol* 2009;65:286–293.
- Zara G, Zambello R, Ermani M: Neurophysiological and clinical responses to rituximab in patients with anti-MAG polyneuropathy. *Clin Neurophysiol* 2011;122:2518–2522.
- Joint Task Force of the EFNS and the PNS: European Federation of Neurological Societies/Peripheral Nerve Society Guideline on management of paraproteinemic demyelinating neuropathies. Report of a Joint Task Force of the European Federation of Neurological Societies and the Peripheral Nerve Society – first revision. *J Peripher Nerv Syst* 2010;15:185–195.
- Chassande B, Léger JM, Younes-Chennoufi AB, Bengoufa D, Maisonobe T, Bouche P, Baumann N: Peripheral neuropathy associated with IgM monoclonal gammopathy: correlations between M-protein antibody activity and clinical/electrophysiological features in 40 cases. *Muscle Nerve* 1998;21:55–62.
- Joint Task Force of the EFNS and the PNS: European Federation of Neurological Societies/Peripheral Nerve Society Guideline on management of chronic inflammatory demyelinating polyradiculoneuropathy: report of a joint task force of the European Federation of Neurological Societies and the Peripheral Nerve Society – First Revision. *J Peripher Nerv Syst* 2010;15:1–9.
- Kaku DA, England JD, Sumner AJ: Distal accentuation of conduction slowing in polyneuropathy associated with antibodies to myelin-associated glycoprotein and sulphated glucuronyl paragloboside. *Brain* 1994;117:941–947.
- Capasso M, Torrieri F, Di Muzio A, De Angelis MV, Lugaresi A, Uncini A: Can electrophysiology differentiate polyneuropathy with anti-MAG/SGPG antibodies from chronic inflammatory demyelinating polyneuropathy? *Clin Neurophysiol* 2002;113:346–353.
- Radziwill AJ, Steck AJ, Renaud S, Fuhr P: Distal motor latency and residual latency as sensitive markers of anti-MAG polyneuropathy. *J Neurol* 2003;250:962–966.
- Lupu VD, Mora CA, Dambrosia J, Meer J, Dalakas M, Floeter MK: Terminal latency index in neuropathy with antibodies against myelin-associated glycoproteins. *Muscle Nerve* 2007;35:196–202.

Kodaira et al.: Rituximab Improves Subclinical Temporal Dispersion of Distal Compound Muscle Action Potential in Anti-MAG/SGPG Neuropathy Associated with Waldenström Macroglobulinemia: A Case Report

- 16 Ansell SM, Kyle RA, Reeder CB, Fonseca R, Mikhael JR, Morice WG, Bergsagel PL, Buadi FK, Colgan JP, Dingli D, Dispenzieri A, Greipp PR, Habermann TM, Hayman SR, Inwards DJ, Johnston PB, Kumar SK, Lacy MQ, Lust JA, Markovic SN, Micallef IN, Nowakowski GS, Porrata LF, Roy V, Russell SJ, Short KE, Stewart AK, Thompson CA, Witzig TE, Zeldenrust SR, Dalton RJ, Rajkumar SV, Gertz MA: Diagnosis and management of Waldenström macroglobulinemia: Mayo stratification of macroglobulinemia and risk-adapted therapy (mSMART) guidelines. *Mayo Clin Proc* 2010;85:824–833.

Table 1. Parameters of NCS before and after rituximab therapy

Nerve	Rituximab therapy	DL ms	MCV m/s	CMAP mV	Duration of distal CMAP, ms	Terminal latency index	F lat ms	SCV m/s	SNAP μ V
Median L	Before	9.1	41.4	7.2	7.4	0.19	35.7	32.5	3.9
	After	7.4	47.5	5.9	7.2	0.20	32.5	27.3	5.5
Tibial L	Before	8.0	25.3	2.1	14	0.50	87.5		
	After	6.2	26.5	5.2	7.2	0.61	70.5		
Sural L	Before							45.8	1.8
	After							44.0	1.6

Abnormal parameters are shown in bold.

CMAP = compound muscle action potential; DL = distal latency; F lat = minimum F-wave latency; L = left; MCV = motor nerve conduction velocity; NCS = nerve conduction study; SCV = sensory nerve conduction velocity; SNAP = sensory nerve action potential.

Kodaira et al.: Rituximab Improves Subclinical Temporal Dispersion of Distal Compound Muscle Action Potential in Anti-MAG/SGPG Neuropathy Associated with Waldenström Macroglobulinemia: A Case Report

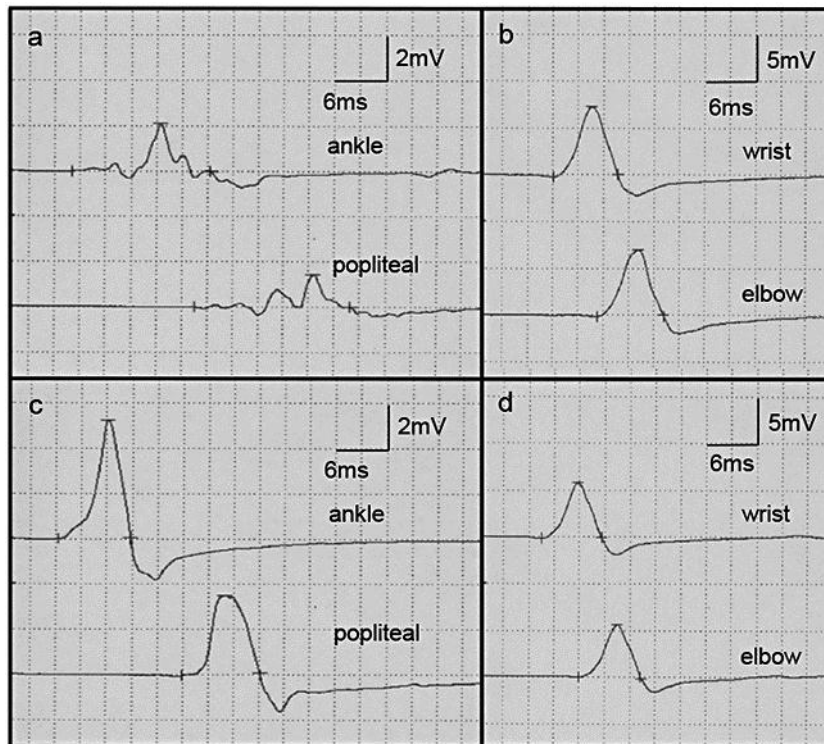


Fig. 1. Motor nerve conduction study of the tibial (**a, c**) and median nerves (**b, d**). Marked temporal dispersion of distal compound muscle action potential (CMAP) in the tibial nerve (**a**) improved after rituximab therapy (**c**). The waveform of the CMAP in the median nerve is unchanged (**b, d**).