

Access this article online

Quick Response Code:



Website:

www.e-tjo.org

DOI:

10.4103/tjo.tjo_45_21

Review of surgical devices using small aperture optics

Robert Edward T. Ang*, Michelle Marie Q. Araneta, Emerson M. Cruz

Abstract:

Small aperture optics work by blocking unfocused peripheral light rays while allowing central light rays to focus on the retina. This pinhole effect creates an extended depth of focus and has been used in presbyopia correction, improving intermediate and near vision without markedly affecting distance vision. Another beneficial effect of small aperture optics is reducing aberrations caused by irregular corneas or irregular pupils. The first small aperture surgical device was the Kamra corneal inlay used on the nondominant eyes of presbyopic emmetropes. The pinhole concept was also adapted into the IC-8 intraocular lens (IOL) for presbyopia correction during cataract surgery and by the XtraFocus piggyback device to lessen unwanted aberrations in eyes with irregular corneas or pupils. The IC-8 IOL can be placed monocularly or binocularly with mini-monovision for further near vision improvement. The XtraFocus piggyback device can be placed either in the sulcus or capsular bag. The aim of this literature review is to synthesize evidence on the efficacy, safety, and patient-reported outcomes on surgical devices utilizing small aperture optics. A comprehensive search on PubMed was conducted with the keywords “small aperture optics,” “small aperture corneal inlay,” “small aperture IOL,” “Kamra corneal inlay,” “IC-8 IOL,” and “XtraFocus.” In this review, we describe the progression of small aperture surgical devices, patient criteria, visual outcomes, complications, satisfaction, and recommendations for surgical success.

Keywords:

Complex corneas, extended depth of focus, IC-8, irregular pupils, Kamra, presbyopia, small aperture, Xtrafocus

Introduction

Small aperture optics work by increasing depth of focus as unfocused peripheral light rays are blocked by an opaque mask while only the central light rays can pass through. This pinhole effect narrows the retinal blur circle, resulting in near and intermediate vision improvement without much effect on distance vision. The first commercially approved small aperture surgical device is the Kamra corneal inlay (CorneaGen, Seattle, Washington, USA), an opaque ring-shaped device. It is the only corneal implant that uses small aperture optics to correct presbyopia. Accommodation is gradually lost due to aging, but accommodation loss also occurs

after cataract surgery when a monofocal intraocular lens (IOL) is implanted. An annular mask similar to the Kamra corneal inlay was embedded inside a monofocal IOL to create the small aperture IC-8 IOL (Acufocus Inc., Irvine, California, USA). It employs the same extended depth of focus mechanism as the Kamra corneal inlay for presbyopia correction but located at the lens plane and with the ability to correct refractive errors.

Irregular corneas or irregular pupils cause unwanted aberrations and patients who suffer from these conditions can benefit from the aberration-reducing capability of small aperture optics. The Xtrafocus small Aperture piggyback device (Morcher, Stuttgart, Germany) is black and shaped like a C-loop IOL. It is implanted in the sulcus or inside the capsular bag. Both

This is an open access journal, and articles are distributed under the terms of the Creative Commons Attribution-NonCommercial-ShareAlike 4.0 License, which allows others to remix, tweak, and build upon the work non-commercially, as long as appropriate credit is given and the new creations are licensed under the identical terms.

For reprints contact: WKHLRPMedknow_reprints@wolterskluwer.com

How to cite this article: Ang RE, Araneta MM, Cruz EM. Review of surgical devices using small aperture optics. Taiwan J Ophthalmol 2022;12:282-94.

Asian Eye Institute, Makati City, Philippines

*Address for correspondence:

Dr. Robert Edward T. Ang,
Asian Eye Institute,
8th Floor PHINMA
Plaza, Rockwell Center,
Makati City, Philippines.
E-mail: angbobby@
hotmail.com

Submission: 15-08-2021
Accepted: 05-10-2021
Published: 07-01-2022

the XtraFocus device and the IC-8 IOL can filter out unwanted aberrations, thereby improving the overall vision of the pseudophakic eye. In this review, we condense published literature and describe the patient selection, surgical techniques, postoperative outcomes, and the current status of these three small aperture surgical devices, namely the Kamra corneal inlay, IC-8 IOL, and XtraFocus piggyback device.

Methods

This literature review was conducted through a systematic search on the PubMed database. The search term applied was “small aperture optics” OR “small aperture corneal inlay” OR “small aperture IOL” OR “Kamra corneal inlay” OR “IC-8 IOL” OR “XtraFocus.” Results revealed 88 articles that spanned from 2010 until the last search done on May 5, 2021. The abstracts were read to identify small aperture corneal inlay, IOL, or device studies with main outcomes of efficacy, safety, visual quality, and satisfaction. Non-English entries, case reports, and research articles with main results other than the stated outcomes were excluded. The full-length articles were retrieved and those that reported original clinical data were chosen. Relevant studies in the references of the remaining articles were added in. The most updated outcomes were included for studies with several publications. Five articles initially considered were excluded because they had more recent publications with the same subject population [Figure 1]. The final list was comprised 26 articles.

Small Aperture Corneal Inlay

Patient selection

The Kamra corneal inlay was placed in the nondominant eye of emmetropic presbyopes with manifest refraction spherical equivalent (MRSE) of ± 0.50 D to improve intermediate and near vision, while the fellow eye was used mainly for distance vision for a modified monovision effect. While the inlay itself was not designed to change the refraction of patients, it was later observed that eyes with postoperative refraction of -0.50 D to -0.75 D, good ocular surface, and stable tear film benefited the most from this inlay.^[1] The slight myopia whether natural or achieved when the procedure was combined with laser *in-situ* keratomileusis (LASIK) lead to more improvement of near vision with no significant effect on distance vision.^[2]

Patients who frequently drive at night, want perfect results immediately, and are unable to follow-up in the clinic are not good candidates for the corneal inlay.^[2] Eye dryness, glare, halo, night-vision disturbances, and haze may occur in some and must be discussed before

surgery. Postoperatively, patients were encouraged to reduce the use of reading glasses to help with neuroadaptation.^[3,4] The characteristics of the Kamra corneal inlay along with the IC-8 IOL and the XtraFocus piggyback device are listed in Table 1. Pointers on surgical techniques for these three small aperture surgical devices are in Table 2.

Efficacy and Refractive Stability

Numerous studies found the Kamra corneal inlay as safe and effective in treating presbyopia with the significant increase in the uncorrected near visual acuity (UNVA) and minimal difference in uncorrected distance visual acuity (UDVA) [Table 3].^[1-4,11,16-24] Uncorrected intermediate visual acuity (UIVA) also improved.^[1,17,18,24] The United States Food and Drug Administration (USFDA) clinical trial reported that at 3 years postoperatively, UNVA mean increase was three or more lines, mean UDVA decreased by around half a line, mean corrected distance visual acuity (CDVA) decreased by one letter at most, and visual acuities of the implanted eyes improved binocularly for all distances.^[1] Simultaneous LASIK with the current Kamra inlay model showed preoperative mean UNVA of J6 (range J2 to J16) in the inlay eyes and at 5 years postoperatively was maintained at J1 or better (range better than J1 to J2) with sustained mean UDVA of 20/30.^[23]

Safety, Contrast Sensitivity, and Satisfaction

The published outcomes reported CDVA loss of two or more lines from 0% to 15% for the current model of the Kamra inlay [Table 4].^[1-4,11,19,20,22-25] Although there were statistically significant decreases for photopic and mesopic contrast sensitivities in the Kamra inlay eyes, the values were still within age-correlated normative values at all spatial frequencies.^[19,26,27] The patients were generally satisfied with their ease of performing near and intermediate tasks, and majority would opt to undergo treatment again.^[10,18] There were reports of glare, halos, and night-vision problems but most ranked them as mild.^[1,4,20]

Explantation and Complications

According to the Kamra corneal inlay USFDA clinical trial, 44 explantations (8.7%) occurred in a span of 3 years amongst their 507 inlay patients from 24 clinical sites.^[1] Explantations due to visual complaints in this population happened in 38 of the 507 patients (7.5%). When only patients with the $6 \mu\text{m} \times 6 \mu\text{m}$ or tighter spot/line setting femtosecond laser-assisted corneal pocket were analyzed, the explantation rate due to visual

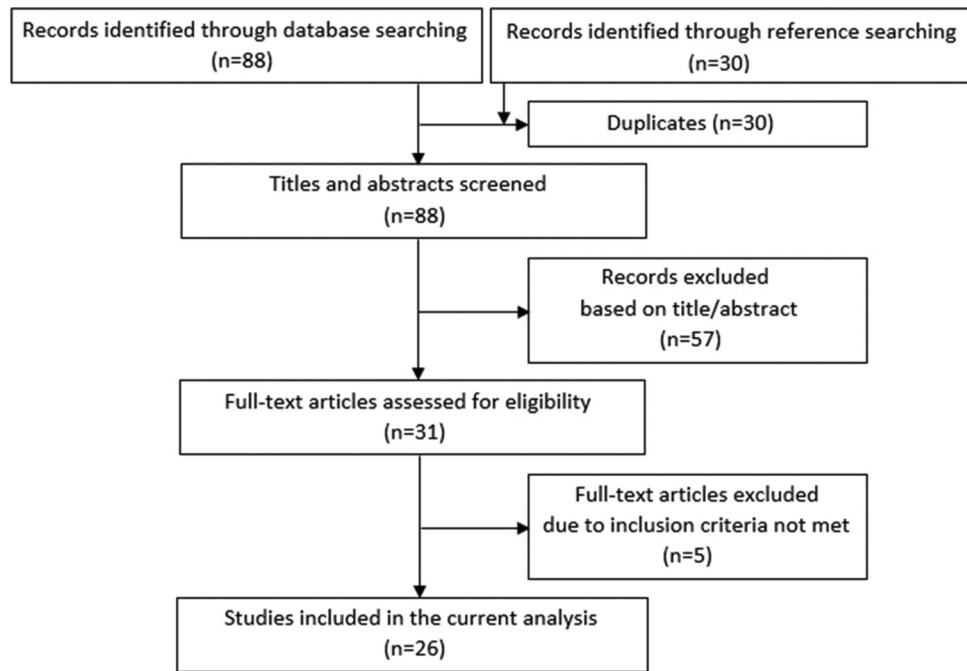


Figure 1: Flow chart showing the study selection process

Table 1: Description of the three small aperture optics devices currently available in select countries

	Kamra Corneal Inlay (3rd generation¹)	IC-8 IOL	XtraFocus piggyback device
Material	Polyvinylidene fluoride and nano particles of carbon to make the inlay opaque ²	Hydrophobic acrylic ⁵	Black hydrophobic acrylic which blocks visible light but is transparent to infrared light to permit retinal examination ⁶
Specifications	Ring-shaped device with outer diameter of 3.8 mm, a central aperture of 1.6 mm, thickness of 5 µm, 8400 holes in a random pattern for adequate nutritional flow (5-11 µm), and 5% light transmission rate ⁷	Optic diameter of 6 mm with a 3.23 mm black circular mask, a central 1.36 mm nondiffractive clear circular aperture, overall diameter of 12.5 mm, thickness of 5 µm, 3200 microperforations, available powers of +15.5 D to +27.5 D, and a 120.5 recommended A-constant ⁵	6 mm diameter for the occlusive part with a concave-convex design and no refractive power, central opening of 1.3 mm, overall diameter of 13.5 mm, haptics that are rounded, well-polished, and only 250 µm thick to avoid uveal tissue injury, with a 14° angulation to prevent iris chafing and pigment dispersion ⁸

¹Current model: ACI7000PDT (1st generation: ACI7000, 2nd generation: ACI7000PD); IOL=Intraocular lens

Table 2: Surgical technique for the small aperture optics devices

Kamra Corneal Inlay	IC-8 IOL	XtraFocus piggyback device
Implanted in a femtosecond laser created pocket for decreased corneal nerve effect and biomechanical changes instead of a corneal flap ¹⁰	Implanted in the capsular bag using a proprietary injector through a clear corneal incision, enlarged to 3.5 mm to avoid excessive folding of the IOL and small aperture mask ^{12,13}	May be placed at the sulcus or anterior to the primary IOL in the capsular bag at the same session as the phacoemulsification or subsequently in pseudophakes ⁶
Corneal pocket should have a 6 µm×6 µm or tighter spot/line separation for reduced postoperative refractive shifts, better visual outcomes, and more patient satisfaction ¹¹	Centered in the capsular bag with the haptics oriented vertically with slight nasal bias ¹⁴	Implanted through a 2.2 mm corneal incision with no particular haptics orientation ⁶
Pocket must be 250 µm or deeper to lessen the inflammatory cascade and hyperopic shift ¹¹	Majority of the studies targeted -0.75 D MRSE for monocular implantation	Centered on the first Purkinje reflex after complete removal of the OVD ⁶
Centered on the first Purkinje image, considered the best approximation of the visual axis, while the patient is fixated on the light source of the operating microscope ¹⁰	When implanted in patients with severe corneal irregularities, target refraction was plano and the Haigis formula was used for IOL power calculation ¹³	
	Bilateral IC-8 implantation targeted emmetropia for the dominant eye and mild myopia (-0.5D to -0.75D) for the nondominant eye ^{15,16}	

MRSE=Manifest refraction spherical equivalent, OVD=Ophthalmic viscosurgical device, IOL=Intraocular lens

complaints was lowered to 3% (5 of 166 patients).¹¹ The rest of the cohort had an explantation rate of 9.7%

(33 of 341 patients), comprised patients who either had the inlay placed in a corneal pocket created by a

Table 3: Published visual acuity outcomes of Kamra corneal inlay

Study ^a	n	Mean age (years)	F/U (months)	UDVA ≥ 20/25	UIVA ≥ 20/25	UNVA ≥ J3	Binocular UDVA ≥ 20/25	Binocular UIVA ≥ 20/25	Binocular UNVA ≥ J3
Inlay on emmetropes									
Yilmaz <i>et al.</i> , 2011 ^{[17]b}	39 ^e	52	52	77%	NA	96%	96%	NA	96%
Dexl <i>et al.</i> , 2015 ^{[18]b}	32	51	60	84%	20/32	74%	94% ≥ 20/20	87% ≥ 20/32	74%
Vukich <i>et al.</i> , 2018 ^{[1]d}	507	53	36	93%	69%	72% ≥ 4	100%	81%	85% ≥ J4
Seyeddain <i>et al.</i> , 2013 ^{[19]d}	24	52	24	96%	20/25	J2	20/16	96%	96% ≥ J4
Moshirfar <i>et al.</i> , 2016 ^{[11]d}	57 ^f	54	6	65%	NA	63% ≥ J5 ^g ; 86% DP, 38% SP ≥ J4	NA	NA	77% ≥ J5
Inlay on post-LASIK									
Tomita <i>et al.</i> , 2013 ^{[20]d}	223	54	6	86%	NA	83% ^h	100%	NA	90% ^h
Inlay with LASIK/PRK									
Tomita <i>et al.</i> , 2012 ^{[2]d}	360	52	6	H: 94% E: 100% M: 85%	NA	H: 69% E: 86% M: 90% ≥ J4	H, E, M: 100% ≥ 20/20	H: 25% E: 57% M: 68% ≥ J1	NA
Tomita and Waring 2015 ^{[21]c,j}	I. 21 II. 154 III. 102	I. 47 II. 55 III. 62	12 12 12	86% 88% 85%	NA NA NA	J2 J3 J3	86% 72% 62%	NA NA NA	95% 84% 73%
Jalali <i>et al.</i> , 2016 ^{[22]d}	50	55	12	92% ≥ 20/32	NA	94%	NA	NA	NA
Igras <i>et al.</i> , 2016 ^{[3]d}	132	56	12	20/25	NA	97%	20/20	NA	J3
Moshirfar <i>et al.</i> , 2018 ^{[23]d, k}	I. 79 II. 47	50 52	6 6	68% 59%	NA NA	95% ≥ J5 83% ≥ J5	NA NA	NA NA	NA NA
Abdul Fattah <i>et al.</i> , 2020 ^{[24]d}	24	54	60	67%	NA	96%	NA	NA	NA
Inlay on pseudophakes									
Huseynova <i>et al.</i> , 2014 ^{[4]d}	13 ^l	55	3	20/20	NA	J4	NA	NA	NA
Elling <i>et al.</i> , 2018 ^{[25]d}	8	71	3	20/30	20/30	J4	20/20	20/20	J2

^aFirst author and year study was published, ^b1st generation Kamra corneal inlay: ACI7000, ^c2nd generation Kamra corneal inlay: ACI7000PD, ^d3rd generation Kamra corneal inlay: ACI7000PDT, ^e27 patients were post-LASIK, ^f13 patients were post-LASIK, 2 were pseudophakic, ^gSub-analyzed after based on depth of inlay implantation (deep pocket ≥ 250 μm, shallow pocket < 250 μm), ^hNear vision measured at 30 cm (standard in Japan; international standard at 40 cm), ⁱAll LASIK patients except for Moshirfar *et al.*, 2018^[23] who also had PRK patients; studies included hyperopic, emmetropic, and myopic patients except for Tomita and Waring 2015^[21] and Abdul Fattah *et al.*, 2020^[24] who only had hyperopic patients, ^jPatients subgrouped by age: I. 45-49 years old, II. 50-59 years old, III. 60-65 years old, ^kPatients subgrouped by treatment: I. LASIK, II. PRK, ^l4 patients with simultaneous LASIK, [†]Target refraction -0.75 D for all^[1-4,11,17-21,23,24] except for Jalali *et al.*^[22] and Elling *et al.*^[25] (target of plano). DP=Deep pocket, E=Emmetropes, F/U=Follow-up, H=Hyperopes, J=Jaeger, LASIK=Laser *in-situ* keratomileusis, M=Myopes, n=Number of implanted eyes, NA=Not available, PRK=Photorefractive keratectomy, SP=Shallow pocket, UDVA=Uncorrected distance visual acuity, UIVA=Uncorrected intermediate visual acuity, UNVA=Uncorrected near visual acuity

femtosecond laser with spot/line setting larger than 6 μm × 6 μm or in a corneal flap created by a mechanical microkeratome. Among the patients who were part of the rest of the cohort, the explantation rate was lowered to 5.7% (6 of 107) when implantation was at 40% or deeper of the total corneal thickness while that of the shallower subgroup was 11.5% (27 of 235). The five explantations due to visual complaints from the 6 μm × 6 μm or tighter pocket group had the inlay

implanted at shallower than 40% of the total corneal thickness. The explantation rate was 0% for patients who had the 6 μm × 6 μm or tighter spot/line setting corneal pocket with the Kamra corneal inlay implanted at a depth of at least 40% of the total corneal thickness.^[1] Reasons for explantation were insufficient uncorrected visual acuities, dissatisfaction from refractive shifts, suboptimal adaptation, and corneal haze.^[1,3,11,17,18,20,22] The high incidence of iron deposits occurred with

Table 4: Published Kamra corneal inlay refractive outcomes, safety, explantation, complications, and subjective reports

Study ^a	Study type	SE (diopters)	Refractive shift	CDVA loss ≥ 2 lines	Explant rate	Recentration and/or other complications	Satisfaction and/or visual symptoms	Spectacle independence
Inlay on emmetropes								
Yilmaz <i>et al.</i> , 2011 ^{[17]b}	Prospective, unmasked	-0.28	9% >1 D myopic shift 5% >1 D hyperopic shift	5%	10%	10% dry eyes 13% epithelial ingrowth	Significant discomfort from glare and halos in 2 patients (-2 D, +3 D refractive shift) resulting in explantation	Nearly all were happy with spectacle independence for near
Dexl <i>et al.</i> , 2015 ^{[18]b}	Prospective, nonrandomized, noncomparative cohort	+0.40	NA	23%	3%	6% recentration, 3% flap striae and epithelial ingrowth, 56% corneal epithelial iron deposits (central/half-moon/ring)	83.9% would have the treatment again, 9.7% undecided, 6.4% no	NA
Vukich <i>et al.</i> , 2018 ^{[1]d}	Prospective, nonrandomized, multicenter, open-label, single-arm	NA	Hyperopic refractive shift at 6 to 12 months, stabilized from 24 to 36 months	<2%	9%	1% recentration, 2.6% 1+ corneal edema/haze, 0.2% 2+ corneal edema/haze (significantly less for 6 μm \times 6 μm pocket group), 1.9% severe dryness	6 μm \times 6 μm : Near tasks much easier, distance tasks slightly reduced but still graded as easy; satisfaction at 5.5/7, 1.7% severe glare, 1.4% severe halos, 2.8% severe night vision problems	Increase in satisfaction with near vision without spectacles from 1.6 to 5 on a Scale of 1-7
Seyeddain <i>et al.</i> , 2013 ^{[19]d}	Prospective, nonrandomized, noncomparative cohort	-0.11	13% myopic shift $\geq 1\text{D}$	0%	0%	4% epithelial ingrowth, 4% brown iron deposits (half-moon shape), some developed a thin haze at the outer/inner inlay rim	NA	NA
Moshirfar <i>et al.</i> , 2016 ^{[11]d}	Retrospective	-0.10	36% hyperopic shift ≥ 0.75 D in SP, 0% in DP group	0%	2%	9% recentration	60% reported some level of satisfaction, 16% of whom were very satisfied	62% were able to do most things (>75%) without reading glasses in good light
Inlay on post-LASIK								
Tomita <i>et al.</i> , 2013 ^{[20]d}	Prospective, interventional, noncomparative case series	NA	NA	0%	<1%	Significant increase for dryness but still ranked as mild	Significant increase in satisfaction and ease for visual tasks at all distances, significant increase in glare, halo, and night-vision disturbances but still mild	Significant increase in not needing reading glasses under bright light

Contd...

Table 4: Contd...

Study ^a	Study type	SE (diopters)	Refractive shift	CDVA loss ≥2 lines	Explant rate	Recentration and/or other complications	Satisfaction and/or visual symptoms	Spectacle independence
Inlay with LASIK/ PRK ^e								
Tomita <i>et al.</i> , 2012 ^{[2]d}	Prospective, non-comparative cohort	NA	1.1% hyperopic shift >1 D	H: 0% E: 0% M: 5%	0%	1.1% recentration, occasional dry eyes	Significant increase in satisfaction with the vision for H and E groups; reports of halo, glare, night-vision disturbances	Significant decrease in the need for reading glasses for all 3 groups (H, E, M)
Tomita and Waring 2015 ^{[21]c,f}	Retrospective, comparative cohort	i. -0.91 ii. -0.72 iii. -0.74	NA	0% 1% 2%	0% 0% 0%	None	Very satisfied: I: 69%, II: 84%, III: 87%, no significant between group differences for visual tasks/ symptoms	Used reading glasses less: I: 100%, II: 97%, III: 92%
Jalali <i>et al.</i> , 2016 ^{[22]d}	Prospective, nonrandomized cohort	0.0	NA	4%	2%	2% recentration	NA	NA
Igras <i>et al.</i> , 2016 ^{[3]d}	Retrospective chart review	-0.45	4% hyperopic shift ≥1 D	0%	1.5%	16% dry eyes at 6 months, 3% epithelial growth, <1% corneal haze	>90% satisfied, 1/5 noted deterioration of night driving	1/3 still required reading glasses intermittently
Moshirfar <i>et al.</i> , 2018 ^{[23]d,g}	Retrospective	I. -0.79 II. -0.38	Significant hyperopic shift, with PRK >LASIK	1% 2%	0% 0%	LASIK: 3% recentration, 1% flap-related epithelial ingrowth, PRK: 2% recentration	NA	NA
Abdul Fattah <i>et al.</i> , 2020 ^{[24]d}	Retrospective	-0.29	25% hyperopic shift 1 D	0%	0%	4% recentration, 4% epithelial ingrowth, 4% flap striae, 13% haze	NA	NA
Inlay on pseudophakes								
Huseynova <i>et al.</i> , 2014 ^{[4]d}	Retrospective	-1.12	NA	15%	0%	NA	77% would have the treatment again, 23% no; severe: halo 15%, glare 8%, night vision problems 15%	NA
Elling <i>et al.</i> , 2018 ^{[25]d}	Prospective, randomized	-0.39	NA	NA	0%	NA	NA	NA

^aFirst author and year study was published, ^b1st generation Kamra corneal inlay: ACI7000, ^c2nd generation Kamra corneal inlay: ACI7000PD, ^d3rd generation Kamra corneal inlay: ACI7000PDT, ^eAll LASIK patients except for Moshirfar 2018^[23] who also had PRK patients; included hyperopic, emmetropic, and myopic patients except for Tomita and Waring 2015^[21] and Abdul Fattah *et al.*, 2020^[24] who only had hyperopic patients, ^fPatients subgrouped by age: I. 45-49 years old, II. 50-59 years old, III. 60-65 years old, ^gPatients subgrouped by treatment: I. LASIK, II. PRK, ^hTarget refraction -0.75 D for all^[1-4,11,17-21,23,24] except for Jalali *et al.*^[22] and Elling *et al.*^[25] (target of plano). CDVA=Corrected distance visual acuity, DP=Deep pocket, E=Emmetropes, H=Hyperopes, LASIK=Laser *in-situ* keratomileusis, M=Myopes, NA=Not available, PRK=Photorefractive keratectomy, SE=Spherical equivalent, SP=Shallow pocket

the first generation corneal inlay implanted under a 170 µm femtosecond laser-assisted flap with no effect on visual acuities up to 5 years follow-up.^[18] Iron deposits were found in far less patients with the current inlay model with no effect on vision or refraction at 2 years postoperatively.^[19]

Corneal Iron Deposition

There have been three generations of the Kamra corneal inlay, the ACI7000, ACI7000PD, and the latest being the ACI7000PDT, with PDT standing for pattern, darker, and thinner.^[9] The first generation had 1600 microperforations,

7.1% light transmission, and 10 μm thickness.^[18] The second generation Kamra inlay was made darker with 5% light transmission but with more microperforations at 8400 while the third generation incorporated the thinner design of 5 μm .^[9] The increased number of microperforations in the latest version of the inlay improved nutritional flow through the cornea, the thinner design resulted in less biomechanical changes, and the decreased light transmission helped reduce visual symptoms.

Dexl *et al.* had corneal iron deposits in 37.5% of their patients (12 out of 32) at 2 years follow-up after implantation of the first generation Kamra inlay.^[7] The location of the corneal iron deposits was correlated with the flattened areas within the corneal surface due to the inlay and where the tear film would break up.^[7] Seyeddain *et al.* reported corneal iron deposits in 4.17% of their patients (1 out of 24) 2 years after implantation of the third generation Kamra inlay.^[19] The high incidence of iron deposits occurred with the first generation Kamra corneal inlay implanted under a 170 μm femtosecond laser-assisted flap.^[18] The iron deposits may be partly due to the tear film changes secondary to the slight corneal topography variations produced by the inlay.^[7] The thinner third-generation inlay implanted in a deeper corneal pocket facilitated the decrease in corneal topography changes.^[19] This meant less changes in the tear film thickness, its composition, and the corneal epithelial basal cell storage resulting in decreased corneal iron deposition.^[7] Despite the high incidence of corneal iron deposits with the first generation Kamra inlay, there was no effect on visual acuities up to 5 years follow up.^[18] There was lower incidence of iron deposits with the current third generation inlay model and these iron deposits also had no effect on vision or refraction at 2 years postoperatively.^[19]

Current Status of the Kamra Corneal Inlay

Interest in the different types of corneal inlays and their usage has declined in the past few years. Most presbyopic patients have co-existing refractive errors which cannot be corrected by the Kamra inlay, limiting its use as a standalone procedure. Long-term biocompatibility was being questioned given the corneal haze seen over and around the inlay. Being a foreign body in the cornea, the Kamra inlay may develop stromal fibrosis that results in hyperopic shifts and decrease in both distance and near vision. From our experience, if explantation is performed, a hazy imprint with the shape of the inlay is left behind but does not seem to progress in density over time [Figure 2a and b].

Small Aperture Intraocular Lens

Patient selection

The IC-8 IOL was initially targeted for patients who desired more spectacle independence after cataract

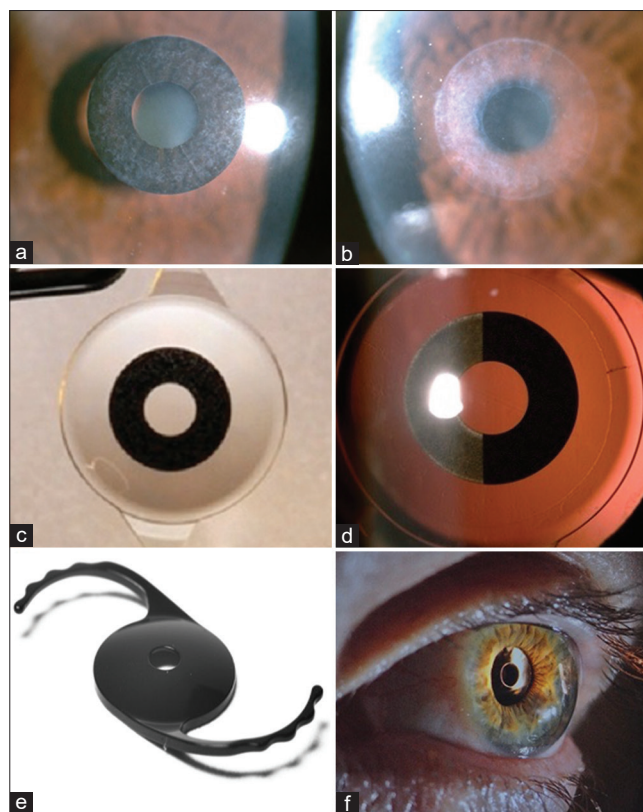


Figure 2: (a) Kamra corneal inlay showing grade 1 haze. (b) The corneal haze imprint after explantation of a Kamra corneal inlay. (c) The IC-8 intraocular lens features a small aperture mask embedded at the center of the optic. (d) The small aperture mask of the IC-8 IOL has microperforations similar to the Kamra corneal inlay. (e) The XtraFocus piggyback device is opaque but is transparent under infrared imaging. (f) The XtraFocus device is intended for pseudophakes and may be implanted in the sulcus or capsular bag (images e and f courtesy of Claudio C. Trindade, MD, PhD, Cancado-Trindade – Brazil)

surgery through its extended depth of focus mechanism [Figure 2c and d]. Surgeons later discovered the potential of the small aperture IOL in complex corneas and eyes with corneal astigmatism up to 1.50 D. The patients in the Shajari *et al.* study, 64.7% of whom did not have cataracts, had nonprogressive advanced keratoconus, corneal scarring after ocular trauma without central corneal opacity, previous penetrating keratoplasty, or ectatic radial keratotomy.^[13] An important criteria for screening IC-8 candidates for surgery is a mesopic pupil size of less than 6 mm as halo, doubling, and vision fluctuation were significantly correlated to larger pupil sizes that may enlarge beyond the outer diameter of the mask.^[5,14]

Efficacy, Defocus Curve, Satisfaction, and Visual Symptoms

High rates of binocular UDVA and UIVA of 20/25 or better and UNVA of J3 or better were achieved in the IC-8 IOL patients [Table 5].^[5,12,14-16,28] The first IC-8 IOL publication by Grabner, Ang, and Vilupuru

Table 5: Published outcomes of IC-8 intraocular lens

Study ^a	Study type	Number of patients (mean age, follow-up)	SE (diopters)	UDVA ≥20/25	UIVA ≥20/25	UNVA ≥J3	Binocular UDVA ≥20/25	Binocular UIVA ≥20/25	Binocular UNVA ≥J3
Monocular IC-8									
Grabner <i>et al.</i> , 2015 ^[28]	Prospective, Nonrandomized, noncomparative, multicenter case series	12 (61 y/o, 12 months)	-0.10	100% ≥20/32	92% ≥20/32	83%	100% ≥20/32	100% ≥20/32	92%
Dick <i>et al.</i> , 2017 ^[14]	Prospective case series	105 (68 y/o, 6 months)	-0.42	20/23	20/24	J3	96%	87%	79%
Hooshmand <i>et al.</i> , 2019 ^[5]	Retrospective, nonrandomized case series	126 (68 y/o, 7 months)	NA	20/26	20/25	J2	98% ≥20/30	94% ≥20/40	91%
Contralateral versus bilateral IC-8									
Dick <i>et al.</i> , 2018 ^[15]	Prospective case series	11 C 6 B (68 y/o, 6 months)	NA NA	64% 50%	45% 67%	45% ≥J4 100% ≥J4	100% 100%	100% 83%	82% 100%
Ang 2020 ^[16]	Prospective, nonrandomized, noncomparative clinical trial	10 C 10 B (63 y/o, 12 months)	-0.58 DE: -0.33 NDE: -0.60	NA NA	NA NA	NA NA	100% 90%	100% 100%	100% 100%
Monocular IC-8 versus binocular technis symfony									
Schojai <i>et al.</i> , 2020 ^[12]	Prospective randomized comparative clinical trial	18 IC-8 18 Symfony (69 y/o, 3 months)	DEb: 0.1 NDE: -0.53 DE: 0.1 NDE: -0.66	20/21 20/26 20/26 20/33	20/38 20/21 20/22 20/22	J5 J3 J3 J3	20/20 20/23	20/20 20/20	J2 to J3 J2
Monocular IC-8 on eyes with severe corneal irregularities									
Shajari <i>et al.</i> , 2020 ^[13]	Prospective, nonrandomized interventional case series	17 (54 y/o, 3 months)	-1.22	20/31	20/49	J5 to J6	NA	NA	NA
Monocular IC-8 or AT lisa tritoric on eyes with previous radial keratotomy									
Agarwal and Thornell 2020 ^[29]	Retrospective case series	3 (70 y/o, NA) 1c (69 y/o, NA)	1st px: -1.00 2nd px: -0.25 3rd px: -0.88 OD: -1.75 OS: -1.75	20/20 20/40 20/25 20/63 20/30 20/32 20/32	20/16 20/40 20/16 20/32 20/32	J3 J6 J6 J6	20/20 20/25 20/20 20/30	20/16 20/12.5 20/16 20/32	J2 J3 J4 to J5 J4 to J5

^aFirst author and year study was published, ^bMonofocal aspheric IOL, ^cBilateral AT Lisa Tritoric IOL, ^dSchojai *et al.*^[12] monocular and binocular UDVA measured under photopic light conditions, ^eTarget refraction -0.75 D for the majority^[5,12,13,28], except for Shajari *et al.*^[13] and all DE (target of plano), Dick *et al.*^[14,15] and Ang^[16] NDE (-0.5 D to -0.75 D), and Agarwal^[29] OD, OS (0 D to ±0.5 D). B=Bilateral, C=Contralateral, DE=Dominant eye, J=Jaeger, m=Months, NA=Not available, NDE=Nondominant eye, OD=Right eye, OS=Left eye, px=Patient, SE=Spherical equivalent, UDVA=Uncorrected distance visual acuity, UIVA=Uncorrected intermediate visual acuity, UNVA=Uncorrected near visual acuity, y/o=Years old, IOL=Intraocular lens

reported mean UDVA, UIVA, and UNVA monocular implantation results of 20/20, 20/25, and J2, respectively, while binocular values were 20/20, 20/21, and J2, respectively.^[28] The mean satisfaction score was 5.1 (1 very dissatisfied, 7 very satisfied).^[28]

Dick *et al.* reported that mean UDVA was better in the monofocal IOL eyes by half a line while the IC-8 IOL

eyes had better mean UIVA and UNVA by two lines and three lines, respectively.^[14] Mean binocular defocus curves with distance correction had visual acuity of 20/32 or better over a range of about 2.15 D of defocus. Functional near vision range was extended by an additional diopter using -0.75 D target-corrected defocus curves without loss of distance vision compared with the distance-corrected defocus curves.

All the patients in the contralateral and bilateral IC-8 IOL study achieved good vision, satisfaction, and low visual symptoms even if the lens was implanted irrespective of eye dominance.^[16] The bilateral group extended depth of focus by 0.25 D, had 0.5 to one line greater binocular UIVA and UNVA, higher spectacle independence, and better overall satisfaction than the contralateral group. In another study, bilateral IC-8 IOL implantation resulted in higher curves in the defocus curve analysis while maintaining the same peak as those contralaterally implanted with the IC-8 IOL.^[15]

Uncorrected visual acuities remained the same in the IC-8 IOL eyes up to 1.5 D of residual astigmatism.^[5,14] As for induced astigmatism, Ang investigated this across three axes (with-the-rule, against-the-rule, and oblique) for three types of IOLs.^[30] When all astigmatic axes were combined, no more than one line of loss from baseline visual acuity occurred with induced astigmatic defocus of up to 1.40 D for the IC-8 IOL small aperture patients, 1.00 D for the enVista IOL (Bausch and Lomb, Rochester, NY, USA) monofocal patients, and 0.70 D for the FineVision IOL (PhysIOL SA, Liege, Belgium) and AT Lisa IOL (Carl Zeiss AG, Jena, Germany) trifocal patients.^[30] This greater tolerance for astigmatism with the IC-8 IOL translates to simplified IOL implantation compared to toric IOLs, wherein alignment is crucial and IOL rotation is a possibility. Additional procedures for astigmatic management such as limbal relaxing incisions may be reduced. Furthermore, there is less risk for dissatisfaction when an IC-8 IOL is used compared to a multifocal or trifocal IOL if there is residual astigmatism of -0.75 D to -1.5 D.

Most of the IC-8 IOL contralateral studies had monofocal IOL in the fellow eye. Hooshmand *et al.* performed IC-8 IOL implantation typically in the nondominant eye and if the fellow eye required cataract surgery, a monofocal, toric monofocal, or multifocal IOL was implanted.^[5] In the extended depth of focus (EDOF) IOL comparative studies, Schojai *et al.* reported that both the IC-8 and Tecnis Symphony ZXR00 IOL (Johnson and Johnson Vision Care, Inc., Santa Ana, CA, USA) widened the range of functional binocular CDVA to the hyperopic and myopic sides of the defocus curve.^[12] However, the IC-8 group showed more tolerance for hyperopic outcomes as they had a statistically significant wider range of functional vision in the hyperopic range compared to the Symphony group. Another study compared the IC-8 IOL, Symphony IOL, and WIOL (Medicem, Czech Republic) and the authors found that these three EDOF IOLs had no statistically significant differences in postoperative visual acuities and amount of reported glare or starburst postoperatively.^[31]

Shajari *et al.* investigated the IC-8 IOL in eyes with severe corneal irregularities, most of whom preoperatively had

early cataracts or none.^[13] Despite this, 94% had better postoperative CDVA compared to preoperatively, were able to perform daily tasks better, and had high satisfaction rates with the IC-8 IOL. Agarwal *et al.* implanted the IC-8 IOL on three patients with irregular astigmatism who had bilateral radial keratotomy from more than 20 to 30 years ago.^[29] Stereopsis was maintained in the IC-8 IOL eyes, majority did not need spectacles, and no visual disturbances were reported despite the high preoperative total corneal higher-order aberrations (HOAs) and coma scores, the lowest being 0.210 μm and 0.098 μm respectively.^[29]

Contrast Sensitivity, Visual Field, and Retina Examinations

Eyes with the monofocal IOL had significantly better mesopic contrast sensitivity without glare at 1.5, 3, 6, and 12 cycles per degree (cpd) and with glare at 1.5, 3, and 6 cpd compared with the eyes implanted with the IC-8 IOL but were still within the upper and lower limits of normative values developed from the monofocal IOL eyes.^[14] Binocular contrast sensitivity was reported to be similar for the contralateral and bilateral IC-8 IOL groups at all spatial frequencies.^[14] Contrast sensitivity was maintained in the post-radial keratotomy patients implanted with the IC-8 IOL.^[29]

Grabner *et al.* found that the diffuse reduction in sensitivity found during visual field testing in patients implanted with the IC-8 IOL was clinically insignificant and no localized scotomas were produced by the IC-8 IOL.^[28] The IC-8 IOL did not hinder retinal examination, routine diagnostic test performance, and possible retinal treatment.^[28]

Explantation and Complications

The few complications were mostly unrelated to the IC-8 IOL itself and had no permanent sequelae after management.^[14-16,28] In one study, the IC-8 IOL was explanted in 5.5% of cases as one patient had difficulty adjusting to the interocular difference, another had large floaters after posterior vitreous detachment, and the other five due to uncertainty with performing Nd:YAG (neodymium-doped yttrium aluminum garnet) capsulotomy for posterior capsular opacity (PCO).^[5]

PCO develops in all types of IOLs, including the IC-8. A modified capsulotomy technique was developed due to the presence of the small aperture mask. Nd:YAG capsulotomy was successfully performed using an omega pattern of firing around the IOL mask, leaving the posterior capsulotomy connected at the bottom to allow the capsule to float down or tilt backward.^[16] Another variation is completely disconnecting the PCO 360° then

firing extra shots through the small aperture to dislodge the capsule that may remain attached to the optic.

Current Status of the IC-8 Small Aperture Intraocular Lens

The IC-8 is undergoing USFDA review for possible approval in the United States. It has received the Conformité Européenne (CE) mark and is commercially available in many other countries. While it is primarily positioned as a presbyopia-correcting IOL with an EDOF mechanism of action, its widespread appeal is strengthened by its ability to reduce unwanted corneal aberrations from complex corneas due to previous corneal refractive surgery or other corneal irregularities.

Small Aperture Piggyback Device

Patient selection

Pseudophakic patients with irregular astigmatism causing significant visual impairment from keratoconus, radial keratotomy or penetrating keratoplasty, traumatic corneal laceration, post-LASIK ectasia, and eccentric excimer laser ablation can be considered for XtraFocus device implantation.^[8] Near vision enhancement in pseudophakes with monofocal IOLs and dysphotopsia reduction in eyes with multifocal IOLs may be secondary indications.^[32] The XtraFocus device is black making it beneficial for patients with large iris defects [Figure 2e and f]. Patients with good fitting rigid gas-permeable contact lens who tolerated them well were excluded from implantation.^[33] Other exclusion criteria were vitreoretinal pathology that may need future treatment, history of uveitis or iritis, uncontrolled diabetes or glaucoma, and lack of central corneal transparency.^[8]

Efficacy, Satisfaction, and Visual Symptoms

Trindade *et al.* reported that their pseudophakic patients with irregular corneal astigmatism had subjective improvement in performing visual tasks for all distances with the median overall satisfaction of 8/10 after XtraFocus device implantation.^[8] While the median score for undesirable optical phenomena improved, dark vision inside a very dark room was reported in 4.2% of their patients and a faint halo in 8.3%. There was no spontaneous report of movement distortion of a laterally swinging pendulum. However when asked if they noticed an elliptical movement, 8.3% said yes.

The statistically significant improvements after XtraFocus device implantation for UDVA and CDVA from baseline values were sustained up to 4 years of follow-up.^[6] In the study by Ho *et al.*, all their patients had poor vision

or glare preoperatively due to a standalone iris defect or coexisting irregular astigmatism and iris defect.^[32] After XtraFocus implantation, 90.9% had better UDVA and 72.7% reported satisfaction with the improved vision or lessened glare.^[32] The refractive and visual acuity outcomes of the XtraFocus IOL publications are summarized in Table 6.

Explantation and Complications

In the bilateral XtraFocus device study, darkening vision complaints were reported in 18.8% after implantation in the first eye causing exclusion from XtraFocus device placement in the fellow eye.^[33] In another study, the patient who had XtraFocus explantation had complete resolution of the persistent glare and halos after device removal.^[32] Dilated infrared photography showed no interlenticular opacification for up to 4 years postoperatively.^[6] The authors noted that this was possibly due to the posterior concave shape of the IOL that reduced contact with the other IOL inside the bag while its central hole allowed exit of lens cells through aqueous movement.^[6] Nd:YAG laser posterior capsulotomy was done with no difficulty using a Peyman contact lens to improve focus and if needed, the capsulotomy could be sized larger than the pinhole by modifying the patient gaze.^[6,33]

Current Status of the XtraFocus Device

The XtraFocus received the CE mark in 2016 and is commercially available in several countries. In patients with clear central corneas, the Xtrafocus can neutralize high amounts of corneal aberration or extend the depth of field for presbyopia correction. Patients with significant dysphotopsia from multifocal IOLs or severe glare and light sensitivity from irregular or large pupils may also benefit from the Xtrafocus device.

Discussion

A decrease in aperture diameter causes an increase in the depth of field or the distance in front of and behind the object of regard that appears in focus. However, if the decrease in the aperture size is too much, the visual acuity suffers due to increased diffraction and decreased light transmission.^[34] The balance between these was found through computer modeling and was applied in the creation of small aperture optics devices.^[34] Surgical devices that utilize small aperture optics have proven their usefulness as extended depth of focus tools. The implanted eye can see well at all distances as the blur circle is reduced, the conoid of Sturm narrowed, and the effect of ocular aberrations minimized.^[1,8,17]

In comparison to classic monovision wherein one eye is made myopic and loses distance vision, eyes implanted

Table 6: Published outcomes of XtraFocus piggyback device

Study ^a	Study Type	n	Mean age (years)	F/U (months)	Preoperative to postoperative				
					SE (diopters)	UDVA	UNVA	CDVA	CNVA
Trindade <i>et al.</i> , 2017 ^[8]	Prospective case series	24 ^b	61	22	-0.82→-0.57	20/200→20/50	J7→J2	20/60→20/40	J3→J2
Trindade <i>et al.</i> , 2020 ^[6]	Retrospective consecutive case series	60 ^c	52	16	-7.29→-0.67	20/400→20/30	J16→J2	20/70→20/25	NA
Trindade <i>et al.</i> , 2021 ^[33]	Retrospective consecutive case series	32 ^d	47	27	NA	20/250→20/40	J5→J3	20/63→20/32	NA
					NA ^e	20/250 ^e →20/40 ^e	J5→J3 ^e	20/60→20/25 ^e	NA ^e
Ho <i>et al.</i> , 2021 ^[32]	Retrospective consecutive case series	11 ^f	54	12	0.375→4.3	20/100→20/32	NA	20/50→20/32	NA

^aFirst author and year study was published, ^bXtraFocus device implanted in the ciliary sulcus of pseudophakic patients with monofocal IOL, ^cXtraFocus device implanted in the capsular bag at the time of cataract surgery together with a primary IOL, ^dBilateral XtraFocus device implanted in the ciliary sulcus of pseudophakic patients or in the ciliary sulcus or capsular bag of phakic patients right after the cataract surgery or refractive lens exchange, ^eBinocular values, ^fXtraFocus device implanted in the ciliary sulcus of pseudophakes with standalone iris defect or iris defect with coexisting corneal irregular astigmatism, [†]All studies include patients with irregular corneal astigmatism, and all values were from the 1 year postoperative follow-up.^[6,8,32,33] CDVA=Corrected distance visual acuity, CNVA=Corrected near visual acuity, F/U=Follow-up, J=Jaeger, n=Number of eyes, NA=Not available, SE=Spherical equivalent, UDVA=Uncorrected distance visual acuity, UNVA=Uncorrected near visual acuity

with a small aperture device gain intermediate and near vision and can still be used for distance vision.^[14] Compared to monovision mean results, the UDVA results were better in both the Kamra corneal inlay and the IC-8 IOL.^[10,24,29,35] Some stereoacuity is lost with traditional monovision because of the anisometropia but stereoacuity is maintained with the -0.75 D mini-monovision used with small aperture devices.^[10,29,35] Small aperture devices are more forgiving in terms of refractive targeting because of their increased depth of focus. Furthermore, the Kamra corneal inlay, IC-8 IOL, and XtraFocus device have been used in combination with other procedures or as a rescue procedure.

The Kamra corneal inlay was reported to be safe and effective for presbyopia correction in different study populations.^[1-4,11,17-25] The near visual acuity of the corneal inlay eyes held up well even up to 5 years postoperatively despite the expected gradual loss of accommodation over time.^[18,24] Inlay modifications and surgical technique refinement improved the Kamra corneal inlay results. However, widespread adoption did not materialize due to biocompatibility concerns and difficulty with placement. Lessons learned from the Kamra corneal inlay experience resulted in moving the benefits of small aperture optics from the cornea towards the lens space.

The IC-8 IOL was found to be effective, safe, and received good patient satisfaction feedback in terms of presbyopia correction and spectacle independence when implanted monocularly or binocularly.^[5,12-16,28,29] Even if the IC-8 IOL has no cylinder correction in its design, patients with up to 1.5 D of corneal astigmatism can benefit whether in virgin corneas or post-refractive surgery patients who may be at risk for postoperative refractive surprises.^[16] Hooshmand *et al.* found that patients with ocular comorbidities such as age-related macular degeneration, epiretinal membrane, and marked corneal HOAs were satisfied with their significant gain

in extended depth of focus after IC-8 IOL implantation.^[5] Patients deemed unsuitable for multifocal IOLs may benefit from the IC-8 small aperture IOL.^[5]

EDOF IOLs such as the IC-8 IOL are meant to bridge the gap between monofocal IOLs and multifocal IOLs.^[36] EDOF IOLs provide better intermediate visual acuity than monofocal IOLs, which can provide a full range of vision with monovision but may come up short for intermediate distance vision and depth perception.^[36] Compared to multifocal IOLs, EDOF IOLs are designed to have better contrast sensitivity and less severe visual disturbances such as glare and halos.^[37] Placing an IC-8 IOL in the second eye of patients with monofocal IOL in the first eye may facilitate easier adaptation than having to adjust to image quality interocular difference with a multifocal IOL.^[14]

In the contralateral versus bilateral IC-8 IOL implantation study by Ang, if the patient did not achieve the desired near or intermediate vision with the first IC-8 IOL eye that was targeted for myopia, the second IC-8 IOL eye was targeted for more myopia instead of the previously planned emmetropia.^[16] This study showed that optimization of refractive targets resulted in excellent visual acuities with the IC-8 IOL across all distances and high patient satisfaction. Ocular surface disorders must be treated well preoperatively and postoperatively to maximize the IC-8 IOL.^[14] Patients must be counseled that some may experience postoperative dysphotopsias which often resolve eventually but might persist in a few cases.^[5] The full benefits from the IC-8 IOL are often experienced after neuroadaptation.^[5]

Rigid contact lenses are the main treatment for irregular corneal astigmatism but some are unable to get an adequate fitting or cannot tolerate them.^[6] There are others who do not qualify for laser refractive surgery or intracorneal ring segments due to inadequate corneal thickness or ocular surface health.^[32] All these patients

can benefit from the piggyback XtraFocus device, found to be safe and effective in improving the vision of those with irregular corneal astigmatism or iris defects be it implanted monocularly or binocularly in the ciliary sulcus or capsular bag.^[6,8,32,33] Patients with irregular corneal astigmatism caused by keratoconus or refractive procedures such as radial keratotomy or penetrating keratoplasty can now have a treatment option other than corneal transplant.^[6]

Patients implanted with the XtraFocus device hardly noticed the Pulfrich effect or the distortion of perceived object motion due to differences in interocular retinal luminance such as when a pendulum moving laterally appears to be moving in an elliptical pattern.^[8] The authors surmised that the retinal luminance difference between the eye implanted with the XtraFocus and the fellow eye may not have been significant enough for the patients to notice the optical phenomenon and that their poorer optical quality from the high corneal aberrations may have played a part. The brightness seen by the patients was also not reduced to the amount expected with the XtraFocus device partly due to the Stiles-Crawford effect, which implies that smaller pupils can achieve per unit light of energy a higher degree of visual response compared to larger pupils.^[8]

Before implanting the XtraFocus device, patients should be informed of the possibility of dimmed vision postoperatively.^[33] This may require explantation if persistent and may limit the use of the bilateral XtraFocus device.^[33] The XtraFocus has to be removed also for patients who need laser or surgery on the retina.^[6] Complete retinal check is mandatory with indirect ophthalmoscopy and scleral depression preoperatively to ensure no retinal pathology exists that may require treatment.^[8]

Conclusion

Small aperture surgical devices accomplished reasonable levels of efficacy, safety, spectacle independence, and satisfaction. The long-term biocompatibility of the Kamra corneal inlay has limited its clinical use. The IC-8 IOL is a promising technology for presbyopia correction during cataract surgery. The EDOF capability provides excellent outcomes for monocular or binocular implantation, the latter further improving near and intermediate vision. Aside from presbyopia, the IC-8 IOL offers an alternative solution for eyes with corneal astigmatism up to 1.50 D and eyes with complex corneas who have had previous corneal refractive surgery or have corneal irregularities. The XtraFocus piggyback device is the ideal rescue solution for pseudophakic eyes suffering from debilitating best-corrected vision arising from iris defects or corneal irregular astigmatism

due to keratoconus, ectasia, trauma, or prior corneal transplant.

Financial support and sponsorship

Nil.

Conflicts of interest

Dr. Ang was a principal investigator for clinical studies conducted on the Kamra corneal inlay and IC-8 intraocular lens. Dr. Ang and the co-authors have no financial interest related to this submitted work.

References

1. Vukich JA, Durrie DS, Pepose JS, Thompson V, van de Pol C, Lin L. Evaluation of the small-aperture intracorneal inlay: Three-year results from the cohort of the U.S. Food and Drug Administration clinical trial. *J Cataract Refract Surg* 2018;44:541-56.
2. Tomita M, Kanamori T, Waring GO 4th, Yukawa S, Yamamoto T, Sekiya K, *et al.* Simultaneous corneal inlay implantation and laser *in situ* keratomileusis for presbyopia in patients with hyperopia, myopia, or emmetropia: Six-month results. *J Cataract Refract Surg* 2012;38:495-506.
3. Igras E, O'Caomh R, O'Brien P, Power W. Long-term results of combined LASIK and monocular small-aperture corneal inlay implantation. *J Refract Surg* 2016;32:379-84.
4. Huseynova T, Kanamori T, Waring GO 4th, Tomita M. Outcomes of small aperture corneal inlay implantation in patients with pseudophakia. *J Refract Surg* 2014;30:110-6.
5. Hooshmand J, Allen P, Huynh T, Chan C, Singh R, Moshegov C, *et al.* Small aperture IC-8 intraocular lens in cataract patients: Achieving extended depth of focus through small aperture optics. *Eye (Lond)* 2019;33:1096-103.
6. Trindade BL, Trindade FC, Werner L, Trindade CL. Long-term safety of in-the-bag implantation of a supplementary intraocular pinhole. *J Cataract Refract Surg* 2020;46:888-92.
7. Dextl AK, Ruckhofer J, Riha W, Hohensinn M, Rueckl T, Messmer EM, *et al.* Central and peripheral corneal iron deposits after implantation of a small-aperture corneal inlay for correction of presbyopia. *J Refract Surg* 2011;27:876-80.
8. Trindade CC, Trindade BC, Trindade FC, Werner L, Osher R, Santhiago MR. New pinhole sulcus implant for the correction of irregular corneal astigmatism. *J Cataract Refract Surg* 2017;43:1297-306.
9. Dextl AK, Seyeddain O, Grabner G. Follow-up to "central and peripheral corneal iron deposits after implantation of a small-aperture corneal inlay for correction of presbyopia". *J Refract Surg* 2011;27:856-7.
10. Dextl AK, Seyeddain O, Riha W, Hohensinn M, Rückl T, Reischl V, *et al.* One-year visual outcomes and patient satisfaction after surgical correction of presbyopia with an intracorneal inlay of a new design. *J Cataract Refract Surg* 2012;38:262-9.
11. Moshirfar M, Quist TS, Skanchy DF, Wallace RT, Linn SH, Hoopes PC Jr. Six-month visual outcomes for the correction of presbyopia using a small-aperture corneal inlay: Single-site experience. *Clin Ophthalmol* 2016;10:2191-8.
12. Schojai M, Schultz T, Jerke C, Böcker J, Dick HB. Visual performance comparison of 2 extended depth-of-focus intraocular lenses. *J Cataract Refract Surg* 2020;46:388-93.
13. Shajari M, Mackert MJ, Langer J, Kreutzer T, Wolf A, Kohnen T, *et al.* Safety and efficacy of a small-aperture capsular bag-fixated intraocular lens in eyes with severe corneal irregularities. *J Cataract Refract Surg* 2020;46:188-92.
14. Dick HB, Piovella M, Vukich J, Vilupuru S, Lin L, Clinical

- Investigators. Prospective multicenter trial of a small-aperture intraocular lens in cataract surgery. *J Cataract Refract Surg* 2017;43:956-68.
15. Dick HB, Elling M, Schultz T. Binocular and monocular implantation of small-aperture intraocular lenses in cataract surgery. *J Refract Surg* 2018;34:629-31.
 16. Ang RE. Visual performance of a small-aperture intraocular lens: First comparison of results after contralateral and bilateral implantation. *J Refract Surg* 2020;36:12-9.
 17. Yilmaz OF, Alagöz N, Pekel G, Azman E, Aksoy EF, Cakır H, *et al*. Intracorneal inlay to correct presbyopia: Long-term results. *J Cataract Refract Surg* 2011;37:1275-81.
 18. Dextl AK, Jell G, Strohmaier C, Seyeddain O, Riha W, Rückl T, *et al*. Long-term outcomes after monocular corneal inlay implantation for the surgical compensation of presbyopia. *J Cataract Refract Surg* 2015;41:566-75.
 19. Seyeddain O, Bachernegg A, Riha W, Rückl T, Reitsamer H, Grabner G, *et al*. Femtosecond laser-assisted small-aperture corneal inlay implantation for corneal compensation of presbyopia: Two-year follow-up. *J Cataract Refract Surg* 2013;39:234-41.
 20. Tomita M, Kanamori T, Waring GO 4th, Nakamura T, Yukawa S. Small-aperture corneal inlay implantation to treat presbyopia after laser *in situ* keratomileusis. *J Cataract Refract Surg* 2013;39:898-905.
 21. Tomita M, Waring GO 4th. One-year results of simultaneous laser *in situ* keratomileusis and small-aperture corneal inlay implantation for hyperopic presbyopia: Comparison by age. *J Cataract Refract Surg* 2015;41:152-61.
 22. Jalali S, Aus der Au W, Shaarawy T. AcuFocus corneal inlay to correct presbyopia using femto-LASIK. One year results of a prospective cohort study. *Klin Monbl Augenheilkd* 2016;233:360-4.
 23. Moshirfar M, Bean AE, Albarracin JC, Rebenitsch RL, Wallace RT, Birdsong OC. Retrospective comparison of visual outcomes after KAMRA corneal inlay implantation with simultaneous PRK or LASIK. *J Refract Surg* 2018;34:310-5.
 24. Abdul Fattah M, Mehanna CJ, Antonios R, Abiad B, Jabbur NS, Awwad ST. Five-year results of combined small-aperture corneal inlay implantation and LASIK for the treatment of hyperopic presbyopic eyes. *J Refract Surg* 2020;36:498-505.
 25. Elling M, Schojai M, Schultz T, Hauschild S, Dick HB. Implantation of a corneal inlay in pseudophakic eyes: A prospective comparative clinical trial. *J Refract Surg* 2018;34:746-50.
 26. Seyeddain O, Hohensinn M, Riha W, Nix G, Rückl T, Grabner G, *et al*. Small-aperture corneal inlay for the correction of presbyopia: 3-year follow-up. *J Cataract Refract Surg* 2012;38:35-45.
 27. Waring GO 4th. Correction of presbyopia with a small aperture corneal inlay. *J Refract Surg* 2011;27:842-5.
 28. Grabner G, Ang RE, Vilupuru S. The small-aperture IC-8 intraocular lens: A new concept for added depth of focus in cataract patients. *Am J Ophthalmol* 2015;160:1176-84.e1.
 29. Agarwal S, Thornell E. Spectacle independence in patients with prior radial keratotomies following cataract surgery: A case series. *Int Med Case Rep J* 2020;13:53-60.
 30. Ang RE. Comparison of tolerance to induced astigmatism in pseudophakic eyes implanted with small aperture, trifocal, or monofocal intraocular lenses. *Clin Ophthalmol* 2019;13:905-11.
 31. Ang RE, Picache GC, Rivera MC, Lopez LR, Cruz E. A comparative evaluation of visual, refractive, and patient-reported outcomes of three extended depth of focus (EDOF) intraocular lenses. *Clin Ophthalmol* 2020;14:2339-51.
 32. Ho VW, Elalfy M, Hamada S, Lake D. One-year visual outcome of secondary piggyback pinhole device implantation in pseudophakic eyes with irregular corneal astigmatism and iris trauma. *Eye (Lond)* 2021;35:1-6.
 33. Trindade BL, Trindade FC, Trindade CL. Bilateral implantation of a supplementary intraocular pinhole. *J Cataract Refract Surg* 2021;47:627-33.
 34. Yilmaz OF, Bayraktar S, Agca A, Yilmaz B, McDonald MB, van de Pol C. Intracorneal inlay for the surgical correction of presbyopia. *J Cataract Refract Surg* 2008;34:1921-7.
 35. Seyeddain O, Riha W, Hohensinn M, Nix G, Dextl AK, Grabner G. Refractive surgical correction of presbyopia with the AcuFocus small aperture corneal inlay: Two-year follow-up. *J Refract Surg* 2010;26:707-15.
 36. Kohnen T, Suryakumar R. Extended depth-of-focus technology in intraocular lenses. *J Cataract Refract Surg* 2020;46:298-304.
 37. Rocha KM. Extended depth of focus IOLs: The next chapter in refractive technology? *J Refract Surg* 2017;33:146-9.