


CASE REPORT

Early liver transplantation after COVID-19 infection: The first report

Anand V. Kulkarni¹  | Kumarswamy Parthasarathy² | Pramod Kumar¹ | Mithun Sharma¹ | Raghuram Reddy² | Krishna Chaitanya Akkaraju Venkata² | Rajesh Gupta¹ | Anand Gupta³ | Shakti Swaroop³ | Premkumar Giri Vishwanathan³ | Gayathri Senapathy⁴ | Palat B. Menon² | Nageshwar D. Reddy¹ | Nagaraja R. Padaki¹

¹Department of Hepatology, Asian Institute of Gastroenterology, Hyderabad, India

²Department of Liver Transplantation and Hepatobiliary Surgery, Asian Institute of Gastroenterology, Hyderabad, India

³Department of Anaesthesia, Asian Institute of Gastroenterology, Hyderabad, India

⁴Department of Radiology, Asian Institute of Gastroenterology, Hyderabad, India

Correspondence

Anand V. Kulkarni, Department of Hepatology, Asian Institute of Gastroenterology, Hyderabad, India. Email: anandvk90@gmail.com

COVID-19 (coronavirus disease 2019) has impacted solid organ transplantation (SOT) in many ways. Transplant centers have initiated SOT despite the COVID-19 pandemic. Although it is suggested to wait for 4 weeks after COVID-19 infection, there are no data to support or refute the timing of liver transplant after COVID-19 infection. Here we describe the course and outcomes of COVID-19-infected candidates and healthy living liver donors who underwent transplantation. A total of 38 candidates and 33 potential living donors were evaluated from May 20, 2020 until October 30, 2020. Ten candidates and five donors were reverse transcriptase-polymerase chain reaction (RT-PCR) positive for severe acute respiratory syndrome coronavirus-2 (SARS-CoV-2) pretransplant. Four candidates succumbed preoperatively. Given the worsening of liver disease, four candidates underwent liver transplant after 2 weeks due to the worsening of liver disease and the other two candidates after 4 weeks. Only one recipient died due to sepsis posttransplant. Three donors underwent successful liver donation surgery after 4 weeks of COVID-19 infection without any postoperative complications, and the other two were delisted (as the candidates expired). This report is the first to demonstrate the feasibility of elective liver transplant early after COVID-19 infection.

KEYWORDS

clinical research/practice, infection and infectious agents, liver transplantation/hepatology, liver transplantation: living donor

1 | INTRODUCTION

The COVID-19 (coronavirus disease 2019) pandemic has impacted solid organ transplantation (SOT) in multiple ways. As the pandemic continues to evolve without any sign of respite, transplant centers have initiated SOT despite the pandemic. The timing of transplantation and organ procurement after SARS-CoV-2 (severe acute

respiratory syndrome coronavirus-2) infection is vital for the candidate's outcomes and donor's health. For patients with end-stage heart or lung disease who contract COVID-19 and recover while waitlisted, the International Society of Heart and Lung Transplantation recommends waiting at least 14 days after the initial diagnosis and two successive negative polymerase chain reaction (PCR)-based tests 48 h apart before transplantation. This timeframe is based on the higher

Abbreviations: ACLF, acute-on-chronic liver failure; ALF, acute liver failure; CO-RADS, COVID-19 Reporting and Data System; COVID-19, coronavirus disease 2019; CT, computed tomography; LDLT, living donor liver transplantation; MELD, Model for End-Stage Liver Disease; SARS-CoV-2, severe acute respiratory syndrome coronavirus-2.

© 2021 The American Society of Transplantation and the American Society of Transplant Surgeons

acuity of heart- and lung- waitlisted patients and lesser opportunities for organ availability.¹ The American Society of Transplantation (AST) recommends at least 28 days of symptom resolution prior to procuring an organ from a COVID-19-positive donor. However, they do not comment on the duration in the recipient.² Further, the AST guidance recommends at least one negative nucleic acid test (NAT) from the respiratory tract within 3 days prior to transplant.³ Although it is suggested to perform living donor liver transplantation (LDLT) in patients with a high Model for End-Stage Liver Disease score (MELD > 25) or patients with fulminant liver failure, the timing of surgery after COVID-19 infection in a recipient is not known.⁴ There are few reports of deceased donor liver transplants 2–70 days after COVID-19 infection.^{5–8} However, there is a paucity of data on managing COVID-19 patients who are awaiting LDLT and the timing of liver transplantation and organ procurement from a living donor. Here we describe the course and outcomes of COVID-19 candidates and healthy living liver donors who underwent LDLT at our center.

2 | METHODS

We performed a retrospective analysis of candidates and donors who underwent LDLT from May 20, 2020 until October 30, 2020. If the candidate or donor had symptoms suggestive of COVID-19 (fever, dyspnea, cough, or any gastrointestinal symptoms of recent onset) anytime while on the waitlist, they were directed to undergo computed tomography (CT) of the chest, SARS-CoV-2 RT-PCR (reverse transcriptase-polymerase chain reaction), and antibody testing. Each donor and candidate would undergo two RT-PCR tests 24 h apart, with CT screening of chest and antibody testing before elective surgery (even in the absence of symptoms). Patients and donors were scheduled for surgery if both the RT-PCR results were negative, CT was normal, and antibodies were negative, or only IgG was positive. If the candidate was RT-PCR positive and/or IgM antibody positive, the surgery was postponed for 14 days. If the donor was positive or both the candidate and donor were positive, and the candidate was stable, the surgery was postponed for 4 weeks. In

case the candidate was worsening (rise in MELD score), we would assess for the feasibility of surgery after 2 weeks with RT-PCR testing, symptom assessment, CT chest, and antibody testing (Figure 1).

For RT-PCR, two separate nylon flocked swabs were taken from the nasopharynx and oropharynx into viral transport medium vial. The extraction of RNA and amplification was done by the RT-PCR apparatus (Allplex 2019-nCoV Assay). SARS CoV-2 antibody assay (Abbott Laboratories) was done using a chemiluminescent microparticle immunoassay intended for the qualitative detection of IgM or IgG antibodies to SARS CoV-2. We considered the day of RT-PCR positive and/or IgM positive as the first day of infection irrespective of symptoms.

COVID-19 Reporting and Data System (CO-RADS) is a categorical assessment scheme for pulmonary involvement of COVID-19 based on CT. CO-RADS assesses the suspicion for pulmonary involvement of COVID-19 on a scale from 1 (very low) to 5 (very high).⁹ CO-RADS 4/5 is considered as COVID-19 positive even in the absence of a positive test.

3 | RESULTS

A total of 38 candidates and 33 potential living donors were evaluated during the study period. Of them, 10 candidates (Cases #1–10) and five donors were RT-PCR positive for SARS-CoV-2 pretransplant (Figure 2). Of the 10 candidates, four patients were symptomatic for COVID-19, and the rest were diagnosed incidentally prior to surgery (Table 1). Given the worsening of liver disease, four patients underwent transplant after 2 weeks (Cases #1–4), and the other two patients after 4 weeks (Cases #5 and 6). Six of the recipients who could undergo LDLT had mild to moderate severity of COVID-19. The other four candidates (Cases #6–10) had moderate to severe disease and succumbed pretransplant. The mean MELD score at transplant listing was 21 ± 3 , and MELD on the day of surgery was 25 ± 5 ($p = .009$) among six patients who underwent transplant. Biochemical variables and inflammatory markers of the candidates at the time of surgery are detailed in Table 2.

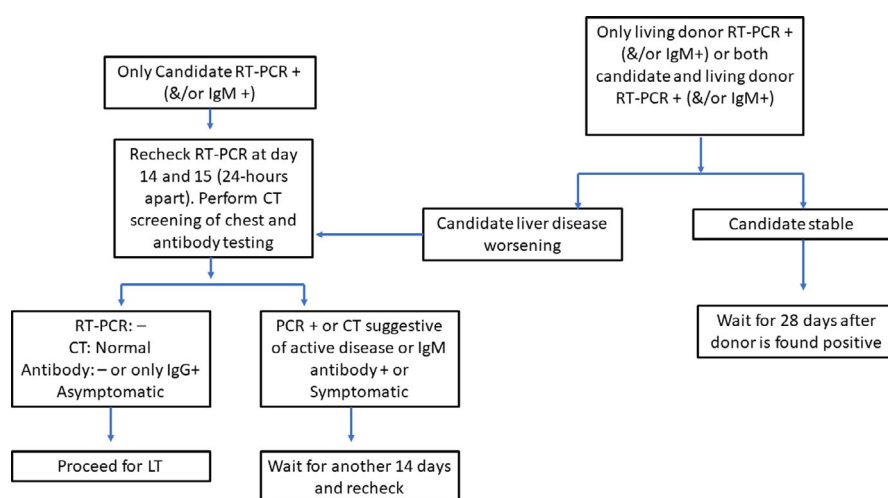
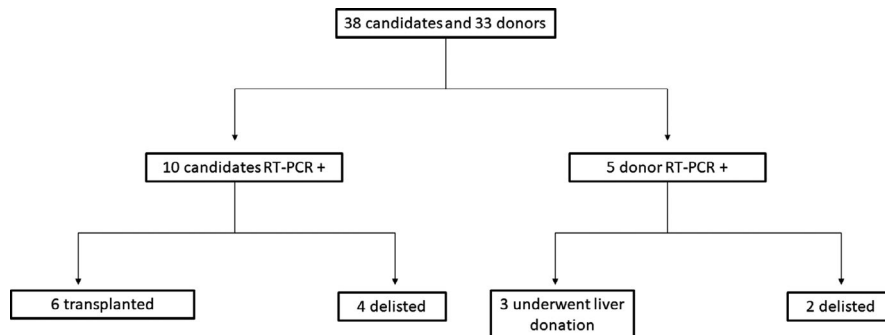


FIGURE 1 Protocol for liver transplant after a SARS-CoV-2 infection. CT, computed tomography; LT, liver transplantation; RT-PCR, reverse transcriptase-polymerase chain reaction; SARS-CoV-2, severe acute respiratory syndrome coronavirus-2 [Color figure can be viewed at [wileyonlinelibrary.com](https://onlinelibrary.com)]

FIGURE 2 Flowchart depicting the candidates and donors screened/transplanted during the study period



Only one of the five donors was symptomatic with cough, and the rest were incidentally detected preoperatively. All the donors had mild disease and were managed conservatively for COVID-19. Three donors underwent successful surgery without any postoperative complications (the other two recipients were delisted). We performed antibody testing in Cases #1–6 (recipient candidates) and three potential donors prior to surgery. Two candidates (#1 and #2) were negative for antibodies (both IgM and IgG) at the time of surgery, and the rest of the individuals who underwent surgery (candidates #3–6 and three donors) were IgG positive.

3.1 | Timeline of COVID-19 in candidates who underwent liver transplant

The mother (donor) of candidate #1 presented with complaints of sore throat and cough for 4 days (8 days prior to surgery). Her RT-PCR was positive. She was isolated and managed conservatively. After 12 days, the candidate (#1) presented with dyspnea on exertion and tense ascites, which was initially thought to be due to COVID-19. His SpO₂ was 97%, and his CT chest was suggestive of no active disease (CO-RADS-1). He had worsening of ascites, rise in bilirubin, and was also found to be RT-PCR positive. Ascitic tapping relieved his dyspnea. He recovered with symptomatic treatment within 48 h. Given the worsening of liver disease (MELD: increased to 29 from 22), we performed LDLT after 17 days when he cleared his virus (2 × RT-PCR negative), and the CT scan was normal.

Candidates #2 and #3 were incidentally detected to be COVID-19 positive prior to elective surgery and later underwent surgery on days 15 and 16, respectively, due to worsening liver disease. Candidate #2 had a rise in MELD from 19 to 24. He was treated with remdesivir. Repeat RT-PCR after 14 days (two samples) was negative, and CT was suggestive of CO-RADS-2 at the time of surgery. Candidate #3 developed hepatic encephalopathy (serum potassium was 3.4 meq/dl) with an increase in MELD score by 3 points. She was treated with remdesivir for 5 days. She also underwent one session of plasma exchange for rising bilirubin and was bridged to liver transplant after 16 days. Prior to surgery, she was SARS-CoV-2 IgG positive.

Candidate #4 was incidentally detected to be RT-PCR positive and IgM+ prior to planned elective surgery. Though he had mild COVID-19, he developed worsening of MELD score from 22 to 28

and underwent liver transplant at day 16 when he was RT-PCR negative and IgG positive.

Candidate #5 presented with complaints of cough and fever for 2 days prior to surgery and was found to be RT-PCR positive. His donor (elder sister) was simultaneously detected RT-PCR positive, although she was asymptomatic. The candidate recovered with symptomatic management. As the candidate was stable, we waited for 4 weeks before surgery. Candidate #6 and his donor (wife) were incidentally detected to be COVID-19 positive prior to surgery. Since the candidate was stable, we waited for 4 weeks. The course of four candidates (#6–10) who succumbed pretransplant is shown in Figure 3.

3.2 | Posttransplant management

Intraoperatively, all the six recipients received 10 mg/kg of methylprednisolone, and postoperatively, from day 1, we initiated 1 mg/kg of methylprednisolone and gradually tapered over 8 days to 30 mg oral prednisolone. Tacrolimus was initiated on day 1 after surgery to achieve a trough level of 8–10 ng/ml. Mycophenolate mofetil (MMF) was introduced on day 2 after surgery for all the six recipients at a dose of 0.5 g/day in two divided doses and escalated up to 2 g/day in two divided doses. Recipient #1 did not tolerate the higher dose of MMF (developed cytopenia on 2 g/day) and is on 1 g/day of MMF. Recipient #2 developed fever and biliary leak. SARS-CoV-2 RT-PCR was negative, and CT chest was normal. He succumbed to sepsis and graft dysfunction at day 24 posttransplant. Recipient #3 developed reactivation of herpes labialis on day 12, for which prednisolone dose was reduced to 10 mg/day, and aciclovir therapy was initiated. Recipient #4 developed tacrolimus toxicity and is being managed with steroids and MMF. Recipient #5 developed acute cellular rejection on day 42 and was pulsed with steroids after sepsis screening was negative. Postsurgery graft function stabilized in all patients except in candidates #1 and #4, who had a very gradual decline in bilirubin levels (Figure 4).

4 | DISCUSSION

In this case series, we report the feasibility of early liver transplant after COVID-19 infection in a selected group of patients. Although it is suggested to wait for 4 weeks after COVID-19 infection, there are

TABLE 1 Characteristics of COVID-19-positive candidates who underwent liver transplant

No.	Age (years)/ Gender	Etiology of liver disease	Severity of COVID-19 ^a	Specific treatment for COVID-19	MELD at enrollment- MELD at transplant	Time to transplant after COVID-19 PCR positive (days)	Posttransplant complications	Outcome (postsurgery)
1	18/M	ACLF-AIH	Mild	None	22-29a	17	None	Alive at day 60 after transplant
2	41/M	DC-Cryptogenic	Mild	Remdesivir	19-24	15	Biliary leak -sepsis- graft dysfunction	Death due to sepsis on day 24 after transplant
3	40/F	ACLF-AIH	Moderate	Remdesivir	26-29	16	None	Alive at day 91 after transplant
4	36/M	ACLF-Ethanol	Mild	None	22-28	16	None	Alive at day 67 after transplant
5	37/M	DC-Ethanol	Mild	None	23-27	32	None	Alive at day 68 after transplant
6	43/M	DC-NASH	Mild	None	16-16	30	None	Alive at day 56 after transplant

Abbreviations: ACLF, acute-on-chronic liver failure; AIH, autoimmune hepatitis; COVID-19, coronavirus disease 2019; DC, decompensated cirrhosis; MELD, Model for End-Stage Liver Disease.

^aSeverity of COVID-19 was graded as per Indian Council for Medical Research (ICMR) guidelines version 3, dated June 13, 2020.

TABLE 2 Biochemical variables of the candidate's pretransplant

No.	Hemoglobin (13-17 g/dl)	Total leucocyte counts (4000-10 000 cell/ mm ³)	Platelets (1.5- 4.1 lakhs/ mm ³)	Serum creatinine (0.7-1.4 mg/dl)	INR	Total bilirubin/ direct bilirubin (mg/ dl)	Serum albumin (g/ dl)	D-dimer (<232 ng/ ml)	C-reactive protein (<0.6 mg/dl)	Ferritin (30-400 ng/ml)	IL-6 (<7 pg/ ml)
1	9.6	5600	1.2	1.21	2.77	13.0/6.7	2.9	6363	2.3	864.7	86.2
2	9.1	7500	0.75	0.82	2.63	10.2/5.3	2.8	5950	4.6	764.5	134
3	7.4	8200	1.4	0.75	2.34	19.1/8.7	3.1	3340	1.2	45.4	26.5
4	7.7	3800	1.2	0.76	2.10	22.1/8.1	3.6	3866	7.5	440	60.1
5	8.5	2400	1.0	1.2	2.3	8.5/4.1	3.0	4030	<0.6	906	25.1
6	10.5	1900	0.30	1.1	1.61	3.4/1.0	3.2	-	-	314	-

FIGURE 3 Timeline of COVID-19 in candidates who succumbed pretransplant. Candidates 7 and 8 succumbed to liver disease, and candidates 9 and 10 succumbed to COVID-19. ACLF, acute on chronic liver failure; ALF, acute liver failure; COVID-19, coronavirus disease 2019; CRRT, continuous renal replacement therapy; HAV, hepatitis A virus; MELD, Model for End-Stage Liver Disease; RT-PCR, reverse transcriptase-polymerase chain reaction [Color figure can be viewed at wileyonlinelibrary.com]

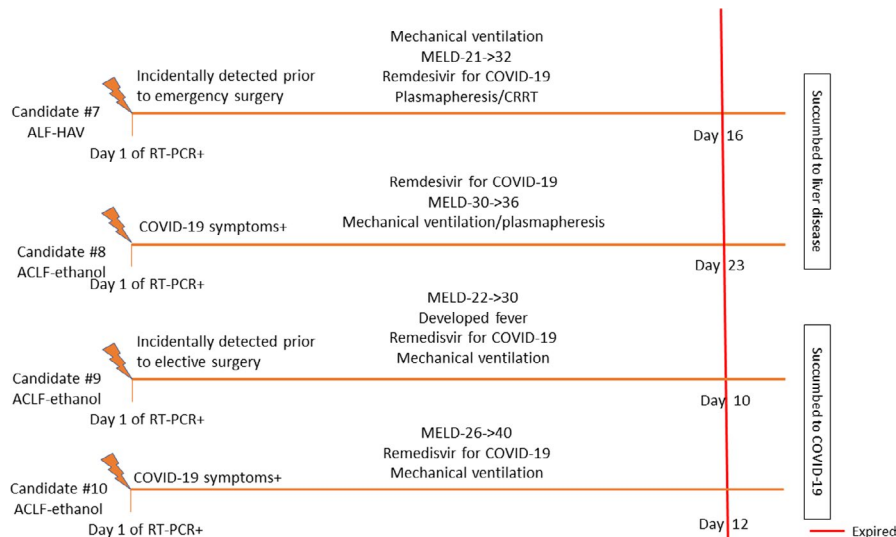
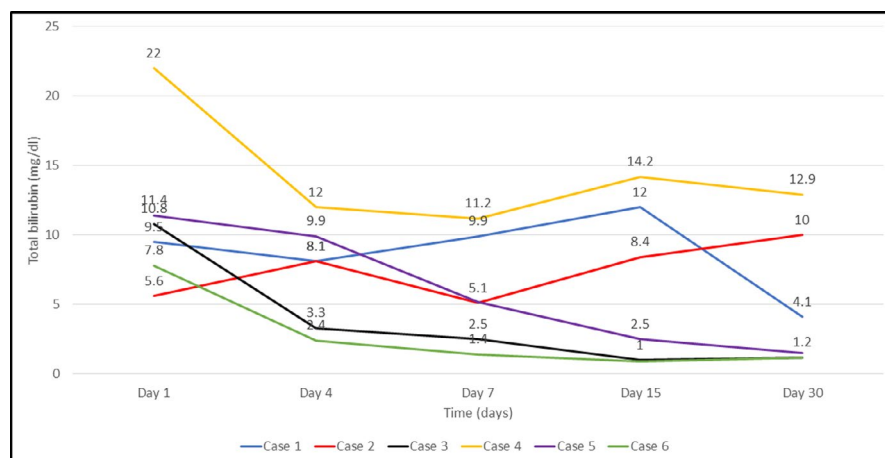


FIGURE 4 Change in serum total bilirubin after liver transplant in recipients (#1-6) from postoperative day 1 to day 30



no data to support or refute liver transplant timing after COVID-19 infection.¹⁰ Further, it is difficult to postpone the surgery for 4 weeks in LDLT due to organ availability and the ethical concern of transplanting those who might succumb if not transplanted soon enough. COVID-19 can induce the worsening of liver disease even in the absence of respiratory symptoms.¹¹ We performed LDLT after 2 weeks for four candidates due to deterioration of liver disease and a rise in MELD score. The other two were transplanted after 4 weeks as the donor was also positive, and the candidates were stable. Patients with mild COVID-19 can safely undergo liver transplant without any added complications after 14 days, provided the patient is asymptomatic, RT-PCR is negative twice 24 h apart with a normal chest CT with or without IgG antibodies. The viral load in COVID-19 peaks during the first week of illness and then gradually declines over the second week.^{12,13} Furthermore, both IgG and IgM antibodies start to increase around day 10 after symptom onset.¹² In our series, the candidates cleared the virus within 15 days though the antibodies were not present in all cases. While we required patients to have both a negative RT-PCR and a waiting period of 14–28 days after COVID-19 infection prior to transplant, it is unknown if both or one of these was the reason for successful outcomes.

Liver injury is well known in COVID-19 and is multifactorial.^{14,15} There are some concerns regarding the transmission of the virus from COVID-19-positive donor to the recipient.^{16–18} There is, however, no evidence currently to support the productive infection of the liver with SARS-CoV-2, and liver injury is probably a bystander phenomenon. Hence, the risk of SARS-CoV-2 transmission from asymptomatic or minimally symptomatic donors is likely very low.^{19,20}

Although we regularly screened the candidates and donors for COVID-19 symptoms (irrespective of the contact history), unfortunately, many of our patients and donors were asymptomatic and were diagnosed through routine pretransplant screening. The liberal way of performing two COVID-19 RT-PCR tests, CT thorax and antibody testing, may help identify infected individuals and improve the outcomes. But it is associated with a cost burden of approximately 150\$ in our setting.

The limitation of the study is the small sample size and retrospective analysis. Further prospective studies are required to compare the outcomes of non-COVID-19 candidates/donors vs. COVID-19 candidates/donors. It is also unknown if donors can also undergo surgery early after mild and asymptomatic COVID-19 infection.

However, this report is the first to demonstrate the feasibility and safety of liver transplant early after COVID-19 infection.

DISCLOSURE

The authors of this manuscript have no conflicts of interest to disclose as described by the *American Journal of Transplantation*.

AUTHOR CONTRIBUTIONS

DNR, PNR, and PBM conceptualized and designed the study. AVK, KP, and PK involved in compilation of data and initial drafting of the manuscript. AVK and MS designed the figures. PBM, AVK, RG, SS, DNR, GVP, and PNR involved in final editing of the draft and critical revision of the manuscript. All the authors approved the final draft.

DATA AVAILABILITY STATEMENT

Data available on request due to privacy/ethical restrictions.

ORCID

Anand V. Kulkarni  <https://orcid.org/0000-0002-1240-1675>

REFERENCES

- Aslam S, Danziger-Isakov L, Luong M. Guidance from the International Society of Heart and Lung Transplantation regarding the SARS CoV-2 pandemic. *ISHLT*. 2020. [Epub ahead of print].
- Ritschl PV, Nevermann N, Wiering L, et al. Solid organ transplantation programs facing lack of empiric evidence in the COVID-19 pandemic: a by-proxy Society Recommendation Consensus approach. *Am J Transplant*. 2020;20(7):1826-1836.
- SARS-CoV-2 (Coronavirus, 2019-nCoV): recommendations and guidance for organ donor testing. https://www.myastorg/sites/default/files/Donor%20Testing_100520_revised_ReadyToPostUpdated10-12pdf. 2020. Accessed November 12, 2020.
- Kumar D, Manuel O, Natori Y, et al. COVID-19: a global transplant perspective on successfully navigating a pandemic. *Am J Transplant*. 2020;20(7):1773-1779.
- Martini S, Patrono D, Pittaluga F, et al. Urgent liver transplantation soon after recovery from COVID-19 in a patient with decompensated liver cirrhosis. *Hepatol Commun*. 2020;5(1):144-145.
- Niess H, Börner N, Muenchhoff M, et al. Liver transplantation in a patient after COVID-19 – rapid loss of antibodies and prolonged viral RNA shedding. *Am J Transplant*. 2020. <https://doi.org/10.1111/ajt.16349>.
- Dhand A, Bodin R, Wolf DC, et al. Successful liver transplantation in a patient recovered from COVID-19. *Transpl Infect Dis*. 2020:e13492. <https://doi.org/10.1111/tid.13492>.
- Rouphael C, D'Amico G, Ricci K, et al. Successful orthotopic liver transplantation in a patient with a positive SARS-CoV2 test and acute liver failure secondary to acetaminophen overdose. *Am J Transplant*. 2020. <https://doi.org/10.1111/ajt.16330>. [Epub ahead of print].
- Prokop M, van Everdingen W, van Rees Vellinga T, et al. CO-RADS: a categorical CT assessment scheme for patients suspected of having COVID-19-definition and evaluation. *Radiology*. 2020;296(2):E97-E104.
- Di Maira T, Berenguer M. COVID-19 and liver transplantation. *Nat Rev Gastroenterol Hepatol*. 2020;17(9):526-528.
- Qiu HE, Wander P, Bernstein D, et al. Acute on chronic liver failure from novel severe acute respiratory syndrome coronavirus 2 (SARS-CoV-2). *Liver Int*. 2020;40(7):1590-1593.
- To K-W, Tsang O-Y, Leung W-S, et al. Temporal profiles of viral load in posterior oropharyngeal saliva samples and serum antibody responses during infection by SARS-CoV-2: an observational cohort study. *Lancet Infect Dis*. 2020;20(5):565-574.
- Bullard J, Dust K, Funk D, et al. Predicting infectious severe acute respiratory syndrome coronavirus 2 from diagnostic samples. *Clin Infect Dis*. 2020;71(10):2663-2666.
- Kulkarni AV, Kumar P, Tevethia HV, et al. Systematic review with meta-analysis: liver manifestations and outcomes in COVID-19. *Aliment Pharmacol Ther*. 2020;52(4):584-599.
- Kumar P, Sharma M, Kulkarni A, et al. Pathogenesis of liver injury in coronavirus disease 2019. *J Clin Exp Hepatol*. 2020;10(6):641-642.
- Lagana SM, De Michele S, Lee MJ, et al. COVID-19 associated hepatitis complicating recent living donor liver transplantation. *Arch Pathol Lab Med*. 2020;144(8):929-932.
- Shah MB, Lynch RJ, El-Haddad H, et al. Utilization of deceased donors during a pandemic: argument against using SARS-CoV-2-positive donors. *Am J Transplant*. 2020;20(7):1795-1799.
- Hong H-L, Kim S-H, Choi DL, et al. A case of coronavirus disease 2019-infected liver transplant donor. *Am J Transplant*. 2020;20(10):2938-2941.
- Kates OS, Fisher CE, Rakita RM, et al. Use of SARS-CoV-2-infected deceased organ donors: should we always "just say no?". *Am J Transplant*. 2020;20(7):1787-1794.
- Kates OS, Fisher CE, Rakita RM, et al. Emerging evidence to support not always "just saying no" to SARS-CoV-2 positive donors. *Am J Transplant*. 2020;20(11):3261-3262.

How to cite this article: Kulkarni AV, Parthasarathy K, Kumar P, et al. Early liver transplantation after COVID-19 infection: The first report. *Am J Transplant*. 2021;21:2279–2284. <https://doi.org/10.1111/ajt.16509>