


# Solitary Fibrous Tumor of Hard Palate: A Case Report and Literature Review

Journal of Investigative Medicine High  
Impact Case Reports  
Volume 10: 1–4  
© 2022 American Federation for  
Medical Research  
DOI: 10.1177/23247096221142275  
journals.sagepub.com/home/hic  


Niloufar Pourfarrokhi, MD<sup>1</sup>, Yilun Wang<sup>2</sup>, Constance Cleaves, MD<sup>1</sup>,  
Riyam Zreik, MD<sup>1</sup>, and Bing Leng, MD, PhD<sup>1</sup>

## Abstract

Solitary fibrous tumor (SFT) is a mesenchymal tumor accounting for less than 2% of soft tissue tumors and has variable clinical behavior. It can arise in many anatomical locations of the body and in rare occasions in the oral cavity mostly in buccal mucosa and tongue. To date, a handful of such cases have been reported in the hard palate. We present a case of SFT in the hard palate of a 32-year-old man and describe the tissue morphology, immunohistochemistry workup, and follow-up together with literature review.

## Keywords

solitary fibrous tumor, SFTs, hard palate, palate, oral cavity

## Introduction

Solitary fibrous tumor (SFT) is a mesenchymal tumor with fibroblastic or myofibroblastic origin, accounting for less than 2% of soft tissue tumors. Although more than 50% of SFT occur intra-thoracically,<sup>1</sup> it has been diagnosed in other parts of the body such as liver, adrenal gland, skin, head, and neck, and in rare occasions, in the oral cavity,<sup>2,3</sup> affecting mostly buccal mucosa and tongue.<sup>2</sup> To the best of our knowledge, only 4 cases of SFT in hard palate have been documented in the literature. Here, we present an additional case of SFT of hard palate.

## Case Report

A 32-year-old man presented to the Oral and Maxillofacial Clinic of our institute in early 2021 with a painless right posterior hard palatal lesion adjacent to the last maxillary molar tooth which grew in size since 2017. The lesion was biopsied in 2020 and initially diagnosed as a benign fibrous tumor. Patient underwent maxillofacial CT scan with contrast prior to surgery in 2021 which showed approximately 2.0 cm enhancing mass projecting inferiorly from the right side of the hard palate. No adenopathy or osseous destruction was identified.

The excisional biopsy was performed. Gross pathologic examination revealed a 2.7 × 2.6 × 1.1 cm lesion with a homogeneous cut surface and an overlying tan-white smooth mucosa. Histologic examination demonstrated a well-circumscribed cellular lesion in the submucosa composed of

bland spindle cells with admixed staghorn vessels in a patternless pattern. There was no evidence of necrosis or mitotic activity (Figure 1).

Immunohistochemical staining was performed with spindle cells strongly positive for STAT6 and CD34 while being negative for AE1/AE3, S100, desmin, and smooth muscle actin (Figures 2 and 3). Based on the histological and immunohistochemical findings, a SFT was diagnosed. The patient recovered well from the surgery with no recurrence within 1 year post-surgery follow-up.

## Discussion

Solitary fibrous tumors are an uncommon group of neoplasm with an unknown origin. It has variable clinical behavior and was first described in pleura by Klemperer and Rabin in 1931.<sup>3,4</sup> This entity has been since identified in many anatomical locations of the body, including upper respiratory tract, breast, spinal cord,<sup>3</sup> liver, adrenal gland, skin, and head and neck.<sup>1,3</sup> Due to the overlapping histopathological features

<sup>1</sup>Baylor Scott & White Medical Center–Temple, TX, USA

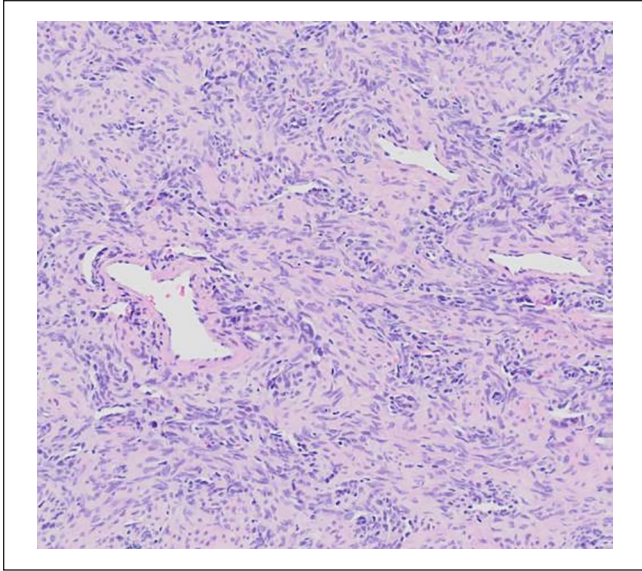
<sup>2</sup>Texas A&M University Health Science Center, College Station, USA

Received August 19, 2022. Revised November 1, 2022. Accepted November 12, 2022.

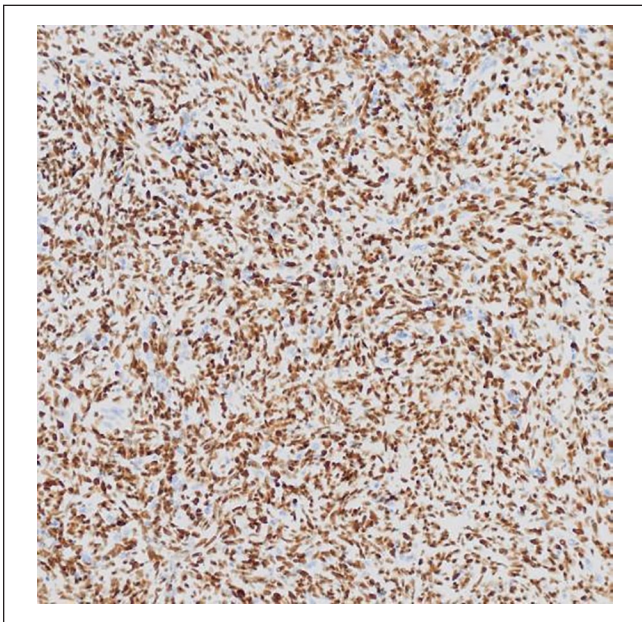### Corresponding Author:

Bing Leng, MD, PhD, Department of Pathology, Baylor Scott & White Medical Center–Temple, 2401 S. 31st Street, Temple, TX 76508, USA.  
Email: bing.leng@bswhealth.org





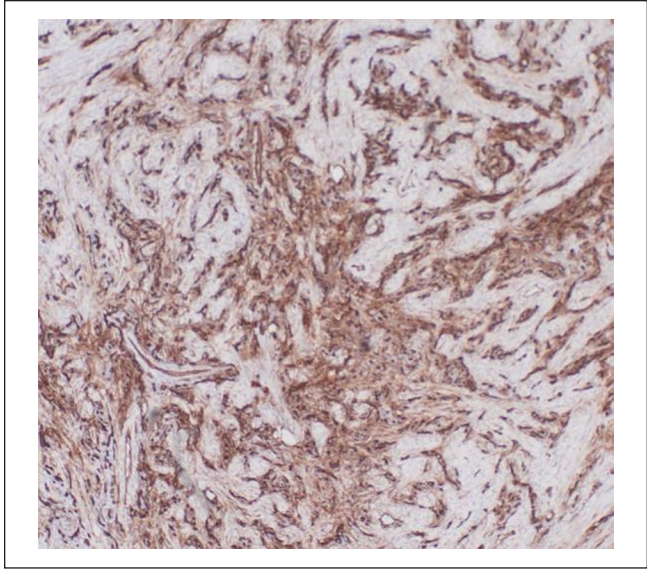
**Figure 1.** Histopathologic examination of excised lesion. Bland spindle cells with admixed staghorn vessels in a patternless pattern ( $\times 40$ ).



**Figure 2.** STAT6 immunohistochemical stain with strong nuclear positivity ( $\times 40$ ).

with many other soft tissue tumors, SFTs have been assigned many different names over the years such as benign mesothelioma, solitary fibrous mesothelioma, and localized fibrous tumor.<sup>5</sup>

Solitary fibrous tumors usually have no significant sexual predominance,<sup>5-7</sup> although some studies showed slight predilection to female adults.<sup>1,8</sup> They may arise at any age but most commonly occur during fifth to seventh decades of life.<sup>9</sup> To



**Figure 3.** CD34 immunohistochemical stain with strong positivity in vessels and spindle cells ( $\times 40$ ).

date, no known environmental elements have been found as predisposing risk factors to SFTs.<sup>5</sup> Generally, SFTs are well-circumscribed slow-growing masses<sup>10</sup> with majority of cases discovered as incidental radiologic findings or due to the symptoms associated with a mass effect.<sup>11</sup> Unusual symptoms including bleeding and tooth mobility were reported in the SFT of oral cavity.<sup>10</sup>

Solitary fibrous tumors in the head and neck are rare and have been reported in the nose and paranasal sinuses, nasopharynx, major salivary glands, larynx, thyroid, skin, oral cavity, and orbit.<sup>1</sup> According to the literature, although rare, oral cavity is the most common site of occurrence in the head and neck.<sup>1</sup> Approximately 150 cases have been reported until May 2019,<sup>12</sup> and the most common sites of involvement are buccal mucosa, tongue, and lower lip.<sup>1</sup> Incidence of SFT in the palate and specifically in the hard palate is extremely rare, and to the best of our knowledge, only 4 cases of hard palate SFTs have been reported in the literature.

In our case and 4 previously reported cases, patients were young with age ranging 26 to 35 years<sup>1,2,8,13</sup> and showed female predilection. The tumors in all 5 cases were located at right side of hard palate with sizes ranging 0.7 to 5.0 cm (Table 1). Histopathologic and immunohistochemical evaluations of the reported cases showed similar features to our case.

The histologic spectrum of SFTs is broad.<sup>14</sup> Classically, SFTs are variably cellular and consist of oval to fusiform spindle cells with minimal nuclear atypia and mitotic figures that are arranged haphazardly or in short, ill-defined fascicles. There is dilated, branching, staghorn-like (hemangiopericytoma-like) vasculature. The tumor may show alternating hypercellular foci and hypocellular sclerotic foci.<sup>14</sup>

**Table 1.** Four Reported SFTs of Hard Palate and Our Case.

Patient age	Sex	Location of tumor on hard palate	Tumor greatest dimension (cm)	Treatment/recurrence
35 <sup>1</sup>	Female	Right side	5.0	Surgical excision/no recurrence
26 <sup>2</sup>	Female	Right side extending to midline	3.0	Surgical excision/no data available
35 <sup>8</sup>	Female	Right posterior	0.7	Surgical excision/ no recurrence
28 <sup>13</sup>	Male	Right side	2.0	Surgical excision/no data available
32 <sup>our case</sup>	Male	Right posterior	2.7	Surgical excision/no recurrence

Immunohistochemical staining plays an important role in diagnosing SFTs. Solitary fibrous tumors are immunoreactive to CD34 and STAT6, and variably positive to CD99 while being negative for muscular, epithelial, and neural markers. It is important to note that CD34 lacks specificity for diagnosis of this entity. Strong nuclear STAT6 staining has been used to reliably differentiate SFT from other soft tissue tumors. Presence of positive staining for CD34 and STAT6 with negative staining for S100, AE1/AE3, smooth muscle actin, and desmin, along with histological features, supports the diagnosis of SFT within the hard palate for our case.

As in our case, complete surgical excision is the treatment of choice. Radiotherapy is suggested as a standard adjuvant therapy for tumors that are difficult to complete resection due to the complexity of anatomical site (ie, head and neck).<sup>1,10</sup> Completely excised tumors with no evidence of any malignant components show an excellent outcome.<sup>10</sup>

Local recurrence and distant metastasis are expected in malignant SFTs, which are extremely rare. In a retrospective study of 110 SFTs, clinicopathological factors associated with metastasis and survival were assessed, and a metastasis risk stratification model was developed. In this model, scores were assigned for age, tumor size, and mitotic figures; total scores were tabulated to determine the risk of aggressive disease (low, moderate, or high).<sup>15</sup> Based on the proposed model, our patient is classified as having a low risk of aggressive disease and metastasis.

In reported cases of SFTs of hard palate as well as our case, no recurrence was reported in up to 15 years follow-up.<sup>1,8</sup> The follow-up data are not available for 2 cases.<sup>2,13</sup> Studies believe that intraoral SFTs tend to follow a more benign non-recurring course.<sup>12</sup> However, certain cases of SFTs with benign histological features do recur. Therefore, long-term follow-up of all patients regardless of anatomical locations is highly recommended.<sup>11</sup>

Solitary fibrous tumors harbor a characteristic gene fusion between NAB2 and STAT6 which is a highly sensitive and specific molecular marker<sup>5</sup> and is a driver mutation for this entity.<sup>16</sup> This fusion is identified in all cases of SFTs<sup>17</sup> and results from inversion of long arm of chromosome 12 (12q13) and induces activation of early growth response (EGR) transcription factors, cellular proliferation, and tumorigenesis.<sup>17</sup> No definitive association with prognosis and malignant potentials has been identified with NAB2-STAT6 fusion variants,<sup>5,17,18</sup> although, in 1 study, fusion type NAB2 *exon 2*/STAT6 *exon 16/17* was

found to be associated with younger age of onset and malignant behavior.<sup>19</sup> In addition, studies showed that loss of NAB2-STAT6 chimeric protein expression was associated with SFT dedifferentiation, and hence negative STAT6 immunohistochemistry does not rule out SFT diagnosis.<sup>20</sup> Due to the small size of the 12q13 inversion, multiplex polymerase chain reaction (PCR) or next-generation sequencing is required for adequate sensitivity for detection of the NAB2-STAT6 fusion. Thus, proof of NAB2-STAT6 fusion is not required or recommended for diagnosis.<sup>21</sup> No genetic analysis was performed in our case. Other molecular alteration that is thought to be involved in the tumorigenesis of this entity includes platelet-derived growth factor receptor beta (PDGFRB) gene which was identified in cases of pleural SFT.<sup>22</sup> Mutations in telomerase reverse transcriptase (TERT) promoter have been also reported in 20% to 30% of SFTs in all sites and were found to be associated with more aggressive tumors and adverse clinical outcomes.<sup>5,22</sup> P53 mutation has been also observed in cases of dedifferentiated and aggressive types of SFT.<sup>22-25</sup>

Due to the broad histologic patterns, SFTs could be difficult to distinguish from other soft tissue tumors and should be considered in the differential diagnosis of well-demarcated submucosal solid mass located in oral cavity and hard palate such as hemangioma, angiofibroma, irritation fibroma, and giant cell fibroma.

## Conclusion

We presented a rare case of SFT in the hard palate. Review of our case and previously reported cases with SFT of hard palate showed occurrence in young patients, right-side predominance, and no recurrence on follow-up (between 2 months and 15 years period). Histopathological evaluation together with immunohistochemical analysis is necessary for the diagnosis of this entity. Due to its rarity and variable clinical behavior including recurrence and malignant transformation, periodic follow-up of patients diagnosed with SFTs is highly recommended.

## Declaration of Conflicting Interests

The author(s) declared no potential conflicts of interest with respect to the research, authorship, and/or publication of this article.

## Funding

The author(s) received no financial support for the research, authorship, and/or publication of this article.

## Ethics Approval

Not applicable, our institution does not require ethical approval for reporting individual cases or case series.

## Informed Consent

Informed consent for patient information to be published in this article was not obtained because this article does not contain any studies with human or animal subjects.

## Trial Registration

Not applicable, because this article does not contain any clinical trials.

## ORCID iDs

Niloufar Pourfarrokhi  <https://orcid.org/0000-0001-6221-2904>

Yilun Wang  <https://orcid.org/0000-0002-0441-4679>

## References

- Pinto ASB, De Araújo VC, Santos FP, et al. Solitary fibrous tumor of the hard palate: a rare entity in oral cavity. *BDS*. 2016;19:113-119.
- Lee JS, Tolomeo PG, Cappetta EJA, et al. Solitary fibrous tumor of the hard palate: a case report and review of the literature. *J Oral Maxillofac Surg*. 2016;74:e73.
- Vimi S, Punnya VA, Kaveri H, Rekha K. An aggressive solitary fibrous tumor with evidence of malignancy: a rare case report. *Head Neck Pathol*. 2008;2(3):236-241.
- de Moraes EF, Moreira DG, Oliveira VA, Rodrigues RR, Germano AR, Freitas RA. An unusual clinical presentation of solitary fibrous tumor in the oral cavity. *Case Rep Pathol*. 2017;2017:4395049.
- Davanzo B, Emerson RE, Lisy M, et al. Solitary fibrous tumor. *Transl Gastroenterol Hepatol*. 2018;3:94-94.
- Gengler C, Guillou L. Solitary fibrous tumour and haemangiopericytoma: evolution of a concept. *Histopathology*. 2006;48(1):63-74.
- Alawi F, Stratton D, Freedman PD. Solitary fibrous tumor of the oral soft tissues: a clinicopathologic and immunohistochemical study of 16 cases. *Am J Surg Pathol*. 2001;25(7):900-910.
- Shimoyama T, Horie N, Ide F. Solitary fibrous tumor of the palate: a case report and review of the literature. *J Oral Maxillofac Surg*. 2004;62:895-897.
- Organisation mondiale de la santé, Centre international de recherche sur le cancer, eds. *Soft Tissue and Bone Tumours*. 5th ed. Geneva, Switzerland: Organisation mondiale de la santé; 2020.
- Künzel J, Hainz M, Ziebart T, et al. Head and neck solitary fibrous tumors: a rare and challenging entity. *Eur Arch Otorhinolaryngol*. 2016;273(6):1589-1598.
- Li XM, Yu JQ, Xu GH. Solitary fibrous tumor of the soft palate: a report of two cases. *Oncol Lett*. 2014;7(6):1975-1977.
- Shmuly T, Ben Zvi Y, Chaushu G, et al. Oral solitary fibrous tumor: a retrospective clinico-pathological study and long-term follow-up. *Medicina*. 2021;57:152.
- Talacko AA, Aldred MJ, Sheldon WR, Hing NR. Solitary fibrous tumour of the oral cavity: report of two cases. *Pathology*. 2001;33(3):315-318.
- O'Regan EM, Vanguri V, Allen CM, Eversole LR, Wright JM, Woo SB. Solitary fibrous tumor of the oral cavity: clinicopathologic and immunohistochemical study of 21 cases. *Head Neck Pathol*. 2009;3(2):106-115.
- Demicco EG, Park MS, Araujo DM, et al. Solitary fibrous tumor: a clinicopathological study of 110 cases and proposed risk assessment model. *Mod Pathol*. 2012;25(9):1298-1306.
- Robinson DR, Wu YM, Kalyana-Sundaram S, et al. Identification of recurrent NAB2-STAT6 gene fusions in solitary fibrous tumor by integrative sequencing. *Nat Genet*. 2013;45(2):180-185.
- Smrke A, Thway K, H Huang P, Jones RL, Hayes AJ. Solitary fibrous tumor: molecular hallmarks and treatment for a rare sarcoma. *Future Oncol*. 2021;17(27):3627-3636.
- Tai H-C, Chuang I-C, Chen T-C, et al. NAB2-STAT6 fusion types account for clinicopathological variations in solitary fibrous tumors. *Mod Pathol*. 2015;28(10):1324-1335.
- Barthelmeß S, Geddert H, Boltze C, et al. Solitary fibrous tumors/hemangiopericytomas with different variants of the NAB2-STAT6 gene fusion are characterized by specific histomorphology and distinct clinicopathological features. *Am J Pathol*. 2014;184:1209-1218.
- Dagrada GP, Spagnuolo RD, Mauro V, et al. Solitary fibrous tumors: loss of chimeric protein expression and genomic instability mark dedifferentiation. *Mod Pathol*. 2015;28:1074-1083.
- Kazazian K, Demicco EG, de Perrot M, Strauss D, Swallow CJ. Toward better understanding and management of solitary fibrous tumor. *Surg Oncol Clin N Am*. 2022;31:459-483.
- Schiroli L, Lantuejoul S, Cavazza A, et al. Pleuro-pulmonary solitary fibrous tumors: a clinicopathologic, immunohistochemical, and molecular study of 88 cases confirming the prognostic value of de perrot staging system and p53 expression, and evaluating the role of c-kit, BRAF, PDGFRs ( $\alpha/\beta$ ), c-met, and EGFR. *Am J Surg Pathol*. 2008;32:1627-1642.
- Bahrami A, Lee S, Schaefer IM, et al. TERT promoter mutations and prognosis in solitary fibrous tumor. *Mod Pathol*. 2016;29(12):1511-1522.
- Machado I, Morales GN, Cruz J, et al. Solitary fibrous tumor: a case series identifying pathological adverse factors—implications for risk stratification and classification. *Virchows Arch*. 2020;476:597-607.
- Kurisaki-Arakawa A, Akaike K, Hara K, et al. A case of dedifferentiated solitary fibrous tumor in the pelvis with TP53 mutation. *Virchows Arch*. 2014;465(5):615-621.