

---

## Short QT syndrome in a 14-year-old patient: The first pediatric case from Turkey

**Yakup Ergül, İsa Özyılmaz, Sertaç Hanedan Onan<sup>1</sup>, Alper Güzeltaş**  
Department of Pediatric Cardiology, Mehmet Akif Ersoy Thoracic and Cardiovascular Surgery Center and Research Hospital; İstanbul-Turkey

<sup>1</sup>Department of Pediatric Cardiology, Bağcılar Training and Research Hospital; İstanbul-Turkey

### Introduction

Short QT syndrome (SQTS) is a cardiac channelopathy associated with sudden cardiac death (SCD) and disposition to atrial-ventricular fibrillation (A-VF) (1). An accelerated ventricular repolarization (VR) abnormality develops in the heart due to an electrical stability disorder secondary to increased extracellular potassium flow in the heart (2, 3). Therefore, ventricular arrhythmias develop, which cause syncope, convulsion, and SD (2).

This paper presents a 14-year-old male patient whose elder brother and father had died because of SD and who presented to us with the complaint of syncope. He was identified to have a short QT interval (SQTi) in his electrocardiogram (ECG) result, diagnosed with SQTS following an electrophysiological study (EPS), and implanted with an implantable cardioverter defibrillator (ICD).

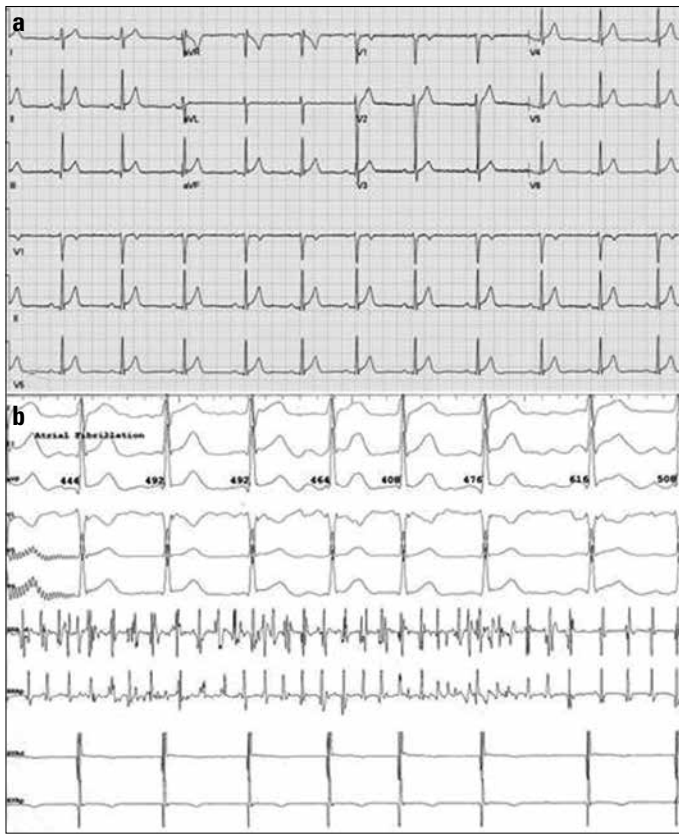
### Case Report

The 14-year-old male patient presented to our center with the symptom of syncope. His elder brother was found dead after taking a bath (autopsy result negative), and his father was found dead while he was asleep. The physical examination, biochemical parameters, telecardiography, and echocardiography results of the patient were normal. The QT and QTc values were identified to be 310 msec and 320 msec in his ECG result, respectively (Fig.1a). After the family's consent was received, in EPS, the patient had a QTc value of 323 msec and the values for the atrial-ventricular effective refractory period (AERP-VERP) pertaining to the SQTS were found to be short, i.e., 150 msec and 160 msec, respectively. It was observed that the patient easily entered AF based on a programmed stimuli delivered through the right atrium catheter (Fig.1b). The six-step ventricular tachycardia (VT) stimulation protocol was started in such a way that the ventricular catheter was placed first on the right ventricle (RV) apex and then on the RV outflow tract. Upon a triple stimulus at the RV apex, polymorphic VT and VF suddenly developed (Fig. 2a). The VF attack was terminated after the delivery of 100 joules of energy by the defibrillator. His SQTS diagnosis score of >4 (diagnosis score-7) were taken into account. A transvenous, single-chamber ICD was successfully implanted in the patient (Fig. 2b). The patient was started on Sotalol therapy; the result of the genetic study is awaited.

### Discussion

According to the HRS/EHRA/APHS specialists' consensus guide, SQTS diagnosis is made if the QTc value is  $\leq 330$  msec. If the QTc distance is measured as  $<360$  msec for girls and as  $<350$  msec for boys, it is diagnosed in the presence of one or more of the following conditions: pathogenic mutation, family history of SQTS, history of sudden death below the age of 40 years, and surviving a VT/VF episode without any cardiac diseases (3,4). During EPS, AERP and VERP are typically measured to be short. The AERP and VERP values of our patient were measured to be  $<160$  msec.

It is recommended that an ICD can be implanted as a Class I indication in short QT syndrome patients, who have survived a cardiac arrest and have symptoms such as a documented spontaneous sustained VT attack with or without syncope. ICD implantation may be considered as a Class IIb indication in asymptomatic patients with a diagnosis of SQTS and a family history of SCD. Furthermore, quinidine and sotalol treatment



**Figure 1. a, b. (a) Patient's first ECG. Particularly, the short QTc (320 msec) and early repolarization pattern is remarkable (b) Induction of atrial fibrillation during EPS**

may be considered as a Class IIb indication in asymptomatic patients with a diagnosis of SQTs and a family history of SCD (3, 4). Our case is the first pediatric case reported in Turkey, who was diagnosed with SQTs based on seven points in total according to the SQTs diagnostic criteria.

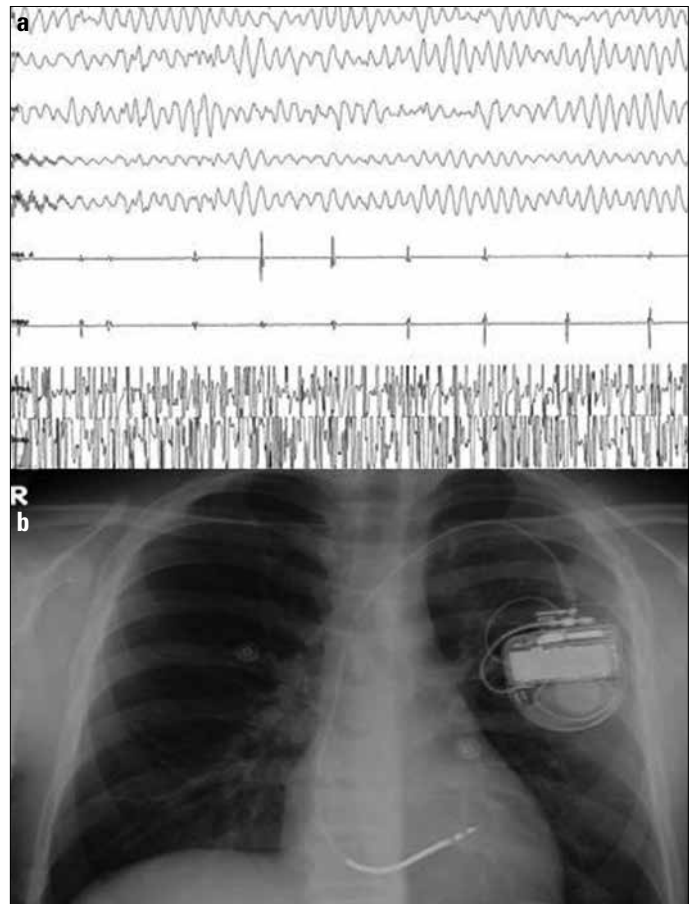
It is reported that genetic transmission is autosomal dominant and highly penetrative with SQTs. To date, seven different mutations have been defined. Some of these include patients associated with the overlapping effect of SQTs (Types 4–7) and Brugada syndrome (Types 3,4) (1, 3). The incidence of early repolarization is high with SQTs (1). Factors that reduce the QT value such as digoxin intake, hypercalcemia, use of androgens, and SQT1 condition must be ruled out. There are also several publications indicating that there are no correlations between SQT1 and life-threatening cardiac events (3, 5, 6). It is considered that SQT1 is marked by the lack of a phenotypical expression, which is not associated with arrhythmia (5). Babaoğlu et al. (6) published a case report with asymptomatic SQT1 where no arrhythmias could be induced during EPS.

## Conclusion

EPS should be performed in selected SQTs cases. It is absolutely recommended that an ICD should be implanted in patients meeting the diagnostic criteria and requiring it. In addition, quinidine or sotalol treatment may be considered for necessary cases.

## References

1. Gollob MH, Redpath CJ, Roberts JD. The short QT syndrome: proposed diagnostic criteria. *J Am Coll Cardiol* 2011; 57: 802-12. [CrossRef]



**Figure 2. a, b. (a) Induction of ventricular fibrillation during EPS (b) Patient's telecardiogram after ICD implantation**

2. Villafane J, Young ML, Maury P, Wolpert C, Anttonen O, Hamilton R, et al. Short QT syndrome in a pediatric patient. *Pediatr Cardiol* 2009; 30: 846-50. [CrossRef]
3. Brugada J, Gussak I, Brugada P. Short QT syndrome: a predictable story. *Cardiology* 2014; 128: 231-3. [CrossRef]
4. Priori SG, Wilde AA, Horie M, Cho Y, Behr ER, Berul C, et al. HRS/EHRA/APHRS expert consensus statement on the diagnosis and management of patients with inherited primary arrhythmia syndromes: document endorsed by HRS, EHRA, and APHRS in May 2013 and by ACCF, AHA, PACES, and AEPCC in June 2013. *Heart Rhythm* 2013; 10: 1932-63. [CrossRef]
5. Couderc JP, Lopes CM. Short and long QT syndromes: does QT length really matter? *J Electrocardiol* 2010; 43: 396-9. [CrossRef]
6. Babaoğlu K, Binnetoğlu K, Altun G, Tuzcu V. A 13-year-old boy with a short QT interval. *Anatol J Cardiol* 2012; 12: 274-5. [CrossRef]

**Address for Correspondence:** Dr. İsa Özyılmaz,  
Mehmet Akif Ersoy Kardiyovasküler Eğitim ve Araştırma  
Hastanesi, Halkalı, Küçükçekmeçe, İstanbul-*Türkiye*  
Phone: +90 212 692 20 00-1134  
Fax: +90 212 471 94 94

E-mail: isaozy@hotmail.com

©Copyright 2015 by Turkish Society of Cardiology - Available online at [www.anatoljcardiol.com](http://www.anatoljcardiol.com)

DOI:10.5152/akd.2015.6291

