

This is an Open Access article licensed under the terms of the Creative Commons Attribution-NonCommercial-NoDerivs 3.0 License (www.karger.com/OA-license), applicable to the online version of the article only. Distribution for non-commercial purposes only.

Adhesive Ileus Complicating Recurrent Intestinal Pseudo-Obstruction in a Patient with Myasthenia Gravis

Charalampos Seretis^{a, b} Fotios Seretis^a
George Gemenetzi^{a, b} Stavros Gourgiotis^a
Emmanuel Lagoudianakis^a Apostolos Pappas^c
Dimitrios Keramidaris^b Nikolaos Salemis^a

^a2nd Department of Surgery and ^bDepartment of Emergency Medicine, 401 General Army Hospital of Athens, Athens, and ^cDepartment of Internal Medicine, Argos Hospital, Argos, Greece

Key Words

Myasthenia gravis · Adhesive ileus · Intestinal pseudo-obstruction · Emergency surgery

Abstract

Intestinal pseudo-obstruction is considered to be one of the most frequent gastrointestinal manifestations of myasthenia gravis, accompanied by the presence of neoplasia of the thymus gland in the vast majority of the cases presented in the international literature. Despite the fact that myasthenia gravis has been implicated to be the cause of recurrent episodes of intestinal pseudo-obstruction, adhesive ileus has never been reported to complicate this – in any sense rare – condition. We present a unique case of a patient with myasthenia gravis, free of thymus neoplasia, who was submitted to emergency surgery due to the presence of extended adhesive ileus as a complication of chronic intestinal functional obstruction.

Introduction

Myasthenia gravis (MG) stands for a disorder of neuromuscular transmission, with its pathogenetic mechanism lying in the presence of circulating antibodies against acetylcholine receptors, resulting in dysfunction of the neuromuscular synapses [1]. Intestinal pseudo-obstruction, a condition characterized by the presence of symptoms and signs of bowel obstruction in the absence of any mechanical etiology, has been

reported as a gastrointestinal manifestation of MG, with possibly paraneoplastic origin, due to the presence of concurrent thymomas, in all relative cases reported up to date [2]. Thus, apart from the conservative measures taken to confront the functional intestinal obstruction, surgical intervention has been limited to the possibility of performing thymectomy, which appears to have a beneficial effect in terms of relieving the patient from the recurrent pseudo-obstruction episodes [3]. Herein, we report a unique case of surgically treated extended adhesive ileus which complicated chronic functional intestinal obstruction in a patient with MG, free of thymus neoplasia.

Case Report

A 34-year-old female, diagnosed with MG since the age of 26 years, for which she was under treatment with pyridostigmine, was referred to the emergency department with symptoms of intestinal obstruction, which had commenced approximately 48 h prior to admission. On physical examination, the patient had a distended abdomen, with absence of bowel sounds, while rectal examination revealed the presence of impacted stool in the anal canal. The patient had mild, bilateral ptosis and ophthalmoplegia, with tendon reflexes being slightly decreased but present. Her vital signs and basic laboratory examinations were within normal values. The patient reported that she had been suffering from chronic constipation and that she had been hospitalized twice during the previous year due to similar pseudo-obstruction episodes, receiving in both cases intravenous pyridostigmine and conservative treatment for decompression of the bowel. Her medical history was otherwise unremarkable. Due to clinical suspicion of underlying concurrent thymoma, the patient was referred to the emergency department for a chest X-ray, which did not demonstrate any mediastinal pathology. Abdominal X-ray revealed distended bowel loops and evidence of impacted stool in the large intestine.

The patient was hospitalized in order to be submitted to further examinations; thoracic CT confirmed the absence of mediastinal pathology, and abdominal CT demonstrated the existence of remarkable generalized intestinal distension, with no evidence of mechanical cause of the obstruction (fig. 1). On the 2nd day of hospitalization, despite all conservative measures, including nasogastric tube, intravenous administration of pyridostigmine and fluids, the patient's general condition was evidently deteriorating, accompanied by onset of metabolic acidosis and persistent abdominal pain. She was scheduled for exploratory laparotomy, with initial intention to perform a loop colostomy. Intraoperatively, the presence of multiple adhesions between the intestinal loops was noticed, which extended throughout the entire length of the small bowel. After manual decompression of the intestine, extended adhesiolysis was performed. The patient's postoperative course was uneventful and she was discharged free of symptoms on the 5th postoperative day.

Discussion

Functional bowel obstruction is characterized by impaired intestinal propulsive motility in the absence of any mechanical obstruction [4]. MG has sporadically been reported to predispose to the derangement of intestinal motility and is thus suggested to be a potential cause of bowel pseudo-obstruction [5]. It is to be mentioned that to the best of our knowledge, in all of these cases, MG was coexisting with thymomas, rising concerns regarding the potential paraneoplastic nature of this clinical manifestation from the gastrointestinal tract [6]. Up to date, from the available reports, in cases of functional bowel obstruction due to MG, surgical intervention has only been required for resection of thymomas, as thymectomy appears to have a favorable effect in alleviating the symptoms of colonic pseudo-obstruction in this group of patients [7]. In our case, although initially suspected, thoracic CT failed to indicate a concurrent thymoma, thus there was no need for scheduled surgical operation. Nevertheless, the

unexpected deterioration of the patient's clinical condition and the failure of conservative treatment set the indication for exploratory laparotomy, having as initial plan to perform a colostomy. The intraoperative findings completely changed the operation plan. It is justified to assume that the recurrent episodes of functional bowel obstruction could have promoted a chronic intestinal inflammatory status, leading to the formation of diffuse adhesions between the small intestine loops. Indeed, recent experimental studies have demonstrated a strong correlation between impaired intestinal motility and chronic gut inflammation [8]. To the best of our knowledge, our case presentation is the first to report adhesive ileus as a complication of recurrent intestinal pseudo-obstruction in a patient with MG.

Conclusions

MG should be considered in the differential diagnosis of intestinal pseudo-obstruction. Although conservative treatment should be adopted as a first-line treatment strategy, surgical intervention may also have a role in cases of chronic functional obstruction.

Disclosure Statement

The authors declare that they have no competing interests.

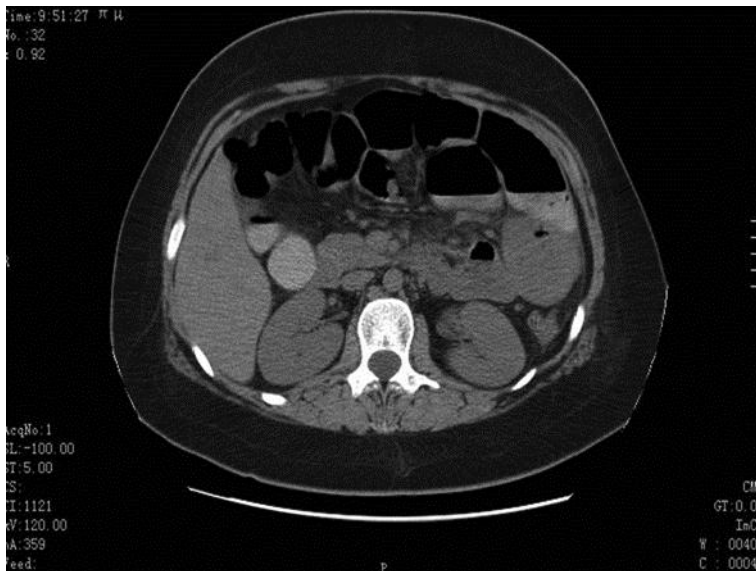


Fig. 1. CT imaging of the abdomen, revealing evident distension of the bowel loops, with no sign of mechanical obstruction.

References

- 1 Pande R, Leis AA: Myasthenia gravis, thymoma, intestinal pseudo-obstruction, and neuronal nicotinic acetylcholine receptor antibody. *Muscle Nerve* 1999;22:1600–1602.
- 2 Anderson NE, Hutchinson DO, Nicholson GJ, Aitcheson F, Nixon JM: Intestinal pseudo-obstruction, myasthenia gravis, and thymoma. *Neurology* 1996;47:985–987.
- 3 Kulling D, Reed CE, Verne GN, Cotton PB, Tarnasky PR: Intestinal pseudo-obstruction as a paraneoplastic manifestation of malignant thymoma. *Am J Gastroenterol* 1997;92:1564–1566.
- 4 Antonucci A, Fronzoni L, Cogliandro L, et al: Chronic intestinal pseudo-obstruction. *World J Gastroenterol* 2008;14:2953–2961.
- 5 Rakocevic G, Barohn R, McVey AL, et al: Myasthenia gravis, thymoma, and intestinal pseudo-obstruction: a case report and review. *J Clin Neuromuscul Dis* 2003;5:93–95.
- 6 Malhotra K, Georgiades IB, Davies J: Functional colonic obstruction in an adult as a presenting feature of thymoma. *Ann R Coll Surg Engl* 2011;93:61–63.
- 7 Musthafa CP, Moosa A, Chandrashekhara PA, Nandakumar R, Narayanan AV, Balakrishnan V: Intestinal pseudo-obstruction as initial presentation of thymoma. *Indian J Gastroenterol* 2006;25:264–265.
- 8 Feinstein RE, Morris WE, Waldemarson AH, Hedenqvist P, Lindberg R: Fatal acute intestinal pseudoobstruction in mice. *J Am Assoc Lab Anim Sci* 2008;47:58–63.