



CASE REPORT

Ventricular pacemaker lead in the left hemithorax: Mechanisms and evidence-based management of a late-onset hazardous complication

Jacopo Marazzato  | Fabrizio Caravati | Federico B. M. Blasi | Taulant Refugjati | Manola Vilotta | Federica Torchio | Andrea M. Musazzi | Cesare Beghi | Roberto De Ponti 

Department of Heart and Vessels, Ospedale di Circolo, University of Insubria, Varese, Italy

Correspondence

Jacopo Marazzato, Department of Heart and Vessels, Ospedale di Circolo, University of Insubria, Viale Borri, 57, 21100 Varese, Italy.
Email: j.marazzato88@gmail.com

Funding information

This research did not receive any specific grant from funding agencies in the public, commercial, or not-for-profit sectors

Abstract

Late-onset migration of pacing leads in the left hemithorax is a rare but potentially life-threatening complication. Radiological examinations are required to detect any involvement of either left ventricle or lung parenchyma, prompting immediate surgical extraction in this setting. Identification of high-risk patients is mandatory to prevent this complex iatrogenic complication.

KEY WORDS

cardiac pacing, cardiac surgical procedures, lead migration, traumatic cardiac perforation

1 | INTRODUCTION

Iatrogenic perforation of the right ventricle by pacemaker (PM) or implantable cardioverter defibrillator (ICD) leads is rare, accounting for 0.3%-0.8% of all pacing procedures.^{1,2} It usually occurs <24 hours after device implantation; however, late-onset (>1 month) cardiac perforations have been described.¹ While percutaneous lead removal by simple traction can be uneventfully performed in some cases,¹ far less clear is the proper management of lead migration in the left hemithorax, since no straightforward recommendations are available in this setting.

In this case report, we described the uneventful management of this rare complication. We also endeavored to explore the pathophysiological mechanisms and risk factors associated with this condition.

2 | CASE REPORT

A 78-year-old woman with nonrevascularizable multivessel coronary artery disease (Figure 1A,B) was implanted with a dual-chamber PM (Biotronik Edora 8 DR-T) for symptomatic sick sinus syndrome at our institution. Briefly, after cephalic vein access, the two active fixation leads were placed at the middle portion of the right interventricular septum (Biotronik Solia S 60) and the right atrial appendage (Biotronik Solia S 53), respectively, with excellent pacing parameters and no peri-procedural complications (Figure 2A). Pre-discharge transthoracic echocardiogram showed no signs of structural heart disease.

Two months after discharge, the patient referred to the emergency department for syncopal episodes and unremitting left chest pain. PM interrogation showed loss of ventricular capture

Abbreviations: CT, computed tomography; ICD, implantable cardioverter defibrillator; PM, pacemaker.

This is an open access article under the terms of the Creative Commons Attribution-NonCommercial-NoDerivs License, which permits use and distribution in any medium, provided the original work is properly cited, the use is non-commercial and no modifications or adaptations are made.

© 2021 The Authors. *Clinical Case Reports* published by John Wiley & Sons Ltd.

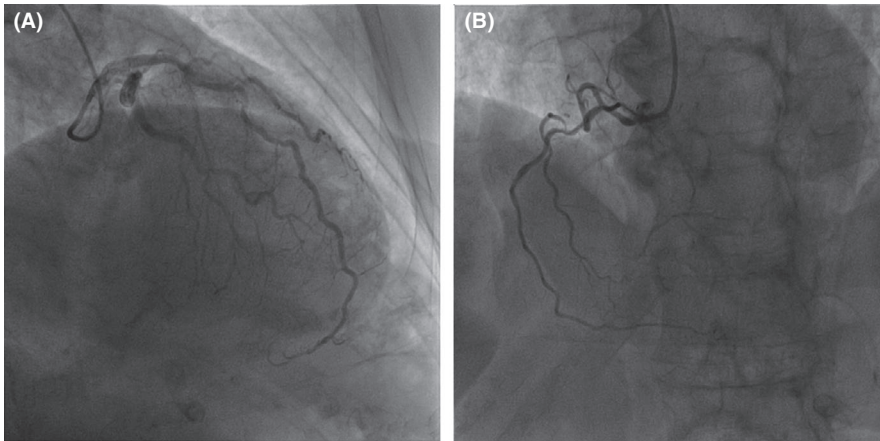


FIGURE 1 A-B, Coronary angiogram. The left anterior descending and circumflex coronary arteries display a diffuse atherosclerotic disease with multiple focal stenoses (A), and the right coronary artery is slender (B). Of note, poor coronary blood flow is observed on the mid-apical portion of the interventricular septum in this patient (A)

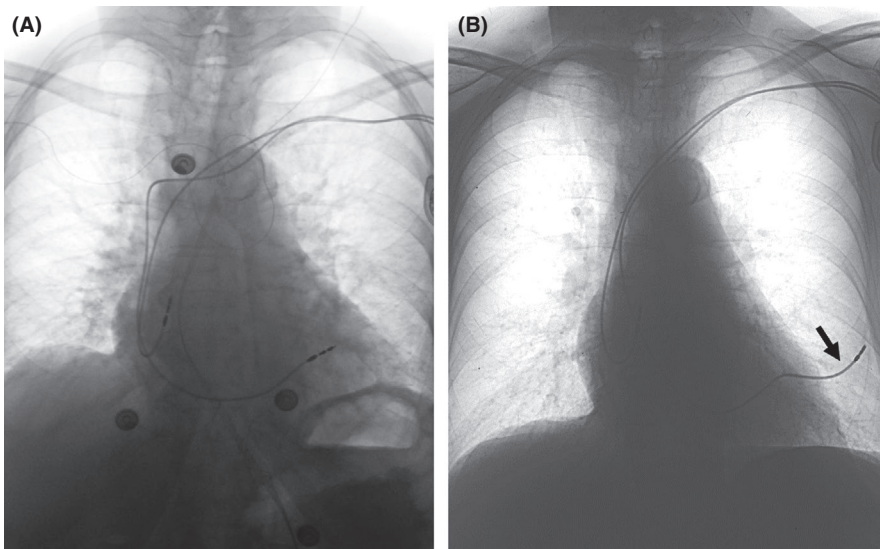


FIGURE 2 A-B, Chest X-rays performed 1 day (A) and 60 days (B) after pacemaker implantation. The day after the procedure, both atrial and ventricular pacemaker leads were properly positioned at the right atrial appendage and septal mid-wall, respectively (A). B, shows the same postero-anterior view of the patient's heart 60 days after the procedure: while the atrial lead is located at the same place as compared with (A), the ventricular lead is well beyond the left cardiac margin and clearly migrated in the left hemithorax (arrow)

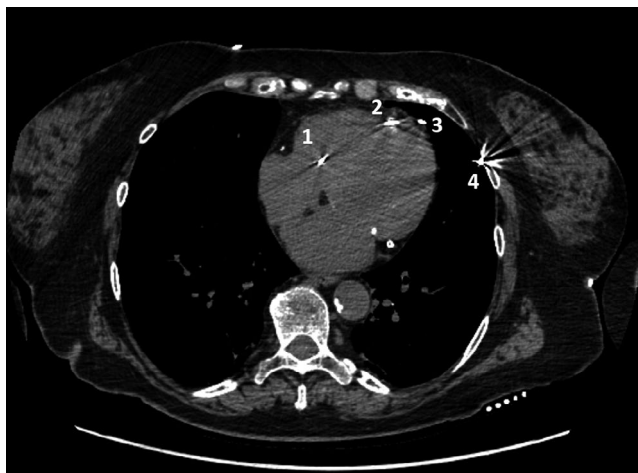


FIGURE 3 Thoracic computed tomography scan. The radiological scan clearly shows the ventricular lead course from the right ventricle (1) to the left chest wall (4) in this patient. Perforation of both the interventricular septum (2) and the left ventricular free wall (3) are well evident, posing the non-surgical lead extraction at an exceedingly high procedural risk. Computed tomography scan should therefore be regarded as the gold standard for the strategical management of this complication

and urgent chest X-ray identified the ventricular lead tip at approximately 3.5 cm from the left cardiac margin, abutting the left chest wall (Figure 2B). Similar findings were reported on the thoracic computed tomography (CT) scan, which showed the passage of the left ventricular lead from the interventricular septum to the left ventricular free wall, reaching the left pleural cavity but with no clear signs of left hemothorax (Figure 3).

The subsequent patient's management was thoroughly debated. However, after a thorough research of the available literature (Table 1) and given the potentially life-threatening complications due to transvenous lead removal, the patient was moved to the surgical theater for off-pump lead extraction. The surgical intervention is fully depicted and described in Figure 4A-D. Surgical extraction was uncomplicated, and the patient was discharged home 7 days after the procedure with an uneventful 6-month follow-up.

3 | DISCUSSION

Late-onset lead migration beyond the left cardiac margin is a rare event, and, to our knowledge, no clear recommendations

TABLE 1 Literature-based clinical cases reporting migration of ventricular PM/ICD leads from the right ventricle to the left hemithorax

Author	Year	Sex	Age (y)	Comorbidity	Ventricular lead type	Lead position	Time from implantation to lead complication	Symptoms	Pacing parameters	Lead migration	Management	New lead position	Follow-up
Selcuk, et al ³	2006	F	30	N/A	N/A	RV apex	2 weeks	Chest pain	N/A	RV apex, left pleural perforation with no hemithorax	Surgical extraction	N/A	Uneventful
Migliore, et al ⁴	2010	M	52	Brugada Syndrome	Active fixation ICD lead	RV apex	12 days	None	Loss of pacing capture. High pacing impedance	Septum, LV free wall	Surgical extraction	Passive fixation ICD lead	Uneventful
Bohora, et al ⁵	2010	M	44	N/A	Active fixation PM lead	RV apex	5 days	Chest pain, fatigue, cough, left hemithorax	Loss of pacing capture. Normal pacing impedance	RV apex, left pleura perforation and hemithorax	Surgical extraction	Epicardial pacing lead	Uneventful
Kondoh, et al ⁶	2012	M	82	N/A	Active fixation PM lead	RV septum	3 months	Acute severe chest pain	Loss of pacing capture	Septum, LV free wall	Surgical extraction	Epicardial pacing lead	Uneventful
Forleo, et al ⁷	2013	F	81	N/A	Active fixation PM lead	RV apex	7 months	Third-degree AV block, left hemithorax	Loss of pacing capture, low ventricular sensing, normal pacing impedance	RV apex, left pleura perforation and hemithorax	Initially conservative, then Surgical extraction	Transvenous active fixation lead on septum	Uneventful
Pojar, et al ⁸	2013	M	74	Dilated cardiomyopathy	Active fixation PM lead	RV apex	3 months	Heart failure and cardiogenic shock	N/A	RV apex, left pleura perforation and hemithorax	Surgical extraction	Transvenous ICD lead	Uneventful
Iribarne, et al ⁹	2018	F	69	Asthma on steroids, hypothyroidism	Active fixation PM lead	RV septum	2 weeks	None	Loss of pacing capture. Variation in Lead impedances	Septum, free wall, left pleura but with no hemithorax	Surgical extraction	Epicardial pacing lead	Uneventful
Satomi, et al ¹⁰	2021	M	84	Hypertension prior history of stroke	Active fixation PM lead	RV septum	2 days	None	Loss of pacing capture.	Septum, free wall, LV posterior wall; scratching the pleural cavity but with no lung damage	Surgical extraction	Transvenous before cardiac surgery	Uneventful

Abbreviations: AV, atrio-ventricular; F, female; ICD, implantable cardioverter defibrillator; LV, left ventricular; M, male; N/A, not available; PM, pacemaker; RV, right ventricular.

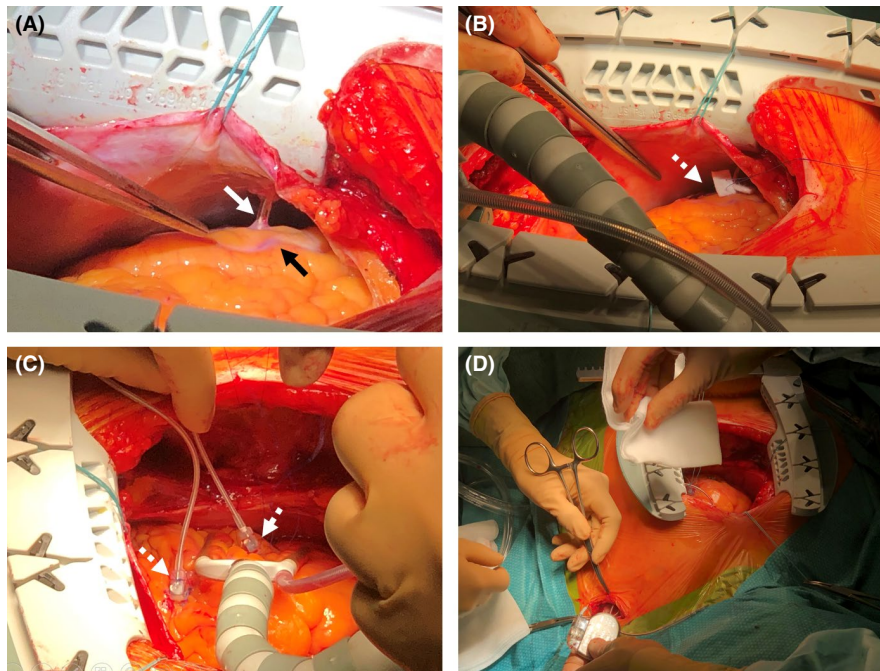


FIGURE 4 A-D, Off-pump surgical extraction of the ventricular lead. After median sternotomy and excision of the pericardial sack, the ventricular lead tip was found projecting from the left ventricular free wall (A, *white arrow*) and 2 cm from the left anterior descending coronary artery (*black arrow*). No damage to the lung parenchyma was observed. The right ventricular lead was then extracted, and the injured myocardium repaired with U stitches reinforced by Teflon-pledgets (B, *dotted white arrows*). A new epicardial bipolar lead (Medtronic 4968–60 cm) was fixed on the right ventricular wall (C, *dotted white arrows*) and tunneled through the subcutaneous layers to reach the surgical pocket in the infraclavicular region where it was connected to the old pulse generator (D)

do exist in this setting. Moreover, the involved pathophysiological mechanisms have not been thoroughly investigated yet.

Table 1 displays lead type, position, migration course, pacing parameters, together with the clinical features, management, and follow-up of all the available clinical cases reported in literature experiencing this troublesome iatrogenic complication.^{3–10}

As previously reported,² active fixation leads placed on the thin-walled right ventricular apex seem associated with an increased risk of cardiac perforation together with lead migration in the left pleural cavity on account of the close anatomical location of these two anatomical structures. However, as shown in Table 1, left-sided migration of ventricular lead could be also due to double perforation of both the thick-walled interventricular septum and the left ventricular free wall.^{6,9,10} Although the mechanisms underpinning septal perforation are far from being established, the beat-to-beat twisting motion of the septal musculature together with poor blood supply in this very anatomical region may have played a pivotal role in the reported clinical case. Indeed, in this regard, the ventricular lead was placed at the mid-septum where the coronary angiogram had previously showed poor coronary flow (Figure 1A).

Furthermore, as shown in Table 1, only right ventricular apex perforation seems to be associated with a greater risk

of life-threatening hemothorax than septal perforation, potentially due to the iterative, beat-to-beat, thrusting movements of the ventricular lead against the left lung parenchyma and through the pierced right ventricular apex.^{5,7,8} The reason why double perforation seems associated with less pleural and/or lung parenchymal damage^{6,9,10} is not clear.

Whatever the mechanism underpinning lead migration in the left hemithorax, as shown in Table 1, off-pump surgical extraction was uneventfully performed in all cases, our patient included. Therefore, chest X-ray and thoracic CT scans are mandatory to assess whether pleural or septal/left ventricular free wall is involved, since these patients, despite the paucity of symptoms, should be promptly taken to the surgical theater for lead extraction. In case of involvement of right ventricular perforation only, transvenous lead extraction can be feasible,⁴ provided that a surgical back-up is warranted.

4 | CONCLUSIONS

Cardiac perforation and PM migration in the left hemithorax is a rare but potentially deadly complication. Radiological tests are mandatory to diagnose left pleural and/or septal/left ventricular involvement, prompting immediate surgical treatment in this setting. Finally, less traumatic passive-fixation

leads might be used in these high-risk patients with evidence of nonrevascularizable myocardial ischemia and clear indication for PM/ICD implantation.

CONFLICT OF INTEREST

Prof. R. De Ponti received lecture fees from Biosense Webster and Biotronik, and his institution received educational grant from Medtronic, Biotronik, Boston Scientific, Biosense Webster, and Abbot.

AUTHOR CONTRIBUTIONS

JM conceived the idea, data collection, intellectual process, manuscript drafting, and contributed to the final version of the manuscript. FC contributed to treatment application, manuscript drafting and contributed to the final version of the manuscript. FBMB, TR, MV, and FT contributed to data collection, intellectual process, follow-up, and manuscript writing. AM and CB contributed to treatment application, contributed to data collection, intellectual process, follow-up, and manuscript writing. RDP supervised the project.

ETHICAL APPROVAL

Ethical approval is waived for single case reports at our study center.

DATA AVAILABILITY STATEMENT

Data used in the current study are available from the corresponding author on reasonable request.

ORCID

Jacopo Marazzato  <https://orcid.org/0000-0003-1205-5925>

Roberto De Ponti  <https://orcid.org/0000-0003-3278-1721>

REFERENCES

- Migliore F, Zorzi A, Bertaglia E, et al. Incidence, management, and prevention of right ventricular perforation by pacemaker and implantable cardioverter defibrillator leads. *Pacing Clin Electrophysiol.* 2014;37:1602-1609.
- Cano Ó, Andres A, Alonso P, et al. Incidence and predictors of clinically relevant cardiac perforation associated with systematic implantation of active-fixation pacing and defibrillation leads: a single-centre experience with over 3800 implanted leads. *Europace.* 2017;19:96-102.
- Selcuk H, Selcuk MT, Maden O, et al. Uncomplicated heart and lung perforation by a displaced ventricular pacemaker lead: a case report. *Pacing Clin Electrophysiol.* 2006;29:429-430.
- Migliore F, Leoni L, Torregrossa G, et al. Asymptomatic right ventricular perforation by an implantable cardioverter defibrillator lead detected by home monitoring system. *J Electrocardiol.* 2010;43:673-675.
- Bohora S, Unnikrishnan M, Ajit Kumar VK, Nayyar S, Tharakan J. Left hemothorax: a presentation of a late ventricular perforation caused by an active fixation pacing lead. *Int J Cardiol.* 2010;141:e43-e46.
- Kondoh H, Funatsu T, Taniguchi K. Late left ventricular perforation by active fixation pacemaker lead implanted in the right ventricular septum. *J Card Surg.* 2012;27:530-531.
- Forleo GB, Zeitani J, Perretta T, et al. Acute left hemothorax as a late complication of an active-fixation pacemaker lead. *Ann Thorac Surg.* 2013;95:1081-1084.
- Pojar M, Vobornik M, Novy J. Left hemothorax: an unusual complication of delayed right ventricular perforation by a permanent pacemaker lead. *J Card Surg.* 2013;28:325-327.
- Iribarne A, Sangha RS, Bostock IC, Rothstein ES, McCullough JN. Right ventricular lead perforation through the septum, left ventricle, and pleura, managed by an open surgical approach. *HeartRhythm Case Rep.* 2018;4:397-400.
- Satomi N, Enta K, Otsuka M, Ishii Y, Asano R, Sawa S. Left ventricular free wall perforation by a right ventricular pacemaker lead: a case report. *Eur Heart J Case Rep.* 2021;5(3):ytab125.

How to cite this article: Marazzato J, Caravati F, Blasi FBM, et al. Ventricular pacemaker lead in the left hemithorax: Mechanisms and evidence-based management of a late-onset hazardous complication. *Clin Case Rep.* 2021;9:e04617. <https://doi.org/10.1002/ccr3.4617>