



Contents lists available at ScienceDirect

International Journal of Surgery Case Reports

journal homepage: www.casereports.com

Repeated resections for liver metastasis from primary adrenocortical carcinoma: A case report



Ryosuke Nakano^{a,*}, Daisuke Satoh^a, Hirochika Nakajima^a, Yuri Yoshimura^a, Hisanobu Miyoshi^a, Kazuhiro Yoshida^a, Hiroyoshi Matsukawa^a, Shigehiro Shiozaki^a, Kouichi Ichimura^b, Masazumi Okajima^a, Motoki Ninomiya^a

^a Department of Surgery, Hiroshima City Hiroshima Citizens Hospital, Hiroshima, Japan

^b Department of Pathology, Hiroshima City Hiroshima Citizens Hospital, Hiroshima, Japan

ARTICLE INFO

Article history:

Received 7 February 2015

Received in revised form 23 February 2015

Accepted 24 February 2015

Available online 26 February 2015

Keywords:

Adrenal cortical carcinoma

Liver metastasis

Resection

ABSTRACT

INTRODUCTION: Adrenal cortical carcinoma (ACC) is a very rare type of tumor that generally has a poor prognosis. Little has been reported on repeated liver resections with recurrent metastasis still confined to the liver. In this report, we describe a case of functioning ACC in a 65-year-old woman with 2 liver metastases of the ACC (at 1.5 and 4 years) after the right adrenalectomy.

PRESENTATION OF CASE: A 65-year-old woman was referred to our hospital based on a suspicion of hyperaldosteronism. Abdominal computed tomography revealed a lesion at the right adrenal gland; therefore, we performed right adrenalectomy and subsequently diagnosed the lesion as ACC. However, follow-up computed tomography at 1.5 and 4 years after the right adrenalectomy revealed liver metastasis of ACC; liver resection was performed for both metastases.

DISCUSSION: Complete surgical resection is the established approach for the treatment of ACC. The prognosis of ACC is usually dismal, and recurrence rates of up to 85% have been reported. However, the appropriate treatment for recurrent ACC is not well established, and the effectiveness of other modalities, such as chemotherapy and radiotherapy, is not proven. Therefore, surgical resection may currently be the most appropriate treatment modality, as the patient achieved a disease-free interval of 2.5 years after the first liver resection.

CONCLUSION: In selected patients with recurrent or metastatic ACC, resection is likely to be associated with prolonged survival. However, a full cure is generally not achievable, and a multidisciplinary approach is likely needed to achieve long-term disease-free status and survival.

© 2015 The Authors. Published by Elsevier Ltd. on behalf of Surgical Associates Ltd. This is an open access article under the CC BY-NC-ND license (<http://creativecommons.org/licenses/by-nc-nd/4.0/>).

1. Introduction

Adrenal cortical carcinoma (ACC) is a very rare tumor, with a heterogeneous presentation and an incidence of 0.7–2.0 cases/million people/year [1]. Although ACC can develop at any age, a bimodal age distribution has been observed, with peaks before the age of 5 years and at the age of 40–59 years [2]. Adrenal tumors are classified as functioning and non-functioning tumors. Functional tumors occur in an estimated 40–60% of adult patients, with the majority of these patients having Cushing's syndrome with hypercortisolism [3]. However, the pathogenesis of ACC remains poorly understood.

Unfortunately, the prognosis for ACC is generally poor, with a 5-year overall survival (OS) of 37% [4]. Although ACC is potentially

curable in the early stages, only approximately 30% of these malignancies are confined to the adrenal gland when they are diagnosed, as these tumors tend to be found years after their genesis. Therefore, these tumors have the opportunity for both near and distant metastases, and this aggressive behavior leads to their poor prognosis [5]. Common sites of metastases include the liver (47%), lungs (43%), and lymph nodes and bone (25%) [2], although the optimal management for recurrent ACC is currently not well established. Due to poor response rates to systemic treatments, surgery remains the best treatment modality for ACC, and complete resection offers the greatest hope for long-term survival [6].

In this report, we present a case of functioning ACC in a 65-year-old woman who initially underwent right adrenal surgical resection, and subsequently experienced recurrent liver metastases (at 1.5 and 4 years after the initial resection) that were surgically resected. We report this case, as little has been reported on repeated liver resections with recurrent metastasis still confined to the liver.

* Corresponding author at: Department of Surgery, Hiroshima City Hiroshima Citizens Hospital 7-33, Motomachi, Naka-ku, Hiroshima 730-8518, Japan. Tel.: +81 82 221 2291; fax: +81 82 223 5514.

E-mail address: r_so18@yahoo.co.jp (R. Nakano).

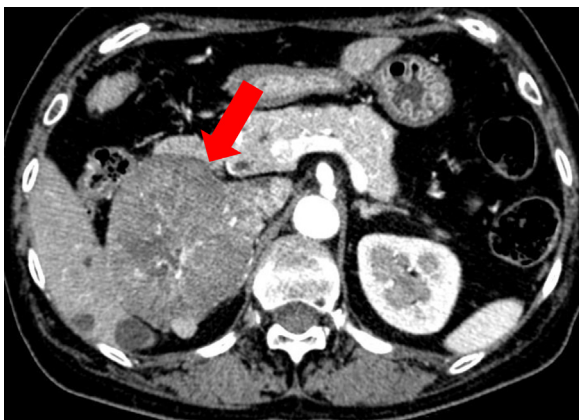

Fig. 1. Computed tomography of the 7 cm right adrenal mass (arrow).

2. Presentation of case

A 65-year-old Japanese woman presented to her family physician complaining of persistent pedal edema over a 2-month period. Blood tests revealed decreased potassium levels (2.2 mEq/L) and a urine test revealed proteinuria; therefore, she was referred to our hospital. Central obesity, moon facies, and stretch marks were observed in the physical examination, and detailed questions regarding her medical history revealed previous hypertension. However, her social history was unremarkable, and she reported no family medical history. Her blood pressure was 160/80 mmHg, and the results of liver and renal function tests with a complete blood count were within the normal limits. Her serum potassium levels were (2.6 mEq/L), and arterial blood gas examination indicated metabolic alkalosis (pH 7.47, $p\text{CO}_2 = 58.6$ mmHg, $\text{HCO}_3 = 42.1$ mEq/L). Abdominal computed tomography (CT) revealed a 7.0 cm lesion at the right adrenal gland (Fig. 1), and hormone testing revealed excessive serum cortisol (with loss of the diurnal pattern), elevated urine free cortisol, and a non-suppressible response to the dexamethasone test (Table 1). Therefore, we performed surgical removal of the right adrenal tumor, and histopathological examination revealed large eosinophilic cells with highly atypical nuclei and more than 5 mitoses per 50 high-power fields (Fig. 2). Based on these findings, the patient was diagnosed with ACC.

She had an uneventful postoperative period, and her blood pressure and serum potassium levels returned to normal levels within a few days. Furthermore, 1 year after the right adrenalectomy, hormone tests revealed normal patterns. However, follow-up abdominal CT at 1.5 year after the initial surgery revealed a solitary hepatic lesion (26 mm in diameter) in segment 7. Magnetic resonance imaging of the liver confirmed the presence of the 26 mm mass in segment 7 and also revealed a 10 mm mass in segment 5 (Fig. 3). Liver needle biopsy was subsequently performed, which

Table 1
Results of the hormone tests.

Hormone	Concentration	Reference
Basal hormones	–	–
09:00 AM serum cortisol ($\mu\text{g}/\text{dl}$)	14.8	3.7–19.4
21:00 PM serum cortisol ($\mu\text{g}/\text{dl}$)	16.1	3.7–19.4
Urinary free cortisol ($\mu\text{g}/\text{day}$)	351.0	176.0–4.3
Plasma renin activity (pg/ml)	0.5	0.3–2.9
Plasma aldosterone (pg/ml)	283	29–159
Urinary freealdosterone ($\mu\text{g}/\text{day}$)	43	<10
Serum DHEA-S ($\mu\text{mol}/\text{l}$)	72	12–133
High-dose dexamethasone test	–	–
Serum cortisol ($\mu\text{g}/\text{dl}$)	17.5	3.7–19.4

revealed metastatic carcinoma; therefore, the patient underwent the right hepatectomy. Histopathological assessment of the lobectomy specimens revealed that the mass was liver metastasis of the ACC. Follow-up abdominal CT at 4 year after the right adrenalectomy revealed another solitary hepatic lesion (29 mm in diameter) in segment 3. Therefore, the patient underwent partial resection of segment 3, and histopathological assessment of the specimens revealed that the mass was liver metastasis of the ACC (Fig. 4). The postoperative course was uneventful, and the patient was discharged 14 days after surgery. At the 6-month follow-up, she appeared healthy without clinical evidence of recurrent disease.

3. Discussion

ACC is a very rare malignancy, with an incidence of 0.7–2.0 cases/million people/year [1], and these tumors can be classified as functioning and non-functioning tumors. Functioning tumors occur in an estimated 40–60% of all adult patients, and these tumors may secrete excessive glucocorticoids (e.g., Cushing's syndrome), mineralocorticoids, and their downstream products, including androgens (virilization), estrogens (feminization), and aldosterone, which can cause hypertension [3,7]. In contrast, non-functioning tumors may present with pain or distention in the abdomen due to mass effect, weight loss, weakness, fever, and myalgia, or may be discovered incidentally during un-related radiographic imaging (e.g., abdominal CT or magnetic resonance imaging) [8,9]. In this case, the patient was referred to our hospital based on a suspicion of hyperaldosteronism, due to pedal edema, hypokalemia, and hypertension, and Cushing's syndrome was confirmed by the loss of the diurnal cortisol patterns and elevated urine levels of free cortisol.

Complete surgical resection is the established approach for treating ACC, and previous reports have demonstrated that the effectiveness of other modalities is limited [10,11]. However, even when the tumors are localized, the prognosis for ACC is usually dismal, and recurrence rates of up to 85% have been reported [12,13]. Furthermore, the 5-year OS for patients with metastatic ACC is <20%, with a median survival of between 6 and 20 months [14,15]. However, the management of recurrent ACC is not as well established in the literature. The currently available chemotherapies have limited efficiency, including the traditional and widely-used adrenolytic agent mitotane, which has a doubtful effect on survival [16,17]. Although radiation therapy has been used to palliate bony metastases, ACC is generally considered radioresistant, and the effectiveness of radiotherapy for ACC remains unclear [18]. In light of these findings, surgery remains the best treatment modality for ACC, and complete resection is considered the best hope for long-term survival [6]. However, data regarding the effectiveness of surgery in the management of recurrent ACC remain scarce. Nevertheless, due to the doubtful efficacy of other modalities, surgery should be considered for the treatment of recurrent or metastasis ACC if complete resection is possible. For example, in the present case, the patient achieved a disease-free interval (DFI) of 2.5 years after the first liver resection.

To achieve prolonged DFI and improve the prognosis, R0-resection has been suggested. For example, Datrice et al. have reported 57 patients who underwent 116 procedures for recurrent or metastatic disease, and the authors noted that the median OS for patients with a DFI of <12 months was 1.7 years, compared to 6.6 years for patients with a DFI of >12 months [6]. In another study of 154 patients with their first recurrence after initial radical resection of ACC, patients who had a DFI of >12 months and underwent R0-resection of the recurrent tumors had the best prognosis (median progression-free survival, 24 months; median OS, >60 months) [19]. The authors concluded that, in selected

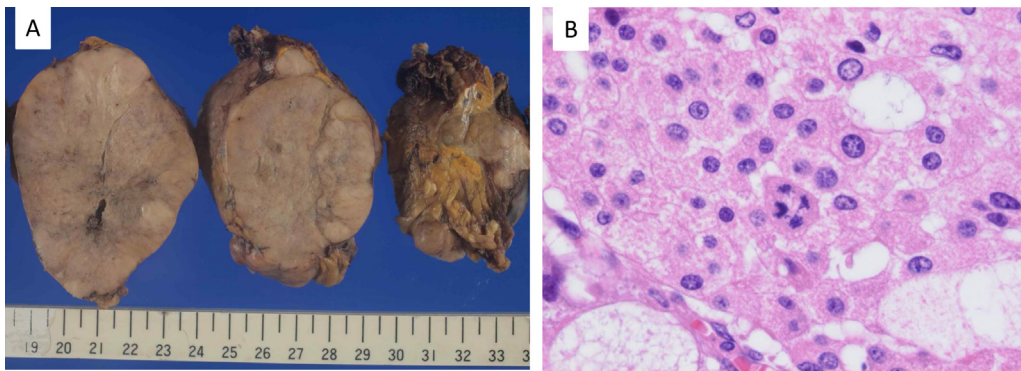


Fig. 2. The resected specimen from the first recurrence. (A) Macroscopic findings reveal a light-gray 7.7 cm mass. (B) Microscopic finding reveal large eosinophilic cells with highly atypical nuclei, and more than 5 mitoses per 50 high-power fields (hematoxylin and eosin, $\times 2$).

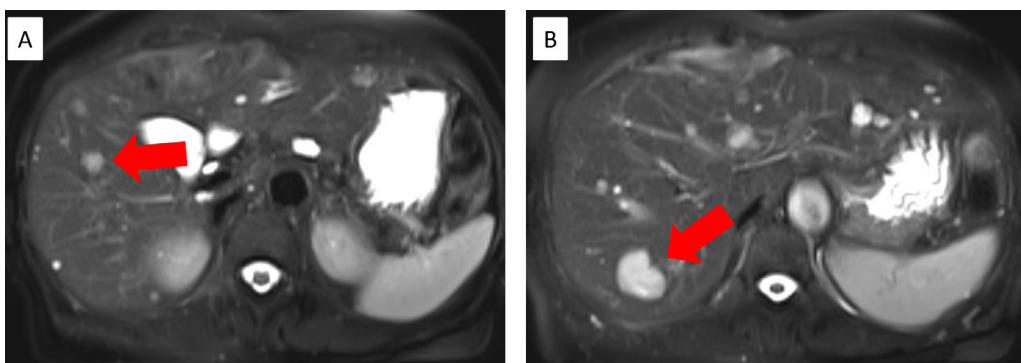


Fig. 3. Magnetic resonance imaging of the liver reveals (A) a 10 mm mass in segment 5, and (B) a 26 mm mass in segment 7.

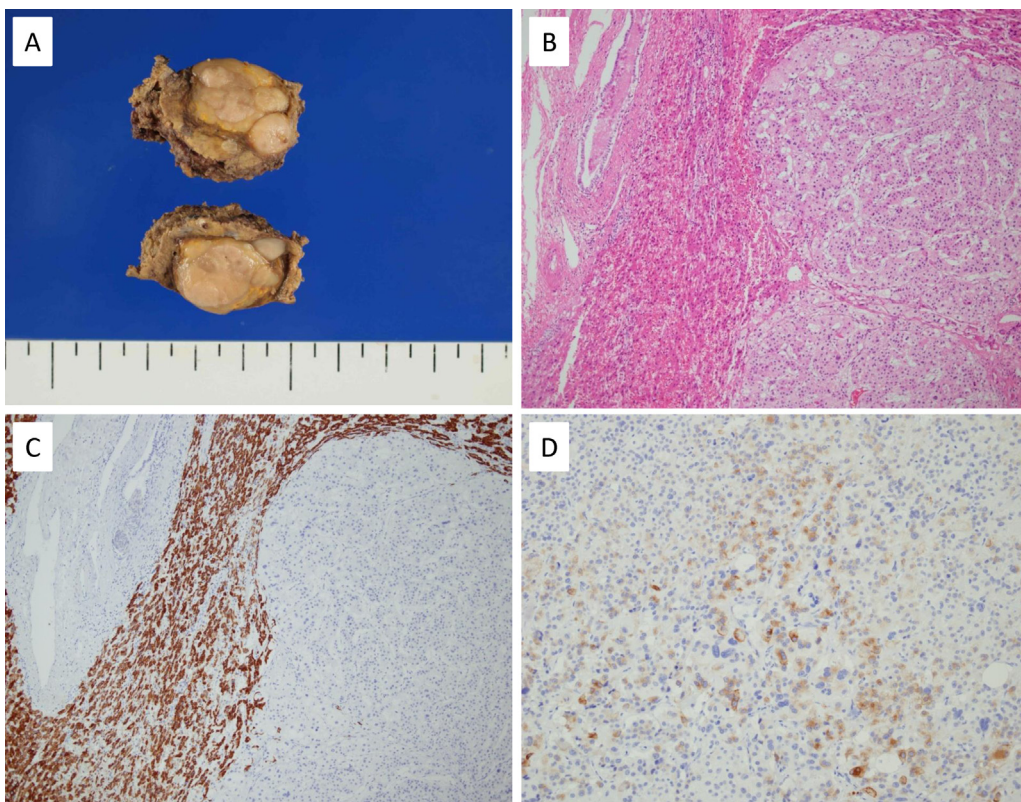


Fig. 4. The resected specimen from the second recurrence. (A) Macroscopic findings reveal a light-gray 2.8 cm mass. (B) Microscopic finding reveal the features of the primary adrenal cortical tumor, which was composed of large eosinophilic cells with highly atypical nuclei (hematoxylin and eosin, $\times 40$). Immunohistochemical staining reveals that the tumor cells were not immunoreactive for hepatocyte paraffin 1 (a monoclonal anti-hepatocyte antibody) (C), although the cells were diffusely immunoreactive for inhibin α (D).

patients with recurrent or metastasis ACC, resection is associated with prolonged survival. In the present case, the patient's prognosis appeared good, and resection should have been recommended, as no predictors of repeat resection were present. However, as there were 2.5 years between the first and second recurrence, we were able to choose surgical resection for the second recurrence. Nevertheless, it is important to note that a full cure after hepatic resection is generally not achievable, and Gaujoux et al. have reported that all 28 patients who underwent resection for ACC liver metastasis subsequently developed recurrent disease [20]. In the present case, the patient experienced recurrent metastasis within the liver, which was treated surgically via repeat hepatectomy. However, she achieved a DFI of 2.5 years after the first resection for liver metastasis; therefore, we believe that this outcome indicates the efficacy of surgical resection in similar cases. As our follow-up period was relatively short, special attention should be paid to the disease course after a second surgical resection, and a multidisciplinary approach is likely needed to achieve long-term disease-free status and survival.

4. Conclusion

We report the case of a 65-year-old Japanese woman with two recurrent liver metastases of ACC (1.5 and 4 years after right adrenal surgical resection) that were both surgically resected. Reports on repeated liver resections with recurrent metastasis still confined to the liver are scarce. In selected patients with recurrent or metastasis ACC, resection is likely to be associated with prolonged survival. However, as a full cure is generally not achievable, a multidisciplinary approach is likely needed to achieve long-term disease-free status and survival.

Conflicts of interest

All authors have nothing to disclose.

Funding

All authors have nothing to disclose.

Ethical approval

All procedures used in this research were approved by the Ethical Committee of Hiroshima City Hiroshima Citizens Hospital.

Consent

Written informed consent was obtained from the patient for publication of this manuscript and the accompanying images. Copies of the written consent are available for review upon request.

Author contributions

Ryosuke Nakano: performed the research, analyzed the data, and wrote the manuscript. Daisuke Satoh, Hirochika Nakajima, Yuri Yoshimura, Hisanobu Miyoshi, Kazuhiro Yoshida, Hiroyoshi Matsukawa, Shigehiro Shiozaki, and Masazumi Okajima:

performed the research and analyzed the data. Kouichi Ichimura analyzed the data. Motoki Ninomiya: performed the research, analyzed the data, designed the study, and interpreted the results.

Guarantor

Ryosuke Nakano.

References

- [1] M. Fassnacht, R. Libe, M. Kroiss, B. Allolio, Adrenocortical carcinoma: a clinician's update, *Nat. Rev. Endocrinol.* 7 (2011) 323–335.
- [2] M.A. Cuesta, H.J. Bonjer, J.C. van Mourik, Endoscopic adrenalectomy: the adrenals under the scope? *Clin. Endocrinol. (Oxford)* 44 (1996) 349–351.
- [3] M. Wandoloski, K.J. Bussey, M.J. Demeure, Adrenocortical cancer, *Surg. Clin. North Am.* 89 (2009) 1255–1267.
- [4] G. Abiven, J. Coste, L. Groussin, P. Anract, F. Tissier, P. Legmann, et al., Clinical and biological features in the prognosis of adrenocortical cancer: poor outcome of cortisol-secreting tumors in a series of 202 consecutive patients, *J. Clin. Endocrinol. Metab.* 91 (2006) 2650–2655.
- [5] N. Aghamohammadzadeh, A. Faraji, F. Bozorgi, I. Faraji, M. Moghadaszadeh, Primary hyperaldosteronism as initial presentation of adrenal cortical carcinoma with liver metastasis: a case report, *Int. J. Hematol. Oncol. Stem Cell Res.* 7 (2013) 38–42.
- [6] N.M. Datrice, R.C. Langan, R.T. Ripley, C.D. Kemp, S.M. Steinberg, B.J. Wood, et al., Operative management for recurrent and metastatic adrenocortical carcinoma, *J. Surg. Oncol.* 105 (2012) 709–713.
- [7] S. Chalasani, H.S. Vats, T.K. Banerjee, A.K. McKenzie, Metastatic virilizing adrenocortical carcinoma: a rare case of cure with surgery and mitotane therapy, *Clin. Med. Res.* 7 (2009) 48–51.
- [8] B. Allolio, M. Fassnacht, Clinical review: adrenocortical carcinoma: clinical update, *J. Clin. Endocrinol. Metab.* 91 (2006) 2027–2037.
- [9] M.M. Grumbach, B.M. Biller, G.D. Braunstein, K.K. Campbell, J.A. Carney, P.A. Godley, et al., Management of the clinically inapparent adrenal mass ("incidentaloma"), *Ann. Intern. Med.* 138 (2003) 424–429.
- [10] R.D. Schulick, M.F. Brennan, Long-term survival after complete resection and repeat resection in patients with adrenocortical carcinoma, *Ann. Surg. Oncol.* 6 (1999) 719–726.
- [11] H.R. Haak, J. Hermans, C.J. van de Velde, E.G. Lentjes, B.M. Goslings, G.J. Fleuren, et al., Optimal treatment of adrenocortical carcinoma with mitotane: results in a consecutive series of 96 patients, *Br. J. Cancer* 69 (1994) 947–951.
- [12] R.F. Pommier, M.F. Brennan, An eleven-year experience with adrenocortical carcinoma, *Surgery* 112 (1992) 963–970, discussion 70–71.
- [13] A. Stojadinovic, R.A. Ghossein, A. Hoos, A. Nissan, D. Marshall, M. Dudas, et al., Adrenocortical carcinoma: clinical, morphologic, and molecular characterization, *J. Clin. Oncol.* 20 (2002) 941–950.
- [14] P. Icard, P. Goudet, C. Charpenay, B. Andreassian, B. Carnaille, Y. Chapuis, et al., Adrenocortical carcinomas: surgical trends and results of a 253-patient series from the French association of endocrine surgeons study group, *World J. Surg.* 25 (2001) 891–897.
- [15] G. Assié, G. Antoni, F. Tissier, B. Caillou, G. Abiven, C. Gicquel, et al., Prognostic parameters of metastatic adrenocortical carcinoma, *J. Clin. Endocrinol. Metab.* 92 (2007) 148–154.
- [16] I. Veytsman, L. Nieman, T. Fojo, Management of endocrine manifestations and the use of mitotane as a chemotherapeutic agent for adrenocortical carcinoma, *J. Clin. Oncol.* 27 (2009) 4619–4629.
- [17] E.G. Grubbs, G.G. Callender, Y. Xing, N.D. Perrier, D.B. Evans, A.T. Phan, et al., Recurrence of adrenal cortical carcinoma following resection: surgery alone can achieve results equal to surgery plus mitotane, *Ann. Surg. Oncol.* 17 (2010) 263–270.
- [18] B. Polat, M. Fassnacht, L. Pfreundner, M. Guckenberger, K. Bratengeier, S. Johanssen, et al., Radiotherapy in adrenocortical carcinoma, *Cancer* 115 (2009) 2816–2823.
- [19] I. Erdogan, T. Deutschbein, C. Jurowich, M. Kroiss, C. Ronchi, M. Quinkler, et al., The role of surgery in the management of recurrent adrenocortical carcinoma, *J. Clin. Endocrinol. Metab.* 98 (2013) 181–191.
- [20] S. Gaujoux, H. Al-Ahmadie, P.J. Allen, M. Gonen, J. Shia, M. D'Angelica, et al., Resection of adrenocortical carcinoma liver metastasis: is it justified? *Ann. Surg. Oncol.* 19 (2012) 2643–2651.

Open Access

This article is published Open Access at sciedirect.com. It is distributed under the [IJSCR Supplemental terms and conditions](#), which permits unrestricted non commercial use, distribution, and reproduction in any medium, provided the original authors and source are credited.