

# Right hepatic arterial pseudoaneurysm with hemobilia following minilaparotomy cholecystectomy: A rare complication

Jun-Jing Zhang,<sup>a</sup> Chao-Xuan Dong,<sup>bc</sup> Xing-Kai Meng,<sup>a</sup> Li-Hong Ge,<sup>d</sup> Zi-Dong Zhang,<sup>e</sup> De-Fang Zhao<sup>a</sup>

From the <sup>a</sup>Department of Surgery, The Affiliated Hospital of Inner Mongolia Medical College, Hohhot, China, <sup>b</sup>Department of Pediatrics, University of Tennessee Health Science Center, Memphis, Tennessee, USA; <sup>c</sup>Department of Neurobiology and Developmental Science, University of Arkansas for Medical Sciences, Little Rock, Arkansas, USA, Departments of <sup>d</sup>Magnetic Resonance Imaging, and <sup>e</sup>Interventional Radiology, The Affiliated Hospital of Inner Mongolia Medical College, Hohhot, China

Correspondence: Dr. Jun-Jing Zhang · Department of Surgery, The Affiliated Hospital of Inner Mongolia Medical College, Hohhot 010 050, China · T: +86-0471-3955060 · zhangxiaofei1998@yahoo.com.cn · Accepted: October 2010

Ann Saudi Med 2011; 31(6): 641-643

DOI: 10.4103/0256-4947.87103

Hepatic arterial pseudoaneurysm with hemobilia occurs less frequently as a complication of minilaparotomy cholecystectomy than laparoscopic cholecystectomy; however, given its severe nature, it needs to be managed promptly. This report presents a case of right hepatic artery pseudoaneurysm with hemobilia in a 36-year-old woman who underwent minilaparotomy cholecystectomy 5 weeks earlier. Angiography with embolization was carried out as definitive treatment.

**M**inilaparotomy cholecystectomy (MC) is a viable alternative to laparoscopic cholecystectomy (LC), especially in patients who cannot tolerate laparoscopic procedures and in areas where cost containment is critical.<sup>1,2</sup> Most published research has focused on the higher risk of vascular and biliary injuries in LC. However, surgeons are likely to ignore the potential of severe vascular complications resulting from MC.

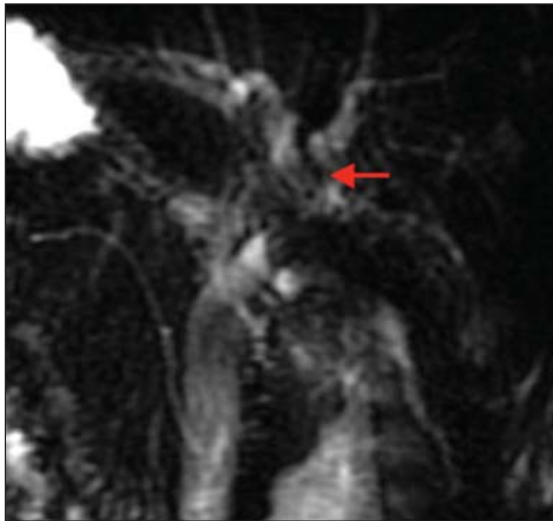
In this report, we present an unusual, life-threatening case of MC complicated by hepatic artery pseudoaneurysm (HAP) and hemobilia. This uncommon combination of anomalies has been only reported rarely. The primary objective of this case report is to increase awareness regarding pseudoaneurysm of the hepatic artery secondary to MC, which presents as near fatal hemobilia.

## CASE

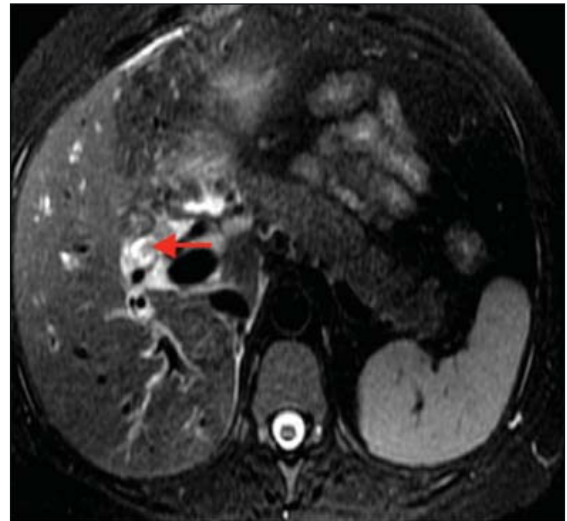
A 36-year-old woman complained of intermittent abdominal pain in the upper right quadrant of 7 days duration. The pain was associated with hematemesis and jaundice. The patient also reported weakness, light-headedness, and syncope. On examination, her vital signs showed a temperature of 37°C, blood pressure of 90/60 mm Hg, respiratory rate of 18 breaths/minute, and oxygen saturation of 98% in room air. Laboratory

tests revealed a hemoglobin level of 10.0 g/dL, hematocrit of 32.4%, total bilirubin of 32.0 μmol/L (normal: 3-20 μmol/L), direct bilirubin of 21.0 μmol/L (normal: 0-6.8 μmol/L), gamma-glutamyl transferase of 1125 U/L (normal: 5-36 U/L), aspartate aminotransferase of 126.8 U/L (normal: <37 U/L), and alanine aminotransferase of 333.9 U/L (normal: <35 U/L). She had undergone MC for a gallstone 5 weeks earlier and reported no history of iatrogenic or other liver injury. Because she had recurrent symptoms of a microlithiasis before MC, a magnetic resonance cholangio-pancreatography (MRCP) was performed to exclude choledocholith and anomalies of the biliary system.<sup>2</sup> Preoperative MRCP revealed a normal biliary tree structure.

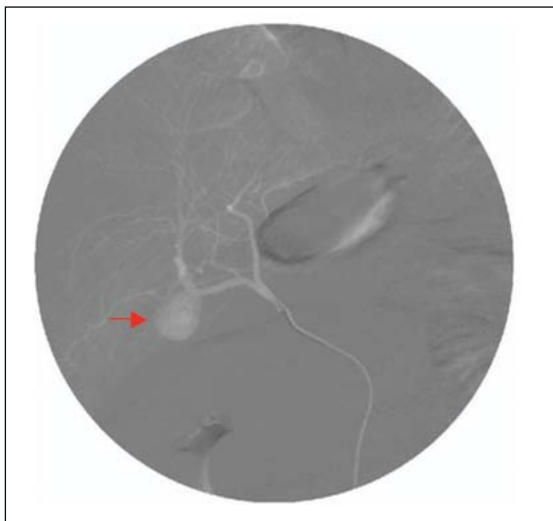
Two days after admission, an axial MR image revealed hemorrhagic fluid in the gallbladder fossa and the subcapsular portion of the liver and an abnormal extrahepatic bile duct (**Figures 1 and 2**). An upper endoscopy revealed gastritis and blood clots at the papilla of Vater. Abdominal ultrasound revealed only fluid collection in the gallbladder fossa. Five days after admission, she developed mild epigastric pain and significant hematemesis again. The epigastric pain worsened with radiation to the right upper shoulder. In addition, hematemesis led to hemodynamic instability. After resuscitation, the patient was transferred



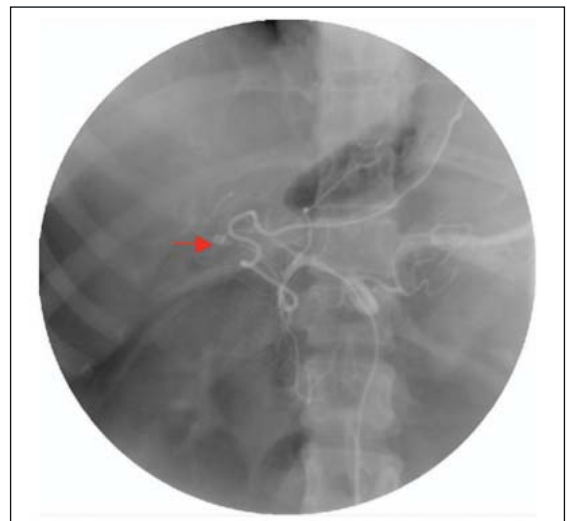
**Figure 1.** On MRCP images, the hypointense region can be seen in the hepatic duct (red arrow).



**Figure 2.** Axial T2-weighted images show a hypo-intense region in right hepatic duct (red arrow).



**Figure 3.** Selective hepatic angiogram demonstrating a pseudoaneurysm at the right hepatic artery (red arrow).



**Figure 4.** Post-embolization film showing effective obliteration of the pseudoaneurysm (red arrow).

to the Department of Interventional Radiology (The Affiliated Hospital of Inner Mongolia Medical College, Hohhot, China). Emergency angiography confirmed the formation of right HAP with active bleeding. Coil embolization was immediately performed on her to control bleeding (Figures 3 and 4). Prior to the procedure, the patient received 6 U of packed red blood cells. After hepatic artery coil embolization, the patient recovered well and was discharged without evidence of bleeding. At the 10-month follow-up, she showed satisfactory recovery, with normal liver function test results.

## DISCUSSION

HAP with hemobilia is a rare but serious complication associated with cholecystectomy. Most reported arterial complications following cholecystectomy are caused by LC, which has been thought to have a higher risk of biliary and vascular injuries compared with the open procedure.<sup>3,5</sup> Few HAP complications, which present as hemobilia, appear after MC. The pathogenesis of HAP after cholecystectomy is unclear. Direct vascular injury, erosion due to clip encroachment, and thermal injury are likely to be precipitating factors.<sup>3,5</sup> Bile leakage and secondary infection have also been reported

as potentially important factors.<sup>6</sup> According to clinical features, the likely cause in this patient was direct vascular injury followed by arterial pseudoaneurysm with hemobilia.

Typically, the clinical manifestation of HAP with hemobilia includes abdominal pain, jaundice, and gastrointestinal bleeding, but the classical triad described by Quincke in 1871<sup>7</sup> presents in only 32% of this type of patient.<sup>8</sup> Definitive diagnosis of HAP with hemobilia requires either endoscopy or radiological imaging. In patients presenting with gastrointestinal bleeding, endoscopy is frequently performed. This may localize the source of bleeding to the upper gastrointestinal tract, biliary tree, or sphincter of Oddi. Ultrasound

and spiral computed tomography may also detect an aneurysm or fluid consistent with hemorrhage, but their diagnostic quality is operator dependent.<sup>9</sup> MRCP helps identify the structure of the biliary tree, as observed in our reported case. If an aneurysm is suspected (based on examination results) or if the situation progressively worsens, trans-arterial angiography with embolization is considered the first line of intervention to diagnose and control bleeding. In conclusion, one must be aware of the possibility of the life-threatening vascular complication resulting from MC. Multidisciplinary cooperation helps diagnose and manage the rare complication of HAP with hemobilia.

## REFERENCES

1. Purkayastha S, Tilney HS, Georgiou P, Athanasiou T, Tekkis PP, Darzi AW. Laparoscopic cholecystectomy versus mini-laparotomy cholecystectomy: A meta-analysis of randomised control trials. *Surg Endosc* 2007;21:1294-300.
2. Jun-Jing Z, De-Xi L, Xing-Kai M, Xiang Cheng W, Gen-Quan Y. Application of MRCP combined with MRI source Images to the management of patients with relative Indication of common bile duct exploration. *Chin Gen Pract* 2008;11:2171-2.
3. Yao CA, Arnell TD. Hepatic artery pseudoaneurysm following laparoscopic cholecystectomy. *Am J Surg* 2010;199:e10-1.
4. Beuran M, Chiotoroiu AL, Avram M, Vartic M, Constantinescu G, Dorobăț B, et al. [Management for pseudoaneurysm of cystic artery with an arterio-biliary fistula after laparoscopic cholecystectomy: A rare case of hemobilia]. *Chirurgia (Bucur)* 2008;103:689-94.
5. De Molla Neto OL, Ribeiro MA, Saad WA. Pseudoaneurysm of cystic artery after laparoscopic cholecystectomy. *HPB (Oxford)* 2006;8:318-9.
6. Madanur MA, Battula N, Sethi H, Deshpande R, Heaton N, Rela M. Pseudoaneurysm following laparoscopic cholecystectomy. *Hepatobiliary Pancreat Dis Int* 2007;16:294-8.
7. Merrell SW, Schneider PD. Hemobilia--evolution of current diagnosis and treatment. *West J Med* 1991;155:621-5.
8. Siablis D, Tepetes K, Vasiou K, Karnabatidis D, Perifanos S, Tzorakoleftherakis E. Hepatic artery pseudoaneurysm following laparoscopic cholecystectomy: transcatheter intraarterial embolization. *Hepatogastroenterology* 1996;43:1343-6.
9. Sibulesky L, Ridlen M, Pricolo VE. Hemobilia due to cystic artery pseudoaneurysm. *Am J Surg* 2006;191:797-8.