

# Retinal Arteriole Pulse Waveform Analysis Using a Fully-Automated Doppler Optical Coherence Tomography Flowmeter: a Pilot Study

Jun Sakai<sup>1,\*</sup>, Kana J. Minamide<sup>1,\*</sup>, Syunsuke Nakamura<sup>1</sup>, Young-Seok Song<sup>2</sup>, Tomofumi Tani<sup>2</sup>, Akitoshi Yoshida<sup>2</sup>, and Masahiro Akiba<sup>1</sup>

<sup>1</sup> Research and Development Division, Topcon Corporation, Tokyo, Japan

<sup>2</sup> Department of Ophthalmology, Asahikawa Medical University, Asahikawa, Hokkaido, Japan

**Correspondence:** Masahiro Akiba, Topcon Corporation, R&D Division, 75-1 Hasunuma-cho, Itabashi-ku, Tokyo, 174-8580, Japan. e-mail: m-akiba@topcon.co.jp

**Received:** 9 November 2018

**Accepted:** 5 February 2019

**Published:** 6 May 2019

**Keywords:** optical coherence tomography; blood flow; pulse waveform; retinal artery; Doppler OCT

**Citation:** Sakai J, Minamide KJ, Nakamura S, Song Y-S, Tani T, Yoshida A, Akiba M. Retinal arteriole pulse waveform analysis using a fully-automated Doppler optical coherence tomography flowmeter: a pilot study. *Trans Vis Sci Tech.* 2019; 8(3):13, <https://doi.org/10.1167/tvst.8.3.13>

Copyright 2019 The Authors

**Purpose:** To evaluate the repeatability and reproducibility of the measurement of retinal arteriole pulse waveforms using a novel fully-automated Doppler optical coherence tomography (DOCT) flowmeter in healthy subjects.

**Methods:** Twenty eyes of 20 healthy subjects were included to test the intrasession repeatability of pulse waveform analysis. DOCT measurements were performed based on a newly developed instantaneous Doppler angle measurement method. Upstroke time (UT), which is the time from the minimum to the maximum retinal blood velocity, and the resistance index (RI) of the retinal arteriole pulse waveform were measured. Coefficients of variation (CVs) and intraclass correlation coefficients (ICCs) were calculated. Interdevice reproducibility between two instruments was assessed in five eyes of five subjects.

**Results:** The mean UT was 130.3 ms (range, 110.1–152.1 ms), and the mean RI was 0.66 (range, 0.51–0.82). The respective ICCs of UT and the RI for the intrasession repeatability of assessment were 0.87 and 0.78. The respective CVs of UT and the RI were  $6.6 \pm 3.3\%$  and  $4.7 \pm 2.1\%$ . Regarding interdevice reproducibility, there were no significant differences between the measurements derived from the instruments ( $P > 0.05$ ).

**Conclusions:** Pulse waveform measurement in retinal arterioles using a fully-automated DOCT flowmeter exhibited good repeatability and interdevice reproducibility.

**Translational Relevance:** The above-described improved DOCT flowmeter system provides reasonably repeatable measurements of retinal arteriole pulse waveforms, potentially facilitating systemic-circulation abnormality monitoring. The examination of the circulation with the novel device can be potentially useful for evaluating systemic circulation.

## Introduction

Blood flow dynamics in retinal arterioles may yield important physiological information pertaining to cardiovascular and cerebrovascular conditions.<sup>1,2</sup> Previous studies using laser Doppler velocimetry (LDV) have shown abnormality of retinal blood flow at the early stage of systemic diseases, such as cardiovascular disease,<sup>3</sup> diabetes,<sup>4</sup> and Alzheimer's disease.<sup>5</sup> Thus, monitoring retinal blood flow could be

useful for screening or monitoring of the whole body's condition. However, LDV requires operator skill, and it may not be readily applied to routine screening.

Doppler optical coherence tomography (DOCT) is a velocimetry modality that uses OCT technology and has recently been investigated in the context of extraction of ocular circulation parameters.<sup>6–8</sup> It utilizes the Doppler shift of reflected light, which provides information on blood flow volume and velocity in individual arterioles and venules. We

previously developed a fully automated DOCT system and demonstrated repeatable measurement of the absolute flow volume and velocity.<sup>9–11</sup> As is commonly reported, the determination of Doppler angle is sensitive with regard to the detection of blood flow speed.<sup>9</sup> In a previously used method, the Doppler angle was measured in advance, and this fixed Doppler angle was used for velocity measurements.<sup>10</sup> This can be applied if no obvious eye movement is observed during at least one cardiac cycle measurement. However, due to the nature of physiological eye movement, the method does not yield accurate and repeatable velocity measurements, especially in diseased eyes with poor fixation.<sup>12</sup> Moreover, although the arterial pulse waveform provides important information regarding systemic blood flow dynamics, little is known regarding the retinal arteriole pulse waveform.

In this paper, we report on an improved Doppler OCT measurement procedure and its ability to stably capture the pulse wave of retinal vessels. To achieve constant clear DOCT signal of blood flow with pulsation, we developed an instantaneous Doppler angle estimation method during consecutive measurements of blood flow. The reliability of the DOCT signal as a general measurement system to acquire pulse waveforms was evaluated in a pilot study.

## Methods

### Subjects

This study included 20 eyes of 20 healthy volunteers (17 men and 3 women, mean age  $33.9 \pm 5.7$  years) with no ophthalmic disease and with mild refractive errors ( $-3.3 \pm 2.1$  diopters of spherical equivalent). All volunteers underwent a medical interview, including recording of medical history, and confirmed that they had no cardiovascular or other systemic diseases. Intraocular pressure (mean  $15.3 \pm 1.7$  mm Hg) was monitored by a noncontact-tonometer (Topcon Corporation, Tokyo, Japan). The systolic blood pressure (mean  $118.6 \pm 11.5$  mm Hg) and diastolic blood pressure (mean  $11.5 \pm 8.0$  mm Hg) were monitored with automated oscillometry (Omron, Kyoto, Japan). This study was performed at the Asahikawa Medical University (AMU), Asahikawa, Japan. The research protocols were approved by the AMU institutional review board (approved project number 17188) and conducted in accordance with the tenets of the Declaration of Helsinki. Each subject provided written informed consent before enrollment after receiving a

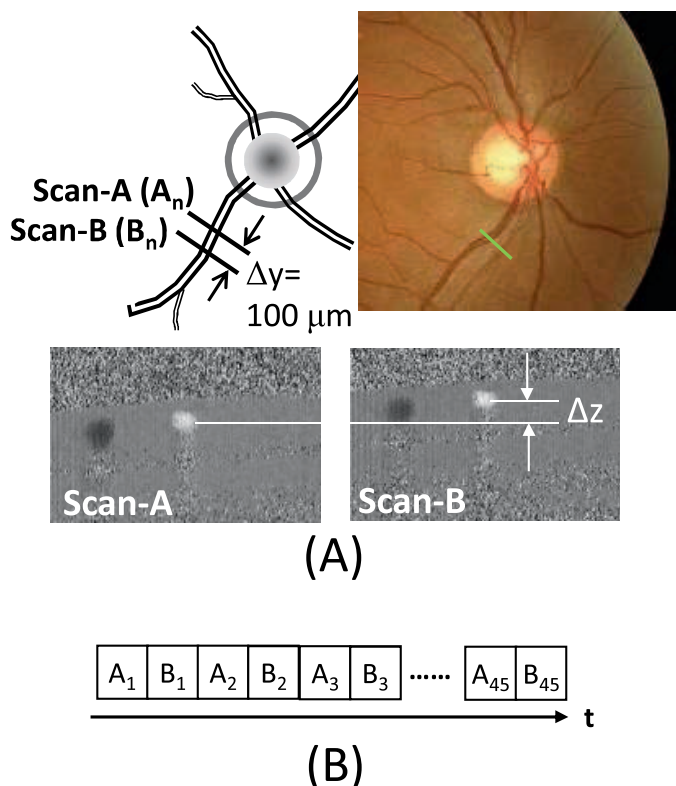
complete explanation of the study design and protocol. No pupil dilation was performed in any subject.

### Imaging Procedure and Analysis

The experimental system was a modified version of commercially available spectral domain OCT (3D OCT-1 Maestro, Topcon Corporation, Tokyo, Japan). This system provides OCT images and color fundus photographs in a single instrument. A fully automated “alignment, focus, optimization, and capture” procedure achieved via touch panel operation was implemented. The auto-alignment procedure in the optical head and signal processing routines performed in external computer were newly developed for the DOCT imaging. Up to four vessels in a single Doppler OCT image are automatically detected and analyzed. The basic DOCT measurement protocol used has been described previously.<sup>10</sup> Before DOCT measurement, a color fundus image centered at the optic disc was captured; then, a region of interest of the retinal vessel, which is typically one-disc diameter away from the optic disc center, was manually selected. The scan location was set such that it was almost perpendicular to the target blood vessel. The transverse scan length utilized in this study was 0.9 mm, with 1024 A-lines. The measurement time of the current retinal arteriole pulse waveform is set to 2 seconds since the normal heart-rate range is 60 to 100 beats per minute.<sup>13</sup> To compensate for ambiguity in the starting position of the blood flow measurement, at least one cardiac cycle should be recorded. In the current study, pupil location and size were monitored in real time to determine the off-axis incident location at the appropriate position. Since two cameras used to monitor the anterior segment for stereo matching were integrated in the instrument, we utilized these images to precisely determine the amount of off-axis alignment. The incident beam was automatically shifted toward the edge of the pupil along with the vessel in order to achieve the maximum Doppler signal. The moving direction of the incident beam was judged by tilting of the target vessel.

### Instantaneous Doppler Angle Measurement Method

To minimize the effects of physiological eye movement, instead of the conventional step-by-step Doppler angle estimation procedure, two alternative parallel OCT scans (A and B) with beam separation  $\Delta y = 100 \mu\text{m}$  were performed, as shown in Figure 1. In this time, 90 frames (45 frames for each location) were



**Figure 1.** Schematic diagram of real-time Doppler angle measurement. (A) The two alternative scan positions set as scans A and B, which are located around one-disc diameter away from the optic disc center of the inferior-temporal vessel. The scan separation distance,  $\Delta y$ , was determined to be  $100 \mu\text{m}$ . Two example phase images showing the identification of vessels separated in  $\Delta z$ . (B) Forty-five repeated alternate scans for both pulse waveform measurement and Doppler angle  $\theta$  calculation.

acquired in total. To increase the signal-to-noise ratio, every nine images in scans A and B were registered and averaged. The vessel center was calculated in an averaged image. Since the blood vessel can be treated as a straight line in a small segment, the Doppler angle was calculated with triangular calculation using values  $\Delta y$  and  $\Delta z$  derived from different scans (A and B), where  $\Delta z$  is the depth difference of center of the vessels.<sup>9</sup> Five individual Doppler angles over a 2-second imaging period were calculated. The least squares method was applied to interpolate over the 2-second measurement cycle. Thus, this instantaneous Doppler angle set  $\theta_m$  ( $m = 1, \dots, 90$ ) was applied to extract the velocity profile. Velocity was calculated with the following well-known equation.

$$v_m = \frac{\lambda_0 \Delta \phi}{4\pi n \tau} \cdot \frac{1}{\cos \theta_m},$$

where,  $\lambda_0$  is the center wavelength,  $\Delta \phi$  is phase

differences,  $\tau$  is the time interval between the adjacent A-lines, and  $n$  is the refractive index of blood. The retinal arteriole pulse waveform over a 2-second period was extracted to take an average of the velocity in scans A and B.

## Glass Capillary Bench Test

To demonstrate this instantaneous Doppler angle measurement method, a bench test system that used glass capillaries through which turbid media (a 23% nonfat powdered milk solution) flowed at a constant speed was conducted. Glass capillaries with respective inner and outer diameters of  $130$  and  $500 \mu\text{m}$  were used, and a syringe pump (AS ONE, Osaka, Japan; model number: MSP-1D) was employed to create constant flow within the glass capillary. In these experiments, the Doppler angle was constantly changed by tilting the glass capillaries during the 2-second imaging period.

## Data Verification

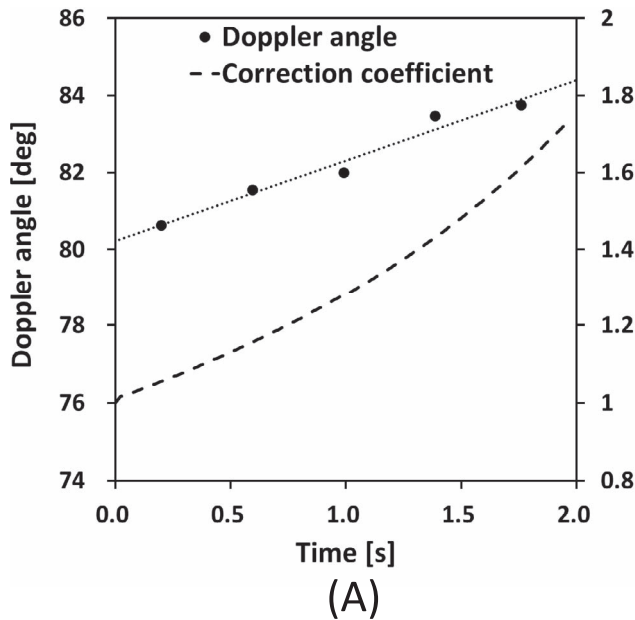
All datasets collected were perused by an ophthalmologist to ensure that no extra eye movement or mis-registration was contained in the series of OCT images. As part of the procedure, the diameter was calculated using the inner vessel from phase images. For blood pulse wave information, the phase information inside the recognized vessel was summed.

## Upstroke Time (UT) and Resistance Index (RI)

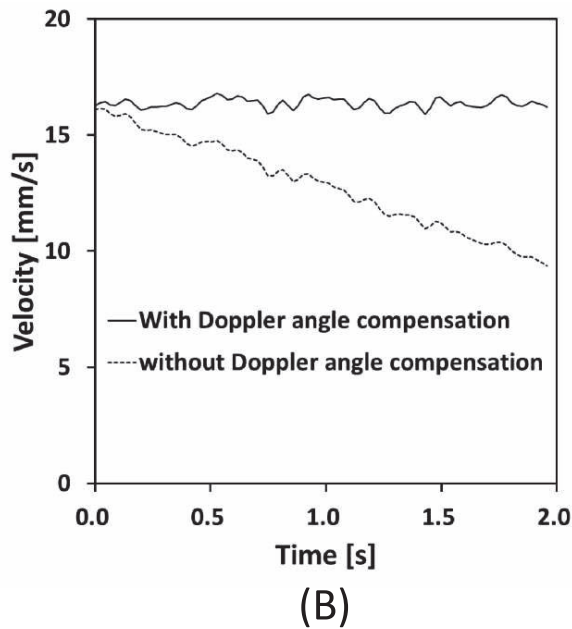
A single cardiac cycle was automatically extracted from a 2-second pulsation curve; UT, the time from the minimum ( $v_{min}$ ) to the maximum ( $v_{max}$ ) retinal blood velocity, was calculated from the systolic and diastolic periods, where  $v_{max}$  and  $v_{min}$  were identified via the pulse waveform.<sup>3</sup> The temporal moving average for three points was used to determine  $v_{max}$  and  $v_{min}$ . UT extension indicates upstream stenosis or embolism.<sup>14,15</sup> RI was calculated using the following equation<sup>16</sup>:  $(v_{max} - v_{min})/v_{max}$ . The RI represents the compliance and resistance of peripheral vessels.

## Repeatability and Reproducibility

To evaluate intrasession repeatability, data from all 20 eyes of all 20 subjects were analyzed. One operator performed the DOCT flowmeter measurements for each subject. The pulse waveform measurements of the arterioles in either the superior-temporal or inferior-temporal sites were repeated three times using the follow-up mode in the software. The coefficients of variation (CVs) and intraclass correla-



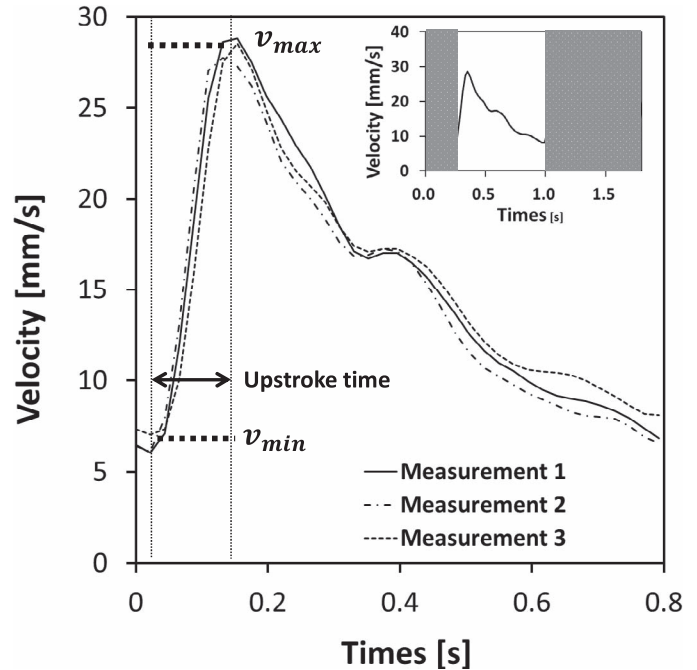
(A)



(B)

**Figure 2.** Bench test result of the real-time Doppler angle measurement method. (A) Measured Doppler angle (dots) and linear regression line (dotted line) in left axis and correction coefficient (broken line) measured over a 2-s period in right axis. (B) Calculated velocity over a 2-s period with and without Doppler angle compensation.

tion coefficients (ICCs) for UT and the RI were determined. To evaluate interdevice session reproducibility of the two DOCT flowmeters (instruments A and B), data from all five eyes of all five subjects were analyzed. The mean differences in UT and the RI between the instruments were assessed.



**Figure 3.** Three repeated measurement results of the retinal arteriole pulse waveform.  $v_{max}$ ,  $v_{min}$ , and UT were determined from the one pulse waveform extracted from Doppler OCT measurement.

## Results

### Instantaneous Doppler Shift Bench Test System

Figure 2 shows the bench test experimental results of the instantaneous Doppler shift measurement. Since the tilting angle was intentionally increased over time, the calculated Doppler angle also increased from  $80^\circ$  to  $85^\circ$  as shown in Figure 2A. Linear regression showed the continuous increase in the Doppler angle as a dotted line. The broken line in Figure 2A showed the compensation coefficient (right axis) that was calculated by applying  $1/\cos \theta$ . Figure 2B shows the velocity value in mm/s for 2 seconds. The dotted line shows the velocity without compensation, while the solid line shows the compensated velocity over 2 seconds. Compensated velocity was measured at an almost constant speed over the 2 seconds, in this case approximately 16 mm/s. Without any eye movement such compensation was not necessary, but our method shows the potential compensation error of the Doppler angle measurement.



**Table 1.** Intrasession Repeatability of UT and the RI Measured by a DOCT Flowmeter

Measurement	Value	ICC	CV, %
UT, ms	130.3 ± 8.8	0.87	6.6 ± 3.3
RI	0.66 ± 0.03	0.78	4.7 ± 2.1

### Repeatability of Pulse Waveform Measurement

Data from all 20 eyes of all 20 subjects were analyzed to test the repeatability of the pulse wave measurement using DOCT. One measurement provides approximately two peaks of the pulse wave as shown in the inset of Figure 3, and one representative pulse wave was extracted for analysis. Figure 3 is an example of a retinal arterial pulse wave obtained from three repeated measurements where  $v_{max}$ ,  $v_{min}$ , and UT were determined. In a previous study, we confirmed the repeatability and reproducibility of the absolute value of velocity.<sup>10</sup>

With regard to the pulse wave measurement, Table 1 summarizes the results of the intrasession repeatability of UT and the RI measured using the DOCT flowmeter. The mean UT was 130.3 ms (range, 110.1–152.1 ms), and the mean RI was 0.66 (range, 0.51–0.82). The respective ICCs of UT and the RI were 0.87 and 0.78, and the respective CVs were  $6.6 \pm 3.3\%$  and  $4.7 \pm 2.1\%$ .

### Interdevice Reproducibility

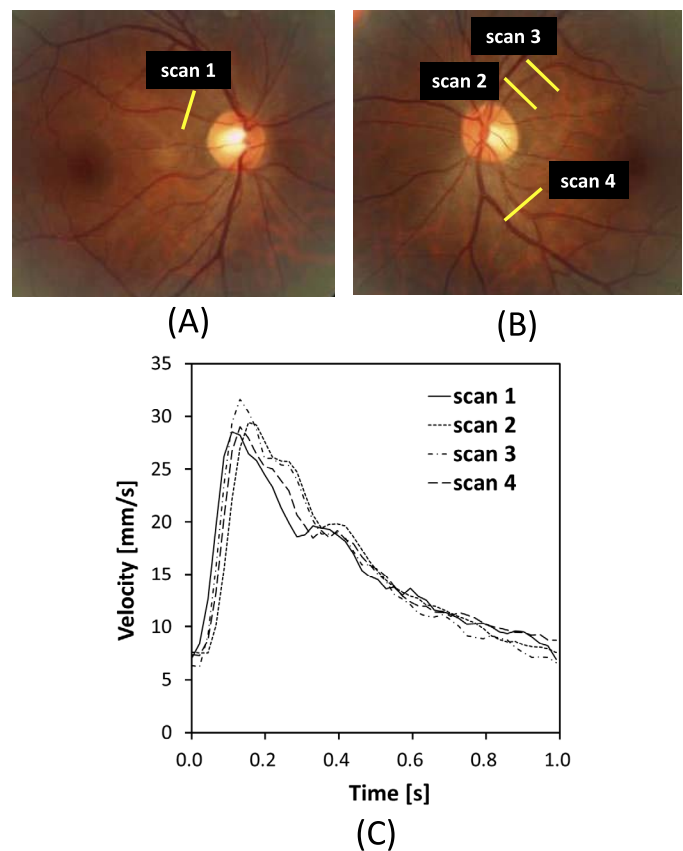
The DOCT flowmeter measurements obtained by the different devices in five subjects were compared (Table 2). In system A, the mean UT was 127.4 ms (range, 120.0–147.4 ms) and the mean RI was 0.66 (range, 0.51–0.78). In system B, the mean UT was 127.2 ms (range, 119.1–147.0 ms) and the mean RI was 0.66 (range, 0.54–0.77). The respective ICCs of UT and the RI were 0.95 and 0.90. There were no statistically significant differences in UT or the RI between the two instruments ( $P > 0.05$ ).

### Within-Subject Coidentity of Pulse Waveforms Derived From Different Scanning Positions

Figure 4 shows the representative results of the DOCT measurements at different scanning points in retinal arterioles of the same subject (Figs. 4A, 4B). The DOCT measurements were performed at the typical scanning position on the superior-temporal

**Table 2.** DOCT Flowmeter Measurements Obtained by a Different Device in Five Subjects

Subject	Instrument	UT, ms	RI
A	A	120.8 ± 3.5	0.51 ± 0.04
	B	122.9 ± 8.3	0.54 ± 0.03
B	A	125.8 ± 2.6	0.62 ± 0.03
	B	121.5 ± 4.5	0.60 ± 0.02
C	A	120.0 ± 4.9	0.72 ± 0.02
	B	119.1 ± 4.8	0.70 ± 0.01
D	A	147.4 ± 10.1	0.69 ± 0.03
	B	147.0 ± 8.3	0.71 ± 0.01
E	A	123.0 ± 2.3	0.78 ± 0.02
	B	125.7 ± 4.5	0.77 ± 0.02



**Figure 4.** Retinal arteriole pulse waveforms of different scanning positions and different vessels. (A) Color fundus image and scanning location of Doppler OCT imaging in superior-temporal (scan 1) in the right eye, (B) superior-temporal (scan 2, 3), and inferior-temporal (scan 4) arterioles in the left eye of the same subject. (C) Four measurement results of retinal arteriole pulse waveform in DOCT imaging.

arteriole (one-disc diameter away from the optic disc center; scan 1), a similar location in the fellow eye (scan 2), a more peripheral position (scan 3), and at the inferior-temporal arteriole (scan 4). As shown in Figure 4C, the pulse waveform of the retinal arteriole within the individual depicts a similar pattern, regardless of vessels or scanning position.

## Discussion

In this study, we demonstrated an improved automated method of retinal blood velocity measurement that allows for real-time follow-up of the Doppler angle between incident beam and retinal artery. We assessed the repeatability and reproducibility of parameters of retinal arteriole pulse waveform. ICCs of UT and RI were 0.87 and 0.78, respectively, which indicated the good to excellent reliability of measurement method.<sup>17</sup> We also demonstrated that the measurement would be performed regardless of individual device.

In a previous method, Doppler angle was measured in advance before the flow measurement. Then, this fixed calculated Doppler angle was employed for all frames to calculate the retinal flow speed. Since Doppler angle measurement is sensitive to eye motion that adversely affects the accuracy of the blood flow measurement, fluctuation of eye motion, especially when the Doppler angle is close to 90°, influences the accuracy of the flow.

To overcome this drawback, LDV was employed to detect Doppler shifts using two photomultipliers at different angles without explicit extraction of blood vessel angles. Similarly, the OCT method detects Doppler shifts in two different directions using two or three spectrometers without a priori knowledge of the Doppler angle, but this requires hardware modifications, which is more difficult to implement with standard commercial OCT.<sup>18,19</sup> Meanwhile, the volumetric approach that measures the flow at a fixed angle of 0°, that is, in a plane perpendicular to the optical beam presented by Baumann et al.,<sup>20</sup> does not require measurement of the vessel angle. However, a very high-speed imaging system is mandatory to achieve this measurement.<sup>20</sup> The proposed method enables capturing of the flow information without modifying the hardware (Maestro). The Doppler angle measurement method was successfully implemented which enabled calculation of the Doppler angle in each frame by interpolating a 2-second measurement. As shown in Figure 2, in the bench test, intentionally changing the Doppler angle over time

was compensated by calculating the instantaneous Doppler angle.

In the current study, we measured UT and the RI using  $v_{max}$  and  $v_{min}$ , which provide information on pulse waveform propagation via vascular resistance. UT and the RI are also common parameters in other noninvasive methods such as plethysmography and ultrasonography. We confirmed that both UT and the RI were within the range of healthy subjects measured by carotid ultrasonography.<sup>21,22</sup> Preliminarily, we also calculated the pulse pressure amplitude from blood pressure data in a manner similar to that used for the RI calculation.<sup>23</sup> However, they were not significantly associated with the RI (data not shown). Meanwhile, it is demonstrated that the DOCT enables to extract the independent pulse waveforms of retinal arteriole blood flow. Similarly, such pulse waveform is typically observed using pulse-oximetry to monitor peripheral blood pulse waves. However, the waveform is rather blunt because pulse oximetry detects signals from both arterial and venous capillaries.<sup>24</sup> Since arterial pulse waveforms reflect the function of ejection and its propagation to an artery, pulse waveform analysis on arteries or arterioles would be important.

Our study had several limitations. First, as we focused on the repeatability and reproducibility of retinal pulse waveform obtained by DOCT, we evaluated the retinal arteriole pulse wave parameters only in healthy subjects. In a previous study using LDV, UT extension was observed in aged subjects, who may have arterial stiffening as an effect of aging.<sup>15</sup> Studies on subjects with certain cardiovascular disorders would be important to demonstrate the clinical relevance of retinal pulse waveform. Second, our study only focused on UT and the RI. In a previous study with laser speckle flowgraphy, some unique parameters by the pulse waveform analysis were introduced and the correlation with another systemic parameter was studied.<sup>25</sup> Detailed analysis of the retinal arteriole pulse waveform warrants further investigation. Finally, our current study did not include a comparison of pulse waveforms obtained by an existing clinical modality for another region such as the neck and limbs. Measurement with DOCT and pulse-oximetry or ultrasonography would be more intriguing to elucidate the relationship between pulse waveforms in a retinal arteriole and another vessel. A study comparing arterial pulse waveforms in the retina and another region would be a good hint to elucidate the general of central and peripheral of systemic circulation.

In conclusion, a fully-automated DOCT measurement procedure combined with instantaneous Doppler angle measurement exhibited good repeatability and interdevice reproducibility. Extraction of retinal arteriole pulse waveforms enhanced the potential capacity of the DOCT.

## Acknowledgments

Disclosure: **J. Sakai**, Topcon Corporation (E); **K.J. Minamide**, Topcon Corporation (E); **S. Nakamura**, Topcon Corporation (E); **Y.-S. Song**, None; **T. Tani**, None; **A. Yoshida**, Topcon Corporation (P); **M. Akiba**, Topcon Corporation (E,P)

\*Jun Sakai and Kana J. Minamide contributed equally to this article.

## References

1. Varma DD, Cugati S, Lee AW, Chen CS. A review of central retinal artery occlusion: clinical presentation and management. *Eye*. 2013;27:688–697.
2. Moss HE. Retinal vascular changes are a marker for cerebral vascular diseases. *Curr Neurol Neurosci Rep*. 2015;15:1–15.
3. Nagaoka T, Ishii Y, Takeuchi T, Takahashi A, Sato E, Yoshida A. Relationship between the parameters of retinal circulation measured by laser Doppler velocimetry and a marker of early systemic atherosclerosis. *Invest Ophthalmol Vis Sci*. 2005;46:720–725.
4. Grunwald JE, DuPont J, Riva CE. Retinal haemodynamics in patients with early diabetes mellitus. *Br J Ophthalmol*. 1996;80:327–331.
5. Fekete GT, Hymal BT, Stern RA, Pasquale LR. Retinal blood flow in mild cognitive impairment and Alzheimer's disease. *Alzheimers Dement (Amst)*. 2015;1:144–151.
6. Leitgeb RA, Schmetterer L, Drexler W, Fercher A, Zawadzki R, Bajraszewski T. Real-time assessment of retinal blood flow with ultrafast acquisition by color Doppler Fourier domain optical coherence tomography. *Opt Express*. 2003;11:3116–3121.
7. White BR, Pierce MC, Nassif N, et al. In vivo dynamic human retinal blood flow imaging using ultra-high-speed spectral domain optical Doppler tomography. *Opt Express*. 2003;11:3490.
8. Leitgeb RA, Werkmeister RM, Blatter C, Schmetterer L. Progress in retinal and eye research Doppler optical coherence tomography. *Prog Retin Eye Res*. 2014;41:26–43.
9. Nagaoka T, Tani T, Song YS, et al. Evaluation of retinal circulation using Segmental-Scanning doppler optical coherence tomography in anesthetized cats. *Invest Ophthalmol Vis Sci*. 2016;57:2936–2941.
10. Tani T, Song YS, Yoshioka T, et al. Repeatability and reproducibility of retinal blood flow measurement using a Doppler optical coherence tomography flowmeter in healthy subjects. *Invest Ophthalmol Vis Sci*. 2017;58:2891–2898.
11. Song YS, Tani T, Omae T, et al. Retinal blood flow reduction after panretinal photocoagulation in type 2 diabetes mellitus: Doppler optical coherence tomography flowmeter pilot study. *PLoS One*. 2018;13:e0207288.
12. Gonzalez EG, Tarita-Nistor L, Mandelcorn ED, Mandelcorn M, Steinbach MJ. Fixation control before and after treatment for neovascular age-related macular degeneration. *Invest Ophthalmol Vis Sci*. 2011;52:4208–4213.
13. Spodick DH. Recalibration of normal sinus heart rate: clinical think and epidemiologic support. *Clin Cardiol*. 1993;702:16.
14. Nagaoka T, Sato E, Takahashi A, Yokota H, Sogawa K, Yoshida A. Impaired retinal circulation in patients with type 2 diabetes mellitus: retinal laser Doppler velocimetry study. *Invest Ophthalmol Vis Sci*. 2010;51:6729–6734.
15. Nagaoka T, Sato E, Takahashi A, Sogawa K, Yokota H, Yoshida A. Effect of aging on retinal circulation in normotensive healthy subjects. *Exp Eye Res*. 2009;89:887–891.
16. Viazzi F, Leoncini G, Derchi LE, Pontremoli R. Ultrasound Doppler renal resistive index: a useful tool for the management of the hypertensive patient. *J Hypertens*. 2014;32:149–153.
17. Koo TK, Li MY. A guideline of selecting and reporting intraclass correlation coefficients for reliability research. *J Chiropr Med*. 2016;15:155–163.
18. Zotter S, Pircher M, Torzicky T, et al. Visualization of microvasculature by dual-beam phase-resolved Doppler optical coherence tomography. *Opt Express*. 2011;19:1217–1227.
19. Haindl R, Trasischker W, Wartak A, Baumann B, Pircher M, Hitzenberger CK. Total retinal blood flow measurement by three beam Doppler optical coherence tomography. *Biomed Opt Express*. 2016;7:287–301.
20. Baumann B, Potsaid B, Kraus MF, et al. Total retinal blood flow measurement with ultrahigh

- speed swept source/Fourier domain OCT. *Biomed Opt Express*. 2011;2:1539–1552.
21. Tomiyama H, Yamashita A. Non-invasive vascular function tests: their pathophysiological background and clinical application. *Circ J*. 2010;74:24–33.
  22. Lee MY, Wu CM, Yu KH, et al. Association between wall shear stress and carotid atherosclerosis in patients with never treated essential hypertension. *Am J Hypertens*. 2009;22:705–710.
  23. Lee MK, Hsu PC, Chu CY, et al. Significant correlation between brachial pulse pressure index and renal resistive index. *Acta Cardiol Sin*. 2015; 31:98–105.
  24. Chan ED, Chan MM, Chan MM. Pulse oximetry: understanding its basic principles facilitates appreciation of its limitations. *Respir Med*. 2013; 107:789–799.
  25. Luft N, Wozniak PA, Aschinger GC, et al. Ocular blood flow measurements in healthy white subjects using laser speckle flowgraphy. *PLoS One*. 2016;11:e0168190.