

## CASE REPORT

# Incidental detection of retained oil-based hysterosalpingography contrast medium on postoperative postpartum radiography: A case report

Harue Hayashida  | Kiichiro Furuya | Hiroki Kurahashi | Saya Yamashita | Yangsil Chang | Hiroaki Tsubouchi | Kayoko Shikado | Kazuhide Ogita

Department of Obstetrics and Gynaecology, Rinku General Medical Centre, Osaka, Japan

**Correspondence**

Kiichiro Furuya, Department of Obstetrics and Gynaecology, Rinku General Medical Centre, Osaka, Japan.  
Email: [kiishin529@yahoo.co.jp](mailto:kiishin529@yahoo.co.jp)

**Funding information**

Osaka Medical Association

**Abstract**

Hysterosalpingography is widely performed in assisted reproductive technology. We present a rare case of contrast medium retention which was incidentally found and mimicked a retained surgical instrument. A medical history of treatment for infertility can facilitate the differential diagnosis of abnormal findings on post-caesarean section radiography.

**KEYWORDS**

case report, contrast medium retention, hysterosalpingography, postpartum

## 1 | INTRODUCTION

Hysterosalpingography (HSG) is widely used as an investigative tool in assisted reproductive technology (ART).<sup>1</sup> It is usually performed using a water- or oil-based iodine contrast medium.<sup>2</sup> While most facilities have chosen the water-soluble contrast medium because of the disadvantages of the oil-based contrast medium including its possible effect on fetus and long-term residue in the body, some facilities still use the oil-based contrast medium due to some reports describing higher pregnancy rates after performing HSG using this medium.<sup>3</sup> However, since abdominal radiography is rarely performed during the perinatal period, there has been few reports on the prevalence of contrast medium retention in this period. Herein, we report a rare case of HSG contrast medium retention that was incidentally found on abdominal radiography after caesarean section and

needed to be differentiated from a retained surgical instrument; we also reviewed the literature.

## 2 | CASE HISTORY

A 34-year-old Japanese primiparous woman who had a twin pregnancy by in vitro fertilization-embryo transfer (IVF-ET) and a history of receiving medical treatment for deep infiltrating endometriosis (DIE) was referred to our hospital for a prenatal check-up. At 32 weeks and 4 days of gestation, she was admitted to the hospital due to preterm premature rupture of membrane and received tocolytics and steroids. At 33 weeks of gestation, fever (38.0°C) and elevated inflammatory responses (white blood cells  $\geq 15\,000/\mu\text{l}$ ; C-reactive protein, 0.53 mg/dl) were observed, and chorioamnionitis (CAM) was eventually diagnosed. The patient also had an elevated blood

Harue Hayashida and Kiichiro Furuya contributed equally as the joint first authors in this case report.

This is an open access article under the terms of the [Creative Commons Attribution-NonCommercial-NoDerivs](https://creativecommons.org/licenses/by-nc-nd/4.0/) License, which permits use and distribution in any medium, provided the original work is properly cited, the use is non-commercial and no modifications or adaptations are made.

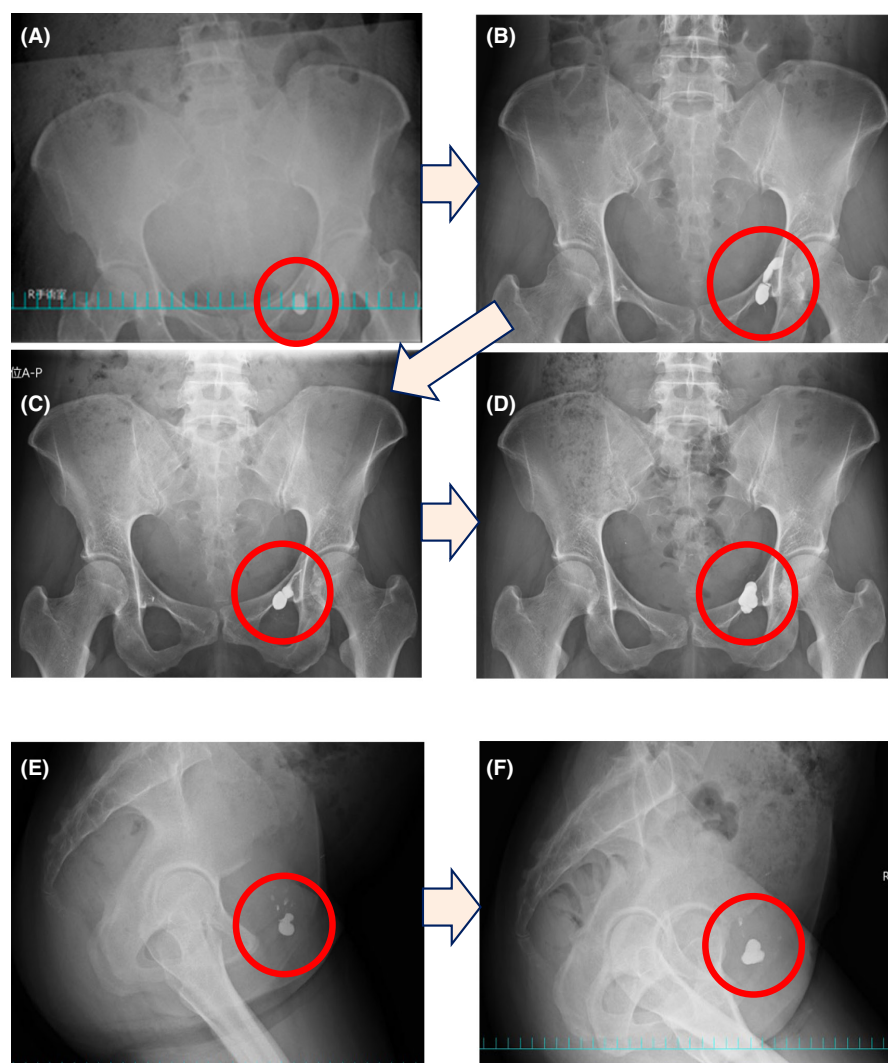
© 2022 The Authors. *Clinical Case Reports* published by John Wiley & Sons Ltd.

pressure (systolic blood pressure: 140 mm Hg), proteinuria (protein/creatinine ratio, 0.418), and pulmonary oedema (revealed on chest radiography) and was diagnosed with severe hypertensive nephropathy. Based on these findings and due to worsening preeclampsia, an emergency caesarean section was performed. No adhesions were observed in the abdominal cavity intraoperatively, and no abdominal bleeding or retained surgical instruments were found. The operative equipment used were carefully counted before abdominal wall closure, and the number tallied with that obtained preoperatively, indicating that no surgical instrument was left behind. However, during abdominal wall closure, maternal respiratory function suddenly deteriorated due to severe pulmonary oedema, and respiratory support with intubation was immediately administered. Immediately after surgery, pelvic radiography was performed to further confirm that no surgical instrument had been left behind. The radiographs showed a high-density lesion in the left lower pelvis (Figure 1A). Initially, we considered it a retained surgical instrument. Therefore, the used operative

equipment and materials were carefully counted again. They were noted to be complete and equal to the number obtained during the preoperative period, indicating that the abnormal finding was not a retained surgical instrument. Subsequently, vascular calcification and/or urinary tract stone were also considered as differential diagnosis. However, because of the severe deterioration of the patient's respiratory condition, we suspended the investigation and prioritized intensive care. In this situation, we could not afford the time required to identify the abnormal lesion in the pelvis.

After admission into the intensive care unit, her condition improved rapidly, resulting in extubation on postoperative day (POD) 2. The patient was then transferred to the general obstetrics ward, and the investigation of the abnormal material in the pelvis was recommenced.

Subsequent follow-up pelvic imaging (Figure 1B,C,E) revealed that the shape and localization of the abnormal lesion had gradually changed, suggesting that it was a liquid component. Since the patient had conceived by IVF-ET, we suspected the lesion could be a remnant

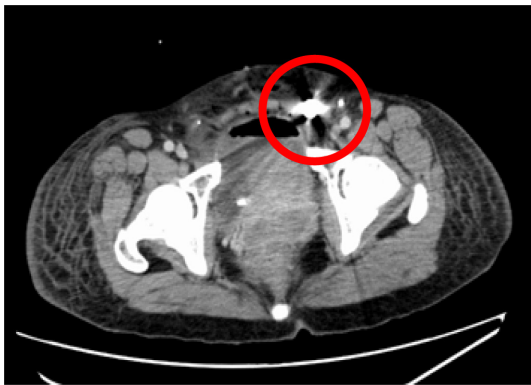

**FIGURE 1** Postoperative radiography performed on the pelvis (anteroposterior and lateral views) immediately after caesarean section (A), on POD 4 (B), POD 8 (C and E), and POD 30 (D and F). The shape and localization of the lesion shows gradual changes, suggesting that it is a liquid component, and thereby indicating the possibility of a retained contrast medium. POD, postoperative day

of the HSG contrast medium used. With the patient's consent, we obtained her clinical information from the previous fertility clinic and found that HSG had been performed using Lipiodol, 10 months before delivery. The results of the HSG had revealed no abnormal findings.

Subsequently, computed tomography (CT) and magnetic resonance imaging (MRI) were performed to identify and localize the abnormal lesion (Figures 2 and 3). CT showed a hyperdense lesion (Figure 2) located in the left lower pelvic cavity (the same position as that in the previous pelvic radiograph).

Only after using a metal detector to confirm that no metal components were present in pelvis, we performed MRI on POD 10 (Figure 3). The lesion was hyperintense on T1- and T2-weighted images and hypointense on fat suppression imaging, strongly indicating the possibility of a retained HSG contrast medium. The patient's postoperative course was uneventful, and she was discharged on POD 15. No complications occurred after hospital discharge, and we continued to perform pelvic radiography monthly to evaluate the details and shape of the contrast medium residue. However, due to the distance from her residence to our hospital, the patient requested



**FIGURE 2** Postoperative computed tomography image at the time of caesarean section showing the details and location of the abnormal shadows in the pelvis which have the same density as metals

to discontinue close follow-up. Therefore, we suspended monthly follow-up and continued conservative and observational follow-up where we asked about symptoms such as abdominal pain and/or fever. Currently, no symptom has been reported by the patient.

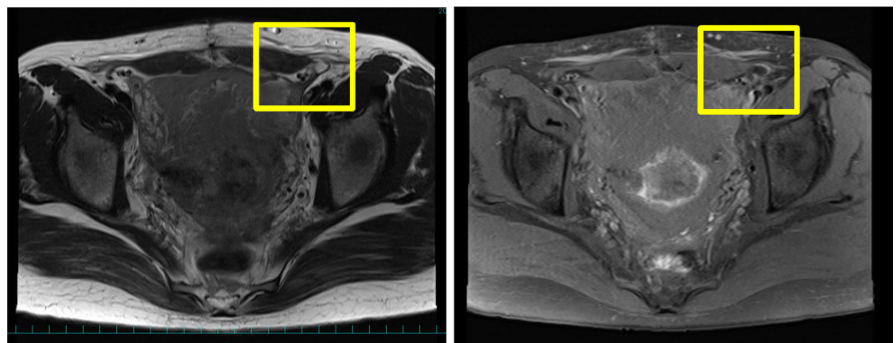
### 3 | DISCUSSION

We encountered a rare case in which a remnant of HSG contrast medium was incidentally found on routine postoperative abdominal radiography and had to be differentiated from a retained surgical instrument. This case highlighted two clinically important points: (1) an HSG contrast medium used in the pre-conception period could persist until the perinatal period, and (2) a history of ART with HSG can facilitate the diagnosis of an HSG contrast medium residue.

#### 3.1 | HSG contrast medium used in the preconception period can persist until the postpartum period

HSG is a very popular imaging procedure for detecting tubal factor infertility. Oil-based and water-soluble contrast media are used in HSG.<sup>4</sup> Oil-based contrast medium is absorbed relatively slowly and may be stored in the fallopian tubes for a long time, resulting in tubal obstruction and adhesion formation.<sup>5</sup> Although one study reported higher pregnancy rates following the use of oil-based contrast medium, subsequent studies have reported no difference in pregnancy rates between oil-based and water-soluble contrast media (73.6% and 72.7% for oil-based and water-soluble contrast media, respectively).<sup>6</sup> Thus, water-soluble contrast medium is widely used at present because of their higher tissue affinity (which provides more detailed findings) and lower risk of complications, including embolism.<sup>5</sup> The contrast medium used in this case was oil-based; very few reports have described its absorption and metabolism in the body. Moreover, no

**FIGURE 3** Postoperative MRI on POD 10. The abnormal finding is hyperintense on T1W1 (A) and hypointense on fat suppression (B). This suggests that these findings may be Lipiodol. POD, postoperative day; MRI, magnetic resonance imaging; T1WI, T1-weighted imaging



previous study and systematic review has evaluated the causes of contrast medium retention and the common sites in which the remnants are found. Serum iodine concentrations are undetectable within 48 h after intraperitoneal iodine contrast medium administration; the urinary excretion rate is 13% at 7 days after administration, and the half-life of the medium is known to be relatively long at approximately 50 days.<sup>7</sup> In addition, it takes 6 months to 1 year for the medium to be completely absorbed from the abdominal cavity through the maternal lymphatic system.<sup>8</sup> This patient's clinical course (in which contrast medium residue was found incidentally approximately 10 months after HSG) is consistent with that described in previous reports.

Intra-abdominal adhesions can be considered a possible cause of contrast medium retention. The patient had a history of DIE, which may have contributed to the obstruction of HSG contrast medium drainage. However, no obvious adhesions were found in the pelvis at the time of surgery. We collected information about adhesive disease, however, the patient did not have any medical history of pelvic inflammatory disease (PID) including chlamydial infections, which closely contribute to the formation of abdominal adhesions. Pathogenically, PID appears to be a considerable cause of contrast medium retention. However, to our knowledge, there has been no report describing the relationship between PID and contrast medium retention. Finally, according to the information obtained from the ART-clinic, HSG did not show any abnormal findings in the uterus and fallopian tubes. Based on these findings and the literature, it was difficult to determine whether the retained contrast medium was due to intra-abdominal adhesions or simply due to an obstruction of the spontaneous evacuation process. These were the limitations of our case report. According to previous reports, 18% of couples have undergone infertility testing and treatment, and one in 17 of all births is a result of infertility treatment.<sup>9</sup> With this increase in the number of ART pregnancies, the implementation of HSG is becoming more common as a means of fertility work up.<sup>4</sup> Although only two studies have described postpartum residues of HSG contrast medium in Japan,<sup>10,11</sup> to our knowledge, this is the first report to highlight the importance of obtaining a medical history of HSG in the differential diagnosis of abnormal findings on postoperative radiography in the postoperative period. Furthermore, there is no report describing the prevalence and management of contrast medium retention or the proper postpartum follow-up plan in such patients. This could be attributed to the limited opportunities to perform routine abdominal radiography during pregnancy and the postpartum period (except after a caesarean section). Moreover, many pregnant women tend to avoid radiological imaging due to the

potential effects of X-ray exposure on the fetus, which is another reason why these examinations are rarely performed during pregnancy.

### 3.2 | Past history of ART facilitates the diagnosis of HSG contrast residue

A history of HSG in patients who conceived by ART can facilitate the diagnosis of postpartum contrast medium residue. In this case, a detailed evaluation of the patient's medical history led to the identification of the history of HSG, ultimately contributing to the diagnosis of contrast medium retention.

## 4 | CONCLUSIONS

We encountered a very rare case of long-term HSG contrast medium retention in the pelvis that was incidentally discovered on postoperative radiography and required differentiation from an intra-abdominal foreign material. With the increasing rates of ART-associated pregnancies, the usage of pre-conception HSG is also increasing. Thus, cases like ours can be expected to become more common in obstetric practice. The lessons from this case can be summarized as follows: (1) HSG contrast medium can remain in the pelvis for a long time, and (2) a medical history of ART and/or HSG can facilitate the differential diagnosis of abnormal findings on post-caesarean section radiography. When abnormal findings are observed in imaging examinations performed post-caesarean section in patients who undergo ART, the obstetrician should obtain a history of HSG to evaluate the possibility of HSG contrast medium retention as a differential diagnosis.

### AUTHOR CONTRIBUTIONS

HH and KF: wrote and conceived this case report. Thus, HH and KF should be considered joint first author. HH, KF, HK, SY, YC, HT, KS, and KO: directly and substantively managed this patient, collected data, and drafted and revised this manuscript. All authors read and approved the final version of this manuscript for submission.

### ACKNOWLEDGEMENTS

The authors received funding from a Grant-in-aid for Perinatal Emergency Medical Care (Osaka Medical Association). This funding was used to pay for English language editing service from Editage, which was endorsed by the Wiley journal group. The funder played no role in the study design, data collection, analysis, interpretation, or writing of our manuscript.

## CONFLICT OF INTEREST

All authors declare that they have no conflict of interest.

## DATA AVAILABILITY STATEMENT

The data and materials are available on request from the corresponding author.

## ETHICAL APPROVAL

Not applicable. Permission to use all data and information including patient's images and medical history from medical chart was obtained from the patient.

## CONSENT

Written informed consent was obtained from the patient to publish this report in accordance with the journal's patient consent policy.

## ORCID

Harue Hayashida  <https://orcid.org/0000-0002-3352-5845>

## REFERENCES

1. Capobianco G, Crivelli P, Piredda N, et al. Hysterosalpingography in infertility investigation protocol: is it still useful? *Clin Exp Obstet Gynecol.* 2015;42(4):448-451.
2. Dreyer K, van Rijswijk J, Mijatovic V, et al. Oil-based or water-based contrast for hysterosalpingography in infertile women. *N Engl J Med.* 2017;376(21):2043-2052.
3. Wang R, Watson A, Johnson N, et al. Tubal flushing for subfertility. *Cochrane Database Syst Rev.* 2020;10:CD003718.
4. Infertility workup for the Women's Health Specialist: ACOG Committee Opinion, Number 781. *Obstet Gynecol.* 2019;133(6):e377-e384.
5. US National Library of Medicine. Lipiodol-ethiodized oil injection. US Food & Drug Administration (FDA) approved

- product information. DOSAGE AND ADMINISTRATION, and 4. Contraindication. Revised June 2020. Accessed February 25, 2021. <https://dailymed.nlm.nih.gov/dailymed/drugInfo.cfm?setid=511d1f64-5cb9-4baa-a12396205467e59a> Section 2
6. van Rijswijk J, van Welie N, Dreyer K, et al. Tubal flushing with oil-based or water-based contrast at hysterosalpingography for infertility: long-term reproductive outcomes of a randomized trial. *Fertil Steril.* 2020;114(1):155-162.
7. Viamonte M Jr, Soto M, Recher L. Chronic toxicity study in dogs following intralymphatic injections of ethiodol, ethiodol with chlorophyll and sterile non-iodinized poppy seed oil. *Ind Med Surg.* 1966;35(8):688-695.
8. Wakabayashi Y, Hashimura N, Kubouchi T. Retained lipiodized oil misdiagnosed as residual metallic material. *Radiat Med.* 2004;22(5):362-363.
9. Ishihara O, Jwa SC, Kuwahara A, et al. Assisted reproductive technology in Japan: a summary report for 2018 by the Ethics Committee of the Japan Society of Obstetrics and Gynecology. *Reprod Med Biol.* 2021;20(1):3-12.
10. Takeyama K, Ishikawa R, Nakayama K, Suzuki T. Intraperitoneal residual contrast agent from hysterosalpingography detected following cesarean section. *Tokai J Exp Clin Med.* 2014;39(2):69-71.
11. Ohashi K, Kotera K, Ito S, Haraguchi M, Irie J. A case of prolonged retention of lipiodized oil suspicious for foreign material in the abdomen. *Jpn J Gynecol Obstet Endosc.* 2016;32(1):260-264.

**How to cite this article:** Hayashida H, Furuya K, Kurahashi H, et al. Incidental detection of retained oil-based hysterosalpingography contrast medium on postoperative postpartum radiography: A case report. *Clin Case Rep.* 2022;10:e05925. doi:[10.1002/ccr3.5925](https://doi.org/10.1002/ccr3.5925)